

Lead Poisoning in Zoo-dwelling Primates

B. C. ZOOK, R. M. SAUER, M. BUSH AND C. W. GRAY

Department of Pathology, School of Medicine, George Washington University, Washington, D.C. and the Division of Pathology and Animal Medicine, National Zoological Park, Smithsonian Institution, Washington, District of Columbia 20009

ABSTRACT Lead intoxication was diagnosed in 42 primates at the National Zoological Park. Diagnoses were made clinically by the observation of signs of encephalopathy and the finding of 200 μg lead or more/100 ml blood, or post-mortem by the presence of renal acid-fast intranuclear inclusion bodies and excess lead in liver specimens. Twenty-five of the primates had signs or lesions of lead encephalopathy.

Lead poisoning was most common in the Cercopithecidae, and in the summer months. Lead encephalopathy was most frequent in juveniles. Leaded paint on the monkey cages was determined to be the source of poisoning. Blood studies revealed slight hypochromic anemia and immature and stippled erythrocytes. Postmortem lesions included acid-fast intranuclear inclusions in renal tubular and other epithelial cells; metaphyseal bone changes (lead lines); necrosis of striated muscle fibers; and other lesions. Treatment of one monkey for encephalopathy was attempted and proved successful.

Lead poisoning was recently discovered to be a common affliction of primates at the National Zoological Park (NZP) (Zook et al., '72a). This disease occurred unrecognized as such for many years at NZP, and evidence has been reported that many primates in other zoos have been affected similarly for at least 57 years (Zook et al., '72a,b). The purpose of this report is to describe the occurrence, source of lead, clinical findings, and some laboratory and necropsy findings from accidentally lead-poisoned zoo primates. It is anticipated that this information will enhance recognition, enable diagnosis and treatment, and encourage prevention of lead poisoning in captive primates.

MATERIALS AND METHODS

Necropsy records of NZP primates ('55 to '68) were searched for cases in which history or lesions were suggestive of lead poisoning. Lead encephalopathy was diagnosed retrospectively in 14 primates by finding at least one of the following: (1) multiple acid-fast intranuclear inclusion bodies in renal proximal tubular or hepatic cells, (2) excess lead¹ in formalin-fixed liver specimens; 11 primates had 3.6 to 106

parts per million (ppm) lead in their livers (liver was not available from 3 monkeys); and history of typical acute central nervous system disorders and/or brain lesions typical of lead encephalopathy (Sauer et al., '70; Zook et al., '72a,b).

Sections of kidney available from all primates that died at NZP between September 1968 and April 1972 were examined for renal and hepatic acid-fast intranuclear inclusions. Typical inclusions, considered essentially pathognomonic for lead poisoning, occurred in 26 primates (not including the 14 primates with encephalopathy previously mentioned). Liver specimens from 22 of these contained 3.0 to 110 ppm lead (liver was not available in four). Lead encephalopathy was diagnosed in nine of these 26 primates; the remaining 17 were diagnosed as lead intoxication without encephalopathy. Forty-six monkeys had no acid-fast inclusions; they formed a non-lead-poisoned control group. Liver samples, randomly selected from 12 of these control monkeys, were tested for

¹Lead was analyzed in formalin-fixed liver specimens by G. Boylen, Massachusetts Institute of Technology, Cambridge, Mass., by a dithizone colorimetric technique; results are reported on a wet-weight basis.

TABLE 1

Comparison of necropsied zoo primates with lead encephalopathy, lead intoxication without encephalopathy, and no lead intoxication by primate family, age, and sex

Primate family	No lead intoxication	Lead intoxication without encephalopathy	Lead encephalopathy
Cercopithecidae	12	6	22
Hylobatidae	9	3	1
Lemuridae	3	4	0
Cebidae	7	4	0
Other ¹	15	0	0
Totals	46	17	23
Sex			
Females/males	22/24	7/10	9/9 ²
Age ³			
Juveniles/adults	10/36	1/16	18/5

¹ Includes eight Lorisidae and seven Callithricidae.

² Sex was unrecorded in five primates with encephalopathy.

³ Primates less than two years old were considered juveniles; those over two years were considered adults.

lead and were found to contain 0.3 to 2.5 ppm lead (mean 1.3 ppm).

Blood was collected from 62 NZP primates for lead analysis² and hematologic studies. Most of the samples (49) were collected and studied in June 1972. Fifty-eight of the blood specimens were taken from primates not known to suffer any medical disorders: three were from monkeys then suffering convulsions, and one individual had a history of repeated seizures over the past few years. Blood was similarly tested from two recently jungle-captured juvenile primates quarantined in galvanized cages and from 17 laboratory-raised rhesus (*Macaca mulatta*) held in stainless steel cages.

Sources of lead exposure for NZP primates were investigated. Samples of cage paint (Zook et al., '72a), primate diets, drinking water, air, and atmospheric fallout in and around the primate cages were analyzed for lead content.³

RESULTS

Occurrence. Lead intoxication was diagnosed in 40 primates necropsied at NZP ('55-'72). Twenty-six of these died during a 44 month period, 1968 to 1972. During that same period 46 primates, aged one month or older, died and on necropsy were found to have no evidence of lead poisoning. The occurrence of lead poisoning in necropsied primates for that period was 36%. Occurrence by family of primate, age, and sex is given in table 1. Of 60

blood-lead determinations of primates not included in the above necropsy series, 11 (18%) had 80 μg or more lead/100 ml blood, a level generally considered diagnostic of lead poisoning in man. Evidence of increased lead absorption (blood lead 40 to 79 $\mu\text{g}/100$ ml) occurred in 17 others. Blood from 19 non-zoo primates (assumedly never exposed to leaded paint) contained 9 to 30 μg lead/100 ml blood. Blood lead values according to primate family, age, and sex (table 2) and hematologic data (table 3) are given.

A seasonal occurrence was noted among the 40 necropsied primates with lead poisoning. Sixty percent of the monkeys died during the four months June through September; only 31% would be expected to die during that time, if the deaths were evenly distributed throughout the year. Only 48% of primates with lead encephalopathy, compared to 81% of those with lead poisoning but without encephalopathy, died during those four summer months.

Sources of lead. Paint samples from the bars and walls of all types of NZP primate enclosures were analyzed and

² Blood was collected in lead-free vials and analyzed for lead by atomic absorption spectroscopy by the District of Columbia Department of Public Health, Washington, D. C. Split samples analyzed by the same laboratory or by a different laboratory were within 10% accuracy.

³ Lead in primate food and water was analyzed by a dithizone colorimetric technique. Air and fall-out samples were collected over at least a 36 hour period by standard methods and analyzed for lead in collaboration with Dr. Ter Haar, Ethyl Corporation, Detroit, Michigan.

TABLE 2
Comparison of blood-lead values in zoo primates by primate family, age and sex

Primate family	Blood lead values ($\mu\text{g}/100\text{ ml}$)			
	0-39	40-79	80+	
			No encephalopathy	Encephalopathy
Cercopithecidae	23	10	7	4 ¹
Hylobatidae	0	2	0	0
Lemuridae	0	2	0	0
Cebidae	5	2	2	0
Pongidae	5	0	0	0
Totals	33	16	13	
Sex				
Females/males	14/19	9/7	4/5	4/0
Age ²				
Juveniles/adults	1/32	3/13	1/8	3/1

¹ Two primates with lead encephalopathy were necropsied and appear in table 1 under lead encephalopathy.

² Primates less than two years old were considered juveniles; those over two years were considered adults.

TABLE 3
Some hematologic data from primates compared to blood-lead values

Blood lead analyses Zoo primates	Blood lead values ($\mu\text{g}/100\text{ ml}$)			
	0-39	40-79	80+	
			No encephalopathy	Lead encephalopathy
No. observations	33	16	9	4
Mean ($\mu\text{g}/100\text{ ml}$)	21	60	130	354
Range ($\mu\text{g}/100\text{ ml}$)	05-39	41-77	80-210	201-580
<i>Non-zoo primates (controls)</i>				
No. observations	19	0	0	0
Mean ($\mu\text{g}/100\text{ ml}$)	14	—	—	—
Range ($\mu\text{g}/100\text{ ml}$)	9-30	—	—	—
<i>Erythrocyte values of zoo primates</i>				
No. observations	27	16	8	4
Mean hematocrit (%)	46	43	40	36
Basophilic stippling ¹	24	21	50	75
Nucleated erythrocytes ²	14	21	63	50

¹ Percent of primates having one or more stippled erythrocytes per 1000 erythrocytes.

² Percent of primates having one or more nucleated erythrocytes per 100 white blood cells.

found to contain two or more percent lead. Most indoor cage paint contained approximately 6 to 10% lead, and most outside cages had paint containing 12 to 67% lead. Many of the primates, especially young Old World monkeys, had been observed to gnaw repeatedly on painted cage bars. Primate drinking water and canned diet contained 0.03 ppm and 1.0 ppm lead respectively. Air sampled from inside the NZP primate house and in outside cages contained 1.2 and 1.4 μg lead/ m^3 respec-

tively. Atmospheric lead fall-out collected from outside primate cages was calculated to be 8.5 μg lead/ cm^2 /year.

Exposure of NZP primates to painted cages varied considerably in time before the onset of signs or sudden death occurred. Five of the primates born at NZP were only four to six months old when they died of encephalopathy. One monkey has been observed to start gnawing on painted bars at one month of age. Juvenile monkeys, not born at NZP, dwelt in the Zoo for as

little as two months before the onset of encephalopathy. Primates with lead intoxication but no encephalopathy dwelt at NZP for one to 18 years; most were here from two to five years before they died.

Clinical findings. Twenty-five NZP primates were diagnosed as having lead encephalopathy. Twenty-three died and had typical signs or brain lesions of lead encephalopathy; one monkey was successfully treated, and one has survived repeated seizures. Signs of encephalopathy, observed in 21 primates, were characterized by generalized clonic-tonic convulsions. Blindness, tremor, and paralysis commonly followed seizures. In most, these signs were followed by coma and death within a few hours to two to four days.

Recently a four-month old female mona monkey (*Cercopithecus mona*) suffered convulsions and was immediately hospitalized. Radiographs of the limbs were negative for lead lines but revealed radiopaque material in the colon. Lead-containing paint chips were eliminated from the colon shortly after an enema was given. Blood studies indicated 326 μg lead/100 ml, 31% hematocrit, stippled red blood cells (RBC), and ten nucleated RBC/100 leukocytes. Calcium ethylenediaminetetraacetate⁴ (Ca EDTA) was diluted to a 10% solution and administered subcutaneously at the dose of 50 mg/lb divided four times per day for five days. Dexamethasone⁵ was given, 2 mg on the first day and 1/4 mg twice a day thereafter. Supportive therapy included antibiotics, a multivitamin preparation, fluids, and electrolytes.

Tremors, apparent blindness and occasional convulsions occurred between periods of coma for the next two days. The monkey's condition improved gradually, and chelation therapy was discontinued after five days' treatment. At that time blood studies indicated 103 μg lead/100 ml, 35% hematocrit, stippled RBC, and 62 nucleated RBC/100 leukocytes. Five days without chelation was followed by another five-day course of Ca EDTA. After the last chelation therapy, the monkey's blood contained 81 μg lead/100 ml; the hematocrit was 43%, and stippled RBC were still present. The monkey was alert and showed no obvious after-effects.

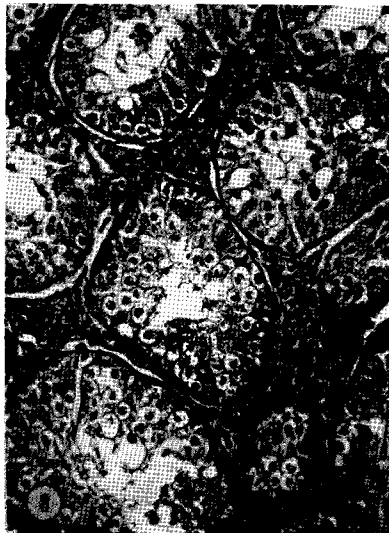
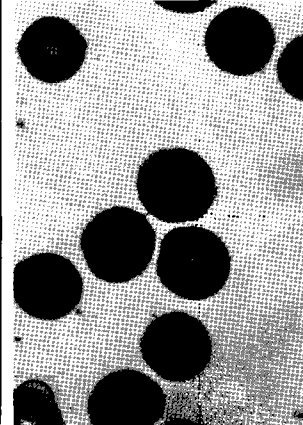
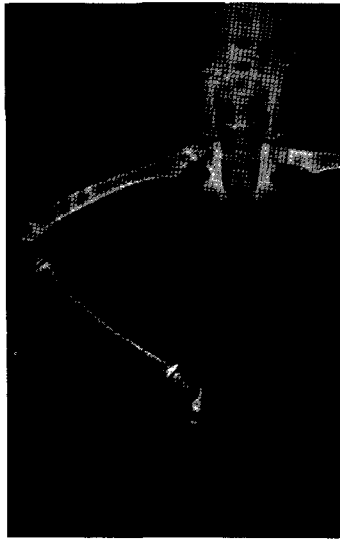Radiographic demonstration of lead lines

in bone (figs. 1, 2) and radiopaque material in the gastrointestinal tract (fig. 1) (later identified as particles of leaded paint) was obtained in two NZP primates. Signs specific for lead poisoning were not observed in the 17 necropsied primates that had lead intoxication without encephalopathy. Gastrointestinal disturbances were reported in some; most affected primates had a short course of anorexia and inactivity and suddenly died. In several animals, there were no reported signs; the animals were unexpectedly found dead. Hematologic studies in four primates with lead encephalopathy demonstrated lead values over 200 μg /100 ml, slight hypochromic anemia, and immature circulating erythrocytes with basophilic stippling (table 3, fig. 3). Leukocyte counts tended to be elevated due to a neutrophilia. Similar, but usually less marked, changes were seen in nine primates that had no observed signs but had blood levels of 80 μg or more lead/100 ml. Several primates, however, had no obvious changes in erythrocytes or leukocytes despite 100 μg or more lead/100 ml in the blood. Occasionally stippled RBC were seen in primates with normal (0-39 μg /100 ml) blood-lead levels and hematocrits.

Postmortem lesions. Gross lesions were generally non-specific. Twenty of 40 necropsied animals were thin, but only four were emaciated. Two primates had superficial wounds inflicted by cagemates. A Burtonian (lead) line was not seen in any primates, whether postmortem or clinical cases. Lesions not generally associated with lead poisoning occurred in several of the 17 primates that had lead intoxication without encephalopathy. These included mild purulent bronchopneumonia in two and acute necrotizing pancreatitis in one and non-specific enteritis and colitis in one other animal. Four ring-tailed lemurs (*Lemur catta*) died within 15 days of each other; all had foci of necrosis in liver and spleen and degenerative changes in the renal tubules. The changes resembled those of a septicemia; stains for *Leptospira* sp. were negative. One of the 23 primates that had lead encephalopathy had a marked bacterial pneumonia.

⁴ Calcium disodium versenate, Riker Laboratories, Northridge, California.

⁵ Azium, Schering Corp., Bloomfield, N. J.



Multiple intranuclear inclusion bodies were present in the renal proximal tubular epithelia in 39 primates (renal tissue was not available from one). The inclusions were eosinophilic and spherical and measured 3–10 μ in diameter (fig. 4). Thin sections (1 μ) revealed that the inclusions were often multiple, within a single nucleus, and of various sizes. The inclusions stained red with acid-fast stains in all primates; but a few inclusions in some primates were not acid-fast, and some inclusions stained variably. Occasionally the center of an inclusion stained more intensely than its periphery; or one inclusion stained pink, while those in adjacent nuclei stained deep red with acid-fast stains. The number and size of the intranuclear inclusions was directly related to the amount of lead found in the liver; the more numerous and the larger the inclusions, the more lead was found. Exceptions to this relationship occurred in four primates. In these, inclusions were large and numerous; yet the amount of lead found in formalin-fixed liver specimens was small (3.0 to 3.8 ppm). In all four of these primates, unlike the others, the tissues were partially autolysed.

Acid-fast intranuclear inclusions were present in hepatocytes in 40% of primates, usually those in which lead in the liver was over 10 ppm. Intranuclear inclusions were also seen in pancreatic acinar cells and adrenal cortical epithelial cells in four and two primates respectively. In the latter two organs the inclusions were small (2–4 μ) and stained poorly, if at all, with acid-fast stains. Renal proximal tubular and hepatocyte nuclei were frequently enlarged and had marginated chromatin, whether or not they contained inclusions (fig. 4). The karyomegaly was most pronounced in those primates with the most inclusions and the most lead in the liver. Swelling and vacuolation of renal and hepatic cells was common, but obvious necrosis of these cells was limited to a few scattered cells. Renal fibrosis was not observed.

Gray-white bands traversed the metaphyses of longitudinally sectioned bones in two juvenile primates (fig. 5). The bands (lead lines) were radiopaque and most obvious in the distal metacarpal, metatarsal, radius, ulna, tibia, and both

femoral metaphyses. Microscopically the bands were composed of numerous thick columns of cartilage extending from the epiphysis well into the metaphysis. The persistent cartilaginous trabeculae were lined by a thin layer of bone, and many large osteoclasts were present between trabeculae (fig. 6).

Necrosis of individual or small groups of skeletal and cardiac muscle fibers (fig. 7) occurred in approximately 50% of the primates. Cellular reaction and fibrosis accompanied the necrosis in a few, especially in the heart. Other lesions were hemosiderosis and hyperplasia of reticulo-endothelial cells in the spleen, hypercellularity of bone marrow, extramedullary hematopoiesis, and degenerative changes in testicles from four of 11 adult males and ovaries from one of two adult females. Testicular changes were characterized by degeneration or necrosis of germinal cells, a decrease or absence of spermatogenesis, and, in two, an apparent hyperplasia of interstitial cells (fig. 8). Ovaries from one specimen had fewer developing follicles than expected. Brain lesions will be described in a subsequent report.

DISCUSSION

The predominant occurrence of lead poisoning, and especially lead encephalopathy, in Cercopithecidae is not completely understood. Reports of acute amaurotic epilepsy (van Bogaert, '35; van Bogaert and Scherer, '38) recently shown to be caused by lead poisoning (Zook et al., '72b) and other reports of accidental lead intoxication, especially with encephalopathy, mostly involve Cercopithecidae (van Bogaert et al., '38; Cordy, '57; Hausman et al., '61; Houser and Frank, '70; Zook et al., '72b). All of the NZP primates, however, had essentially equal exposure to sources of lead except that paint in Lorisidae, Callithricidae, and Pongidae cages contained approximately half the lead found in other primate cages. Investigations to determine the cause of this Cercopithecidae family occurrence are presently underway.

The high occurrence of lead encephalopathy in juvenile simian primates was expected, as the young of other species are similarly affected by lead. The slight predominance of encephalopathy in female

juveniles was not statistically significant. The seasonal occurrence of lead poisoning in summer and early fall is evident in NZP primates and is well known in other species. A similar summer occurrence was reported in lead-poisoned monkeys diagnosed as having acute amaurotic epilepsy (van Bogaert et al., '38). The seasonal occurrence in NZP primates could have been influenced by the higher content of lead in the paint of outdoor cages where most of the primates dwelt during the summer months.

Significant sources of lead for NZP primates are essentially limited to lead-containing paint. The small amounts of lead in the food, air, and water of NZP primates are similar to those quantities available to most urban Americans and have not been shown to cause lead poisoning (National Research Council, '72). The lead-based paints and primers on NZP cages were apparently applied over many years. Lead-containing paint has been found in other zoos (Zook et al., '72a) and is likely to be present wherever animal enclosures are old and constructed of material that requires periodic painting.

Clinical signs of central nervous system disorders in captive primates should invoke suspicion of lead poisoning. Findings of diagnostic value are a significant source of lead, radiographic lead lines in bones of immature monkeys (de Bisschop, '56) radiopaque particles of lead in the gastrointestinal tract, and changes consistent with lead poisoning in the peripheral blood, i.e. slight hypochromic anemia and immature and stippled erythrocytes (Lambert and Desmedt, '66; Vermande-Van Eck and Meigs, '60). Some reports indicate that no basophilic stippling may be found (Hopkins, '70; Houser and Frank, '70). Analysis for lead in blood should in most cases confirm the diagnosis. If signs of encephalopathy are present, 150 μg or more of lead/100 ml may be expected. Lead intoxication without encephalopathy is difficult to diagnose in zoo primates, since signs of colic or alternate constipation and diarrhea would be at best difficult to observe. If, however, such signs are seen and typical hematologic changes are present, blood-lead values of 80 μg or more lead/

100 ml may be considered compatible with lead intoxication.

Treatment of lead encephalopathy with Ca EDTA appears to be as successful in simian primates as it is in children and other species. Enemas to remove lead from the intestines and dexamethazone to help relieve cerebral edema are recommended.

Postmortem diagnosis of lead poisoning may be indicated by the presence of acid-fast intranuclear inclusion bodies in renal proximal tubular epithelia (Cordy, '57; Hausman et al., '61; Houser and Frank, '70) and other cells. Bone changes in immature primates and brain lesions in those cases with nervous disorders are somewhat less specific but are also of diagnostic importance (Zook, '71; Zook et al., '72b). Analysis for lead in unfixed liver specimens should in most lead-poisonings reveal 5 ppm or more lead. Formalin-fixed samples of liver are also useful for lead determinations, especially for retrospective diagnosis. It is suspected that autolysed liver specimens may allow lead to leach into the formalin, as may have occurred in four primates in this study and in one monkey previously reported (Zook et al. '72b).

Lesions not generally associated with lead intoxication occurred in some primates that had lead poisoning without encephalopathy. The lesions may represent disease processes unrelated to lead intoxication; or possibly, lead poisoning may have predisposed these individuals to infections and other toxic conditions. It is well known that lead poisoning increases susceptibility to endotoxins in several species.

Prevention of lead poisoning in zoo primates requires the removal of paint accessible to the animals that contains 1% or more lead. It may be possible to cover some painted surfaces with materials that prevent the paint from being gnawed or peeled. Paint removal by torch or sandblasting may be dangerous to unprotected workmen or nearby species. Plans to remove the painted cages in the NZP primate house and replace them with materials that do not require painting are presently underway.

LITERATURE CITED

- Bisschop, de D. 1956 Un cas de saturnisme chez un gorille. Soc. Roy. Zool. d'Anvers unpublished communication to International Union Zoological Soc. Directors, Chicago, Illinois.)
- Bogaert, van L. 1935 L'épilepsie amaurotique aigue du singe. Bull. Acad. Roy. Med. Belg., 15: 244-245.
- Bogaert, van L., and H. J. Scherer 1938 Acute amaurotic epilepsy in *Macaca rhesus*. Arch. Neurol. Psychiat., 40: 521-547.
- Cordy, D. R. 1957 Osteodystrophia fibrosa accompanied by visceral accumulations of lead, Cornell Vet., 47: 480-490.
- Hausman, R., R. A. Sturtevant, and W. J. Wilson 1961 Lead Intoxication in Primates, J. Forens. Sci., 6: 180-196.
- Hopkins, A. 1970 Experimental lead poisoning in the baboon, Brit. J. Ind. Med., 27: 130-140.
- Houser, W. D., and N. Frank 1970 Accidental lead poisoning in a rhesus monkey (*Macaca mulatta*). J. Am. Vet. Med. Assoc., 157: 1919-1922.
- Lambert, D., and J. E. Desmedt 1966 La production de nevites experimentales chez le singe: premier essais d'intoxication chronique au plomb. C. R. Seances Soc. Biol. 160: 2504-2507.
- National Research Council 1972 Committee on Biological Effects of Atmospheric Pollutants: Lead, Airborne Lead in Perspective. Nat Acad. Sci., Washington, D. C.
- Sauer, R. M., B. C. Zook and F. M. Garner 1970 Demyelinating encephalomyelopathy associated with lead poisoning in nonhuman primates. Science, 169: 1091-1093.
- Vermande-Van Eck, G. J. and J. W. Meigs 1960 Changes in the ovary of the rhesus monkey after chronic lead intoxication. Fertility and Sterility, 11: 223-234.
- Zook, B. C. 1971 An animal model for a human disease — lead poisoning in nonhuman primates. Comp. Pathol. Bull., 3: 3-4.
- Zook, B. C., R. M. Sauer and F. M. Garner 1972a Lead poisoning in captive wild animals. J. Wildlife Diseases, 8: 264-272.
- 1972b Acute amaurotic epilepsy caused by lead poisoning in nonhuman primates. J. Am. Vet. Med. Assoc., 161: 683-686.

PLATE 1

EXPLANATION OF FIGURES

- 1 Radiograph of three-month old female celesbes ape (*Cynopithecus niger*). Lead lines appear in metaphyses of radius, ulna, femur, tibia and metatarsal bones. Radiopaque particles in colon are leaded paint chips.
- 2 Radiograph from primate of figure 1 demonstrates lead lines in distal radius, ulna, and metacarpal bones.
- 3 Basophilic stippled erythrocyte (near center) from blood of lead-poisoned mona monkey (*Cercopithecus mona*).
- 4 Intranuclear inclusion bodies (arrows) in swollen renal proximal convoluted tubular cells of lead-poisoned primate. Notice enlarged nuclei. H&E stain.
- 5 Distal radius in transverse section from gelada baboon (*Theropithecus gelada*). Lead line appears grossly as dense gray-white band (arrow) just distal to the epiphysis.
- 6 Metaphysis of radius from primate of figure 6. Lead lines are composed of persistent thick cartilaginous trabeculae thinly lined with bone. Notice the many large osteoclasts. H&E stain.
- 7 Foci of hyalinization and necrosis (center) of cardiac muscle in lead-poisoned monkey. H&E stain.
- 8 Testicle from adult lead-poisoned primate. Notice lack of sperm, pyknotic germ cells, and abundant interstitial cells. H&E stain.