

Clinical and Morphologic Findings of Familial Goiter in Bongo Antelope (*Tragelaphus eurycerus*)

C. A. SCHILLER, R. J. MONTALI, S. DOI, AND E. F. GROLLMAN

Department of Pathology, National Zoological Park, Smithsonian Institution, Washington, DC (CAS, RJM); and Laboratory of Biochemistry and Metabolism, National Institute of Diabetes and Digestive and Kidney Diseases, National Institutes of Health, Bethesda, MD (SD, EFG)

Abstract. Inherited defects of thyroglobulin synthesis resulting in congenital goiter are well described in certain breeds of domestic ungulates and in human beings. Goiter associated with synthesis of an abnormal thyroglobulin and the presence of thyroidal albumin was identified in five closely related bongo antelopes (*Tragelaphus eurycerus*). The goiter had an adult onset, and the affected bongos appeared to remain euthyroid with normal serum T3 and T4 values, normal serum cholesterol concentrations, and nonelevated concentrations of circulating thyroid stimulating hormone (TSH). Goitrous bongos had significant reproductive difficulties, including reduced cyclic activity and prolonged gestations, but were otherwise normal. Over the course of the disease, the thyroid glands greatly enlarged (up to 10 × 20 cm) and became polycystic. Microscopically, there was an admixture of giant colloid-filled follicles and follicles of normal size lined with variable follicular epithelium ranging from squamoid to mildly to moderately hyperplastic. The pathogenesis of goiter in the bongo may reflect a mixture of genetic predisposition coupled with environmental factors, including a period of exposure to a goitrogen.

Key words: Bongo antelope; defective thyroglobulin synthesis; familial; goiter; *Tragelaphus eurycerus*.

Congenital goiter associated with an inability to synthesize adequate amounts of normal 19S thyroglobulin (Tg) has been documented in human beings,^{8,9} Afrikaner cattle,¹⁸ Merino sheep,¹³ a mixed strain of Saanen and dwarf goats,¹⁷ and a mutant strain of mice (AKR.L-cog).²⁰ In the three domestic ungulate species, the thyroid gland produces no normal 19S Tg; instead, varying amounts of Tg-like proteins are present.^{2,4,12,21} Congenital goiter is inherited as an autosomal recessive trait in the domestic ungulate species,^{4,7,15} and in the goat it is associated with clinical hypothyroidism in kids and adults.¹⁷ Young goitrous Merino lambs and Afrikaner calves are hypothyroid; however, despite the large, often massive goiters, adults usually remain euthyroid.^{5,13,15}

In this report, we describe the morphologic and clinical findings in a group of closely related bongo antelopes (*Tragelaphus eurycerus*) with goiter. The goiter occurred in adulthood and was associated with the synthesis of an abnormal 19S Tg and the presence of thyroidal albumin.³ The goitrous bongos in this study were euthyroid, with thyroid hormones remaining normal to low normal;³ however, reproductive difficulties, including reduced cyclic activity, diminished conception rates, prolonged gestations, dystocias, and increased neonatal mortalities, were often present.

Materials and Methods

This study began in 1988 on bongo antelope Nos. 1 and 2 at the National Zoological Park (NZN) in Washington, DC, and it also included four other NZN bongos (Nos. 5-8) with case histories dating back to 1970. Table 1 lists the animals involved in the study, and Fig. 1 shows the close familial relationship of the goitrous bongos.

The foundation animals of the NZN herd, bongo No. 1 (female) and bongo No. 2 (male), were each obtained at approximately 1 year of age from the wild (western Africa). While exhibited at the NZN, bongo No. 1 was first noted with clinical goiter at 10 years of age, and bongo No. 2 was approximately 14 years old when noted to be goitrous. Bongo No. 1 died at 17 years of age after being gored by a cagemate, and bongo No. 2 was euthanatized at 16 years of age due to severe osteoarthritis.

Bongo Nos. 3 and 4 were from the Los Angeles Zoo and were also obtained from the wild. At the time of this study, both of the animals were at least 10 years old, and there was no evidence of clinical goiter. Bongo No. 5, the dam of bongo Nos. 7 and 8, was also not clinically goitrous. Necropsy at 8 years of age revealed no gross evidence of thyroid enlargement, and histologic examination of thyroid tissue was not performed. Bongo No. 6, a male with no relationship to the NZN founders that was euthanatized because of severe osteoarthritis at 9 years of age, had histologic and biochemical changes consistent with goiter.

Table 1. Bongo antelopes involved in study.

Animal No.	Sex	Source*	Residence	Presence of Goiter	Age at Appearance of Goiter (years)
1	F	WC	NZP	+	10
2	M	WC	NZP	+	14
3	F	WC	LA	-	
4	M	WC	LA	-	
5	F	NZP	NZP	-	
6	M	NZP	NZP	+§	9
7	F	NZP	NZP	+	7
8	F	NZP	NZP	+	10

* WC = wild caught; NZP = National Zoological Park, Washington, DC; LA = Los Angeles Zoo.
 § Microscopic evidence only.

Bongo Nos. 7 and 8, both females, developed goiters as adults at the NZP. Bongo No. 8 was euthanatized at 12 years of age due to adenocarcinoma of the cervix, and bongo No. 7 was alive at the time of this study. The maternal lineage of bongo Nos. 7 and 8 is identical, and for bongo No. 8, the sire was also the maternal grandfather (Fig. 1).

Since the arrival of bongo Nos. 1 and 2 at the NZP in 1970, the bongo herd at the NZP has had an average composition of one or two adult males and three or four adult females, with outside bongos introduced occasionally to prevent inbreeding and to maintain herd size. Between 1970 and 1990, the viable calf birth rate was approximately 1.4 animals/year. The bongos are housed in a fenced outdoor enclosure with free access to sheds.

Between 1970 and 1985, the bongos' diet consisted of a mixture of crushed roots, dried grasses, alfalfa pellets, sweet potatoes, apples, carrots, and cabbage in various amounts, all fed twice daily. Each animal received 5,000 g (about half of a head) of cabbage at each feeding or, when cabbage was not available, approximately the same amount of kale. In 1985, feeding cabbage and kale was discontinued.

Complete necropsies were performed on bongo Nos. 1, 2, 6, and 8, and multiple sections of thyroid gland were fixed in 10% neutral buffered formalin, embedded in paraffin, and sectioned at 5 µm. Sections were stained with hematoxylin and eosin (HE), Gömöri's trichrome, and periodic acid-Schiff. Thyroidal biopsy tissue from bongo No. 7 was processed in an identical manner.

Portions of the thyroid gland from bongo Nos. 6 and 8 and colloid extracted from a large follicular cyst from bongo No. 7 were also frozen at -70 C for Tg analysis. Serum samples from bongo Nos. 7 and 8 and from a number of clinically normal bongos were taken periodically for thyroid hormone measurements. Methods and results of thyroglobulin analysis and T3, T4, and rT3 evaluations have been published elsewhere.³

Serum cholesterol concentrations from bongo Nos. 1, 6, 7, and 8 and three clinically normal adult bongos were also determined periodically throughout the study. Samples were analyzed using Sigma reagents (Sigma Chemical Co., St. Lou-

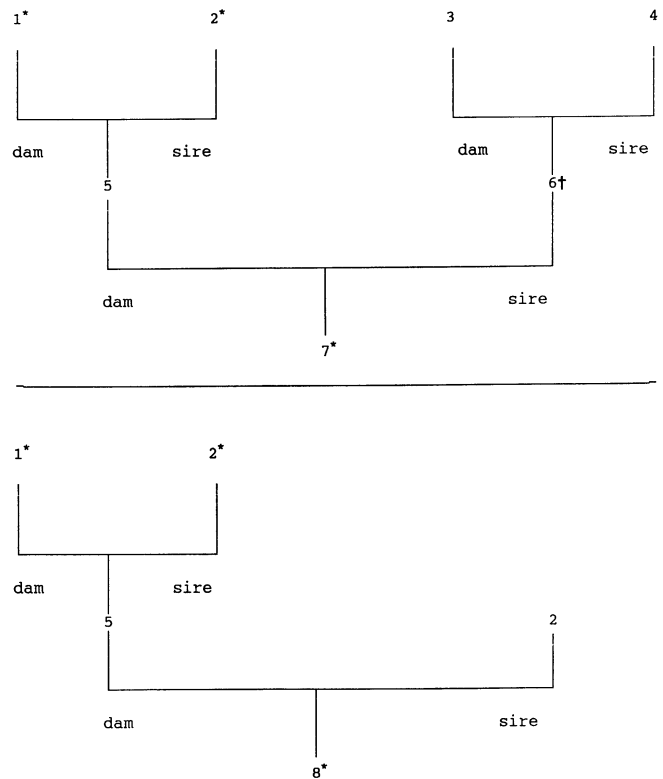


Fig. 1. Pedigree chart of goitrous Bongo antelopes. * = animal with clinical goiter; † = animal with microscopic goiter (no gross enlargement).

is, MO) on a Gemstar chemistry machine (Electro-Nucleonics, Fairfield, NJ).

Serum thyroid-stimulating hormone (TSH) values were determined randomly throughout the study on three clinically healthy adult bongos and on bongo Nos. 7 and 8 by radioimmunoassay (RIA) using two methods. With the first method, bovine TSH was iodinated (Hazelton Biotechnologies, Vienna, VA) by using lactoperoxidase to a specific activity of 154 µCi/µg, and rabbit anti-ovine TSH was used as provided. To the standards, ¹²⁵I-TSH (10,000 cpm/tube) was added followed by dilution in buffer (2 M ethylenediaminetetraacetic acid, 1% bovine serum albumin in phosphate-buffered saline [PBS]). Serum free of bovine TSH was also present in the assay and was made using a TSH affinity column prepared with anti-ovine TSH. Anti-ovine TSH was then added at a final dilution of 1:300,000. The assay mixture (total volume, 500 µl) was incubated overnight at 4 C after the addition of 1% bovine gamma globulin in PBS along with 14.67% ice cold polyethylene glycol (molecular weight = 8,000). Amerlax-M donkey anti-rabbit TSH at a quantity of 250 µl was used following the manufacturer's directions (Amersham, UK) (RIA protocol referenced from USDA Animal Hormone Program, and the National Hormone and Pituitary Program, Beltsville, MD, technical report No. 139). Radioactivity was measured using a Beckman Gamma 9000 (Beckman Instruments, Irvine, CA). The same samples were also assayed using a commercial RIA kit for human TSH




Fig. 2. Thyroid gland; bongo No. 8. The gland is enlarged (7×4.5 cm) and polycystic, with cysts ranging in size from 2 to 15 mm in diameter.

(Magic TSH, Ciba-Corning Immunodiagnostics, Medfield, MA).

Results

Clinical and gross pathologic findings

Bongo Nos. 3 and 4 had no clinical evidence of goiter. Histologic evaluation of the thyroid glands was not performed; thus microscopic goiter cannot be definitively ruled out. These animals had no further involvement in the study. The two male bongos (Nos. 2, 6) had clinical histories of intermittent and chronic lamenesses. Both had sired several calves; however, electroejaculation and semen collection from each had been unsuccessful the 2–3 years prior to their deaths. Bongo No. 2 was at least 16 years old when he was euthanatized due to severe degenerative osteoarthritis. At necropsy, both lobes of the thyroid gland were markedly enlarged (10×20 cm) and compressed the trachea dorsally. The thyroid contained numerous cysts, 1–9 mm in diameter, that were filled with clear yellow to red fluid (colloid) and a few cystic areas that contained caseous material. Bongo No. 6 (9 years old) was also euthanatized because of severe osteoarthritis. Apart from a few scattered cysts (up to 2 mm in diameter), the thyroid gland was normal.

Bongo No. 1 was approximately 17 years old when she died as a result of a gore wound. During the later years of her life she had numerous reproductive difficulties, including a prolonged gestation and associated in utero death with subsequent cesarean section delivery, chronic endometritis, and pyometra. She also had prolonged periods of noncyclic activity indicated behaviorally and by serial low serum progesterone concentrations. As a young adult she had delivered two

healthy calves. Both calves reached adulthood: one was bongo No. 5 and the other was shipped to another zoo and lost to further study. A throat mass thought to be an enlarged thyroid gland was first noted approximately 7 years prior to her death. At necropsy, the thyroid lobes were bilaterally enlarged, each 15×8 cm, and were polycystic, containing cysts up to 7 mm that were filled with yellow watery fluid.

Bongo No. 5, the dam of bongo Nos. 7 and 8, had no evidence of clinical goiter and at necropsy at 8 years of age there was no gross thyroid enlargement. Histologic examination of the thyroid tissue was not performed, and microscopic goiter cannot be ruled out. Bongo No. 8 was a 12-year-old female that had delivered one live calf at 3 years of age. Subsequent to that time, despite repeated breedings, no pregnancies occurred. Two years prior to her death, a mass within the cervix was identified by rectal palpation. During periodic clinical observation of the pelvic mass, a throat enlargement thought to be an enlarged thyroid gland was noted. The bongo was euthanatized because of the large cervical mass and secondary pyometra. At necropsy, the thyroid lobes were bilaterally enlarged, up to 7×4.5 cm, and contained many cysts from 2 to 15 mm in diameter filled with clear yellow to red fluid (Fig. 2).

Bongo No. 7, a 10-year-old female, was still alive at the completion of this study. Her reproductive history includes a dystocia associated with breech presentation and what was believed to be a prolonged gestation (normal gestation is approximately 280–285 days). A live, weak calf, extracted manually, lived for 6 months and then died of bacterial pyelonephritis. Vaginal and cervical prolapse and pyometritis occurred subsequent to the dystocia in bongo No. 7. The next year, a second

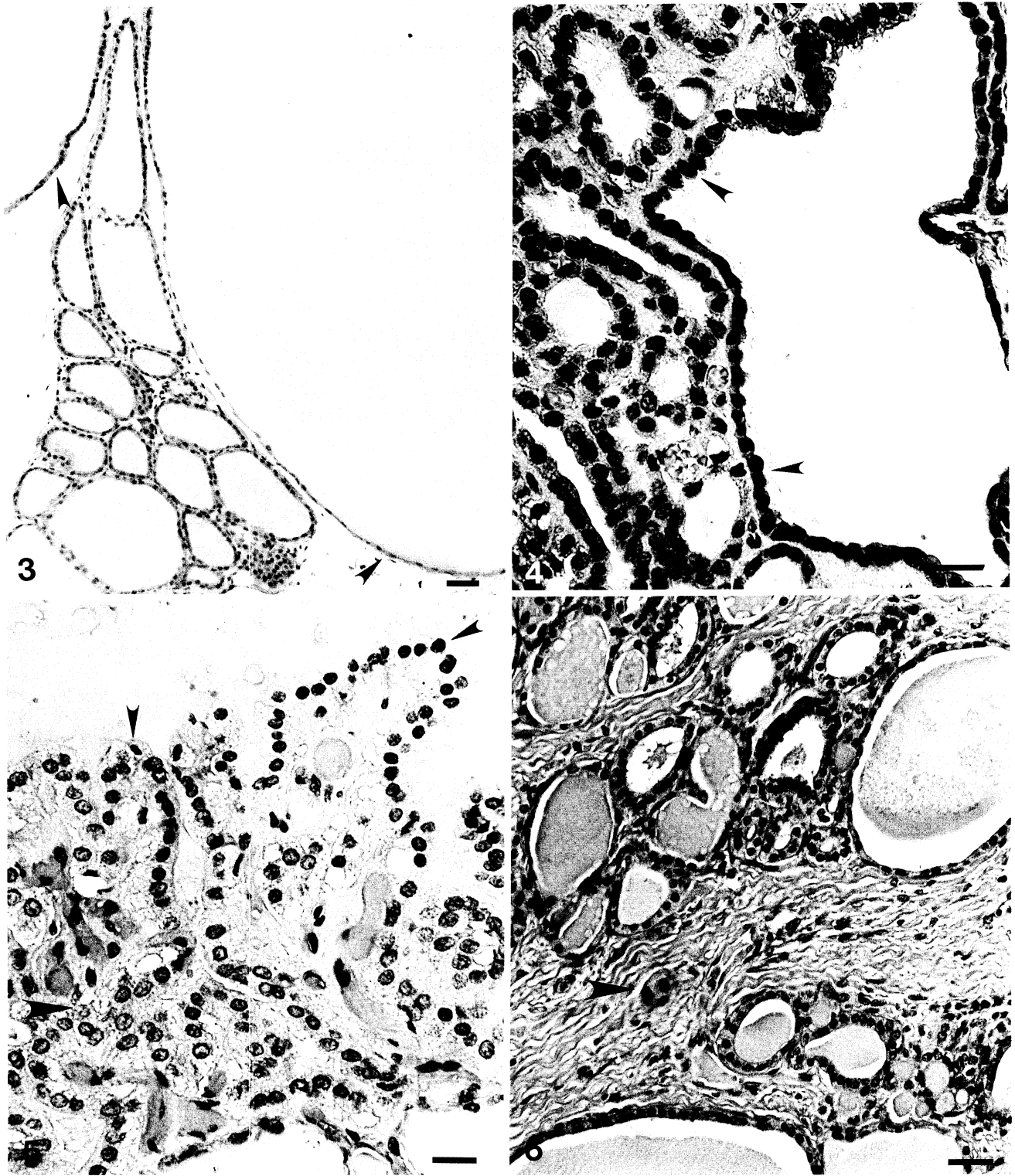


Fig. 3. Goitrous thyroid gland; bongo No. 8. Giant colloid-filled follicles are lined with squamous epithelium (arrowheads). HE. Bar = 200 μ m.

Fig. 4. Goitrous thyroid gland; bongo No. 7. Normal-sized, and large follicles contain colloid and are lined with cuboidal secretory epithelium in which some resorption vacuoles are present (arrowheads). HE. Bar = 50 μ m.

Fig. 5. Goitrous thyroid gland; bongo No. 8. Note the broad papillary fronds (small arrowheads) and collapsed hyperplastic follicles (large arrowhead), which contain little or no colloid. HE. Bar = 25 μ m.

Fig. 6. Goitrous thyroid gland; bongo No. 7. Follicular atrophy (arrowhead) and interfollicular fibrosis is present. HE. Bar = 100 μ m.

dystocia also thought to be associated with a prolonged gestation occurred, and a dead calf was delivered manually. An enlarged thyroid was noted, and during surgery to control chronic vaginal prolapse, the thyroid gland was evaluated and biopsied. The lobes were bilaterally enlarged, up to 12 × 8 cm, and polycystic, with cysts up to 4.5 cm that contained up to 50 ml of clear red to tan fluid.

Serum cholesterol concentrations

Serum cholesterol concentrations from goitrous and nongoitrous bongos are shown in Table 2. Values for goitrous bongos range from 92 to 126 mg/dl and for nongoitrous bongos from 64 to 130 mg/dl. These values are close to those established for domestic cattle (80–120 mg/dl).⁶

Serum TSH concentrations

All values (goitrous and nongoitrous bongos) for endogenous TSH were close to the lowest value on the standard curve (<0.156 ng/ml) or were not detectable by both the methods used. These results suggest that TSH values in the goitrous and nongoitrous bongos were not elevated.

Histologic lesions

The thyroid glands from bongo Nos. 1, 2, 7, and 8 were made up of a mixture of large and giant, colloid-filled follicles (Fig. 3), colloid-containing follicles of more normal size (Fig. 4), and some mildly to moderately hyperplastic follicular areas (Fig. 5). Giant follicles (up to 5 mm) were usually lined by a single layer of squamous epithelium that became more cuboidal in some areas (Fig. 3). Smaller follicles were lined by cuboidal to occasionally columnar epithelium, with some resorption vacuoles present (Fig. 4). There were also scattered small areas composed of collapsed, hyperplastic follicles containing little or no colloid (Fig. 5). The cuboidal and columnar follicular epithelium usually contained abundant periodic acid–Schiff (PAS)-positive apical cytoplasmic granules indicative of its secretory state, and the majority of the follicles were filled with homogenous, PAS-positive colloid. Some follicular lumina contained vacuolated colloid, a few exfoliated follicular cells, and occasional multinucleated follicular cells. Various degrees of interfollicular fibrosis with some compression of adjacent follicles was another consistent feature (Fig. 6).

The thyroid gland of bongo No. 6, which was not grossly goitrous, contained numerous giant, colloid-filled follicles lined with an admixture of primarily squamous epithelium with some taller, more active cells and some scattered areas of small collapsed, usually empty follicles. A few giant, colloid-filled follicles were also present in sections of the thyroid gland from

Table 2. Serum cholesterol values of nongoitrous (clinically normal) and goitrous bongo antelopes and normal domestic cattle.

Animal* No.	Sex†	Serum Cholesterol (mg/dl)	Date of Blood Sample
Nongoitrous bongos‡			
9	F	112	6 Dec. 1985
		130	2 Aug. 1987
10	F	123	20 June 1986
		129	16 Feb. 1988
11	M	79	14 May 1987
		64	13 Oct. 1987
Goitrous bongos			
1	F	92	24 April 1980
		97	20 June 1986
6	M	126	8 Aug. 1986
		112	8 Nov. 1985
7	F	103	28 Feb. 1989
		93	15 Nov. 1985
8	F	107	15 Oct. 1987
Domestic cattle		80–120§	

* All animals were adults when cholesterol was evaluated as part of total serum chemistry profile (exact age was often unknown).

† Values in females are of nonpregnant, nonlactating animals.

‡ Clinically healthy animals not included in study.

§ Normal value.⁶

the two calves of bongo No. 7. The remainder of the thyroidal tissue from these two calves was normal.

Discussion

The bongo antelope, a member of the family Bovidae, is the largest of the forest-dwelling antelopes and weighs between 150 and 220 kg. They are deep chestnut-brown with an intricate white stripe pattern, and both sexes have horns that spiral in one complete twist. The bongo is discontinuously distributed in western and eastern parts of the Lowland Forest zone of Africa and in several isolated populations in the montane forests of East Africa. Bongos in the wild are generally browsers and eat the tips, shoots, and trailers of many plants. They are the rarest large antelope and are considered one of the most beautiful of the bovids.^{10,14}

The close genetic relationship among the goitrous bongos strongly suggests that goiter is a familial condition. Breeding studies have determined that goiter in Afrikander cattle, Merino sheep, and Saanen-dwarf goats is inherited as a simple autosomal recessive trait.^{4,7,15} In these domestic species, heterozygote carrier animals are not clinically affected, although they may pass the defect. The findings in this study suggest the possibility of a similar defect in the bongo, but the low number of animals involved precludes any assumptions as to the mode of inheritance.

Biochemical studies of bongo thyroïdal tissue (bongo Nos. 6, 8) and of colloid (bongo No. 7) indicate that the majority of 19S Tg present has an apparent molecular mass of 220 kd instead of 245 kd, which is the normal apparent molecular mass of Tg.³ Goiter in domestic ungulates is also associated with synthesis of abnormal Tg. Afrikander cattle synthesize two abnormal Tg molecules that have sedimentation coefficients of 9S and 12S as opposed to normal 19S Tg.²¹ This synthesis is associated with a splicing defect in exon 9 of the Tg gene.¹⁶ Goiter in Saanen-dwarf goats is associated with a truncated Tg molecule with a sedimentation coefficient of 7S due to a defect in the structure of the Tg gene in exon 8.¹⁹

In addition to the presence of a Tg molecule of abnormal size, goiter in bongos is associated with the presence of iodinated thyroïdal albumin.³ Various amounts of iodinated albumin and albuminlike proteins are also present in the thyroids of Merino sheep,⁴ Afrikander cattle,²¹ Saanen-dwarf goats,² and human beings⁹ with congenital goiter. Iodinated albumin in the thyroïd gland and peripheral blood can be found in almost any circumstance where there is thyroïd enlargement.¹⁸ The site of synthesis, which could be extrahepatic, and the function of thyroïdal albumin is currently being investigated.

Plant goitrogens coupled with marginal iodine-deficient diets may result in severe hyperplastic goiter and congenital hypothyroidism in ruminants.¹ Cabbage or kale was part of the bongos' diet from 1970 through 1985 and may have contributed to goiter formation; however, the small amounts fed should not have resulted in the massive goiters seen. The stable iodine concentrations (¹²⁷I) from colloid of bongo No. 7 was 0.15 µg/mg protein and from thyroïd extract of bongo No. 6 was 0.56 µg/mg protein.³ These values are sufficient for thyroïd function and suggest that iodine deficiency was an unlikely solitary cause of goiter in these bongos.⁶ The pathogenesis of goiter in the bongo may reflect a mixture of a genetic predisposition, marginal iodine deficiency, and exposure to a goitrogen.

Serum cholesterol concentrations of goitrous bongos were within the normal range, as compared with clinically normal bongos and domestic cattle. The serum cholesterol concentration generally varies inversely with thyroïd activity, because thyroïd hormones increase the rate of cholesterol catabolism by the liver. The net effect of hypothyroidism is thus a decrease in hepatic catabolism resulting in an increase of serum cholesterol concentrations. Cholesterol concentrations alone have limited value as an index of thyroïd function, but used in conjunction with T4 levels they have predictive properties.⁶ The serum T4 concentrations of goitrous bongos ranged from 3.64 to 6.81 µg/dl.³ There have

been an insufficient number of bongos studied to establish normal thyroïd hormone values in this exotic species; however, the values obtained are similar to those found in domestic cattle serum measured under the same conditions (T4 = 5.34 ± 4.80 µg/dl, *n* = 4). Normal T4 concentrations and normal cholesterol concentrations suggest that goitrous bongos are euthyroid.

Goiter in the bongo does not appear to occur until adulthood, although the mild microscopic follicular changes seen in calves suggest that the condition may begin early in life. This is in contrast to goiter in domestic ungulates, which is congenital.^{5,12,13} Bongos with the large goiters are apparently able to compensate for the lack of normal 19S Tg by increased production of thyroïd proteins, and thus they remain biochemically euthyroid, as do goitrous Afrikander cattle.¹⁵ The significant reproductive difficulties seen in goitrous bongos suggest, however, that the concentrations of thyroïd proteins may not be adequate for maintenance of normal estrous cycles, conception rates, and pregnancy. In fact, the lowest T3 and T4 concentrations for bongo No. 7 (T3 = 0.79 ng/ml, T4 = 3.86 µg/dl)³ occurred when she was late in gestation. Other factors that may affect reproductive functions, such as nutritional imbalances (vitamin E deficiency), pituitary structural or functional (decreased gonadotrophins) abnormalities, or nonintact hypothalamic-pituitary-adrenocortical axis, have not been evaluated and cannot be ruled out as contributing to the reproductive conditions.

Bovine TSH and bongo TSH have been examined and found to have only minor amino acid differences in their proteins. This finding suggests that the biological activity of bongo TSH and domestic bovine TSH is similar and that bovine TSH antigen should cross-react with bongo TSH sufficiently to be clinically useful when determining endogenous TSH concentrations on the bongo. Goitrous bongos have nonelevated endogenous TSH values and normal to low normal amounts of circulating T3 and T4 as compared with clinically normal bongos and domestic cattle, which suggests that TSH is rapidly and continuously used to supply sufficient serum concentrations of thyroïd hormones. TSH concentrations appear to be high enough to result in an actively secretory state of some follicular epithelium present in scattered areas of goitrous bongo thyroïdal tissue.

The morphologic characteristics of bongo goiter are unique. The thyroïd glands were greatly enlarged and polycystic and made up of large to giant colloid-filled follicles with areas of collapsed empty follicles. Follicular epithelium ranged from inactive squamoid to active cuboidal and columnar. Cysts were sometimes lined with an admixture of both types of epithelium,

with some gradations between the two extremes. These findings represent changes seen in both hyperplastic and colloid goiters. Hyperplastic goiter is characterized by decreased concentrations of circulating thyroid hormones with continued increased TSH stimulation, resulting in small or collapsed follicles devoid of colloid and lined with hypersecretory cells.¹¹ This is the form present in congenital dysmorphogenetic goiter of Afrikander cattle, Merino sheep, and Saanen-dwarf goats; however, cysts lined with squamous cells are occasionally encountered.^{5,12,13} Colloid goiter, which is often associated with chronic iodine deficiency, occurs with the reduction of TSH stimulation of a hyperplastic thyroid usually after sufficient amounts of iodine have been added to the diet or after the requirement for thyroid hormones have diminished in an older animal.^{1,11} The resulting involution stage is characterized by colloid-filled large follicles lined with flattened inactive epithelium.^{1,11} The histologic picture in bongo goiter suggests primarily a colloid goiter with areas of hyperplastic tissue still remaining. The lack of elevation of serum TSH concentrations is consistent with this interpretation.

A low-molecular-weight iodinated material has been identified in the urine of goitrous Saanen-dwarf goats and in the urine of heterozygote pregnant females carrying goitrous kids.⁷ Unfortunately, no urine was available from goitrous bongos for analysis, but urinalysis could be a noninvasive screening method. Another finding in goitrous hypothyroid goats that may be beneficial to bongos with goiter is that excessive dietary iodine results in sufficient T3 and T4 to sustain clinical euthyroidism, although the goiters remain.²² Providing excessive dietary iodine for goitrous bongos may help prevent the reproductive difficulties encountered in this rare African antelope.

Acknowledgements

This study was supported by a Senior Research Grant (FONZ 90-80A to C. A. Schiller) from The Friends of the National Zoo. We thank Dr. M. Bush and L. Phillips, Department of Animal Health, National Zoological Park (NZN), for providing clinical samples and Vera Bonshock, Department of Pathology, NZN, for histologic sections. Bovine TSH was prepared by Dr. A. F. Farlow, Pituitary Hormones and Antisera Center, Torrance, CA. Rabbit anti-ovine TSH was provided by USDA, Animal Hormone Program, and the National Hormone and Pituitary Program, Beltsville, MD.

References

- 1 Capen CC: The endocrine glands. *In: Pathology of Domestic Animals*, ed. Jubb KVF, Kennedy PC, and Palmer N, 3rd ed., vol. 3, pp. 266–276. Academic Press, London, England, 1985
- 2 de Vijlder JJM, van Voorthuizen WF, van Dijk JE, Rijnberk A, Tegelaers WHH: Hereditary congenital goiter with thyroglobulin deficiency in a breed of goats. *Endocrinology* **102**:1214–1222, 1978
- 3 Doi S, Shifrin S, Santisteban P, Montali RJ, Schiller C, Grollman EF: Familial goiter in bongo antelope (*Tragelaphus eurycerus*). *Endocrinology* **127**:857–864, 1990
- 4 Dolling CE, Good BF: Congenital goitre in sheep: isolation of the iodoproteins which replace thyroglobulin. *J Endocrinol* **71**:179–182, 1979
- 5 Falconer IR, Roitt IM, Seamark RF, Torrigiani G: Studies of the congenitally goitrous sheep: iodoproteins of the goitre. *Biochem J* **117**:417–424, 1970
- 6 Kaneko JK: Thyroid function. *In: Clinical Biochemistry of Domestic Animals*, ed. Kaneko JK, 4th ed., pp. 631–649. Academic Press, London, England, 1989
- 7 Kok K, van Dijk JE, Fokkens RH, Gons MH, de Vijlder JJM: Prenatal diagnosis of a thyroglobulin synthesis defect in goats. *Acta Endocrinol* **110**:83–89, 1985
- 8 Lissitzky S, Bismuth J, Jaquet P, Casstay M, Michel-Becht M, Koutras DA, Pharmakoitid AD, Moschos A, Psarras A, Malamos B: Congenital goiter with impaired thyroglobulin synthesis. *J Clin Endocrinol Metab* **36**:17–29, 1973
- 9 Medeiros-Neto GA, Knobel M, Cavaliere H, Simonetti J, Mattar E: Hereditary congenital goitre with thyroglobulin deficiency causing hypothyroidism. *Clin Endocrinol* **20**:631–641, 1983
- 10 Nowak RM, Paradiso JL: Artiodactyla; Bovidae; genus *Tragelaphus*. *In: Walker's Mammals of the World*, 4th ed., vol. 2, pp. 1233–1239. Johns Hopkins University Press, Baltimore, MD, 1983
- 11 Olen E: The fine structure of experimentally induced hyperplastic and colloid goiter in the hamster. *Lab Invest* **21**:336–345, 1969
- 12 Pammenter M, Albrecht C, Liebenberg W, van Jaarsveld P: Afrikander cattle congenital goiter: characteristics of its morphology and iodoprotein pattern. *Endocrinology* **102**:954–965, 1978
- 13 Rac R, Hill GN, Pain RW: Congenital goitre in Merino sheep due to an inherited defect in the biosynthesis of thyroid hormone. *Res Vet Sci* **9**:209–223, 1968
- 14 Ralls K: *Tragelaphus eurycerus*. *In: Mammalian Species*, No. 111, pp. 1–4. American Society of Mammalogists, Washington, DC, 1978
- 15 Ricketts MH, Schulz K, van Zyl A, Bester AJ, Boyd CD, Meinhold H, van Jaarsveld PP: Autosomal recessive inheritance of congenital goiter in Afrikander cattle. *J Hered* **76**:12–16, 1985
- 16 Ricketts MH, Simons MJ, Parma J, Mercken L, Ding Q, Vassart G: A nonsense mutation causes hereditary goitre in the Afrikander cattle and unmasks alternative splicing of thyroglobulin transcripts. *Proc Natl Acad Sci USA* **84**:3181–3184, 1987
- 17 Rijnberk A, de Vijlder JJM, van Dijk JE, Jorna TJ, Tegelaers WHH: Congenital defect in iodothyronine synthesis. Clinical aspects of iodine metabolism in goats with congenital goitre and hypothyroidism. *Br Vet J* **133**:496–503, 1977
- 18 Robbins J, van Zyl A, van der Walt K: Abnormal thy-

- roglobulin in congenital goiter of cattle. *Endocrinology* **78**:1213–1223, 1966
- 19 Sterk A, van Dijk JEE, Veenboer GJM, Moorman AFM, de Vijlder JJM: Normal-sized thyroglobulin messenger ribonucleic acid in Dutch goats with a thyroglobulin synthesis defect is translated into a 35,000 molecular weight N-terminal fragment. *Endocrinology* **124**:477–483, 1989
- 20 Taylor BA, Rowe L: The congenital goiter mutation is linked to the thyroglobulin gene in the mouse. *Proc Natl Acad Sci USA* **7**:1986–1990, 1987
- 21 van Jaarsveld P, van der Walt B, Theron CN: Afrikaner cattle congenital goiter: purification and partial identification of the complex iodoprotein pattern. *Endocrinology* **91**:470–482, 1972
- 22 van Voorthuizen WF, de Vijlder JJM, van Dijk JE, Tegelaers WHH: Euthyroidism via iodide supplementation in hereditary congenital goiter with thyroglobulin deficiency. *Endocrinology* **103**:2105–2111, 1978