

MORTALITY OF CAPTIVE TORTOISES DUE TO VIVIPAROUS NEMATODES OF THE GENUS *PROTRACTIS* (FAMILY ATRACTIDAE)

B. A. Rideout,¹ R. J. Montali,² L. G. Phillips,² and C. H. Gardiner³

ABSTRACT: Between September 1982 and January 1984, verminous colitis was diagnosed post mortem in eight red-footed tortoises (*Geochelone carbonaria*) and three leopard tortoises (*Geochelone pardalis*) from the reptile collection of the National Zoological Park. This represented 69% of 16 tortoise necropsy accessions for that period. Etiology was determined to be a viviparous pinworm-like nematode of the genus *Protractis* (Family Atractidae). Clinical signs were either nonspecific, consisting of anorexia, lethargy, and depression, or were absent. Limited trials with piperazine citrate and fenbendazole appeared to be ineffectual against the parasite and supportive therapy was unsuccessful. Post mortem examination revealed roughening and thickening of the mucosa of the cecum and colon, and in severe cases myriads of tiny (0.5-1.0 cm) nematodes were evident on the mucosal surface. In six tortoises, worms were found also in the small intestine. Histopathologic features in severe cases included mucosal necrosis with parasites and mixed inflammatory cells extending into the tunica muscularis. Focal to diffuse lymphoplasmacytic infiltrates were present consistently in the submucosa of the cecum and colon, and similar but milder lesions occasionally occurred in the small intestine.

INTRODUCTION

Nematodes of the family Atractidae (Travassos, 1919), genus *Protractis* were first described in 1971 (Caballero R., 1971) and evidence so far indicates that their host range is limited to tortoises. Like oxyurids, protractids inhabit the lower digestive tract and the life-cycle is direct, with infection occurring by the fecal-oral route. Protractids are viviparous, however, and larvae are able to complete the life-cycle without leaving the host.

The only published report of infection by *Protractis* sp. is Caballero's original report in 1971 and no mention is made of clinical or pathologic abnormalities associated with the infection. The purpose of this report is to describe the pathological findings in eight mature red-footed tor-

toises (*Geochelone carbonaria*) and three mature leopard tortoises (*Geochelone pardalis*) found to have infections of *Protractis* at necropsy and to discuss the pathogenesis, treatment and prevention of infection.

MATERIALS AND METHODS

In late 1980 the National Zoological Park moved its collection of 15 red-footed and 13 leopard tortoises to a temporary holding facility. In May 1981, the zoo acquired an additional 14 wild-caught red-footed tortoises which, due to a shortage of space, were added to the existing population in the holding facility.

While in the holding facility, the tortoises were kept on a substrate of hay. Although fecal material was removed daily, the hay was changed less regularly. In August 1981, the tortoises were moved to a new enclosure, approximately 6 m across the front viewing window, 8 m across the back, and 4 m deep with a plastic-coated concrete floor. Although the thermostats were set at 32 C, that temperature was not reached at floor level, so heat lamps were added. The exhibit was hosed and scrubbed with a brush daily. Once a week from late spring to fall the tortoises were locked out in a grass sideyard and the floor scrubbed with a solution of sodium hypochlorite.

The diet consisted of apples, oranges, bananas, carrots, sweet potatoes, green beans, kale,

Received for publication 4 March 1986.

¹ School of Veterinary Medicine, University of California, Davis, California 95616, USA.

² Departments of Pathology and Animal Health, National Zoological Park, Washington, D.C. 20008, USA.

³ Department of Veterinary Pathology, Armed Forces Institute of Pathology, Washington, D.C. 20306, USA.

hard-boiled eggs, canned dog food and a powdered multi-vitamin supplement (Pervinal, U.S. Vitamin and Pharmaceutical Corp., 303 South Broadway, Tarrytown, New York 10591, USA). This was spread on the floor of the enclosure twice a week. The red-footed tortoises also were given adult mice once a week, and additional kale was provided for all the tortoises on 2 alternate days per week.

Eleven affected tortoises were either found dead or were presented with anorexia, lethargy and depression. Three tortoises developed a mucoid diarrhea terminally. Dehydration was variable. The severity of infection did not always appear to influence the severity of clinical signs, but since a large number of tortoises were being held in the exhibit some clinical signs may have been overlooked. Tissues were fixed in buffered 10% formalin, embedded in paraffin, sectioned at 6 μ m and stained with hematoxylin and eosin. Parasites were collected and placed in buffered 10% formalin for later identification. Voucher specimens have been deposited in the U.S. National Parasite Collection, Beltsville, Maryland 20705, USA, Accession number USNM 79266. Specimens from affected colonic mucosa were plated on 5% sheep blood agar, MacConkey's agar, Salmonella-Shigella agar and gram-negative broth. When growth occurred, identification of bacteria was coded out with the Analytical Profile Index system (Analytical Products, 200 Express Street, Plainview, New York 11803, USA).

In some cases, fecal examinations were performed prior to death by a sugar flotation/centrifugation method and by direct smear. In tortoises that were positive for the worms and/or larvae, limited trials with two anthelmintics were performed. In the first trial, fenbendazole (Panacur, American Hoechst Corp., Somerville, New Jersey 08876, USA) was given orally to 27 tortoises at a dosage of 12 mg/kg of body weight daily for 5 days. The second trial, was conducted on the same tortoises approximately 2 mo after the first trial with piperazine citrate. Fecal examinations were repeated at the end of both trial periods. Health records were reviewed retrospectively for clinical signs and treatment modalities.

RESULTS

Treatment varied depending on the severity of signs and whether parasitism was suspected or confirmed. If parasitism was not suspected, empirical treatment consisted of systemic antibiotics, subcuta-

neous fluids, vitamins, and in some cases, forced feedings via stomach tube. No improvement was seen with this form of therapy and the animals usually died 2–4 wk after the onset of signs. Fecal examinations were not performed initially, but shortly after the first mortality due to the worms was discovered, *Protractis* sp. larvae were identified by direct smear of a composite fecal sample from five other tortoises.

All tortoises treated with piperazine citrate and fenbendazole remained infected with *Protractis* sp. as determined by fecal analysis.

During the study period, 16 tortoises died, resulting in a crude mortality rate of 29.1%. Eleven of the 16 (69%) had infections of *Protractis* sp., and in seven of these, verminous colitis was determined to be the cause of death based on histopathological findings and the absence of other significant lesions. The cause-specific mortality rate for this period was 12.7%. Since only adult animals were exhibited in this enclosure, no age relationship could be determined. There did not appear to be any host species differences in prevalence or severity of infection.

The most prominent feature on gross examination was roughening and thickening of the mucosa of the cecum and proximal colon (Fig. 1). The mucosa had a greenish discoloration in several tortoises and mucosal petechiae were seen in the colon of one. In the most severely affected tortoises, myriads of tiny nematodes (0.5–1.0 cm in length) were on the mucosal surface and within luminal contents. With a dissecting microscope the worms were either lying on or embedded in the mucosa and in one case, they were attached to a necrotic membrane on the mucosal surface.

In six tortoises, worms were found in the small intestine as well. Multiple, small (2–4 mm) white foci were seen on the serosal surface of the distal jejunum in two




FIGURE 1. Roughened and thickened mucosal surface of proximal colon of a red-footed tortoise infected with *Protractis* sp. (parasites not visible).

of these tortoises. In another case, the worms were attached to the jejunal mucosa, which was roughened and hyperemic.

In the most severe cases, there was extensive necrosis of the colonic mucosa, in which numerous protractids were embedded. Mixed inflammatory cells infiltrated deeply into the intestinal wall (Fig. 2). Sections of the parasites in the lesions had the following microscopic characteristics: prominent lateral alae, a thin cuticle, platymyarian musculature, lateral chords, and a prominent digestive tract lined by columnar cells (Fig. 3). Uteri of the viviparous female worms were often filled with larvae (Fig. 4). In all cases, there was increased submucosal lymphoplasmacytic infiltration in the lamina propria of affected ceca and colons. The submucosa was edematous in several cases and mucus, sloughed cells and protractids

often filled the lumen of the intestine. In a few specimens, parasites were present only in the lumen.

The most prominent microscopic change in the small intestine attributed to the parasites was a mild increase in submucosal lymphoplasmacytic infiltration. Sections of parasites were seen in the lumen of the small intestine in five cases and within the lumen, submucosa, and muscularis in one case. In the latter, autolysis obscured evaluation of the type and extent of cellular infiltrate.

Occasionally, other parasites were found in intestinal tissue sections, but none appeared to be eliciting an inflammatory response. Among these were *Balantidium* sp. in the lumen of the large intestine and flagellates in the lumen of the small and large intestine. A colitis due to *Entamoeba invadens* was a complicating factor in one case. Eggs of trematodes and *Kali-*



FIGURE 2. Large intestine of red-footed tortoise with numerous *Proatractis* sp. embedded in necrotic mucosal plaque (AFIP MIS #83-6527). H&E, $\times 60$.

cephalus sp. were detected also on an antemortem fecal exam in several tortoises.

Colonic cultures yielded *Aeromonas* sp. in one case and several types of gram-negative enteric bacteria in another. *Edwardsiella tarda* was isolated in pure culture from the liver of the tortoise with secondary amebic colitis.

DISCUSSION

Reptiles are hosts for a wide variety of protozoan and metazoan parasites and the numbers of parasites are often high (Frank, 1981; Marcus, 1981; Frye, 1981). Oxyurid pinworms are among the most common parasites found in tortoises (Marcus, 1981), however, most authors consider them non-pathogenic (Telford, 1971;

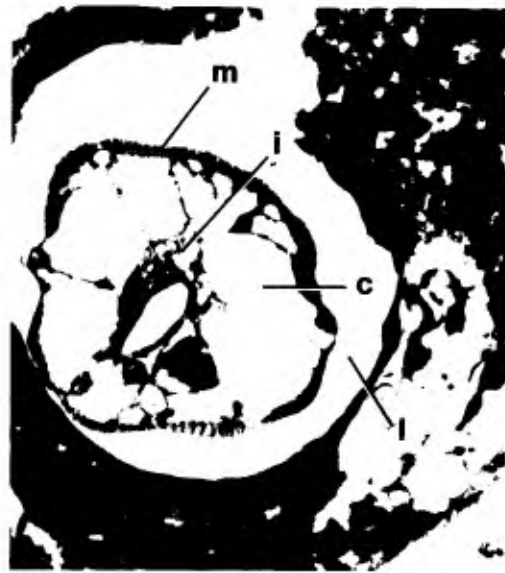

FIGURE 3. Cross-section through posterior end of female *Proatractid* sp. in large intestine of a red-footed tortoise. c, lateral chord; i, intestine; l, lateral ala; m, platymyarian musculature (AFIP MIS #83-6525). H&E, $\times 630$.

Frank, 1981; Marcus, 1981). It has even been suggested that pinworms benefit the host by breaking up fecal masses, preventing constipation (Telford, 1971).

The present report demonstrates that a pinworm-like nematode of the family Atractidae is capable of causing significant morbidity and mortality in captive tortoises. Like other pinworms they are probably of little consequence when present in small numbers in the lumen of the intestine. Unlike most pinworms however, proatractids are viviparous and the larvae are capable of completing the life cycle without leaving the host. This potential for internal autoinfection accounts in part for the enhanced pathogenicity of this parasite. If the host is stressed or debilitated, massive accelerated infections and increased invasiveness apparently result, similar to the hyperinfections of *Strongyloides* in human and non-human primates (Dwork et al., 1975; Toft, 1982).

Several factors probably contributed to

captivity-induced stress and the spread of the infection in this study. The addition of fourteen wild-caught tortoises to the temporary holding facility caused overcrowding. The source of infection was not determined, but the parasite may have been introduced with these wild-caught tortoises. The conditions in the holding facility would have encouraged the spread of infection to the other tortoises. The sanitation and overcrowding problems were largely corrected when the tortoises were moved to the new exhibit.

The effect of malnutrition on susceptibility to infections is well known (Beisel, 1982; Watson and Petero, 1984), and should not be overlooked in outbreaks of this kind. Although the quality of the diet was excellent, increasing the amount being fed seemed to significantly reduce further morbidity and mortality.

The presence of worms in the small intestine of six of the tortoises was an unexpected finding since protractids normally inhabit the lower digestive tract. This may just represent a transient or aberrant luminal migration since there was more severe large intestine involvement in each of these cases. However, in at least one case, invasion of the small intestine occurred.

Bacteria isolated from colons affected with protractids were considered as secondary invaders.

Attempts to treat protractid infections with ivermectin have yielded inconclusive results (Teare and Bush, 1983) and subsequent limited trials reported in the present study with piperazine citrate and fenbendazole were ineffectual in controlling this parasite. Further research is needed to clarify the possible efficacy of other available anthelmintics against this parasite. Even if complete elimination of *Protractis* is not possible, reducing the intensity of infection with anthelmintics may allow restoration of a commensal relationship.

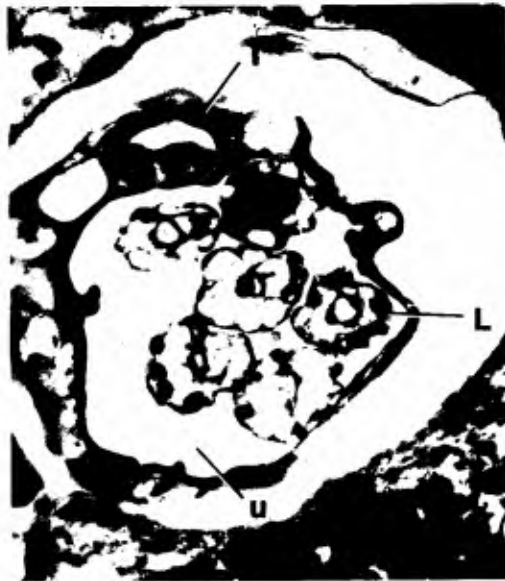

FIGURE 4. Cross-section of gravid female *Protractis* sp. in large intestine of a red-footed tortoise. Note numerous larvae within uterus. i, intestine; l, larva; u, uterine lumen (AFIP MIS #83-6526). H&E, $\times 630$.

Since clinical signs were nonspecific and may have been absent or difficult to detect, preventing introduction of this parasite into a collection requires routine fecal examinations for incoming animals. Only larvae are shed in the feces, so a direct smear, examination of sediment, or use of a Baermann apparatus would be more reliable than fecal flotation in identifying infected animals (Georgi, 1985).

Although this parasite is still present in the reptile collection of the National Zoological Park, as a result of improved husbandry there have been no parasite-related deaths since January of 1984.

ACKNOWLEDGMENTS

The authors would like to thank Dr. Benjamin Tuggle for assistance with parasite identification, Dr. Mitchell Bush for reviewing the manuscript, and Michael Davenport for providing historical information. This project was funded by a Friends of the National Zoo summer traineeship in pathology for Bruce Rideout.

LITERATURE CITED

- BEISEL, W. R. 1982. Synergism and antagonism of parasitic diseases and malnutrition. *Rev. Infect. Dis.* 4: 746-750.
- CABALLERO R., G. 1971. Contribucion al conocimiento de los nematodos que parasitan los reptiles de Mexico. *Rev. Biol. Trop.* 18: 149-154.
- DWORK, K. G., J. R. JAFFE, AND H. D. LIEBERMAN. 1975. Strongyloidiasis with massive hyperinfection. *N.Y. State J. Med.* 75: 1230-1234.
- FRANK, W. 1981. Endoparasites. *In* Diseases of the Reptilia, Vol. 1, J. E. Cooper and O. F. Jackson (eds.). Academic Press, London, 386 pp.
- FRYE, F. L. 1981. Biomedical and Surgical Aspects of Captive Reptile Husbandry. Veterinary Medicine Publishing Co., Edwardsville, Kansas, 456 pp.
- GEORGI, J. R. 1985. Parasitology for Veterinarians. W. B. Saunders Company, Philadelphia, Pennsylvania, 344 pp.
- MARCUS, L. C. 1981. Veterinary Biology and Medicine of Captive Amphibians and Reptiles. Lea and Febiger, Philadelphia, Pennsylvania, 239 pp.
- TEARE, J. A., AND M. BUSH. 1983. Toxicity and efficacy of ivermectin in chelonians. *J. Am. Vet. Med. Assoc.* 183: 1195-1197.
- TELFORD, S. R. 1971. Parasitic diseases of reptiles. *J. Am. Vet. Med. Assoc.* 159: 1644-1652.
- TOFT, J. D. 1982. The pathoparasitology of the alimentary tract and pancreas of nonhuman primates: A review. *Vet. Pathol.* 19(Supp. 7): 44-92.
- WATSON, R. R., AND T. M. PETRO. 1984. Resistance to bacterial and parasitic infections in the nutritionally compromised host. *C.R.C. Crit. Rev. Microbiol.* 10: 297-315.