

**First Report of *Protechinostoma mucronisertulatum*
(Echinostomatidae) in a Sandhill Crane (*Grus canadensis*) from
Saskatchewan, Canada**

Author(s): Jamie L. Rothenburger, Eric Hoberg, and Brent Wagner

Source: Comparative Parasitology, 83(1):111-116.

Published By: The Helminthological Society of Washington

DOI: <http://dx.doi.org/10.1654/1525-2647-83.1.111>

URL: <http://www.bioone.org/doi/full/10.1654/1525-2647-83.1.111>

BioOne (www.bioone.org) is a nonprofit, online aggregation of core research in the biological, ecological, and environmental sciences. BioOne provides a sustainable online platform for over 170 journals and books published by nonprofit societies, associations, museums, institutions, and presses.

Your use of this PDF, the BioOne Web site, and all posted and associated content indicates your acceptance of BioOne's Terms of Use, available at www.bioone.org/page/terms_of_use.

Usage of BioOne content is strictly limited to personal, educational, and non-commercial use. Commercial inquiries or rights and permissions requests should be directed to the individual publisher as copyright holder.

Research Note

First Report of *Protechinostoma mucronisertulatum* (Echinostomatidae) in a Sandhill Crane (*Grus canadensis*) from Saskatchewan, Canada

JAMIE L. ROTHENBURGER,^{1,4} ERIC HOBERG,² AND BRENT WAGNER³

¹Department of Pathology, Western College of Veterinary Medicine, University of Saskatchewan, 52 Campus Drive, Saskatoon, Saskatchewan, Canada, S7N 5B4 (e-mail: jamie.rothenburger@gmail.com),

²United States National Parasite Collection, Agricultural Research Service, USDA, Beltsville Area Research Center, BARC East 1180, 10300 Baltimore Avenue, Beltsville, Maryland 20705, U.S.A. (e-mail: eric.hoberg@ars.usda.gov), and

³Department of Microbiology, Western College of Veterinary Medicine, University of Saskatchewan, 52 Campus Drive, Saskatoon, Saskatchewan, Canada, S7N 5B4 (e-mail: brent.wagner@usask.ca)

ABSTRACT: We report a new host record for *Protechinostoma mucronisertulatum*. These small trematode parasites were found in a debilitated, immature, male sandhill crane (*Grus canadensis*) during autumn migration from the Canadian prairies. Necropsy examination identified fibrinonecrotizing and ulcerative jejunitis with a focal perforation and associated local fibrinous coelomitis. Cross sections of *P. mucronisertulatum* were present within lesions, although their role in the pathogenesis of these lesions is undetermined. Prior reports of natural infections attributed to these flukes are rare and have been limited primarily to sora rails (*Porzana carolina*) from the central North American flyway. Specimens in the sandhill crane were morphologically consistent with the original description; we provide the first complete series of measurements from flukes derived from a natural infection.

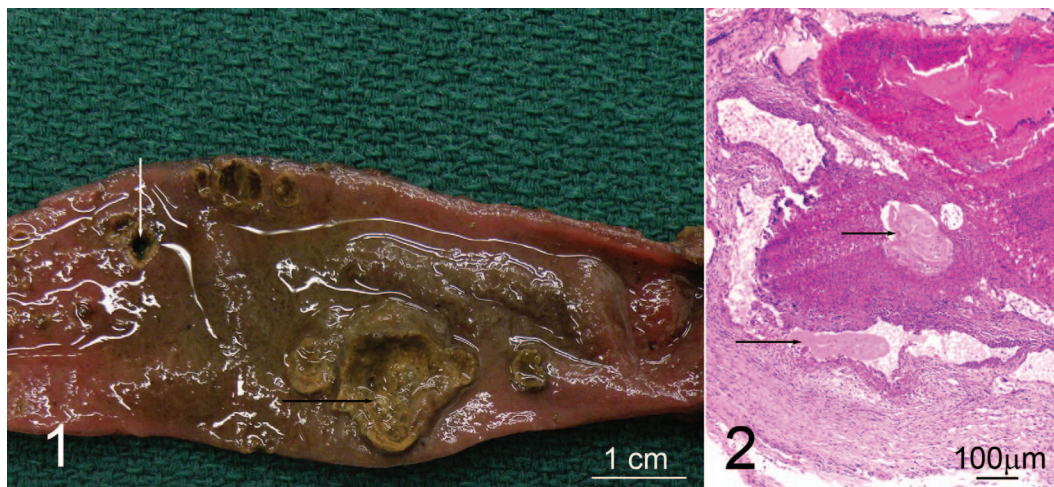
KEY WORDS: Canada, Digenea, disease, Echinostomatidae, Echinostomida, enteritis, *Grus canadensis*, pathology, *Protechinostoma mucronisertulatum*, sandhill crane, Saskatchewan.

Trematodes in the family Echinostomatidae infect terrestrial and aquatic vertebrates including wild and domestic mammals, birds, reptiles, and humans (Maldonado and Lanfreid, 2009) indicating a considerable capacity for host utilization by respective species within this assemblage (Agosta et al., 2010). Coincidental with ongoing and accelerating environmental perturbation and climate change, the introduction, geographic colonization, and spread of these parasites to new hosts and regions is anticipated (Brooks and Hoberg, 2007; Maldonado and Lanfreid, 2009; Hoberg and Brooks, 2015). Given a capacity for an extensive host range, their recognized impact

on wildlife health, and documented zoonotic potential, identification of these parasites in previously unrecognized wildlife hosts contributes to the development of an increasingly important and more nuanced picture of biodiversity (Brooks et al., 2014). In particular, migratory birds may be at increased risk of debilitating parasitological infections, including those involving echinostomatids. Aggregation of potential avian hosts on limited migration corridors and staging areas may lead to more intense infection pressure (Maldonado and Lanfreid, 2009; Hoberg et al., 2013). Here we document the first known occurrence of a poorly known echinostomatid, *Protechinostoma mucronisertulatum* Beaver, 1943, in a sandhill crane (*Grus canadensis*) from Saskatchewan, Canada.

On September 19, 2012, an immature male sandhill crane was found recumbent and unable to move its head near Waskesiu Lake, Prince Alberta National Park, Saskatchewan, Canada (53°94'N, 106°08'W). Following euthanasia, the crane was submitted to the Western-Northern Region of the Canadian Wildlife Health Cooperative for diagnostic investigation. A necropsy was performed, and representative tissue samples were collected and submerged in 10% buffered formalin, embedded in paraffin, sectioned at 5 µm, and routinely stained with hematoxylin and eosin. Segments of small and large intestine that were not sampled for histological examination were frozen and subsequently thawed for parasitological examination. Contents of the intestines and caeca were initially sieved using a no. 18 (1 mm) followed by a no. 100 (150 µm) screen to collect parasites. Helminth parasites recovered were initially preserved in 10% formalin, later transferred to 70% ethanol, and prepared for identification. Flatworms were stained in acetic carmine, dehydrated through an ethanol

⁴ Corresponding author. Current address: Department of Pathobiology, Ontario Veterinary College, University of Guelph, 50 Stone Road, Guelph, Ontario, Canada, N1G 2W1.



Figures 1–2. Jejunum from a sandhill crane (*Grus canadensis*) from Saskatchewan, Canada with fibrinonecrotizing and ulcerative jejunitis. **1.** The moderately dilated segment features multifocal to coalescing mucosal ulcers with overlying fibrinonecrotic membranes (black arrow) and a focal transmurular perforation (white arrow). **2.** Cross sections of degenerative *Protechinostoma mucronisertulatum* (arrows) within the necrotic mucosa and submucosa are surrounded by degenerative heterophils, macrophages, and cell debris.

series, cleared in xylene, and mounted in Canada balsam. Representative voucher specimens are deposited in the collections of the Parasitology Division of the Museum of Southwestern Biology, University of New Mexico, Albuquerque, New Mexico (MSB:Para:20895).

Examination at necropsy revealed the bird was emaciated with no visible fat stores and severe pectoral muscle atrophy. The carcass was severely dehydrated (tacky air sacs and subcutaneous tissues with urates visible in the ureters and cloaca). A segmental section of mid-jejenum was moderately dilated with multifocal to coalescing areas of ulceration covered by a fibrinonecrotic membrane (Fig. 1). A 1 mm focal, transmural puncture was present in the affected area and was associated with local fibrinous coelomitis. Histologically, the affected areas within the jejunum were characterized by aggregates of degenerative heterophils, macrophages, mineralization, bacterial colonies, and cellular debris that effaced the mucosa and extended into the submucosa and tunica muscularis. A perforation, present in one section, was bordered by macrophages, heterophils, and multinucleated giant cells. A thick layer of macrophages, lymphocytes, plasma cells, and bacterial colonies coated the serosa and extended to the pancreas in some sections. Cross sections of intact, degenerative, and mineralized trematodes were present in the jejunal lesion (Fig. 2), as well as in sections of the duodenum and ileum. Other

histological findings included pulmonary pneumoconiosis, skeletal muscle bradyzoites consistent with *Sarcocystis* sp., renal coccidiosis as indicated by oocysts, and developmental stages attributable to *Eimeria* sp. with associated lymphoplasmacytic interstitial nephritis and tubular urate crystals consistent with dehydration.

Specimens identified as *Protechinostoma mucronisertulatum* were present within the intestinal lesions, and subsequent parasite recovery focused specifically on these helminths. Based on examination of 10 specimens from the crane, these trematodes were morphologically similar to those originally described by Feldman (1941) and were consistent with a later partial redescription of this worm's structural attributes (Beaver, 1943). Morphometric characters in specimens from the crane were consistently smaller relative to the series of measurements presented in the original description, although the ratios for organ and sucker dimensions were consistent (Table 1); these are the first complete data from a naturally infected avian host. Flukes were typically linguiform, flat, and bluntly rounded (Fig. 3). The weakly-developed cephalic collar featured 2 rows of poorly differentiated collar spines (Fig. 4). Body spination was continuous from the anterior into the hindbody, with diminishing numbers and density of spines posteriad. The oral sucker was consistently smaller than the ventral sucker, the latter being situated near the level of the midbody, with the

Table 1. Size comparisons of various morphological characteristics of trematodes reported in the current study and those reported by Feldman (1941).

Feature	Sandhill crane specimens		Feldman (1941) specimens	
	Mean (μm)	Range (μm)	Mean (μm)	Range (μm)
Length	1,306.2	1,065–1,574	1,470	1,460–1,830
Width	239.5	175–292	460	420–620
Oral sucker	64.2	55–73	70	60–90
Ventral sucker	117.8	98–130	130	110–160
Pharynx length	49.1	35–54	60	50–60
Pharynx width	35.4	31–47	55	50–60
Anterior testis width	111.9	54–168	130	120–170
Anterior testis length	109.7	85–143	180	110–200
Posterior testis width	110.5	91–146	130	120–170
Posterior testis length	143	98–175	190	140–210
Esophagus*	165.5	n/a	220	200–230
Ovary	60.1	46–69	100	90–110
Egg length†	83.5	n/a	80	70–90
Egg width	53	n/a	56	50–60

* Only 2 esophagi were measured.

† Only 2 eggs were measured.

genital pore placed near the anterior margin and slightly posterior to the cecal bifurcation. Testes were tandem and spherical to cuboidal. The ovary was anterior to the testes and round or oval. The vitellaria were large and closely distributed, extending to the level of the ventral sucker and converging behind the posterior testis to form a single mass occupying most of the post-testicular region of the body. Eggs were not seen in all specimens.

The genus *Protechinostoma* Beaver, 1943, is monotypic. *Protechinostoma mucronisertulatum* appears to be endemic and is known only from the sora rail (*Porzana carolina*) on the central North American flyway (Redington and Ulmer, 1966; McDonald, 1981). This report is the first to document an infection by *P. mucronisertulatum* in a sandhill crane. Flukes attributable to this genus and species were first discovered in the ileum of a sora rail near Black Creek, Wisconsin (Beaver, 1943). Subsequently, infections were found in sora rails on breeding habitats from northeastern Iowa (Redington and Ulmer, 1966). There appears to be a sole record of immature flukes in a blue-winged teal (*Anas discors*) from this region (Redington and Ulmer, 1966).

The life cycle of *P. mucronisertulatum* involves development in several species of fresh-water pulmonate snails, with metacercarial stages present in the gastropod second intermediate hosts (Beaver, 1943; Redington and Ulmer, 1966). Thus, circulation and transmission is associated with aquatic/semi-terrestrial habitats apparently coincidental with the

breeding range for the central North American population of sora rails. These birds have extensive migratory patterns into Central and South America, yet there is no evidence for the occurrence of this trematode in these locations. Annual distribution of infected snails and birds appears to be heterogeneous with the overall occurrence of these echinostomatids depending upon seasonal patterns of habitat use by avian hosts (Redington and Ulmer, 1966). Additionally, this apparently localized geographic range suggests that the occurrence of *P. mucronisertulatum* among sora rails does not reflect a marine cycle and retention of parasites on a northern migration trajectory. The potential for infections in sandhill cranes would occur in areas of temporal or spatial sympatry with rails or infected snails.

Reports of *P. mucronisertulatum* are notably absent in several surveys of endoparasites in sandhill cranes and closely-related whooping and European cranes (Iverson et al., 1983; Cole et al., 2009; Fanke et al., 2011). The macro- and microparasite faunas of sandhill cranes are of particular interest to researchers due to their overlapping range and biological similarities with whooping cranes, a highly endangered species that has undergone intensive conservation management, including captive rearing and reintroduction programs (Spalding, 1996). The conspicuous absence of *P. mucronisertulatum* in previous studies of wild cranes suggests that the individual in this report may have been an incidental host. However, recovery of *P. mucronisertulatum*

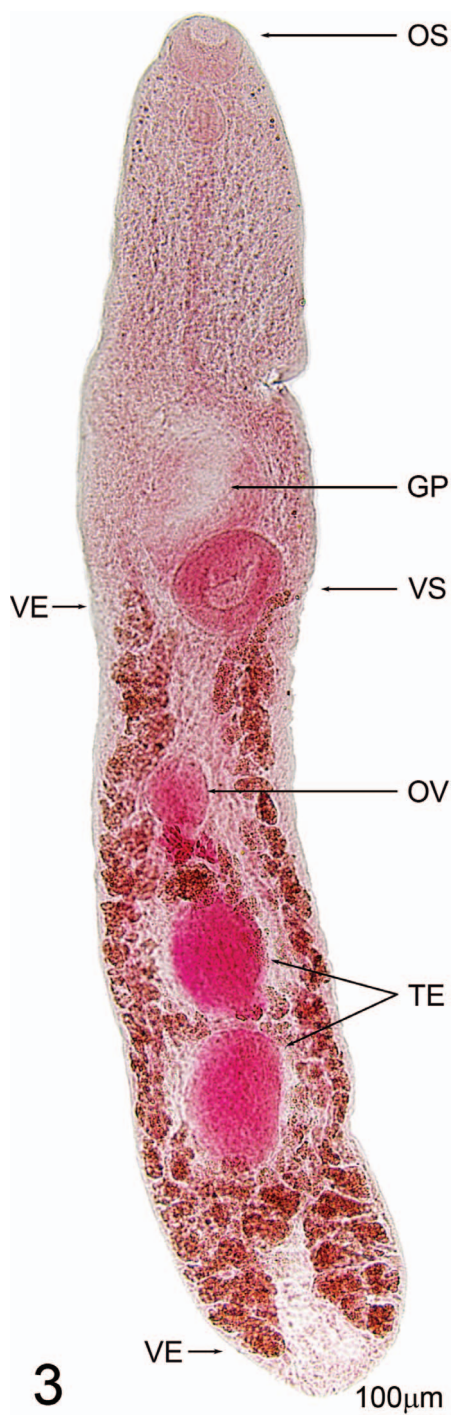


Figure 3. *Protechinostoma mucronisertulatum* collected from the intestines of a sandhill crane (*Grus canadensis*) from Saskatchewan, Canada. Stained whole mount of *P. mucronisertulatum* showing the oral sucker (OS), ventral

from a sandhill crane suggests host switching is possible in suitable habitats, conditions of sympatry, and overlap in foraging, which may be associated with ecological disruption.

The sandhill crane is host to a number of other trematode species, including other echinostomatids (Table 2). Among these, *Orchipedium jolliei* is the most frequently reported and resides in the trachea, lungs, and air sacs of infected birds (Forrester et al. 1974, 1975; Iverson et al., 1983; Gaines et al., 1984). In the whooping crane, *Echinostoma trivolvis* was recovered from the small intestine of 2 reintroduced individuals without associated lesions (Cole et al., 2009). These reports are consistent with genera and species characterized by a distinctly developed cephalic collar and armature and would not be confused with specimens of *Protechinostoma* (McDonald, 1981). Direct comparisons of specimens needed to accurately document the dimensions of diversity in natural systems, however, are possible only when representative voucher specimens are permanently archived in museum repositories (Hoberg et al., 2009).

Specimens of *P. mucronisertulatum* in the crane were morphologically consistent with the original description but were smaller. It is possible this size difference is associated with the host from which they were recovered or it may reflect age of the specimens. Specimens in the original description were obtained from experimental infections in young domestic chickens (Feldman, 1941), while those from the crane were the result of a natural infection, and thus the nature of size discrepancies cannot be resolved. Development of *P. mucronisertulatum* in the crane resulted in at least some proportion of gravid flukes being recovered, suggesting that typical ontogeny might be expected in this avian host.

This crane suffered from dehydration, emaciation, and intestinal perforation with an associated local coelomitis, yet it is unclear if the debilitation and lesions were caused by *P. mucronisertulatum* infection. A previous report of *P. mucronisertulatum* in sora rails includes “extensive tissue damage” associated with infection (Redington and Ulmer, 1966); however, contemporary assessment of this description is hampered by poor image quality and

←
sucker (VS), genital pore (GP), ovary (OV), testes (TE), and the extent of the vitelline follicles (between arrows labeled VE).

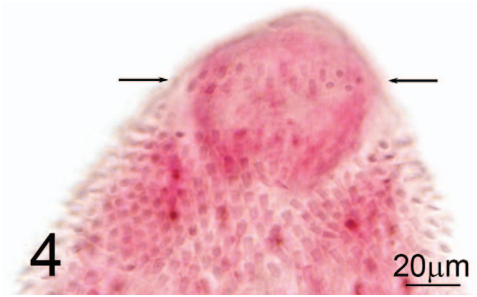


Figure 4. *Protechinostoma mucronisertulatum* collected from the intestines of a sandhill crane (*Grus canadensis*) from Saskatchewan, Canada. Anterior portion featuring a weakly-developed cephalic collar with 2 rows of collar spines (arrows).

apparent autolysis. While there is attachment of *P. mucronisertulatum* deep within the mucosa, substantial tissue response (e.g., necrosis and inflammation) suggestive of a host response cannot be identified in the report. The lesions in this sandhill crane are considerably more severe compared to this previous report, with sections of *P. mucronisertulatum* occurring within the submucosa and associated with a substantial host inflammatory response.

Severe infections of echinostomatids in definitive hosts are typically associated with weight loss, mild enteritis, and weakness (Toledo et al., 2006). Most often, evidence of macroscopic lesions in association with echinostomatid infection is absent (Cole et al., 2009; Fanke et al., 2011). Furthermore, intestinal disease, including perforation, is an apparently rare cause of mortality in sandhill cranes. For instance, Windingstad (1988) found no evidence of intestinal disease among 170 cases of natural mortality in sandhill cranes from Wisconsin. Alternatively, severe infection with an anisakid nematode, *Porrocaecum ardeae*, was associated with fatal intestinal perforation in 3 Eurasian cranes (*Grus grus*) (Fanke et al., 2011). Further research is needed to understand the prevalence of *P. mucronisertulatum* in sandhill cranes as well as to clarify its association with intestinal lesions.

The Canadian Wildlife Health Cooperative Western-Northern Region supported this work. J.R. received funding from the Western College of Veterinary Medicine Interprovincial Graduate Student Fellowship. Andy Allen assisted in gross lesion photography.

Table 2. Trematode species previously identified in the sandhill crane (*Grus canadensis*).

Trematode species	Study location	Location in host	Prevalence <i>n/N</i> (%)	Infection intensity range (mean)	Reference
<i>Brachylaima fuscattum</i>	Florida	Small intestine	5/34 (15)	1–5 (3)	(Forrester et al., 1974)
	Florida	Small intestine	3/15 (20)	1–27 (13)	(Forrester et al., 1975)
<i>Echinostoma revolutum</i>	Alaska	Small intestine	2/146 (1)	1–24 (12.5)	(Gaines et al., 1984)
Echinostomidae	Florida	Ceca	1/34 (3)	1 (1)	(Forrester et al., 1974)
	Florida	Large intestine and ceca	1/15 (7)	4 (4)	(Forrester et al., 1975)
<i>Orchipedium jolizei</i>	Alaska, Saskatchewan, Texas	Trachea and air sacs	82/146 (56)	1–50 (8.1)	(Gaines et al., 1984)
	Oklahoma, Texas, Nebraska, Saskatchewan, Alaska	Trachea	129/320 (40)	1–21 (6)	(Iverson et al., 1983)
	Florida	Trachea and lung	19/34 (56)	1–28 (7.0)	(Forrester et al., 1974)
	Florida	Lungs	1/15 (7)	1 (1)	(Forrester et al., 1975)
<i>Prohaptanmus gruis</i>	Alaska, Texas	Body cavity	13/146 (9)	1–7 (2.3)	(Gaines et al., 1984)
	Oklahoma, Texas, Nebraska, Saskatchewan, Alaska	Body cavity	32/319 (10)	1–21 (5.6)	(Iverson et al., 1983)
<i>Prosthogonimus macrorchis</i>	Florida	Cloaca	1/34 (3)	1 (1)	(Forrester et al., 1974)
<i>Stomylotrema vicarium</i>	Florida	Small intestine, ceca, and cloaca	3/15 (20)	6–43 (28)	(Forrester et al., 1975)
<i>Strigea gruis</i>	Alaska	Small intestine	3/14 (23)	5–80 (31)	(Dubois and Rausch, 1964)
	Florida	Small intestine	2/34 (6)	11–19 (15)	(Forrester et al., 1974)
	Florida	Small intestine	3/15 (20)	51–258 (141)	(Forrester et al., 1975)
<i>Tamaisia fedtschenkoi</i>	Florida	Kidney	1/15 (7)	9 (9)	(Forrester et al., 1975)

LITERATURE CITED

- Agosta, S. J., N. Janz, and D. R. Brooks.** 2010. How specialists can be generalists: resolving the “parasite paradox” and implications for emerging infectious disease. *Zoologia* 27:151–162.
- Beaver, P. C.** 1943. Studies on *Protechinostoma mucronisertulatum*, N.G., N.N. (*Psilostomum reflexae* Feldman, 1941), a trematode (Echinostomidae) from the sora rail. *Journal of Parasitology* 29:65–70.
- Brooks, D. R., and E. P. Hoberg.** 2007. How will global climate change affect parasite-host assemblages? *Trends in Parasitology* 23:571–574.
- Brooks, D. R., E. P. Hoberg, W. A. Boeger, S. L. Gardner, K. E. Galbreath, D. Herczeg, H. H. Mejía-Madrid, A. E. Rácz, and A. Tsogtsaikhan.** 2014. Finding them before they find us: informatics, parasites, and environments in accelerating climate change. *Comparative Parasitology* 81:155–164.
- Cole, G. A. N. J. Thomas, M. Spalding, R. Stroud, R. P. Urbanek, and B. K. Hartup.** 2009. Postmortem evaluation of reintroduced migratory whooping cranes in eastern North America. *Journal of Wildlife Diseases* 45:29–40.
- Dubois, G., and R. L. Rausch.** 1964. Studies on the helminth fauna of Alaska. XL. *Strigea gruis* sp. n., a trematode parasite of *Grus canadensis* (L.). *Journal of Parasitology* 50:445–447.
- Fanke, J., G. Wibbelt, and O. Krone.** 2011. Mortality factors and diseases in free-ranging Eurasian cranes (*Grus grus*) in Germany. *Journal of Wildlife Diseases* 47:627–637.
- Feldman, S. I.** 1941. Studies on the morphology and biology of a psilostome fluke. *Journal of Parasitology* 27:525–533.
- Forrester, D. J., A. O. Bush, E. S. Williams, and D. J. Weiner.** 1974. Parasites of greater sandhill cranes (*Grus canadensis tabida*) on their wintering grounds in Florida. *Journal of the Helminthological Society of Washington* 41:55–59.
- Forrester, D. J., A. O. Bush, and L. E. Williams.** 1975. Parasites of Florida sandhill cranes, *Grus canadensis psratensis*. *Journal of Parasitology* 61:547–548.
- Gaines, G. D., R. J. Warren, and D. B. Pence.** 1984. Helminth fauna of sandhill crane populations in Texas. *Journal of Wildlife Diseases* 20:207–211.
- Hoberg, E. P., and D. R. Brooks.** 2015. Evolution in action: climate change, biodiversity dynamics and emerging infectious disease. *Philosophical Transactions of the Royal Society B: Biological Sciences* 370: 20130553.
- Hoberg, E. P., S. J. Kutz, J. A. Cook, K. Gataktinov, V. Haukisalmi, H. Henttonen, S. Laaksonen, A. Markarikov, and D. J. Marcogliese.** 2013. Parasites in terrestrial, freshwater and marine systems. Pages 476–505 in H. Meltote, ed. *Arctic Biodiversity Assessment—Status and Trends in Arctic Biodiversity. Conservation of Arctic Floral and Fauna*, Arctic Council, Akureyi, Iceland.
- Hoberg, E. P., P. A. Pilitt, and K. E. Galbreath.** 2009. Why museums matter: a tale of pinworms (*Oxyuroidea: Heteroxyematidae*) among pikas (*Ochotona princeps* and *O. collaris*) in the American West. *Journal of Parasitology* 95:490–501.
- Iverson, G. C., P. A. Vohs, A. A. Kocan, and K. A. Waldrup.** 1983. Some helminth parasites of sandhill cranes from mid-continental North America. *Journal of Wildlife Diseases* 19:56–59.
- Maldonado, A., Jr., and R. M. Lanfreid.** 2009. Echinostomids in the wild. Pages 129–145 in B. Fried, R. C. Peoples, and R. Toledo, eds. *The Biology of Echinostomes: From the Molecule to the Community*. Springer, New York.
- McDonald, M. E.** 1981. Key to trematodes reported in waterfowl. U.S. Fish and Wildlife Service, Washington, D.C. 156 pp.
- Redington, B. C., and M. J. Ulmer.** 1966. Helminth parasites of rails and host-parasite relationships of the trematode *Protechinostoma mucronisertulatum*. *Iowa Academy of Science* 73:391–405.
- Spalding, M. G.** 1996. Helminth and arthropod parasites of experimentally introduced whooping cranes in Florida. *Journal of Wildlife Diseases* 32:44–50.
- Toledo, R., J. G. Esteban, and B. Fried.** 2006. Immunology and pathology of intestinal trematodes in their definitive hosts. *Advances in Parasitology* 63: 285–365.
- Windingstad, R. M.** 1988. Nonhunting mortality in sandhill cranes. *Journal of Wildlife Management* 52:260–263.