

# Cranial Computed Tomography in the Evaluation of Neurologic Disorders in Two Nonhuman Primates

Donald L. Janssen, DVM; M. Kathryn Hammock, MD; David O. Davis, MD; Mitchell Bush, DVM

## SUMMARY

Cranial computed tomography (CCT) was used to evaluate neurologic disorders in 2 primates. In the 1st case, acute left hemiparesis developed in an adult female proboscis monkey (*Nasalis larvatus*). A CCT scan revealed a right frontal lobe abscess that was subsequently surgically drained. In the 2nd case, a juvenile black spider monkey (*Ateles fusciceps*) experienced recurrent seizures following an episode of trauma and anoxia. A CCT scan demonstrated enlarged lateral ventricles and cerebral atrophy. Computed tomography proved to be a valuable technique for localizing and characterizing brain lesions in these 2 primates, after more conventional methods of investigation had failed to establish diagnoses.

CRANIAL computed tomography (CCT) is a radiographic imaging system that gives cross-sectional displays of internal structure. The image is made by moving an x-ray source and detector around the head so that a series of radiographic "slices" are made in a predetermined plane. The computer analyzes the large number of measurements of x-ray absorption through each anatomic slice, and an image is then constructed on a video monitor. The process distinguishes between tissue densities, allowing visualization of lesions within the cerebral parenchyma.

With these unique characteristics, CCT has profoundly altered the manner in which intracranial disease in human beings is studied. In veterinary medicine, computed tomography has been used to describe normal anatomy of the dog<sup>1</sup> and primates,<sup>2,3</sup> brain tumors in dogs,<sup>4</sup> and a case of spina bifida in a celebes macaque.<sup>5</sup>

The purpose of this report is to demonstrate the value of CCT scanning in evaluating the nature and location of brain lesions in 2 nonhuman primates.

From the Department of Animal Health, National Zoological Park, Smithsonian Institution, Washington, DC 20008 (Janssen, Bush); Children's Hospital, National Medical Center, Washington, DC 20010 (Hammock); and the Department of Radiology, George Washington University Medical Center, Washington, DC 20037 (Davis).

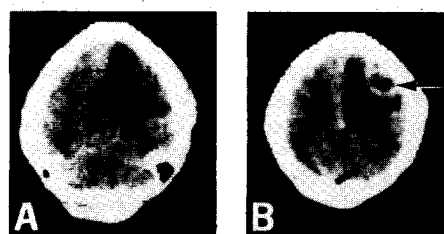

Fig 1—Horizontal CCT scan of an adult proboscis monkey with left hemiparesis caused by an abscess in the right frontal lobe. An area of decreased density, representing edema (arrow), is in the right frontal region, producing a right-to-left shift of cerebral tissue (A). Following injection of contrast material, a ring of enhancement defines the necrotic core (arrow) of the abscess (B). These are typical findings in cases of encapsulated brain abscess.

## Materials and Methods

Prior to the CCT procedure, each primate was given a physical examination; complete blood counts and serum biochemical profiles were determined; and each animal was tuberculin tested and found to be negative. Skull radiographs were taken. Each animal was anesthetized for the scan with ketamine HCl (10 mg/kg) IM; ketamine or diazepam was given IV as needed to maintain sedation and minimize motion. The primates were positioned in dorsal recumbency. The scans were performed with head scanners.<sup>6</sup> Serial 8-cm radiographic sections of the head were made with an exposure time of 90 sec. The scans were made along a horizontal plane approximately parallel to the orbitomeatal line. To improve visualization of cerebral mass lesions, contrast scans were accomplished by administration of diatrizoate meglumine<sup>b</sup> (3 ml/kg) IV via venous catheter immediately prior to the 2nd scan.<sup>6</sup> A clinically normal juvenile spider monkey was evaluated in a similar way to serve as a control.

**Case 1**—A wild-caught aged female proboscis monkey (*Nasalis larvatus*) was favoring the left leg. She was active and alert, and a tentative diagnosis of a traumatic episode was made. However, the next morning paresis of the left leg developed and the left arm had become flaccid. A brain lesion was suspected and a CCT scan was performed (Fig 1). An exploratory craniotomy was performed to drain the cerebral abscess. The patient recovered from anesthesia and received intensive supportive care for 2 days, but then died. The abscess was sterile on culture, but that may have been attributable to the preoperative administration of antibiotics. In addition to the brain abscess, extensive pulmonary damage from lung mites (*Pneumonyssus* sp) was found at necropsy.

**Case 2**—A 2-year-old male hand-raised black spider monkey (*Ateles fusciceps*) had seizures on 5 occasions

<sup>a</sup>Ohio Nuclear Delta-25 (case 1) and EMI CT 1005 (case 2).

<sup>b</sup>Hypaque Meglumine 30%, Winthrop Laboratories, New York, NY.

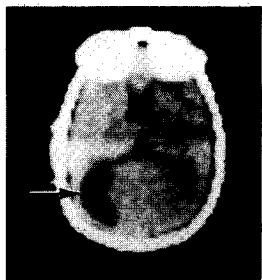


Fig 2—Horizontal CCT section through brain of a young spider monkey with history of trauma and anoxia. The occipital horns of the lateral ventricles are dilated, the left greater than the right (large arrow). The 3rd ventricle is not appreciably enlarged (small arrow).

during the previous 15 months. The animal had been severely attacked by a cagemate at 8 days of age, receiving a compound femoral fracture resulting in marked blood loss and anemia. With appropriate care, he eventually recovered from the incident. To investigate the origin of the seizures, a CCT scan was performed, demonstrating ventricular enlargement (Fig 2). No seizures have been observed in the past 10 months, and no anticonvulsant medication has been given.

### Discussion

In both cases, CCT provided the key in describing the character and location of the neurologic lesions. In the proboscis monkey, the left hemiparesis indicated a lesion in the right cerebral hemisphere. Cranial computed tomography findings of an encapsulated lesion with central lucency and decreased density of surrounding tissue (edema) suggested a brain abscess or a highly malignant tumor with central necrosis. Brain abscesses often result from extension of infections from elsewhere in the body, especially from the head, heart, or lungs. The lung damage associated with lung mite infection in this case may have served as the source of infection in the brain.

The black spider monkey, in contrast, showed no localizing signs. Computed tomography findings of ventricular enlargement suggested either hydrocephalus or cerebral atrophy. Because the temporal horn dilatation was not as great as that of the bodies, it was believed that this was not obstructive hydro-

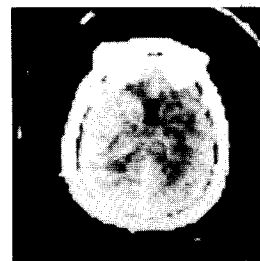


Fig 3—Horizontal CCT section through brain of a control spider monkey, showing normal-sized lateral ventricles and surrounding brain. The linear density at the bottom of the scan is the falx cerebri.

cephalus, but rather, cerebral atrophy or loss of brain substance around the ventricles. Normal-sized ventricles of a spider monkey are shown for comparison (Fig 3). In children with posttraumatic epilepsy, CCT occasionally demonstrates focal ventricular dilatation from cerebral atrophy.<sup>7</sup>

Neurologic examination of primates is often imprecise because of problems in restraint. These cases demonstrate the value of computed tomography when more conventional techniques have failed to establish the diagnosis. This noninvasive procedure, capable of detecting a wide variety of disorders, has the potential for prompt resolution of many diagnostic problems in nondomestic animals.

### References

1. Fike JR, Drury EM, Zook BC, et al: Canine anatomy as assessed by computerized tomography. *Am J Vet Res* 41:1823-1832, 1980.
2. Drayer BP, Dujovny M, Wolfson SK, et al: Cranial computed tomography in the baboon: Normal anatomy. *Radiology* 125:403-406, 1977.
3. Drayer BP, Wolfson SK, Rosenbaum AE, et al: Comparative cranial CT enhancement in the normal primate. *Invest Radiol* 14: 88-96, 1979.
4. Fike JR, LeCouteur RA, Cann CE, et al: Computerized tomography of brain tumors of the rostral and middle fossas in the dog. *Am J Vet Res* 42:275-281, 1981.
5. Meier JE, Boyce WL: Spina bifida occulta in a Celebes crested macaque. *J Am Vet Med Assoc* 173:1236-1238, 1978.
6. Butler AR, Kricheff II: Non-contrast CT scanning: Limited value in suspected brain tumor. *Radiology* 126:689-693, 1978.
7. Hammock MK, Milhorat TH: *Cranial Computed Tomography in Infancy and Childhood*. Baltimore, Williams and Wilkins Co, 1981, p 37.