

SMITHSONIAN MISCELLANEOUS COLLECTIONS

PART OF VOLUME LI

THE DEVELOPMENT OF THE  
AMERICAN ALLIGATOR

(*A. mississippiensis*)

WITH TWENTY-THREE PLATES

BY

ALBERT M. REESE

Professor of Zoology, West Virginia University



No. 1791

CITY OF WASHINGTON  
PUBLISHED BY THE SMITHSONIAN INSTITUTION  
1908

WASHINGTON, D. C.  
PRESS OF JUDD & DETWEILER, INC.  
1908

THE DEVELOPMENT OF THE AMERICAN ALLIGATOR  
(*A. MISSISSIPPIENSIS*)

By ALBERT M. REESE

(With 23 plates)

---

INTRODUCTION

With the exception of S. F. Clarke's well-known paper, to which frequent reference will be made, practically no work has been done upon the development of the American alligator. This is probably due to the great difficulties experienced in obtaining the necessary embryological material. Clarke, some twenty years ago, made three trips to the swamps of Florida in quest of the desired material. The writer has also spent parts of three summers in the southern swamps—once in the Everglades, once among the smaller swamps and lakes of central Florida, and once in the Okefenokee Swamp. For the first of these expeditions he is indebted to the Elizabeth Thompson Science Fund; but for the more successful trip, when most of the material for this work was collected, he is indebted to the Smithsonian Institution, from which a liberal grant of money to defray the expenses of the expedition was received.

The writer also desires to express his appreciation of the numerous courtesies that he has received from Dr. Samuel F. Clarke, especially for the loan of several excellent series of sections, from which a number of the earlier stages were drawn.

The present paper gives a general outline of the whole process of development of the American alligator (*A. mississippiensis*), it being the intention of the author to take up in detail the more specific points in subsequent researches.

In preparing the material several kinds of fixation were employed, but the ordinary corrosive sublimate-acetic mixture gave about the most satisfactory results. Ten per cent formalin, Parker's mixture of formalin and alcohol, etc., were also used. In all cases the embryos were stained *in toto* with borax carmine, and in most cases the sections were also stained on the slide with Lyon's blue. This double stain gave excellent results. Transverse, sagittal, and horizontal series of sections were made, the youngest embryos being cut into sections five microns thick, the older stages ten microns or more in thickness.

## THE EGG

FIGURES 1, 1a (PLATE I)

The egg (fig. 1) is a perfect ellipse, the relative lengths of whose axes vary considerably in the eggs of different nests and slightly in the eggs of the same nest. Of more than four hundred eggs measured, the longest was 85 mm.; the shortest 65 mm. Of the same eggs, the greatest short diameter was 50 mm.; the least short diameter was 38 mm. The average long diameter of these four hundred eggs was 73.74 mm.; the average short diameter was 42.59 mm. The average variation in the long axis of the eggs of any one nest was 11.32 mm., more than twice the average variation in the short axis, which was 5.14 mm. No relation was noticed between the size and the number of eggs in any one nest. Ten eggs of average size weighed 812 grams—about 81 grams each.

Voeltzkow (18)<sup>1</sup> states that the form of the egg of the Madagascar crocodile is very variable. No two eggs in the same nest are exactly alike, some being elliptical, some "egg-shaped," and some "cylindrical with rounded ends." The average size is 68 mm. by 47 mm., shorter and thicker than the average alligator egg.

When first laid, the eggs are pure white, and are quite slimy for a few hours, but they generally become stained after a time by the damp and decaying vegetation composing the nest in which they are closely packed.

The shell is thicker and of a coarser texture than that of the hen's egg. Being of a calcareous nature, it is easily dissolved in dilute acids.

The shell membrane is in two not very distinct layers, the fibers of which, according to S. F. Clarke, are spirally wound around the egg at right angles to each other. No air-chamber, such as is found in the hen's egg, is found in any stage in the development.

In most—probably all normal—eggs a white band appears around the lesser circumference a short time after being laid. This chalky band, which is shown at about its maximum development in fig. 1a, is found, on removal of the shell, to be caused, not by a change in the shell, but by the appearance of an area of chalky substance in the shell membranes. Clarke thinks this change in the membrane is to aid in the passage of gases to and from the developing embryo. Generally this chalky area forms a distinct band entirely around the shorter circumference of the egg, but sometimes extends only partly

---

<sup>1</sup> The numerical citations throughout the article are to bibliographical references at the end of the paper.

around it. It varies in width from about 15 mm. to 35 mm., being narrowest at its first appearance. Sometimes its borders are quite sharp and even (fig. 1*a*); in other cases they are very irregular. If the embryo dies the chalky band is likely to become spotted with dark areas.

The shell and shell membrane of the egg of the Madagascar crocodile are essentially the same as those just described, except that the shell is sometimes pierced by small pores that pass entirely through it. The same chalky band surrounds the median zone of the egg (18).

The white of the egg is chiefly remarkable for its unusual density, being so stiff that the entire egg may be emptied from the shell into the hand and passed from one hand to the other without danger of rupturing either the mass of albumen or the enclosed yolk. The albumen, especially in the immediate neighborhood of the yolk, seems to consist of a number of very thin concentric layers. It varies in color, in different eggs, from a pale yellowish white, its usual color, to a very decided green.

As might be expected, no chalazæ are present.

The yolk is a spherical mass, of a pale yellow color, lying in the center of the white. Its diameter is so great that it lies very close to the shell around the lesser circumference of the egg, so that it is there covered by only a thin layer of white, and care must be taken in removing the shell from this region in order not to rupture the yolk. The yolk substance is quite fluid and is contained in a rather delicate vitelline membrane.

The albumen and yolk of the crocodile's egg, as described by Voeltzkow, differ from those of the alligator only in the color of the albumen, which in the crocodile is *normally* light green (18).

As pointed out by Clarke, the position of the embryo upon the yolk is subject to some variation. During the earliest stages it may occur at the pole of the yolk nearest the side of the egg; later it may generally be found toward the end of the egg; and still later it shifts its position to the side of the egg. It is probable, as Clarke says, that the position at the end of the egg secures better protection by the greater amount of white, at that point, between the yolk and the shell; while the later removal to the side of the egg, when the vascular area and the allantois begin to function, secures a better aëration of the blood of the embryo.

Around the embryo, during the stages that precede the formation of the vascular area, is seen an irregular area of a lighter color and a mottled appearance. This area is bounded by a distinct, narrow,

white line, and varies in size from perhaps a square centimeter to one-third the surface of the yolk.

During the earliest stages of development the embryo is very transparent; so that, as there is no fixed place upon the yolk at which it may be expected to occur, it is often very difficult to find. Owing to this transparency, to the extreme delicacy of the embryo, and to the character of the white, the removal of an early embryo from the egg of the alligator is a difficult operation and is accomplished only after some practice.

#### THE DEVELOPMENT OF THE EMBRYO

As the writer has pointed out elsewhere (13), the embryo of the alligator is often of considerable size when the egg is laid. This makes the obtaining of the earliest stages of development a difficult matter; so that the writer, as has already been said, like S. F. Clarke (5), made three trips to the South in quest of the desired material. Voeltzkow (18) experienced the same difficulty in his work on the crocodile, and made several trips to Africa before he succeeded in obtaining all the desired stages of development.

To obtain the earliest stages, I watched the newly made nests until the eggs were laid, and in this way a number of eggs were obtained within a very few hours after they had been deposited, and all of these eggs contained embryos of a more or less advanced stage of development. Gravid females were then killed, and the eggs removed from the oviducts. These eggs, although removed from a "cold-blooded" animal, generally contained embryos of some size, and only one lot of eggs thus obtained contained undeveloped embryos, which embryos refused to develop further in spite of the most careful treatment. Voeltzkow (18) found, in the same way, that the earlier stages of the crocodile were extremely difficult to handle; so that, in order to obtain the earlier stages, he was reduced to the rather cruel expedient of tying a gravid female and periodically removing the eggs from the oviducts through a slit cut in the body wall.

The older embryos are hardy and bear transportation well, so that it is comparatively easy to obtain the later stages of development.

For the stages up to the formation of the first four or five somites, I am indebted, as I have already said, to Professor Clarke, and, since I have had opportunity to examine only the sections and not the surface views of these stages, I shall quote directly Clarke's paper in the *Journal of Morphology* (5) in description of these surface views.

## STAGE I

## FIGURES 2-2f (PLATES I, II)

The youngest embryo that we have for description is shown in figures 2 and 2a. Of figure 2 Clarke says:

"The limiting line between the opaque and pellucid areas is clearly marked, and within the latter is a shield-shaped area connected by the narrower region of the primitive streak with the area opaca. The blastopore is already formed near the posterior end of the shield.

"A ventral view of another embryo of the same age (fig. 2a), seen from the ventral side, shows that the blastopore extends quite through the blastoderm, in an oblique direction downwards and forwards, from the dorsal to the ventral side. The thickened area of the primitive streak is here very prominent. There is, too, the beginning of a curved depression at the anterior end of the shield, the first formation of the head-fold."

Transverse sections of this stage are shown in figures 2b-2f.

Figure 2b, through the anterior region of the blastoderm, shows a sharply defined ectoderm (*ec*) which is composed of three or four layers of cells in the median region, while it gradually thins out laterally. Closely underlying this ectoderm is a thin sheet of irregular cells, the entoderm (*en*).

Figure 2c is about one-fifth of the length of the blastoderm posterior to the preceding and represents approximately the same conditions, except that there is an irregular thickening of the entoderm in the median region (*en*). This thickening apparently marks the anterior limit of the mesoderm, to be discussed shortly.

Figure 2d represents the condition of the blastoderm throughout about one-third of its length, posterior to the preceding section. The somewhat regular folds in the ectoderm (*ec*) are probably not the medullary folds, but are such artificial folds as might easily be produced in handling the delicate blastoderm. The thickening of the entoderm, noticed in the preceding figure, is here more sharply defined, and as we pass toward the blastopore becomes separated somewhat from the entoderm proper as a middle layer or mesoderm (fig. 2e, *mes*). It would thus seem, from a study of these sections, that most of the mesoderm is derived from the entoderm. In fact, all of the mesoderm in front of the blastopore seems to have this origin, for it is not until the anterior edge of the blastopore is reached that there is any connection between the ectoderm and entoderm (fig. 2e).

Figure 2e is a section through the region just mentioned, where, medially, the ectoderm, mesoderm, and entoderm form a continuous

mass of cells. Laterally the mesoderm (*mes*) is a distinct layer of cells of a fairly characteristic mesodermal type. The notochord is not yet discernible, though a slight condensation of cells in the middle line may indicate its position.

Figure 2*f* is one of the four sections that were cut through the blastopore (*blp*), which is a hole of considerable size that opens, as the figure shows, entirely through the blastoderm. Along the walls of the blastopore the ectoderm and entoderm are, of course, continuous with each other and form a sharply defined boundary to the opening. As we pass laterally from the blastopore the cells become less compact, and are continued on each side as the mesodermal layer (*mes*). In this series the sections posterior to the blastopore were somewhat torn, and so were not drawn; but they probably did not differ materially from those of the corresponding region of the immediately following stages, which are shown in figures 3*m* and 6*i* and will be described in their proper order.

## STAGE II

### FIGURES 3-30 (PLATES II, III, IV)

The next stage to be described is shown in surface views in figures 3 and 3*a*. Of this stage Clarke says:

"The head-fold rapidly increases in depth and prominence, as shown in figure 3, which is a ventral view a few hours later [than the preceding stage]. The time cannot be given exactly, as it is found that eggs of the same nest are not equally advanced when laid, and differ in their rate of development. The lighter curve in front of the head-fold is the beginning of the anterior fold of the amnion. The notochord has been rapidly forming, and now shows very distinctly on the ventral side, when viewed by transmitted light. A dorsal view of the same embryo (fig. 3*a*) shows that the medullary or neural groove is appearing, and that it ends abruptly anteriorly near the large transverse head-fold. Posteriorly it terminates at the thickened area in front of the blastopore, which still remains open."

Figures 3*b-m* are drawn from transsections of an embryo of about this state of development. For a short distance in front of the beginning of the head-fold, there is a mass of cells of considerable thickness between the ectoderm and entoderm. In figure 3*b* these cells appear as an irregular thickening of the entoderm, while in figure 3*c* they form a continuous mass, uniting the upper and lower germ layers. This condition is seen, though in a much less striking degree, in the following stage of development. As to its significance the writer is not prepared to decide.



Figure 3*d* passes through the head-fold, which in this embryo was probably not so far developed as it was in the embryo shown in figures 3 and 3*a*. Not having seen the embryo, however, before it was sectioned, the writer cannot be certain of this point. The ectoderm and entoderm are here of nearly the same thickness.

Figure 3*e* is a short distance posterior to the preceding. It shows a marked thickening of the ectoderm in the medial region (*cc*), which is continuous posteriorly with the anterior ends of the medullary folds that are just beginning to differentiate (figs. 3*f*–*h*).

Figure 3*g* passes through the anterior end of the medullary plate or folds (*mf*), whichever they may be called. The ectoderm of the folds is thickened and is considerably elevated above the rest of the blastoderm. There is scarcely any sign, in this region, of a medullary groove. The entoderm (*en*) is considerably thickened in the medial region, this thickening being continuous posteriorly, as in the preceding stage, with the mesoderm.

In figure 3*h*, cut in a plane at some distance posterior to the preceding, the medullary groove (*mg*) is well marked; its bordering folds gradually thin out laterally to the thickness of the ordinary ectoderm. The medial thickening of the entoderm is very marked, but it has not in this region separated into a distinct mesoblastic layer.

Immediately under the medullary groove is a dense mass of cells (*nt*), apparently the anterior end of the notochord in process of formation.

Figure 3*i*, still farther toward the blastopore, shows the medullary groove wider and shallower than in the more anterior sections. The mesoderm (*mes*) is here a layer laterally distinct from the entoderm. In the middle line it is still continuous with the entoderm, and at this place it is the more dense mass of cells that may be recognized as the notochord (*nt*). It is evidently difficult to decide whether this group of cells (*nt*), which will later become a distinct body, the notochord, is derived directly from the entoderm or from the mesoderm, which is itself a derivative of the entoderm. There is here absolutely no line of demarcation between the cells of the notochord and those of the mesoderm and entoderm.

In figure 3*j* the ectoderm (*cc*) is nearly flat, scarcely a sign of the medullary groove appearing. The mesoderm (*mes*) is here a distinct layer, entirely separate from both notochord (*nt*) and entoderm (*en*). The notochord is a clearly defined mass of cells, distinct, as has been said, from the mesoderm, but still closely united with the underlying entoderm, which is much thinner than the ectoderm.

This condition of the notochord, which is found throughout about one-third of the length of the embryo, would give the impression that the notochord is of a distinctly entodermal origin.

In figure 3*k* there is no sign of the medullary groove, though ectoderm (*ec*) is still much thickened in the middle line. The section passes, posterior to the notochord, through the anterior edge of the ventral opening of the blastopore (*blp*). The mesoderm (*mes*) is here again continuous with the entoderm, around the edge of the blastopore, but is distinct from the ectoderm.

Figure 3*l* represents the third section posterior to the preceding. The blastopore, which passes upward and backward through the blastoderm, is seen as an enclosed slit (*blp*). It is surrounded by a distinct layer of compactly arranged cells continuous with the thickened ectoderm (*ec*) above, with the thin entoderm (*en*) below, and laterally with the gradually thinning and scattering mesoderm (*mes*).

Figure 3*m* is the next section posterior to the one just described. It passes through the dorsal opening of the blastopore (*blp*), which appears as a deep, narrow cleft with thick ectodermal borders. The three germ layers are still continuous with each other, though the connection of the entoderm with the other two is slight. The sections posterior to this one will be described in the next stage, where they have essentially the same structure and are better preserved.

Figures 3*n* and 3*o* are sagittal sections of an embryo of about the stage under discussion. In both figures the head-fold is seen as a deep loop of ectoderm and entoderm, while the head-fold of the amnion is seen at *a*.

The beginning of the foregut is seen in figure 3*n* (*fg*), which is the more nearly median of the two sections, figure 3*o* being a short distance to the side of the middle line.

In figure 3*o* the thin entoderm (*en*) is separated from the much thicker ectoderm (*ec*) by a considerable layer of rather loose mesoderm (*mes*). In figure 3*n*, which is almost exactly median in position, there is, of course, no mesoderm to be seen in front of the blastopore, and the entoderm shows a considerable increase in thickness, due to the formation of the notochord (*nt*). The blastopore (*blp*) is the most striking feature of the figure, and is remarkable for its great width in an antero-posterior direction. Its anterior and posterior borders are outlined by sharply defined layers of ectoderm and entoderm. Posterior to the blastopore the lower side of the ectoderm is continuous with a considerable mass of cells, the primitive streak (*ps*).

## STAGE III

FIGURES 4, 4*a*, 5, 5*a*, and 6-6*i* (PLATES V, VI)

"Figures 4 and 4*a* are of an embryo removed, on June 18, from an egg which had been taken out of an alligator two days before. Figure 4, a dorsal view, is of special interest in that it shows a secondary fold taking place in the head-fold. This grows posteriorly along the median dorsal line, forming a V-shaped process with the apex pointing backward toward the blastopore. There is quite a deep groove between the arms of the V. The head-fold on the ventral side, as seen in figure 4*a*, made from the same embryo as figure 4, grows most rapidly on the mid-line, and also becomes thicker at that place. The medullary folds now begin to form on either side of the medullary groove, ending posteriorly on either side of the blastopore and anteriorly on either side of the point of the V-shaped process in the middle of the head-fold. This is seen in figure 5, which is a dorsal view of an embryo from an egg three days after it was taken out of an alligator. A ventral view of the same embryo (fig. 5*a*) represents the thickened process on the mid-line at its greatest development. For some reason the notochord did not show in this embryo, possibly owing to particles of the yolk material adhering about the mid-line.

"In an embryo a day or two older, the V-shaped fold of the head-fold is seen to have broken through at the apex, and each of the arms thus separated from one another unites with the medullary fold of its respective side. This can be seen in figure 6, which is a dorsal view of part of an embryo a day or two older than the one represented by figures 5 and 5*a*.

"This is so unexpected a method of formation for the anterior part of the medullary folds that I have made use of both figures 4 and 5. They were made from very perfect specimens, and the sections of both of them, and of the specimen from which figure 6 was drawn, proves that the structure is what it is indicated to be in surface appearance. That is, the transverse sections posterior to the V, in the embryos shown in figures 4 and 5, show the medullary groove and the medullary folds; the several sections passing through the apex of the V show neither groove nor folds, but only a median thickening; and in front of the point or apex of the V the successive sections discover a gradually widening groove between the arms, which is also much deeper than the shallow groove found posterior to the V. While I have not seen, and from the nature of the conditions one cannot see, the change actually proceeding from the form

of fig. 5 to that of fig. 6, still the explanation given appears to be the only one possible" (5).

A somewhat extended series of transverse sections of an embryo of about this age is represented in figures 6*a*-*i*.

Figure 6*a* is a section through the head-fold; it passes through the extreme anterior end of the secondary folds (*sf*) that were described, in surface view, above (figs. 5 and 6). The section was not quite at right angles to the long axis of the embryo, so that the fold on the right was cut further toward its anterior end than was the fold on the left. The pushing under of the head causes a forward projection of the secondary folds, so that the fold to the right appears as rounded mass of cells with a small cavity near its center. On the left the plane of the section passes through the posterior limit of the head-fold, and shows the cells of the secondary fold continuous with the dorsal side of the ectoderm (*ec*). As pointed out above by Clarke, the secondary folds are here some distance apart, and gradually approach each other as we proceed toward the posterior. The entoderm (*en*) is here flat and takes no part in the secondary folds.

In figure 6*b*, a short distance back of the one just described, the secondary folds (*sf*) are much larger and are closer together. On the right the section passes through the extreme limit of the head-fold, so that the secondary fold of that side is still a closed circle, with a few scattered cells enclosed. On the left the section is posterior to the head-fold; on this side the secondary fold is seen as a high arch of ectoderm, with a thick mass of entoderm beneath it.

Figure 6*c* represents a section which passes back of the head-fold on both sides. The secondary folds (*sf*) are seen as a pair of ectodermal arches continuous with each other in the middle line of the embryo. The ectoderm of the folds is much thickened and gradually becomes thinner distally. On the right the entoderm shows the same thickening (*en*) that was shown on the left side of the preceding figure. This thickened appearance of the entoderm is due to the fact that the section passes through the anterior limit of a tall fold of that layer, which underlies the similar fold of the ectoderm that has already been described. This secondary fold of the entoderm is seen on the left side of the section. It may be traced through several sections, but soon flattens out posteriorly.

Figure 6*d* is a short distance posterior to the preceding. The secondary folds are here much less pronouncedly arched and the deep groove between them is reduced to a line (*l*). The entoderm (*en*) is no longer markedly arched and is closely adherent, along the median plane, to the ectoderm, where there is seen the thickening

(*th*) that has been mentioned by Clarke (see above). Springing from the entoderm on each side of this thickening is a small mass of mesoderm (*mes*).

The section immediately posterior to the one just described is represented in figure 6*c*. The line (*l*) which separated the two secondary folds in the preceding section is no longer present, so that the ectoderm (*ec*) is continuous from side to side, with only a shallow depression (*mg*), which may be considered as the extreme anterior end of the medullary groove. The median thickening (*th*) is cut near its posterior limit and still shows a close fusion of the germ layers. There is no line of demarcation between the gradually flattening secondary folds of the anterior end of the embryo and the just forming medullary folds of the posterior end, so that it is impossible to say whether the thickening of ectoblast in this figure should be called secondary folds or medullary folds. As a matter of fact, the secondary folds become, of course, the anterior ends of the medullary folds. The mesoblast (*mes*) is here of considerable extent, and its entodermal origin is beyond doubt, though not well shown in the figure.

Figure 6*f* is about one-sixth of the length of the embryo posterior to the preceding. The medullary thickening of the ectoderm (*ec*) is still marked and the shallow medullary groove (*mg*) is fairly distinct. The entoderm (*en*) is medially continuous with both mesoderm (*mes*) and notochord (*nt*), though these two tissues are otherwise distinct from each other.

Figure 6*g* is nearly one-third the length of the embryo posterior to the preceding and passes through the posterior third of the embryo. The medullary thickening of the ectoderm (*ec*) is marked, but shows no sign of a medullary groove; in fact, the median line is the most elevated region of the ectoderm. The notochord (*nt*) is larger in cross-section than in the more anterior regions. It is still continuous with the entoderm (*en*) and is fairly closely attached to, though apparently not continuous with, the mesoderm (*mes*) on each side.

Figure 6*h* passes through the blastopore (*blp*). The appearance of the section is almost identical with that of figure 2*f*, already described.

Figure 6*i* is five sections posterior to the preceding and has about the same structure as the corresponding sections in the preceding two stages, where this region of the embryo was injured, and hence not drawn. Continuous with the posterior border of the blastopore (seen in the preceding figure) is the deep furrow, the primitive groove (*pg*). The ectoblast (*ec*) bordering this groove is much

thickened and may be called the primitive streak. The lower side of this primitive streak is continuous with the mesoblast (*mes*), while the entoderm (*en*) is here entirely distinct from the mesoderm. It is evident that the mesoderm posterior to the blastopore is proliferated from the lower side of the ectoblast and not from the upper side of the entoblast, as is the case anterior to the blastopore. The primitive groove gradually becomes more and more shallow, as it is followed toward the posterior, until it is no longer discernible; back of this point the primitive streak may be traced for a considerable distance, becoming thinner and thinner until it too disappears, and there remains only the slightly thickened ectoblast underlaid by the thin and irregular layers of mesoblast and entoblast. The primitive streak may be traced for a distance equal to about one-third the distance between the head-fold and the blastopore.

#### STAGE IV

FIGURES 7a-7h (PLATES VI, VII)

No surface view of this stage was seen by the writer, and hence is not figured. The figures were drawn from one of the series of sections obtained through the courtesy of Prof. S. F. Clarke. This series was marked "3 Urwirbeln," so that the embryo was apparently slightly younger than the youngest stage obtained by myself and represented in figures 8 and 8a.

Figure 7a represents a section that passed through the head-fold of the amnion (*a*) just in front of the head-fold of the embryo; the amniotic cavity here appears as a large empty space.

Figure 7b is several sections posterior to the preceding; it passes through the head-fold of the embryo, but is just back of the head-fold of the amnion. The deep depression of the ectoderm (*ec*) and entoderm (*en*) caused by the head-fold is plainly seen. In this depression lie the ends of the medullary folds, distinct from each other both dorsally and ventrally. Each medullary fold is made up of two parts—a medial, more dense nervous layer (*nl*), and a distal, less dense epidermal layer (*ep*). The section corresponding to this one will be more fully described in connection with the following stage.

Figure 7c is some distance posterior to the preceding, though the exact distance could not be determined because of a break in the series at this point. The section passes through the posterior limit of the head-fold. The medullary groove (*mg*) is very deep and comparatively wide; around its sides the germ layers are so closely associated that they may scarcely be distinguished. Ventral to the medullary groove the foregut (*fg*) is seen as a crescentic slit.

Figure 7*d* is about a dozen sections posterior to the one just described and is about one-seventh the length of the embryo from the anterior end. The embryo is much more compressed, in a dorso-ventral direction, and the medullary groove (*mg*) is correspondingly more shallow. Where the ectoderm (*ec*) curves over to form the medullary folds it becomes much more compact and somewhat thicker. The notochord (*nt*) is large and distinct, but is still fused with the entoderm (*en*). The mesoderm (*mes*) forms a well-defined layer, entirely distinct from both the notochord and the entoderm. From this region, as we pass caudad, the size of the embryo in cross-section gradually decreases and the medullary groove becomes more shallow.

Figure 7*e* is about one-third of the length of the embryo from the posterior end, and is only a few sections from the caudal end of the medullary groove. The ectoderm (*ec*) is much thinner than in the preceding figure and the medullary groove (*mg*) is much more shallow. The notochord (*nt*) is of about the same diameter as before, but is here quite distinct from the entoderm (*en*) as well as from the mesoderm (*mes*).

Figure 7*f* is seven sections posterior to figure 7*e*. The medullary groove has disappeared and the medullary folds have flattened to form what might be called a medullary plate (at the end of the reference line *ec*), which continues to the anterior border of the blastopore. The notochord (*nt*) is larger in cross-section than in the more anterior regions; it is still distinct from the entoderm.

Figure 7*g* passes through the blastopore and shows essentially the same structure as was described in connection with the corresponding section of stage I (fig. 2*f*).

Figure 7*h* represents the region of the primitive groove (*pg*) and primitive streak (*ps*). The section shows the typical structure for this region—a thick mass of cells is proliferating from the ventral side of the ectoderm (*ec*) and is spreading laterally to form a distinct mesoderm (*mes*). The entoderm (*en*) is entirely distinct from the other layers.

## STAGE V

### FIGURES 8-8*j* (PLATES VII, VIII, IX)

On opening the egg this embryo (figs. 8 and 8*a*) was found to lie on the end of the yolk, near the center of the irregular, lighter area which was mentioned in connection with the description of the egg. The length of the embryo proper is 3 mm. This was the youngest

stage found in 1905, and approximates quite closely the condition of the chick embryo after 24 hours' incubation. The dorsal aspect of this embryo, viewed by transmitted light, is shown in figure 8. The medullary folds (*mf*) have bent over until they are in contact, though apparently not fused for a short distance near their anterior ends. As will be described in connection with the sections of this stage, the medullary folds are actually fused for a short distance at this time, though in surface views they appear to be separated from each other. In the Madagascar crocodile (18) the first point of fusion of the medullary folds is in the middle region of the embryo, or perhaps even nearer the posterior than the anterior end of the medullary groove. Throughout the greater part of their length the medullary folds are still widely separated; posteriorly they are merged with the sides of the very distinct primitive streak (*ps*), which seems, owing to its opacity, to extend as a sharp point toward the head. Extending for the greater part of the length of the primitive streak is the primitive groove (*pg*), which, when the embryo is viewed by transmitted light, is a very striking feature at this stage of development and resembles, in a marked way, the same structure in the embryo chick. Clarke (5) figures the blastopore at this stage as a small opening in front of the primitive streak, but does not mention any such condition as above described at any stage of development. Five pairs of somites (*s*) have been formed and may be seen, though but faintly outlined, in both dorsal and ventral views of the embryo; they lie about half way between the extreme ends of the embryo. The head-fold (*h*, fig. 8*a*) shows plainly in a ventral view as a darker, more opaque anterior region, extending for about one-fourth the length of the embryo. The still unfused region of the medullary folds may be seen also in the ventral view at *mg*. The head-fold of the amnion (*a*) forms a very thin, transparent hood over the extreme anterior end of the embryo. The tail-fold of the amnion has not made its appearance, and in fact is not apparent at any stage in the development. This is true also of the Madagascar crocodile. The notochord (*nt*) may be seen in a ventral view as a faint, linear opacity extending along the middle line from the head-fold to the primitive streak.

Two sagittal sections of this stage are shown in figures 8*b* and 8*c*. The embryo from which the sections were made was apparently somewhat crooked, so that it was not possible to get perfect longitudinal sections. For example, in figure 8*b* the plane of the section is almost exactly median in the extreme posterior and middle regions, but is on one side of the middle line elsewhere. This explains the enormous thickening of the ectoblast in the region of the head, where



the section passes through one of the medullary folds (*mf*) at its thickest part; and also explains the fact that the ectoblast is thinner in the middle region (*cc*), where the section passes through the medullary groove, than it is farther toward the blastopore, where the section cuts the edge of the medullary folds. The outlines of the middle and extreme posterior regions of the ectoblast are much more irregular and ragged than is shown in the figure. The plane of the section passes through the notochord (*nt*) in the posterior region, but not in the anterior end of the embryo, where a layer of mesoblast (*mes*) is seen. The great size of the blastopore (*blp*) is well shown, as is the beginning of the foregut (*fg*). Comparison of this figure with the more anterior transverse sections and with the dorsal surface view of this stage will make the rather unusual conditions comprehensible.

Figure 8c is cut to one side of the median plane, distal to the medullary folds. Being outside of the medullary folds, the ectoderm (*cc*) is thinner and less dense than in figure 8b; anteriorly it is pushed down and back as the head-fold, and posteriorly it becomes thin where it forms the dorsal boundary of the primitive streak (*ps*).

The foregut (*fg*), as would be expected, is not so deep as in the median section (8b). The most striking feature of the section is the presence of five mesoblastic somites (*s*). Each somite, especially the second, third, and fourth, is made up of a mass of mesoblast whose cells are compactly arranged peripherally, but are scattered in the center, where a small myocoel may be seen.

A series of transverse sections of the embryo shown in figures 8 and 8a is represented in figures 8d-j.

Figure 8d is through the anterior end of the embryo; the posterior edge of the amnion is cut only on one side (*a*). The medullary folds (*mf*) are shown as two distinct masses of tissue, separated by a considerable space from each other, both dorsally and ventrally; they are underlaid by the ectoderm of the head-fold, through which the section passes. A mass of yolk (*y*) is shown at one side of the section.

Figure 8e represents a section a short distance posterior to the one just described, and passes through the short region where the dorsal edges of the medullary folds have fused with each other. The ventral side of the medullary groove (*mg*) is, as in the preceding section, still unclosed. An epidermal layer of ectoblast (*ep*) is now distinct from the nervous layer (*nl*).

Figure 8f is through a region still farther toward the posterior end. Here the medullary groove is *again* open above, and is still

open below. A well-marked space is seen between the epidermal (*ep*) and nervous (*nl*) layers of the ectoderm, but no mesoblast is yet to be seen.

Figure 8g passes through the middle part of the head-fold, and shows that the medullary folds in this region are fused below, but are widely separated above, where their margins are markedly bent away from the mid-line. Between the epidermal and nervous layers of the ectoderm a considerable mass of mesoderm cells (*mes*) is seen. The curious appearance of the preceding four figures, as well as the first three figures of the next stage, was at first quite puzzling, until a model of the embryo was made from a series of sections. It was then plain, as would have been the case before, except for the unusual depth dorso-ventrally of the head of the embryo, why the medullary canal should at the extreme anterior end be open both dorsally and ventrally, while a few sections caudad it is open only ventrally, and still farther toward the tail it is again open both above and below. These conditions are produced by the bending under of the anterior region of the medullary folds, probably by the formation of the head-fold. It is apparently a process distinct from the ordinary cranial flexure, which occurs later. The fusion of the medullary folds to form a canal begins, as has been already mentioned, near the anterior end, whence it extends both forward and backward. Hence, if the anterior ends of the medullary folds be bent downward and backward, their unfused dorsal edges will come to face ventrally instead of dorsally, and sections through the anterior part of this bent-under region will show the medullary canal open both above and below, as in figure 8d, while sections farther caudad pass through the short region where the folds are fused, and we have the appearance represented in figure 8e. In figure 8f is shown a section passing posterior to the short, fused region of the folds, and we again have the medullary canal open both above and below. Figure 8g represents a section through the tip of the bent-under region of the medullary folds, which are here fused below and open above.

Figure 8h passes through the posterior part of the head-fold, between the limits of the fold of the ectoderm and that of the entoderm. The medullary groove (*mg*) is here very wide and comparatively shallow; its walls are continued laterally as the gradually thinning ectoderm (*ec*). The enteron (*ent*) is completely enclosed, and forms a large, somewhat compressed, thick-walled cavity. Between the dorsal wall of the enteron and the lower side of the medullary canal lies the notochord (*nt*), a small, cylindrical rod of closely packed cells derived, in this region at least, from the entoderm. In the posterior region of the embryo it is not possible to determine

with certainty the origin of the notochord, owing to the close fusion of all three germ layers. Between the wall of the enteron and the lower side of the ectoderm is a considerable mass of mesoderm (*mes*), which here consists of more scattered and angular cells than in the preceding section.

Figure 8*i* shows the appearance of a section through the mesoblastic somites, in one of which a small myocoel (*myc*) is seen. As is seen by the size of the figure, which is drawn under the same magnification as were all the sections of the series, the embryo in this region is much smaller in section than it is toward either end, especially toward the anterior end. The medullary groove (*mg*) is still more shallow than in the more anterior sections, and the ectoderm (*ec*), with which its folds are continuous laterally, is here nearly horizontal. The mesoblast (*mes*) is of a more compact nature than in the preceding section and shows little or no sign of cleavage, although a distinct myocoel may be seen and cleavage is well marked in sections between this one and the preceding.

The notochord (*nt*) has about the same appearance as in the preceding section, but is more distinctly separated from the surrounding cells.

Figure 8*j* is through the posterior end of the embryo; it shows the relation of parts in the region of the primitive streak. Although not visible in surface views, and hence not represented in figure 8, the medullary groove is continued without any line of demarcation into the primitive groove, and the medullary folds into the edges of the primitive streak, so that it is impossible to set any definite boundaries between these structures unless the dorsal opening of the blastopore be taken as the point of division. The medullary groove (*mg*), if it be here so called, is proportionately more shallow than in the preceding figure and is actually much wider. The section passes behind the posterior end of the notochord, so that structure is not seen. Though not so well indicated as might be desired in the figure, the three germ layers are here indistinguishable in the middle line, and in the center of this mass of cells the blastopore (*blp*) or neurenteric canal may be seen as a small vertical slit. As will be more fully described in the following stage, this canal opens dorsally a few sections posterior to the one under discussion and ventrally a few sections farther toward the head.

In all the sections of this stage the ectoderm and entoderm are fairly thick in the region of the embryo proper, but become thinner until reduced to a mere membrane as we pass to more distal regions. Both layers are composed of loosely arranged cells, with scattered

nuclei. Where the ectoderm becomes thickened to form the medullary folds, the cells are much more compactly arranged; hence this region stands out in strong contrast to the rest of the ectoderm.

## STAGE VI

### FIGURES 9a-9m (PLATES IX, X)

The embryo represented by this series of transverse sections is intermediate in development between those represented in surface views by figures 8 and 10. The amnion and head-fold are nearly the same as in figure 8; the medullary folds are intermediate in development, the anterior end not showing so marked an enlargement as shown in figure 10, *v'*. There are six or seven faintly distinguishable somites.

Figure 9a represents a section through the anterior part of the head-fold; it shows one unusual condition: the head lies entirely beneath the surface of the yolk. This condition is quite confusing when the section is studied for the first time. The pushing of the head under the yolk is shown at its commencement in figure 11. The process continues until nearly the entire anterior half of the embryo is covered; but when the embryo attains a considerable size it is seen to lie entirely above the yolk, as in the chick. According to Voeltzkow's figures (18), this same condition is found in the crocodile, and Balfour (2) also mentions it in connection with the lizard. The fusion of the medullary folds has made considerable progress, so that the entire anterior end of the canal is enclosed, except in the region where the folds are bent down and back, as in the preceding stage; here the folds are still distinct from each other, leaving the medullary canal open on the ventral side, as shown in figures 9 and 9b. In the section under discussion the ectoderm (*cc*) is a very thin membrane on top of a considerable mass of yolk, while no entoderm can be distinguished. The amnion (*a*) completely surrounds the embryo as an irregular membrane of some thickness in which no arrangement into layers can be seen. The epidermal ectoderm (*ep*) is composed of the usual loosely arranged cells, so that it is clearly distinguishable from the compactly arranged cells of the nervous layer (*nl*), from which it is separated by only a line.

In figure 9b, which shows a section a short distance posterior to the preceding, the medullary canal (*mc*) is somewhat deeper and is still open ventrally. There is a distinct space between the nervous (*nl*) and epidermal (*ep*) layers of the ectoderm, in which space a few mesoblast cells (*mes*) may be seen. The section is cut just posterior to the edge of the amnion, so that there is now neither amnion nor yolk above the embryo.

Figure 9c is about ten sections posterior to figure 9b. The section passes through the anterior wall of the bent-under part of the medullary canal (*mc'*), so that the actual canal is shown only on the dorsal side (*mc*), where it is completely closed and begins to assume the shape of the typical embryonic spinal cord. The space between the superficial (*ep*) and nervous (*nl*) layers of the ectoderm is quite extensive and is largely filled by a fairly compact mass of mesoderm (*mes*).

Figure 9d, although only five sections posterior to the preceding, shows a marked change in structure. The medullary canal (*mc*) is here of the typical outline for embryos of this age. A large, compact mass of cells (*ent*) appears at first glance to be the same that was noted in the preceding stage at the tip end of the turned-under medullary canal; it is, however, the extreme anterior wall of the enteron, which is in close contact with the above-mentioned tip of the medullary canal. Between this anterior wall of the enteron, of which wall it is really a part, and the medullary canal is the notochord (*nt*). The space surrounding the notochord and enteron is filled with a fairly compact mass of typical, stellate mesoblast cells. The depression of the ectoderm (*ec*) and entoderm (*en*) of the blastoderm caused by the formation of the head-fold is here less marked, and the dorsal side of the embryo in this region is slightly elevated above the level of the blastoderm.

Figure 9e represents a section passing through the posterior edge of the head-fold. The epidermal ectoderm is here continuous with the thin layer of superficial ectoderm (*ec*) of the blastoderm, while the entoderm (*en*) of the blastoderm is still continuous beneath the embryo. The thick ectoderm of the embryo is sharply differentiated from the thin layer of ectoderm that extends laterally over the yolk. The pharynx (*ent*) is a large cavity whose wall is thick except at the dorsal side, where it is thin and somewhat depressed, apparently to make room between it and the medullary canal for the notochord (*nt*).

Figure 9f is about twenty sections posterior to the preceding section, and passes through the point of separation of the folds of the entoderm (*en*). From this point the entoderm gradually flattens out, leaving the enteron unenclosed. The medullary canal (*mc*) and notochord (*nt*) are about as in the preceding section, but the ectoderm (*ep*) is somewhat thinner and more flattened. The mesoderm (*mes*) on the right side exhibits a distinct cleavage, the resulting body cavity (*bc*) being a large, triangular space.

Figure 9g, the twenty-fifth section posterior to that represented in

figure 9f, shows a marked change in the form of the embryo. While of about the same lateral dimensions, the dorso-ventral diameter of the embryo in this region is less than one-half what it was in the head region. The epidermal ectoderm (*ep*) is now nearly horizontal in position and is not so abruptly separated laterally from the thin lateral sheets of ectoblast. The medullary groove (*mg*) is here a very narrow vertical slit. At this stage the fusion of the medullary folds has taken place over the anterior third of the embryo. For a short distance, represented in about thirty-five sections, the canal is open, as in the figure under discussion; for the next one hundred sections (about one-third the length of the embryo) in the region of the mesoblastic somites the canal is again closed, while throughout the last one-third of its length the canal is widely open dorsally. The enteron is here entirely open ventrally, the entoderm being almost flat and horizontal. The notochord (*nt*) is distinctly outlined and is somewhat flattened in a dorso-ventral direction. The body cavity (*bc*) is well marked, but is separated by a considerable mass of uncleft mesoblast from the notochord and the walls of the medullary groove.

A space of about one hundred sections, or one-third the length of the embryo, intervenes between figures 9g and 9i. This is the region of the mesoblastic somites, and in this region, as has been above stated, the medullary canal is completely enclosed. It is evident then that the entire anterior two-thirds of the medullary canal is enclosed except for the short region represented in figure 8g. Whether or not this short open region between the two longer enclosed regions is a normal condition the material at hand does not show.

Figure 9h represents a typical section in the region of the mesoblastic somites just described. It shows the enclosed medullary canal (*mc*), the body cavity (*bc*) on the right, and a mesoblastic somite with its small cavity (*myc*) on the left. The entire section is smaller than the sections anterior or posterior to this region, and seems to be compressed in a dorso-ventral direction, this compression being especially marked in the case of the notochord.

Figure 9i is through a region nearly one hundred sections posterior to the preceding, and cuts the embryo, therefore, through the posterior one-fourth of its length. The chief difference between this and the preceding section is in the medullary canal, which is here open and is in the form of a wide groove with an irregular, rounded bottom and vertical sides. The size of the section is considerably greater than in the preceding, the increase being especially noticeable

in the notochord (*nt*), which is cut near its posterior end. There is little or no sign of mesoblastic cleavage.

Figure 9*j* is about twenty sections posterior to figure 9*i*. The medullary groove (*mg*) is considerably larger than in the more anterior regions, and its folds are somewhat inclined toward each other, though still wide apart. The notochord and entoderm are fused to form a large, compact mass of tissue close under the ventral wall of the medullary groove. On the ventral side of this mass of cells a groove (*blp*) marks the anterior and ventral opening of the blastopore shown in the next figure. The mesoblast shows no sign of cleavage.

Figure 9*k* shows the medullary groove (*mg*) in about the same position as in the preceding section. The blastopore (*blp*) is here seen as a small cavity in the center of the large mass of cells that was noted in the last figure. The entoderm (*en*) is continuous from side to side, but is not so sharply differentiated from the other germ layers as is represented in the figure.

Figure 9*l* is four sections back of the preceding; the wide, dorsal opening (*blp*) of the blastopore or neurenteric canal into the medullary groove (*mg*) is shown. The blastopore or neurenteric canal, then, is still at this stage a passage that leads entirely through the embryo, the medullary canal being in this region unenclosed above. Ventrally it is seen as a narrow opening through the entoderm; it then passes upward and backward, behind the end of the notochord, as a small but very distinct canal, which may be traced through about ten sections. The enclosed portion of the canal lies, as has been stated (figure 9*k*, *blp*), in the center of the mass of cells that is fused with or is a part of the floor of the medullary groove.

The above-described neurenteric canal is essentially like that described by Balfour (2) in the *lacertilia*. He does not say, however, and it is not possible to tell from his figures, whether there is a long, gradually diminishing groove posterior to the dorsal opening of the canal, as in the alligator. He says that the medullary folds fuse posteriorly until the medullary canal is enclosed over the opening of the neurenteric canal; also that "the neurenteric canal persists but a very short time after the complete closure of the medullary canal."

In figure 9*m*, for about thirty sections (one-tenth the entire length of the embryo), behind the section represented in the last figure, there is a very gradual change in the embryo, converting the deep groove, *mg* in figure 9*l*, into the shallow slit, *pg*, figure 9*m*.

There is no line of demarcation between the typical medullary groove region of figure 9*l* and the equally typical primitive groove

region represented in figure 9*m*. As was noted in the preceding stage, the medullary folds are quite continuous with the folds of the primitive streak, and the medullary groove with the primitive groove; so that, unless we take the dorsal opening of the neurenteric canal as the point of separation, there is no line of division between these structures. The entoderm (*en*) and the lateral regions of the ectoderm (*ec*) and mesoderm (*mes*) in figure 9*m* are about as they were in figure 9*l*, but in the middle line is seen a compact mass of cells forming the primitive streak (*ps*), with the shallow primitive groove (*pg*) on the dorsal side. The cells on each side of the primitive groove and for a short distance below it are compact, as is shown in the figure, but as we pass ventrally and laterally they become looser and more angular to form the lateral sheets of mesoblast (*mes*), very much as is the case in the chick and other forms. For a few sections posterior to the one shown in figure 9*m* the primitive streak may be seen, then it disappears, and only the ectoderm and entoderm remain as thin sheets of tissue above the yolk.

## STAGE VII

### FIGURES 10 and 10*a* (PLATES X, XI)

Although of practically the same size as the preceding, this stage has advanced sufficiently in development to warrant a description.

The medullary folds are apparently still slightly open for the greater part of their length, though they are evidently fused together in the head region, except at the extreme end. Transverse sections, however, of figure 12, in which the medullary folds, from the dorsal aspect, seemed open (*mg*) as in figure 10, have shown that these folds are fused throughout their length.

The first cerebral vesicle (*v'*) is clearly indicated as an enlargement of the anterior end of the nervous system, and a slight enlargement (*v''*) posterior to the first probably represents the second cerebral vesicle.

There are now eight pairs of somites (*s*).

The head-fold (*h*) now shows in both dorsal and ventral views, appearing in the former, when viewed by transmitted light, as a lighter, circular area on either side of the body, just posterior to the hinder edge of the amnion.

The head-fold of the amnion (*a*) has extended about twice as far backward as it did in the preceding stage.

Owing to the opacity caused by the medullary folds being in contact along the middle line, the notochord is no longer visible in surface views.



The head at this stage begins to push down into the yolk in a strange way that will be described later.

### STAGE VIII

FIGURES 11-11*k* (PLATES XI, XII, XIII)

This stage is about one-fourth longer than the preceding. The medullary canal is enclosed throughout its entire length, though it appears in surface view (fig. 11) to be open in the posterior half (*mc*) of the embryo. An enlargement of this apparently open region at the extreme posterior end (*pg*) is probably caused by the remains of the primitive groove or the neurenteric canal, and a slight opacity at the same point may be caused by the primitive streak. The anterior end of the neural tube is bent in a ventral direction (*v'*), as in the preceding stage. The somites (*s*) now number fifteen pairs; they are somewhat irregular in size and shape.

The head-fold is not so striking a feature as in the preceding stage. The head-fold of the amnion (*a*) now covers nearly two-thirds of the embryo. The heart (*ht*) is seen as a dark, rounded object projecting to the right side of the neural canal, just anterior to the first somite. The vitelline blood-vessels are just beginning to form, but are not shown in the figure.

The depression of the anterior region that was noted in the preceding stage has advanced so far that a considerable part of the embryo now projects forward under the blastoderm. In some cases it is almost concealed in a dorsal view; in other cases it may easily be seen through the transparent membranes, especially after clearing.

In opening eggs of this stage one is at first apt to underestimate the size of the embryos, since the anterior part of the embryos cannot be seen until after they are removed from the yolk and are viewed from the ventral side.

The embryo from which the series of transverse sections of this stage was made, while of the same state of development as that shown in figure 11, was more fully covered by the blastoderm than is shown in the surface view in question.

Figure 11*a* passes through the tip of the head. Dorsal to the embryo is the ectoderm and a thick mass of yolk (*y*). The amnion (*a*) is seen as an irregular membrane which entirely surrounds the head. The medullary canal (*mc*) is entirely closed, except at the extreme anterior end, which is bent downward so that the opening is on the ventral side. The nervous (*nl*) and epidermal (*ep*) layers of the ectoderm are in contact throughout, but are clearly distinguishable because of the difference in the compactness of their cells.

In figure 11*b* is represented a section, behind the preceding, which passes through the posterior tip of the turned-under anterior end (*mc'*). Here the medullary canal is closed both above (*mc*) and below (*mc'*). The amnion (*a*) has about the same appearance as in the more anterior section, but there is here a considerable space, filled with mesoblast (*mes*), between the nervous (*nl*) and epidermal (*ep*) layers of ectoderm.

Figure 11*c* is twenty sections, about one-tenth the length of the embryo, posterior to the one last described. The large mass of overhanging yolk (*y*) is still present, as is also the amnion (*a*), though the latter no longer passes entirely around the embryo; only the true amnion could be made out. The thickened walls of the medullary canal have reduced that cavity to a narrow, Y-shaped slit (*mc*). The notochord (*nt*) is very slender in this region, compared to its diameter farther toward the posterior end. The enteron (*ent*) is a large cavity, whose wall is made up of loosely arranged cells except around a median, ventral depression where the cells are more compact. This depression may be traced through ten or fifteen sections and may represent the beginning of the thyroid gland, though this point was not worked out with certainty. Surrounding the notochord and enteron is a loose mass of typical, stellate mesoblast cells (*mes*), which are cleft on either side to form the anterior limit of the body cavity (*bc*). Between the body cavity below and the enteron above, on each side, is a small blood-vessel (*bv*) which when followed caudad is found to open ventrally and medially into the anterior end of the heart.

Figure 11*d* is about a dozen sections posterior to the preceding. The appearance of the overhanging yolk (*y*) of the amnion (*a*) and of the notochord (*nt*) is about as in the more anterior section. The medullary canal (*mc*) is a straight, vertical slit, and the depression in the floor of the pharynx (*ent*) is much more shallow. The body cavity (*bc*) is much larger and extends across the mid-ventral line beneath the heart (*ht*), which is cut through its middle region. The heart may be traced through about twenty sections (one-tenth the length of the embryo); its mesoblastic wall (*mes'*) is thin and irregular, and is lined by a distinct endothelium (*en'*) whose exact origin has not yet been worked out.

Figure 11*e* is just back of the heart, and shows in its place the two vitelline veins (*vv*). The depression in the floor of the enteron (*ent*) is entirely distinct from the one that has been mentioned above, and is simply the posterior limit of the head-fold of the enteron; the fifth section posterior to this shows where this depression

opens ventrally to the yolk sac. The other structures shown in the figure are not markedly different from what was seen in figure 11*d*.

Figure 11*f* is about one-tenth the length of the embryo posterior to figure 11*c*. The chief differences here noticed are in the enteric and coelomic cavities. The former is no longer enclosed, a dorsal fold in the entoderm being all that remains of the cavity that was seen in the more anterior figures, while the latter is here reduced to a narrow cleft between the somatic and splanchnic mesoblast. A thickening of the mesoblast on either side of the notochord, especially on the left, represents a mesoblastic somite. The medullary canal (*mc*) is more open than in the more anterior sections.

For about one-third of the length of the embryo posterior to figure 11*f* there is a gradual flattening, in a dorso-ventral direction, with loss of the amnion, until the condition represented in figure 11*g* is reached. The most striking feature of this region is the great thickness of the ectoderm (*ec*), which is still made up of scattered, irregular cells. In the middle line, directly over the medullary canal (here a nearly cylindrical tube), is a sort of break in the ectoderm, as though there had not been a complete fusion of the epidermal layer when the nervous layer came together on the closure of the medullary groove. This break in the ectoderm may be followed back to the region of the primitive streak, and will be mentioned again. As has been noted, the medullary canal (*mc*) is nearly circular in cross-section, and is closely underlaid by the notochord (*nt*), which is several times the diameter that it was in more anterior sections. The mesoblast (*mcs*) is a comparatively thin layer, intermediate in thickness between the ectoderm and entoderm. It shows laterally a slight separation to form the body cavity.

Figure 11*h* is about ten sections posterior to figure 11*g*, and differs from it chiefly in that the notochord (*nt*) is continuous with the lower side of the medullary canal (*mc*), though still distinct from the underlying entoderm (*en*).

Figure 11*i*, four sections farther from the head, shows the same greatly thickened ectoderm (*ec*) with the same break (*ec'*) in the middle line. The section is posterior to the notochord and passes through the anterior edge of the blastopore or, as it may now perhaps better be called, the neurenteric canal. The cells of the medullary wall are continuous with those of the entoderm. The mesoderm (*mcs*) is still distinct from the other germ layers.

Figure 11*j* is the next section posterior to the one just described and differs from it only in showing the actual opening of the neurenteric canal (*nc*) into the medullary canal (*mc*). The medullary canal extends, with gradually diminishing caliber, for about fifteen

sections posterior to the point at which the neurenteric canal empties into it. The mesoblast (*mes*) is so closely attached to the lower wall of the neurenteric canal that it seems to be actually continuous with it.

For a considerable distance posterior to the end of the medullary canal we find the structure similar to that shown in figure 11*k*, which is about the twentieth section posterior to figure 11*j*. The break (*cc'*) in the ectoderm is here seen as a compact group of cells which at first glance seem to be continuous with a rounded mass of cells below (*ps*). Examination under greater magnification, however, shows that the two groups of cells are distinct. As the sections are followed back of this region, the upper mass of cells (*cc'*) gradually disappears, and after its disappearance the lower mass (*ps*), which is already continuous with the mesoderm (*mes*) on either side, becomes continuous with the under side of the ectoderm. The mass of cells (*ps*) is apparently the primitive streak, though it is distinct from the ectoderm for a considerable distance posterior to the neurenteric canal. Just what may be the meaning of the thickened ridge of ectoderm (*cc'*) it is difficult to determine.

## STAGE IX

### FIGURES 12-12*g* (PLATES XIII, XIV)

The entire length of the embryo proper is 6.5 mm. from the extreme posterior end to the region of the midbrain (*v*<sup>2</sup>), which now, on account of the cranial flexure, forms the most anterior part of the body. Besides being slightly longer than the preceding stage, the embryo has increased in thickness, especially in the anterior region, where the enlargement of the cerebral cavity is considerable.

Body torsion has begun (fig. 12), so that the anterior third of the embryo now lies on its right side, while the rest of the body is still dorsal side up. The direction of body torsion does not seem to be as definite as it is in the chick, some alligator embryos turning to the right side, others to the left. Clarke has illustrated this fact in his alligator figures. He says (5) that embryos lie "more frequently on the left, but often on the right side."

The head is distinctly retort-shaped, and at the side of the fore-brain (*v'*) a small crescentic thickening is the optic vesicle (*e*). The auditory vesicle, though of considerable size, does not show in this surface view. The head-fold (*h*) extends for about one-third the length of the entire embryo, though its exact limit is difficult to determine in surface view. There is no sign of a tail-fold.

About seventeen pairs of somites are present.

The amnion extends over the anterior two-thirds of the embryo.

The above-mentioned increase in the diameter of this embryo over that of the preceding is evident when the first two transverse sections of this stage are compared with the corresponding sections of the earlier stage: in the middle and posterior regions there is not very much difference in size.

Figure 12a passes through the region of the forebrain. This end of the embryo lies on its side, as was noted above and as may be recognized from the relative positions of the head and the overlying yolk (*y*). The great size of this and the following figure is due partly to the increase in size mentioned above and partly to the fact that the sections pass through the region of cranial flexure. The present figure (12a) represents the brain cavity as large and dumb-bell-shaped, with comparatively thick walls of compactly arranged cells. The ventral end of this cavity (*fb*) is cut anterior to the region of the optic vesicles, while the dorsal end (*mb*) may perhaps be called the midbrain. In the sections that follow this one the two cavities are distinct from each other. The medullary canal, as was stated above, is now completely enclosed, except for the ventral opening of the neurenteric canal, to be presently noticed. Surrounding the brain is a considerable mass of mesoblast (*mes*). It is composed of the typical stellate cells. The ectoderm (*ec*) is made up of the same irregularly and loosely arranged cells that have been seen in earlier stages; it is of unequal thickness in different regions, the thicker parts being at the sides. The amnion (*a*) has the usual appearance, and in this region of course completely surrounds the embryo.

Figure 12b is ten sections posterior to the section just described. The width of the embryo is greater in this region, but the dorso-ventral diameter is about the same as in the more anterior section.

The overlying yolk and blastoderm are not shown in any figure of the series except the first. In this figure the forebrain (*fb*) and midbrain (*mb*) are widely separated instead of being connected, as in the preceding figure, where the section passed through the actual bend of the cranial flexure. The anterior and ventral part of the cranial cavity, the forebrain (*fb*), is nearly circular in outline. It exhibits on one side a well-marked optic vesicle (*ov*), which is sufficiently advanced in development to show a rudimentary optic stalk. The outer wall of the optic vesicle is in close contact with the superficial ectoderm, which shows as yet no sign of the formation of a lens vesicle. The plane of the section being probably not quite at right angles to the long axis of the embryo, the optic vesicle of one

side only was cut. The wall of this part of the forebrain is of about the same thickness and appearance as in the preceding stage. The other cerebral cavity (*mb*) of this section is probably the hinder part of the midbrain, though it may be the anterior part of the hindbrain; there is no sharp line of demarcation between these regions of the brain. This cavity (*mb*) is much smaller in section than the forebrain; its walls are of about the same thickness.

Ventral to the midbrain is the anterior end of the notochord (*nt*), surrounded by the mesoblast. At various places throughout the mesoblast irregular open spaces may be seen; these are blood-vessels. The ectoderm (*cc*) and amnion (*a*) have about the same appearance as in the preceding figure, though the former seems somewhat thinner.

Figure 12c is just back of the bent-under forebrain represented in the preceding figure and in front of the main body of the heart. The plane of the section not being at right angles to the long axis of the body (as was mentioned above), the figure is not bilaterally symmetrical. The neural canal, since the section passes through the auditory vesicles, may here be called the hindbrain (*hb*). It has an almond-shaped cavity, surrounded by a wall of medium thickness. In close contact with the wall of the hindbrain, on each side, is the inner side of the auditory vesicle (*o*), which is seen as a deep, wide-mouthed pit in the superficial ectoderm. On the right side of the section the auditory pit is cut through its middle region; it is simply a thickened and condensed area of the ectoderm which has been invaginated in the usual way. Directly beneath the hindbrain is the notochord (*nt*), on each side of which, in the mesoblast, is the dorsal aorta (*ao*), or rather the continuation of the aorta into the head. Beneath these structures and extending from one side of the section to the other is the pharynx (*ph*); its lining wall is fused on each side with the ectoderm, but there is no actual opening to the exterior. These points of contact (*g*) between entoderm and ectoderm are of course the gill clefts; they are not yet visible from the outside. The roof of the pharynx is flat and comparatively thin, while the floor is thickened and depressed to form a deep, wide pit, traceable through six or eight sections. This pit may be the thyroid gland already noticed in the preceding stage. Below the main cavity of the pharynx and close to each side of the thyroid rudiment just mentioned is a large blood-vessel (*tr*). These two vessels when traced posteriorly are found to be continuous with the anterior end of the heart, and hence may be called the truncus. They were noticed in figure 11c, *bv*. The ectoderm surrounding the lower side

of the embryo was so thin and indistinct that it could scarcely be distinguished from the mesoderm of that region. The amnion (*a*) is still a continuous envelope entirely surrounding the embryo.

Figure 12*d*, about twenty sections posterior to figure 12*c*, is in the posterior heart region. The spinal cord (*sc*), as might be expected, is smaller than in the more anterior region, but is otherwise not markedly different from what was there seen. The notochord (*nt*) also has the same appearance as before. The enteron (*ent*) shows of course in this region no gill clefts; it is a small, irregular cavity with thicker walls than in the figure just described. The ventro-lateral depression is entirely distinct from the depression that was called the thyroid rudiment in the preceding figure. Dorsal to the enteron are the two dorsal aortæ (*ao*), now smaller and more ventral to the notochord than in the preceding figure. Ventral to the enteron is the large heart (*ht*), projecting below the body cavity, which is no longer enclosed. The mesodermic wall (*mcs'*) of the heart is still comparatively thin and is separated by a considerable space from the membranous endocardium (*en'*). The extent and shape of the heart are shown in the surface view of this stage. On the right side of the section the body cavity extends to a point nearly opposite the middle of the spinal cord, considerably dorsal to the notochord, while on the left side the dorsal limit of the body cavity is scarcely level with the lower side of the notochord. Between the dorsal end of the body cavity and the side of the spinal cord, on the left, is a dense mass of mesoblast (*s*), one of the mesoblastic somites. A few sections either anterior or posterior to the one under discussion will show the condition of the two sides reversed—that is, the body cavity will extend to the greater distance on the left and will be interrupted by a mesoblastic somite on the right. It is evident, then, that the upper angle of the body cavity is extended dorsally as a series of narrow pouches between the somites. The mesoblast that lines the body cavity, the splanchnopleure (*sm*), and somatopleure (*so*) is somewhat denser than the general mass of mesoblast, so that these layers are quite distinct, the former (*sm*) extending around the enteron (*ent*) and heart (*ht*), and the latter (*so*) being carried dorsalward as the mesoblastic part of the amnion (*a*). The amnion may be traced through about 130 of the 200 sections into which this embryo was cut.

Figure 12*e* is nearly one-fourth the length of the embryo posterior to figure 12*d*; it is approximately in the middle region. The diameter of the embryo has been gradually decreasing until now it is very much less than in the head region. The section being behind the head-fold the entoderm (*en*) is nearly flat and the enteron is

quite unenclosed. The canal of the spinal cord (*sc*) is smaller in proportion to the thickness of its walls, and the notochord (*nt*) is somewhat larger than in the preceding sections. In proportion to its extent, the ectoderm is very thick. Under the notochord the dorsal aortæ (*ao*) are seen as two large, round openings in the mesoblast. On the left side the section passes through the center of a somite and shows a small, round myocoel (*myc*). The mesoblastic layer of the amnion (*sa*) is distinct throughout from the ectoblastic layer (*a*).

The most important structures to be here noted are the first rudiments of the Wolffian ducts (*wf*). They are seen in the present section as lateral ridges of mesoblast projecting outward and upward toward the ectoblast, which suddenly becomes thin as it passes over them. These ridges or cords of mesoblast are as yet quite solid. They arise suddenly at about the eightieth section of the series of two hundred and may be traced through about forty sections, or one-fifth of the length of the embryo. Their exact length is difficult to determine because, while their anterior ends are blunt and sharply defined, they taper so gradually posteriorly that it is hard to tell just where they end. They apparently originate anteriorly and gradually extend toward the tail. In a slightly younger embryo the rudimentary Wolffian duct could be seen as a still smaller rod of cells extending posteriorly for a few sections, from the seventy-fifth section of a series of about two hundred. In the particular series under discussion the left rudimentary Wolffian duct was about one-fifth longer than the right one.

Figure 12*f* is just posterior to the head-fold of the amnion, passing, in fact, on the left side through the extreme edge of its lateral fold, which is shown as an upward bend in the ectoblast and somatopleure.

The ectoblast (*ec*) shows the same remarkable thickening that was noted in the corresponding region of the preceding stage. The spinal cord (*sc*), notochord (*nt*), aortæ (*ao*), and entoderm (*en*) need no special mention. The mesoderm seems to be separated by unusually wide spaces from both ectoderm and entoderm, and is made up of rather closely packed cells except around the aortæ, where there seems scarcely enough tissue to hold these vessels in place. The body cavity (*bc*) is large, and a small myocoel (*myc*) is seen on the left.

Figure 12*g* is through the neurenteric canal (*nc*), a distinct opening through the floor of the spinal canal. The section is of course just back of the posterior end of the notochord. The entoderm (*en*) along the margin of the neurenteric canal is naturally contin-



uous with the wall of the spinal cord (*sc*). The ectoderm (*ec*) is thicker than ever, except in the median plane, where it passes over the spinal cord. The mesoblast is more abundant than in the preceding figure, and shows on the left what appears to be a distinct myocoel (*myc*), though in surface view the mesoblastic somites do not extend this far toward the tail.

## STAGE X

FIGURES 13-13g (PLATES XIV, XV, XVI)

This embryo (fig. 13) is about 5 mm. in length, and hence is slightly smaller than the preceding stage, though somewhat more advanced in development. The medullary canal is still *apparently* unclosed for a short distance at the extreme posterior end; this appearance is probably due to the neurenteric canal (*nc*) and to the thinness of the roof of the medullary canal rather than to any lack of fusion of the medullary folds. The optic vesicle is more distinct than in the preceding stage; a somewhat similar, though smaller, opacity (*o*) marks the position of the ear. There are now about twenty pairs of somites, though it is difficult to determine their exact number on account of the torsion of the body. The amnion is at about the same stage of development as in stage IX. The heart (*ht*) is a large double mass, whose outlines may be dimly seen when the embryo is viewed by transmitted light. The vitelline vessels (*vv*) are still but faintly outlined in the vascular area; the veins and arteries cannot yet be distinguished from each other. The gill clefts, though not visible externally in the embryo drawn, may be seen in sections of this stage as evaginations of the wall of the pharynx.

The transverse sections of this stage are slightly more advanced in development than was the embryo that has just been described in surface view. Only those sections have been figured which show a decided advance in the development of some special structures over their condition in the preceding stage. The sections of the preceding stages were drawn under a magnification of eighty-seven diameters; those of this and the following stage were drawn under a magnification of only forty-one diameters. All of the figures have been reduced one-half in reproduction.

Figure 13*a* is the most anterior section of this series to be described. On account of the cranial flexure, which causes the long axis of the forebrain to lie at right angles to that of the spinal cord, this section cuts the head region longitudinally. The ectoderm (*ec*)

is of varying thickness, the thickest areas being on each side of the forebrain; it is more compact than in the earlier stages, and, owing to the low magnification under which it is drawn, it is represented here by a single heavy line. Under this magnification only the nuclei of the mesoderm cells (*mes*) can be seen, so that this tissue is best represented by dots, more closely set in some places than in others. The forebrain is an elongated cavity (*fb*) with thick, dense walls. Attached to each side of the forebrain is an optic vesicle (*ov*), which is considerably larger than in the preceding stage. The connection between the cavity of the forebrain and that of the optic vesicle is not seen in this section; it is a wide passage that may be seen in several sections posterior to the one under discussion. The beginning of the invagination of the optic vesicle to form the optic cup may be seen on both sides, but more plainly on the right. On the right side also is noticed a marked thickening of the ectoderm, which is invaginated to form a small pit, the lens vesicle (*lv*); on the left side the section is just behind the lens vesicle. Above the optic stalk on each side, in the angle between the optic vesicle and the side of the forebrain, is a small blood-vessel (*br*). Several other blood-vessels may be seen at various places in the mesoblast, four of them, near the pharynx being especially noticeable. The hindbrain (*hb*) is wider than, but not so deep as, the forebrain; its walls are very thick laterally, but are thin on the dorsal and ventral sides. The dorsal wall is reduced to a mere membrane, which, with the overlying ectoderm, has been pushed into the brain cavity, as is generally the case with such embryos. Close to the ventral wall of the hindbrain the notochord (*nt*) is seen. The character of the notochord has already begun to change; the cells are becoming rounded and vacuolated, with but few visible nuclei except around the periphery of the notochord. Near the center of the section, close to the ventral end of the forebrain, is the pharynx (*ph*), cut near its anterior limit; it is here a small, irregularly rectangular cavity with a comparatively thin wall. On the left side of the pharynx the first gill cleft (*g*) is indicated as a narrow diverticulum reaching toward the ectoderm. A few sections posterior to this one the first gill cleft is widely open to the exterior. As has been said, in the surface view of this stage above described none of the gill clefts showed; so that in this respect at least the sectioned embryo was more nearly of the state of development of the embryo represented in figure 14, to be described later.

Figure 13*b*, about forty sections posterior to figure 13*a*, passes through the hindbrain in the region of the ears. Being back of the region affected by cranial flexure, this section is of course of much

less area than the preceding. The ectoderm shows no unusual features; it is of uniform thickness except where it becomes continuous with the entoderm around the mandibular folds (*md*); there it is somewhat thickened. The most striking feature of the section is the presence of two large auditory vesicles (*o*). The section being not quite at right angles to this part of the embryo, the vesicles are not cut in exactly the same plane; the one on the left is cut through its opening to the exterior, while the one on the right appears as a completely enclosed cavity. In a section a short distance posterior to this one the appearance of the vesicles would be the reverse of what it is here. As may be seen in the figure, the vesicles are large, thick-walled cavities lying close to the lateral walls of the hindbrain. The hindbrain itself has the usual triangular cross-section, with thick lateral walls and a thin, wrinkled dorsal wall. Close to the ventral side of the hindbrain lies the notochord (*nt*), on each side of which, in the angle between the brain and the auditory vesicles, is a small blood-vessel (*bv*). Ventral to these structures and close to the dorsal wall of the pharynx (*ph*) are the two large dorsal aortæ (*ao*). The ventral side of the section passes through the open anterior end of the pharynx (*ph*). On the left is seen the widely open hyomandibular cleft (*g'*), between the main body of the section and the mandibular arch (*md*). On the right side the plane of the section was such that the hyomandibular cleft was not cut through its external opening. In each mandibular fold a large aortic arch (*ar*) is seen, and also a slight condensation of mesoblast, the latter probably being the forerunner of cartilage.

Figure 13*c* passes through the anterior part of the heart about seventy-five sections posterior to figure 13*b*. The embryo in this region is narrow but deep (dorso-ventrally), the depth being largely due to the size of the heart. The ectoderm (*cc*) is considerably thickened on each side of the pharynx (*ph*); this thickened area may be traced for some distance both anteriorly and posteriorly from this point; its significance could not be determined. The spinal cord (*sc*) and notochord (*nt*) need no special description; the former is smaller and the latter larger than in the more anterior sections. The two large blood-vessels (*ac*) near the spinal cord and notochord are probably the anterior cardinal veins. The aortæ are cut by the plane of this section just anterior to their point of fusion into a single vessel. A few blood corpuscles are seen in the right aorta. The enteron (*ent*), cut posterior to the region of the gill clefts, is a large elliptical cavity, with its long axis in a transverse position. Its entodermal wall is comparatively thin and smooth, with the cell nuclei arranged chiefly on the outer side, *i. e.*,

away from the cavity of the enteron. The body cavity (*bc*) is here still unenclosed, and its walls, the somatic stalk, are cut off close to the body of the embryo. The heart (*ht*), the most conspicuous feature of this section, is nearly as large in cross-section as all the rest of the embryo. As seen in such a section it is entirely detached from the body of the embryo, and in this particular case has about the shape of the human stomach. The mesoblastic portion of its wall (*mes'*) is of very irregular thickness; it forms a dense layer entirely around the outside, except for the pointed dorsal region, and is especially thick along the ventral margin, where it is thrown into well-marked folds, the heavy muscle columns. Lining the cavity of the heart is the membranous endothelium (*en'*), and between this and the dense outer wall just described is a loose reticular tissue with but few nuclei.

As the series is followed toward the tail the sections diminish in size until, at a point about one-third the embryo length from the posterior end, they are of scarcely one-fourth the area of the sections through the region of the hindbrain.

Figure 13*d* is about one hundred and twenty-five sections posterior to figure 13*c*. Although not so small as the sections that follow it, this section is considerably smaller in area than the one last described. The amnion (*a*), which was not represented in the last three figures, is very evident here. The spinal cord (*sc*) is considerably smaller here than in the preceding figure, while the notochord (*nt*) is not only relatively but actually larger than in the more anterior regions. Beneath the notochord is the aorta (*ao*), now a single large vessel. The mesoblast on each side of the body is here differentiated into a distinct muscle plate (*mp*). These muscle plates have very much the appearance of the thickened ectoderm seen in the younger stages of development. At about its middle region (*i. e.*, at the end of the reference line *ec*) each muscle plate is separated from the overlying ectoderm by an empty space; this space is still more marked in some other series. Ventral to the aorta, and supported by a well marked though still thick mesentery (*ms*), is the intestine. It is a small, nearly cylindrical tube with thick walls; the splanchnic mesoblast which surrounds it is more dense than the general mass of mesoblast; it was somewhat torn in the section and is so represented in the figure. The urinary organs have made considerable progress since the last stage. In the figure under discussion they are seen as a group of tubules on either side of the aorta. The tubule most distant from the middle line, on each side, is the Wolffian duct (*w**d*). It extends through the posterior two-thirds of the embryo and varies in diameter at

different points; it is usually lined with a single layer of cubical cells which contain large nuclei. The Wolffian bodies (*wf*) are a mass of slightly convoluted tubules that may be traced throughout the greater part of the region through which the Wolffian duct extends. These tubules also vary somewhat in diameter, but they are usually of greater caliber than the duct. No actual nephrosomes are to be seen, though the occasional fusion of a tubule with the peritoneal epithelium, as is seen on the left side of the present figure, may represent such an opening. A detailed description of these structures may be given in a subsequent paper.

Figure 13*e* is about one hundred and forty sections posterior to the section just described. The embryo is here very slender, so that the contrast between this and the first figure (13*a*) of this stage is remarkable. Except in size, this section does not differ greatly from the preceding. The spinal cord, notochord, etc., are smaller than before, but are of about the same relative size. The mesentery (*ms*) in the section drawn was torn across, so that the intestine is not represented. Medial to the Wolffian duct is a tubule (*wf*) which seems to be the same as those which were called Wolffian tubules in the preceding stage, but which may be the beginning of the ureter.

Figure 13*f*, about two hundred and fifty sections posterior to the last, passes through the extreme posterior end of the embryo. The section is nearly circular in outline and is somewhat larger than the preceding. The amnion (*a*) completely encircles the embryo. The ectoderm (*cc*) is of fairly even thickness, and the mesoblast which it encloses is of the usual character. The spinal cord (*sc*) is nearly circular in outline, as is its central canal. The digestive tract (*ent*) is larger in section than it was in more anterior regions; it is nearly circular in cross-section and its walls are made up of several layers of cells, so that it resembles to a considerable degree the spinal cord of the same region. In the narrow space between the spinal cord and the hindgut is seen the notochord (*nt*), somewhat flattened and relatively and actually smaller than in the preceding figure. A few scattered blood-vessels may be seen in the mesoblast at various places.

A sagittal section of an embryo of this stage, drawn under the same magnification as were the transverse sections, is shown in figure 13*g*. The embryo being bent laterally could not be cut by any one plane throughout its entire length, so that only the anterior end is represented in the figure. The amnion (*a*) may be clearly seen except at certain places where it is closely adherent to

the superficial ectoderm. Under the low magnification used the superficial ectoderm cannot be distinguished from the ectoderm of the nervous system. The plane of the section being in the anterior end almost exactly median, this part of the central nervous system is seen as the usual retort-shaped cavity, while in the region back of the brain, where the neural canal is narrow, the section passes through the wall of the spinal cord (*sc*) and does not show the neural canal at all. The wall of the forebrain (*fb*) is quite thick, especially at the extreme anterior end; the wall of the midbrain (*mb*), where the marked cranial flexure takes place, is somewhat thinner, and it gradually becomes still thinner as it is followed posteriorly over the hindbrain (*hb*). Between the floors of the fore- and hindbrains, in the acute angle caused by the cranial flexure, is the anterior end of the notochord (*nt*), the only part of that structure that lies in the plane of the section. Ventral and posterior to the notochord is a large cavity, the pharynx (*ph*), whose entoblastic lining can scarcely be distinguished under this magnification from the surrounding tissues. The stomodeal opening being as yet unformed, the pharynx is closed anteriorly; posteriorly also, owing to the plane of the section, the pharynx appears to be closed, since its connection with the yolk stalk is not shown. In the floor of the pharynx, almost under the reference line *ph*, a slight depression marks the position of the first gill cleft. In the mesoblast ventral to the pharynx and near the gill cleft just mentioned, a couple of irregular openings represent the anterior end of the *bulbus arteriosus*, posterior and ventral to which is the heart (*ht*), a large, irregular cavity. The dorsal aorta (*ao*) may be seen as an elongated opening in the mesoblast, extending in this section from the middle region of the pharynx to the posterior end of the figure where it is somewhat torn. Two of the eighteen or twenty pairs of mesoblastic somites possessed by this embryo are shown at the posterior end of the figure (*s*), where the plane of the section was far enough from the median line to cut them.

## STAGE XI

### FIGURE 14 (PLATE XVI)

Only the anterior region of this embryo is shown in the figure, which is a ventro-lateral view. While there is some change in the general shape and in parts of the head, the reason for figuring this stage is to show the first gill cleft (*g'*), which lies at an acute angle to the long axis of the neck behind the eye (*e*). The cleft is narrow

but sharp and distinct in outline; it shows, neither in this nor in the following stages, the branched, Y-shaped outline mentioned by Clarke.

## STAGE XII

FIGURES 15-15f (PLATES XVI, XVII)

In this stage, also, only the anterior region of the embryo is figured in surface view. The shape of the head is about the same as in the preceding stage, but it is drawn in exact profile. Three gill clefts ( $g^{1-3}$ ) are now present, and are wide and distinct. The first cleft, as in the preceding stage, lies at an acute angle to the long axis of the pharynx and nearly at right angles to the second cleft. The third cleft sends a wide branch ( $g^4$ ) toward the posterior, as has been described by Clarke, from which, or in connection with which according to Clarke, the fourth cleft will develop. All three clefts may be distinctly seen to open entirely through the pharyngeal wall. The outlines of the visceral folds, especially of the mandibular, begin to be apparent. The nasal pit ( $n$ ) now shows as a round depression in front of the more definitely outlined eye ( $e$ ). The auditory vesicle ( $o$ ) is so deep beneath the surface that it may be seen only by transmitted light.

Figures 15*a-c* represent transverse sections of an embryo of about this general state of development, except that the gill clefts are not so definitely open as in the surface view.

Figure 15*a*, the most anterior section of the series, passes through the forebrain ( $fb$ ) in the region of the eyes, and through the hindbrain ( $hb$ ) anterior to the auditory vesicles. The forebrain is here a large cavity with a dense wall of a comparatively even thickness. Owing probably to the section not being exactly in the transverse plane, the eyes are cut in different regions, that on the left ( $ov$ ) being cut through its stalk, while that on the right ( $oc$ ) is cut near its middle region and hence does not show any connection with the forebrain. The almost complete obliteration of the cavity of the optic vesicle to form the optic cup by the invagination of the outer wall of the vesicle is shown on the right side of the section ( $oc$ ). The lens vesicle ( $lv$ ) is completely cut off from the superficial ectoderm ( $cc$ ), which is comparatively thin. The hindbrain ( $hb$ ) has the usual shape for that structure. Its ventral wall is dense and thick, while its roof is reduced to the usual thin, wrinkled membrane. Close to the floor of the hindbrain lies the notochord ( $nt$ ), which is large and is distinctly vacuolated. To the right of the hindbrain a large mass of darkly stained cells ( $cn$ ) is one of the

cranial nerves, which is connected with the hindbrain a few sections anterior to the one under consideration. The pharynx (*ph*), which is cut near its extreme anterior end, is represented by three irregular cavities near the base of the forebrain. Scattered throughout the mesoblast, which makes up the greater part of the section, are numerous blood-vessels (*bv*).

Figure 15*b* is twenty sections posterior to figure 15*a* and passes through the tip of the bent-under forebrain (*fb*). On the left the section is anterior to the optic vesicle and barely touches the side of the optic stalk, which is seen as a small lump on the ventrolateral wall of the brain. On the right the connection of the optic vesicle (*ov*) with the forebrain is shown. Dorsal to the optic vesicle just mentioned is a markedly thickened and slightly invaginated region of the ectoderm (*n*); this is the nasal pit; on the left side of the figure the thickening is shown, but the section did not pass through the invagination. The hindbrain (*hb*) is somewhat narrower than in the preceding figure, but is otherwise about the same; the origin of a cranial nerve is seen on its left side (*cn*). The notochord (*nt*) has the same appearance as in the preceding section. A number of blood-vessels may be seen, the pair lying nearest the notochord being the aortæ (*ao*), while the two other pairs, on either side of the fore- and hindbrains, are the anterior cardinals (*ac*). The first aortic arches are shown at *av*. On the left the section passes through the exterior opening of the first gill cleft (*g'*), so that the mandibular fold (*md*) on that side is a distinct circular structure, made of a dense mass of mesoderm surrounded by a rather thick ectoderm. The mesoderm of this fold is especially dense near the center, probably the beginning of the visceral bar. Near the center is also seen the aortic arch that has already been mentioned. On the right the section does not pass through the external opening of the first gill cleft (*g'*) so that the tissue of the mandibular fold is continuous with the rest of the head. It is of course the slight obliquity of the section that causes the pharynx (*ph*) to be completely enclosed on the right, while on the left it is open to the exterior both through the gill cleft and between the mandibular fold and the tip of the head. The superficial ectoderm shown here as a heavy black line varies considerably in thickness, being thickest in the region of the nasal pit already mentioned and thinnest over the roof of the hindbrain. The amnion (*a*) in this, as in the other sections of the series, has the appearance of a thin, very irregular line.

Figure 15*c* is posterior to the region affected by cranial flexure and so shows only one region of the embryo, that of the hindbrain (*hb*), which is here of essentially the same structure as above de-



scribed. On each side of the hindbrain is a large auditory vesicle (*o*); that on the left is cut through its center and shows the beginning of differentiation, its lower end being thick-walled and rounded, while its upper end is more pointed and has a thin, somewhat wrinkled wall. The notochord (*nt*) is slightly larger than in the more anterior sections. Numerous blood-vessels (*bv*, *ar*) are seen in the mesoblast. The pharynx (*ph*) is here open ventrally and also through the gill cleft of the left side; on the right side the plane of the section did not pass through the external opening of the cleft. The mesoblast of the visceral folds is much more dense than that of the dorsal region of the section.

Figure 15*d*, as is evident, is a section through the region of the heart, which appears as three irregular cavities (*ht*) with fairly thick mesoblastic walls (*mes'*) lined with endothelium (*en'*). The body wall, though consisting of but little besides the ectoderm (*ec*), completely surrounds the heart, and the pericardial or body cavity thus formed extends dorsally as a narrow space on either side of the foregut, giving the appearance of a rudimentary mesentery, though no especial development of such a structure would naturally be expected in this region of the embryo. The foregut (*ent*) is a moderately large cavity lined with a very distinct entoderm of even thickness. Dorsal to the foregut are three large blood-vessels, a median, and now single, dorsal aorta (*ao*), and a pair of cardinal veins (*cv*). The notochord (*nt*) is small and is flattened against the ventral side of the spinal cord (*sc*), which latter structure needs no special mention. The muscle plates (*mp*) are considerably elongated, so that they now extend ventrally to a point slightly below the upper angles of the body cavity.

Figure 15*e* is through the middle region of the embryo, and, owing to the curvature of the body, is not an exact dorso-ventral section; this accounts, in part at least, for the unusual diameter in a dorso-ventral direction of the aorta (*ao*), which is very large in proportion to the other structures. The posterior cardinal vein is shown on the left, but not on the right. The relative sizes of the spinal cord (*sc*) and notochord (*nt*) are very different from what was seen in the preceding figure. In this section the spinal cord is considerably smaller than in the preceding, while the notochord is very much larger; in fact the notochord here seems abnormally large when compared to corresponding sections of other series. It is true, however, that while the spinal cord has been diminishing in diameter the notochord has been increasing. The spinal cord, notochord, and dorsal aorta are all so large that they are flattened against each other, the pushing in of the ventral side of the spinal

cord being even more marked than is shown in the figure. On either side of the spinal cord a large spinal ganglion (*sg*) is seen, closely wedged in between the spinal cord and the adjacent muscle plate (*mp*). As in the preceding stage, there is a marked space between the muscle plate and the adjacent ectoderm (*ec*). The somatic mesoblast at the upper angle of the unenclosed body cavity is thickened on each side and somewhat bulged out by the Wolffian body to form what might be termed a Wolffian ridge (*wr*). In the mid-ventral line is the considerably developed mesentery (*ms*), from which the intestine has been torn. The Wolffian bodies now consist, on each side, of a group of five or six tubules (*wt*) of various sizes, near which in a more ventro-lateral position, close to the upper angle of the body cavity, is the more distinct Wolffian duct (*wd*). The allantois is fairly large by this time, and may be seen in the most posterior sections as an irregular, thick-walled out-growth from the hindgut.

A horizontal section through the anterior end of an embryo of this age is shown in figure 15*f*. While enclosed of course in the same membranous amnion (*a*), the pharyngeal region of the section is separated by a considerable space from the more anterior region where the section passes through the forebrain (*fb*) and eyes. The spinal cord (*sc*), notochord (*nt*), muscle plates (*mp*), aortæ (*ao*), and anterior cardinal veins (*ac*) need no special description. The appearance of the pharynx (*ph*), with its gill clefts and folds, is quite similar to that of the corresponding structures in the chick. None of the four clefts (*g<sup>1-4</sup>*) show, in the plane at which the section was cut, any connection with the exterior; in fact the fourth cleft (*g<sup>4</sup>*) would scarcely be recognized as a cleft if seen in this section alone. One or two of the more anterior clefts are open to the exterior. Three pairs of aortic arches are seen, and each visceral fold has a central condensation of mesoblast.

### STAGE XIII

FIGURES 16-16*g* (PLATES XVII, XVIII)

The embryo (fig. 16) now lies on one side, body torsion being complete. The curvature of the body is so marked that the exact length is difficult to determine. The eye (*e*) and ear (*o*) have about the same superficial appearance as in the preceding stage. The nose is not shown in this figure. About thirty somites are present; the exact number cannot be determined in surface view. The amnion is complete, though not shown in the figure, and the tail (*t*) is well formed. The umbilical stalk was torn in the removal

of the embryo, so that it is not shown in the figure. The dim outline of the now convoluted heart may be seen if the "cleared" embryo be viewed by transmitted light; it is not shown in the figure. The allantois (*al*) is a rounded sac of considerable size just anterior to the tail. Four gill clefts ( $g^{1-4}$ ) are now present; the most posterior one is more faint than is represented in the figure, and it could not be definitely determined from a surface view whether or not it opened to the exterior. The mandibular fold (*md*) is now fairly well outlined, but there is as yet no sign of the maxillary process.

Figure 16*a* is the most anterior of a series of transverse sections made of an embryo of the approximate age of the surface view just described; it passes through the tip of the forebrain (*fb*) and shows the nasal pit (*n*) of the right side. The great thickening of ectoderm in the region of the nasal invagination is represented by a solid line. Owing to the obliquity of the section, the left nasal pit was not cut. The mesoblast is quite dense and contains two or three small blood-vessels near the roof of the brain. The plane of this section, owing to the cranial and body flexure, cut the embryo also in the region of the pharynx; this part of the section was, as a matter of convenience, omitted from the drawing.

Figure 16*b* is in reality more anterior in position considering the entire embryo, than the preceding; but the region of the embryo represented is most posterior, so that it is described at this point. The greatly elongated outline of the brain is due to its being cut through the region of flexure, so that the forebrain (*fb*) or, perhaps, midbrain, is shown at one end and the hindbrain (*hb*) at the other. The walls of these cavities are somewhat wrinkled and irregular and their constituent cells are beginning to show slight differentiation, though this is not shown in the figure. On the left side are seen a couple of darkly stained masses; one is the origin of a cranial nerve (*cn*); and the other is one of the auditory vesicles (*o*), which is still more irregular in outline than it was in the preceding stage. The only blood-vessels to be seen are a few very small ones that lie close to the wall of the brain. The ectoderm is quite thin at all points.

Figure 16*c*, the largest section of this series, passes through the forebrain in the region of the eyes and through the gill clefts. The forebrain (*fb*) exhibits on the left a marked thickening of its wall (*ch*), the edge of the cerebral hemisphere of that side, which is just beginning to develop; on its right side the lower part of the forebrain is connected by a well-marked optic stalk (*os*) with the optic

cup (*oc*), in whose opening lies the lens vesicle (*lv*), now reduced to a crescentic slit by the thickening of its posterior wall. The mesoblast is more dense in those parts of the section adjacent to the pharynx than in the more distant regions, and the ectoderm thickens in a marked way as it approaches the borders of the pharynx and gill clefts. Only a few small blood-vessels (*bv*) are to be seen in the region of the forebrain.

Parts of three pairs of clefts (*g*) are shown in the figure: one pair opens widely on either side, so that there is a large area of the section that is distinct from the two still larger portions and contains a small, thick-walled cavity (*g*) on the right side; this cavity is a gill cleft that is cut through neither its outer nor its pharyngeal opening.

No structures other than this small portion of a gill cleft and a few blood-vessels are to be seen in this middle region of the section. In the more posterior part of the section, in which the notochord (*nt*) is located, a pair of curved clefts may be seen, opening entirely through the wall on the left, but closed on the right (*g*). One distinct pair of aortic arches is shown (*ar*), and also the dorsal aortæ (*ao*), which are of very unequal size. The spinal cord (*sc*) and muscle plates need no special description.

Figure 16*d* is in the region of the heart (*ht*) and lungs (*lu*). The former is an irregular cavity whose walls, especially on the ventral side (*mes'*) are becoming very thick and much folded. Although thin, the body wall completely surrounds the heart, as would be expected, since this was true of the preceding stage. The lung rudiments (*lu*) and the foregut from which they have arisen have the same appearance as in the chick; they consist of three small, thick-walled tubes so arranged as to form a nearly equilateral triangle. They are surrounded by a swollen, rounded mass of mesoblast which almost completely fills the surrounding portion of the body cavity (*bc*). The pleural sides of these crescentic portions of the body (or pleural) cavity—that is, the boundary of the mass of mesoblast just mentioned—is lined with a thickened layer of cells, shown by the solid black lines in the figure. The lung rudiments may be traced through about fifty sections of this series, or about one-twelfth of the entire series. At the dorsal angle of the part of the body cavity (*bc*) just described; near the dorsal aorta (*ao*), are two dark, granular masses (*ge*), which, under a higher magnification than is here used, are seen to consist of a small group of blood-vessels filled with corpuscles; although several sections in front of the anterior limits of the kidneys, these are evidently glomeruli. They may be traced, though diminishing in size, far toward the

tail, in close connection with the Wolffian bodies. At intervals they are connected by narrow channels with the dorsal aorta; no such connection was present in the section drawn. The notochord (*nt*), spinal cord (*sc*), muscle plates (*mp*), and spinal ganglia (*sg*) need no special mention. The mesoblast is beginning to condense in the neighborhood of the notochord, and the ectoderm is slightly thickened laterally and dorsally.

Figure 16*e* is in the region of the liver and the Wolffian bodies; it also shows the tip of the ventricular end of the heart. The liver (*li*) is a large irregular mass, of a blotchy appearance under this magnification, lying between the heart (*vn*) and the intestine (*i*). Under greater magnification it is seen to be made up of indefinite strings of cells; and its still wide opening into the intestine may be seen in more posterior sections. The intestine (*i*), which in this section might be called the stomach, is a fairly large cavity with the usual thick entodermic walls; it is supported by a comparatively narrow mesentery. The body cavity on the side next this mesentery has the same thick lining that was noted in the region of the lungs. The convolutions of the thick peritoneal lining may easily be mistaken in places for parts of the enteron. The Wolffian bodies may be seen as two groups of tubules (*wt*) in their usual location. The heart is cut through the ventricle (*vn*), as has been said. The section being at right angles to the long axes of the villi-like growths of the myocardium, the depressions between these mesoblastic cords are seen as a number of small irregular areas, each one lined with its endocardium. The incompleteness of the body wall below the heart is apparently due to an artificial break and not to a lack of fusion. The only point that need be mentioned in connection with the structures of the dorsal part of the section is that the distinctness of the myocoel (*myc*) on the right side is somewhat exaggerated.

Figure 16*f* is in the middle region of the embryo, where both spanchnopleure and somatopleure are unfused. Owing chiefly to the unclosed condition of the midgut (*i*) and to the increase in length of the mesentery (*ms*), the section is quite deep dorso-ventrally. The continuation of the amnion (*a*) with the somatopleure is of course here evident.

The most striking feature of the section is the marked projection of the Wolffian ridges, though no local enlargements of these ridges indicate the rudiments of the limbs. A large mass of Wolffian tubules (*wt*) is seen projecting into the upper part of the body cavity on each side; close to each of these masses is the posterior cardinal vein (*pc*), and between them is the large aorta (*ao*). The other structures are about as in the preceding section.

Figure 16g represents a sagittal section of the anterior half of the body of an embryo of this or possibly a slightly younger stage of development. The three regions of the brain are clearly indicated, as well as the cavity of the spinal cord (*sc*). The roof of the hindbrain has been made too thick in the figure; it should be represented by a mere line. A little mesoblast is to be seen at places between the roof of the brain and the superficial ectoderm. A slight invagination of the epithelium (*p*), between the floor of the brain and the anterior end of the notochord, probably represents the beginning of the hypophysis. No indication of the pineal body is yet to be seen. Extending from the region of the hypophysis to the posterior end of the section is the notochord (*nt*); it is much vacuolated and gradually increases in thickness toward the posterior, though its outline is quite irregular; except at the extreme anterior end and at one or two other places, it lies in close contact with the floor of the neural tube. Directly under the notochord lies, in the posterior half of the figure, the large dorsal aorta (*ao*). The pharynx (*ph*), opening between the end of the forebrain and the thick mandibular fold (across which opening the amnion (*a*) of course extends), is a funnel-shaped space which passes out of the plane of the section toward the posterior end of the figure. Its thick endodermal lining extends to the mandibular fold on the ventral side, while on the dorsal side it gradually thins out and becomes continuous with the thin ectoderm that extends over the forebrain. Just back of the mandibular fold is the bulbus (*b*), and back of that is the edge of the ventricle (*vn*). Posterior and dorsal to the ventricle the liver (*li*) is seen as an irregular mass of cells, and dorsal to the liver one of the Wolffian bodies (*wt*) is cut through its extreme edge.

#### STAGE XIV

FIGURES 17-17g (PLATES XVIII, XIX)

Body flexure has increased until now the forebrain and tail are almost in contact (fig. 17). The eye has developed somewhat; the ear vesicle, which is not shown in the figure, is small and seems to lie nearer the ventral side; the nasal pit is much larger and is crescentic in shape. The hyomandibular cleft (*g'*) still persists as a small crescentic slit, while the next three clefts are now represented merely by superficial grooves separated by distinct ridges, the visceral folds. No indication of a fifth cleft is seen. The maxillary process (*m.r*) grows ventralward under the forebrain and is already longer than the mandibular arch (*md*).

The chief advance in development over the preceding stage, be-

sides the formation of the maxillary process, is in the appearance of the appendages (*aa* and *pa*); they have the characteristic shape of the rudimentary vertebrate appendage, though the anterior pair seem to point in an unusual direction at this stage and to be slightly more developed than the posterior. The curious, anteriorly directed heart (*ht*) is, perhaps, somewhat abnormal. The umbilical stalk (*u*) is comparatively narrow and, like the allantois, was cut off close to the body.

Transverse sections of an embryo of this stage are represented in figures 17*a-g*, drawn under a lower magnification than were any of the preceding figures.

Figure 17*a* is in the region of the pharynx, and passes through the forebrain (*fb*) and posterior part of the hindbrain (*hb*). In the thick walls of both of these structures histological differentiation has begun, so that even under low power an inner granular and an outer clear zone may be distinguished. Under greater magnification the presence of short fibers may be made out among the cells. The cerebral hemispheres (*ch*) are well-marked structures, their asymmetry being of course due to the obliquity of the section. Only one eye is cut by the plane of the section, and this one shows no connection with the forebrain. The outer wall of the optic cup (*oc*) is so thin that under this magnification it can scarcely be seen as a dark line surrounding the retinal wall. The lens (*ln*) is now a solid mass, of the usual type for vertebrate embryos, its front or outer wall being a scarcely discernible line. The hindbrain (*hb*) has the usual form for that region and does not differ particularly from what was noted in earlier stages except in the histological differentiation that has already been mentioned. As with the eye, it is only on the right side that the auditory vesicle (*o*) is shown. It shows some differentiation, but not so much as would be seen were it cut in another region. In the center of the section the pharynx (*ph*) forms an irregular cavity connected with the exterior on the left by a gill cleft (*g*) and by another slit which is simply the anterior margin of the stomodaeum. On the right neither of these openings are in the plane of the figure, though the gill cleft (hyomandibular), which lies close to the auditory vesicle, is almost an open passage. A few small blood-vessels are scattered through the section; one of these (*bv*), lying between the notochord (*nt*) and the floor of the brain, is noticeable from its being very closely packed with corpuscles, so that at first glance, under low magnification, it looks more like a nerve than a blood-vessel.

Figure 17*b* is also through the pharyngeal region, a short distance behind the preceding section. The growth of the cerebral hemi-

spheres (*ch*) is better shown than in the preceding figure, as is also the general form of the optic cup (*oc*). On the left the nasal cavity (*n*) is seen as an elongated slit with thick walls; it is cut near, but not through, its opening to the exterior. The same gill cleft (*g*) that was seen in the preceding figure is seen here as a narrow, transverse cleft, open at both ends. Between the notochord (*nt*) and the spinal cord (*sc*) is the same, though now double, blood-filled vessel (*bv*) that was seen in the preceding section. The other blood-vessels are larger here than in the more anterior region. There is a faint condensation of mesoblast in the neighborhood of the notochord, and a more marked condensation (*mp*) farther toward each side is the curiously shaped muscle plate.

Figure 17*c* is through the heart region, and that organ is cut through the opening from the lower or ventricular into the upper or auricular chamber. The thickening of the wall of the ventricle, which was noticed in the preceding stage, has increased to such an extent that there is now a marked difference in the thickness of the ventricular and auricular walls. As in the preceding stage, the body wall is torn, probably in handling, so that it appears to be incomplete around the ventral side of the heart. Dorsal to the heart two small circular holes (*ent*) with thick walls are the œsophagus and trachea, cut anterior to the point of bifurcation of the latter into the bronchial or lung rudiments. On either side of these structures is an elongated blood-vessel (*ac*), the anterior cardinal vein, its elongation being due to the fact that it is cut at the place where it turns downward to empty into the heart. Dorsal to the œsophagus are the aortæ (*ao*), which are here cut just at the point where the two vessels unite to form one; the next section, posterior to the one under discussion, shows an unpaired aorta. The notochord (*nt*) and spinal cord (*sc*) need no description, except to note that the latter shows active histological differentiation, numerous mitotic figures being seen under higher magnification, especially in the cells that line the spinal canal. On the right of the cord the edge of a spinal ganglion (*sg*) is seen, in connection with which in other sections are seen the clearly defined nerve roots. The condensation of mesoblast around the notochord is quite evident, and in close contact with this medial condensation are two very characteristic, S-shaped muscle plates (*mp*), which extend from the level of the dorsal side of the spinal cord to the upper limits of the cardinal veins. In some sections the muscle plates even yet show slight remains of the myocoel at the dorsal end.

Figure 17*d* is in the region of the posterior end of the heart (*ht*), which is cut through the tip of the ventricle, and the anterior end of



the liver (*li*), which has the appearance of a mass of darkly stained cords or strands of cells surrounding a large blood-vessel (*mv*). This blood-vessel may be called the *meatus venosus*, though it is not separated by any line of demarcation from the auricle. A few sections anterior to this region the *meatus venosus* opens dorsally into a large vessel on each side (*dc*), which at first glance seems a part of the body cavity, but which is in reality the *ductus Cuvieri*, formed by the union of the anterior and posterior cardinal veins. An irregular, crescentic cleft (*bc*), lying medial and parallel to each of the Cuvierian vessels, is the body cavity. In the upper angle of this cavity is a granular mass, the glomerulus, that of the left side being accompanied by the extreme anterior end of the Wolffian duct. In the rounded mass of mesoblast, between the cleft-like regions of the body cavity, the lung rudiments (*lu*) and the œsophagus (*oc*) are seen as three small, circular openings; that of the œsophagus is somewhat smaller than the other two. The notochord (*nt*), spinal cord (*sc*), and muscle plates (*mp*) have almost the same appearance as in the preceding section. A spinal ganglion (*sg*) is seen on each side of the spinal cord; the one on the left shows a well-defined spinal nerve (*sn*), which may be traced ventrally as far as the end of the muscle plate, along whose medial side it courses. The ventral nerve root is plainly seen; the dorsal root, in this section, less plainly. The amnion (*a*) and abdominal wall are, as in the preceding figure, torn in the region of the ventricle.

Figure 17*e* is a short distance posterior to the figure just described. The liver is cut through its middle region and forms a large, darkly staining, reticular mass on the left side of the figure. The digestive tract is seen at two places to the right of the liver; the smaller and more ventral of these openings (*i*) may be called the intestine, while the larger is evidently the stomach (*i'*). The body wall is here unfused and becomes suddenly thinner as it passes upward into the amnion (*a*). The Wolffian tubules (*wt*) form a very conspicuous mass on either side of the mesentery, in close connection with the posterior cardinal veins (*pc*). In the mesoblast between the dorsal aorta (*ao*) and the notochord are two small, irregular, darkly stained masses (*sy*). These are shown in the preceding two figures, but were not mentioned in the description. They may be traced through a great part of the length of the embryo back of the head region; at intervals corresponding in length to the distance between the spinal ganglia they are enlarged, while between these enlargements they are very small in cross-section. At certain points a small blood-vessel is given off by the dorsal aorta to the immediate neighborhood of each of these small areas. Although

they show no connection with the central nervous system, these structures appear to be the rudiments of the sympathetic nerves.

Figure 17*f* is in the region just in front of the hind legs. The abdominal walls are here unfused, and into the unenclosed body cavity projects the intestine (*i*), supported by a narrow mesentery and surrounded by a comparatively thick mass of mesoblast. The Wolffian body and duct form a mass of considerable size on each side of the mesentery. The Wolffian body is cut near its posterior end and consists of smaller tubules than in the more anterior regions. The Wolffian ducts (*w<sub>d</sub>*), on the other hand, are very large and are much more clearly distinguishable from the Wolffian tubules than in the preceding sections. The Wolffian ridges (*w<sub>r</sub>*) are very marked projections on the sides of the body, and in a region further caudad become especially developed as the posterior appendages, to be described in connection with the following section. Both spinal ganglia are shown in this figure (*sg*), and in connection with the left ganglion the spinal nerve (*sn*), extending ventrally as far as the level of the Wolffian duct. The sympathetic nerve rudiments do not extend so far caudad as the plane of this section. The dorsal end of each muscle plate (*mp*) is seen, in this and other sections, to be slightly enlarged to form a round knob; this knob contains a distinct cavity (not shown in the figure), the myocoel.

In figure 17*g*, owing to the curvature of the body, the plane of the section passes through the body at three places: through the region of the heart and lungs (fig. 17*d*), through the region of the posterior appendages, and through the tail. In fact, the plane of the section represented by each of the preceding figures cut the embryo in more than one region, but for the sake of simplicity only one region was represented in each figure. In the figure under discussion only the leg and tail regions have been drawn, though the latter region (*t*), being cut through one of its curves, is seen as an elongated body with a section of the spinal cord, notochord, etc., at each end. Both regions shown in the figure are enclosed in the same fold (*a*) of the amnion. Of the structures in the dorsal side of the larger or more anterior part of this figure nothing need be said. The most striking feature of the section is the presence of the large posterior leg rudiments (*pa*). As was noted in the preceding figure, they are, as usual, merely local enlargements or projections of the mesoblast (covered, of course, with ectoblast) of the Wolffian ridge. They are, as shown in this section and in the surface view of this stage (fig. 17), bluntly pointed projections from the sides of the body. The anterior appendage seems to be slightly more developed than the posterior, as was noted in describing the surface view of the

embryo. The digestive tract is cut through its extreme posterior end, in the region that may be termed the cloaca (*cl*), for into it at this point the Wolffian ducts open (*wdo*). As the narrow cloacal chamber is followed toward the tail, it becomes still smaller in diameter, and the ventral depression or cleft seen in this figure gradually becomes deeper until its walls are continuous with the ectoderm that covers the ventral projection of mesoderm between the hind legs; no actual opening to the exterior is present, however. There is a space of about twenty-five or thirty sections (in a series of eight hundred) between the posterior ends of the Wolffian bodies and the cloacal openings of the Wolffian ducts. The body cavity (*bc*) and the posterior cardinal veins (*pc*) are very small in this region, as might be expected.

#### STAGE XV

##### FIGURE 18 (PLATE XIX)

Only the head of this embryo is represented, as the general state of development is about the same as in the preceding stage.

The chief object in making the figure is to show the five gill clefts ( $g^{1-5}$ ). The fifth cleft, though small and probably not open to the exterior, is quite distinct in this embryo. The writer would feel more doubt of its being a true, though rudimentary, gill cleft had not Clarke (5) found a fifth pair of clefts in his material. The nasal pit has advanced in development somewhat and shows the beginning of the groove that connects it with the mouth. In this figure the crescentic hyomandibular cleft shows its connection with the groove between the mandibular and the hyoid folds.

#### STAGE XVI

##### FIGURE 19 (PLATE XIX)

This embryo is only slightly more developed than the preceding. Body flexure is so great that the forebrain and tail nearly touch. Only the anterior three gill clefts are visible. The maxillary process (*mx*) is longer and more narrow; the mandibular fold has not changed appreciably. The nasal pit (*n*) is now connected by a distinct groove with the stomodaeum. The appendages have increased in size, the posterior (*pa*) being the longer. The anterior appendage (*aa*) is distinctly broadened to form the manus, while no sign of the pes is to be seen at the extremity of the posterior appendage. The heart (*ht*) is still very prominent. The stalk of the umbilicus (*u*), which is quite narrow, projects from the ventral wall in the region between the heart and the hind legs. The tail is of considerable length and is closely coiled.

## STAGE XVII

FIGURES 20-20j (PLATES XX, XXI)

The superficial changes noted in this stage chiefly concern the head, which has increased considerably in length (fig. 20). The curvature of the body is slightly more marked, and the tail is more tightly coiled at the end. There are still signs of three gill clefts. The maxillary process (*mx*) is long and narrow, while the mandibular arch (*md*) is still short and broad. The fronto-nasal region has greatly increased and has the acquiline profile noted by Clarke. The nasal groove has disappeared, and there remains the small opening (*n*) at the side of the fronto-nasal region, near the end of the still separate maxillary process. The umbilicus is in about the same condition as in the preceding stage, but the heart is less prominent. The outline of the manus (*ma*) is more definite, and the extremity of the posterior appendage is distinctly flattened out to form the rudimentary pes (*pc*). The position of the elbow-joint in the anterior appendage is seen at the end of the reference line *aa*.

Typical transverse sections of this stage are shown in figures 20a-j.

Figure 20a is a section through the middle region of the head, cutting the hindbrain on one side and the forebrain on the other. The walls of the brain show rather more histological differentiation than was seen in the preceding sections, though this cannot be shown under the low magnification used. The hindbrain (*hb*), which is cut near its anterior border, exhibits the usual membranous dorsal and thick ventral walls. The forebrain is here seen as three distinct cavities—a median third ventricle (*tv*), with a thick ventral wall, and a thin dorsal wall extended to form a large pineal body (*epi*), and two lateral ventricles (*ch*), the cavities of the cerebral hemispheres, whose walls are quite thick except on the side next the third ventricle. The sections of this series being slightly oblique, the eye is here cut on the right side only, where it is seen as a large, semicircular cavity (*e*) with thick, dense walls. The mesoblast, in which several blood-vessels (*bv*) are seen, exhibits three distinct areas—a median, lighter zone, with a more dense area on either side. The significance of this variation in the density of the mesoblast is not apparent.

Figure 20b is only a few sections posterior to the section just described. It is drawn chiefly to show the appearance of the forebrain, the other structures being about as in the preceding figure, except that both eyes (*e*) are here represented. The section passes through the wide opening between the third (*tv*) and the lateral

ventricles (*ch*) and cuts the anterior edge of the pineal body (*cp*). The pineal body is very large and is directed backward instead of forward, as is usually the case among the lower vertebrates (if the alligator may be so classed). It is shown in figure 17*a* of a preceding stage and will be again shown in a sagittal section to be described later. The same areas of more dense and less dense mesoblast noted in the preceding figure are seen here.

Figure 20*c*, though still in the head region, shows several features that were not seen in the preceding figures. On the left of the hind-brain (*hb*) the auditory vesicle (*o*), which is now considerably more advanced than in earlier figures, is seen as a larger, flask-shaped cavity and a smaller, round one. Between the larger cavity and the hindbrain is the root of a cranial nerve (*cn*), apparently the eighth, since in another section it comes in close contact with the wall of the larger part of the auditory vesicle just mentioned. On the right side, ventral to the hindbrain, another and much larger nerve (*cn*) is seen. Nearly in the center of the figure is seen a small, irregular, thick-walled cavity (*p*), this is the pituitary body, and its connection with the roof of the pharynx may easily be made out in another section. The mesoblast in this region of the sections contains numerous large and small blood-vessels and exhibits certain denser areas which probably represent the beginnings of the cranial cartilages. No sign of the forebrain is seen (the plane of the section passing in front of that region), except that the tip of the wall of one of the cerebral hemispheres (*ch*) is cut. The left nasal chamber (*n*) is shown: it will be noted again in the following section. The eye on the right side shows no remarkable features; its lens (*ln*) is large and lies well back of the lips of the optic cup, which may now be called the iris (*ir*). A thin layer of mesoblast has pushed in between the lens and the superficial ectoderm to form the cornea, and the outer wall of the optic cup is now distinctly pigmented. The inner wall of the optic cup is beginning to differentiate into the retinal elements. The eye on the left side is cut farther from its central region and has a very different appearance from the eye just described. This unusual appearance is due to the fact that the section passed through the choroid fissure, which is very large and seems to be formed by the pushing in of the walls of the cup and not by a mere cleft in these walls. This fissure is hardly noticeable in the stage preceding the present, and in a stage slightly older it has disappeared; so that it would seem to be a very transient structure. It apparently is formed at about the time that the optic stalk, as such, disappears. It is in the region of the choroid fissure, if not through it, that the optic nerve (*on*) enters the eye. Through the

fissure also enters a vascular tuft of mesoblast (*pt*) which may be seen projecting into the optic cup after the disappearance of the fissure. This loop of blood-vessels is doubtless the pecten.

Figure 20*d* represents a section through the hindbrain (*hb*), pharynx (*ph*), and tip of the snout. On either side of the hindbrain are a convoluted auditory vesicle (*o*), and several blood-vessels and nerves, while ventral to it is seen the anterior end of the notochord (*nt*), around which the mesoblast is somewhat more dense than elsewhere. The pharynx (*ph*) sends out toward the surface a narrow gill cleft (*g'*) in the neighborhood of each auditory vesicle. These clefts connect with the exterior by very narrow slits, not seen in the plane of this section. The opposite end of the pharynx, as seen in this figure, opens on the left (*pn*) into the nasal chamber. The nasal cavity on the right is cut in such a plane that it shows neither its external nor its pharyngeal opening. The nasal passages are here fairly long and nearly straight chambers; their lining epithelium is quite thick in the middle region, but becomes thinner where it merges into the epithelium of the pharynx at one end, and into the superficial epithelium at the other end. The unusual appearance of the eye (*e*), on the right side of the figure, is due to the fact that the plane of the section cut tangentially through the extreme edge of the eye in the region of the choroid fissure.

Figure 20*e* is only a short distance posterior to the preceding. On the left side the pharynx (*ph*) is connected with the exterior through the stomodeum, and on the right the hyomandibular cleft (*g'*) is cut almost through its opening to the exterior. The auditory vesicle (*o*) on the right is cut near its middle region, while that on the left is barely touched by the plane of the section. The notochord (*nt*), with its condensed area of mesoblast, is somewhat larger than in the preceding section. The nasal canal on the right (*n*) is cut through neither anterior nor posterior opening, while on the left side the canal shows the anterior opening (*an*).

Figure 20*f*, which is in the region of the posterior part of the pharynx and the anterior part of the heart, shows some rather unusual conditions.

The spinal cord (*sc*) and notochord (*nt*), with the faintly outlined condensations of mesoblast in their region, need no special description. The pharynx (*ph*) is here reduced to an irregular, transversely elongated cavity, the lateral angles of which are connected on each side with the exterior through a tortuous and almost closed gill cleft (*g*), which must be followed through many sections before its inner and outer openings may be determined. Dorsal to the pharynx numerous blood-vessels (*bv*), both large and small, may

be seen, while ventral to it is noticed a faint condensation of mesoblast (*la*), in the form of an inverted 'T', the anlage of the laryngeal structures. The ventral portion of the figure is made up of a nearly circular, thin-walled cavity, the pericardium (*pr*). Most of the pericardial cavity is occupied in this section by the thick-walled ventricle (*vn*), above which is the bulbus (*b*) and the tip of the auricle (*au*). The bulbus is nearly circular in outline, though its cavity is very irregular. A few sections anterior to this, the opening of the bulbus into the ventricle is seen.

In figure 20*g* the section represented is only a short distance posterior to the one represented by figure 20*f*. The mesoblastic structures in the neighborhood of the spinal cord (*sc*) and notochord (*nt*) will be described in connection with the next figure, where they are more clearly defined. The œsophagus (*oe*)—or posterior end of the pharynx, whichever it may be called—is here a crescentic slit, with its convex side upward; ventrally it opens by a narrow glottis into the trachea (*ta*). The trachea is surrounded by the same condensed area of mesoblast (*la*) that was mentioned in connection with the preceding figure, but the condensation is here more marked. From the bulbus (*b*) an aortic arch (*ar*) extends upward for a short distance on the right side, while to the left of the œsophagus an aortic arch (*ar*) is cut through the upper part of its course. Ventral to the bulbus the ventricle (*vn*) and two auricles (*au*) are seen surrounded by the pericardial wall.

Figure 20*h* is in the region of the liver (*li*), which has about the same position in relation to the auricles (*au*) that was occupied by the ventricle in the last figure. The auricles are connected with each other by a wide passage. The trachea (*ta*) and the œsophagus (*oe*) are entirely distinct from each other; the former is a small, nearly circular hole, while the lumen of the latter is obliterated and its walls form a solid, bow-shaped mass of cells. Since there is a narrow space between this mass of cells and the surrounding mesoblast, it might be thought that the lumen of the œsophagus had been closed by the simple shrinkage of its walls; higher magnification, however, fails to show any sign of a collapsed lumen. It is doubtless the problematic and temporary closure of the œsophagus that is noticed in other forms. On each side of the œsophagus, in close relation with the anterior cardinal vein (*ac*), is noticed a nerve (*cn*) cut through a ganglionic enlargement. When traced forward these nerves are seen to arise from the region of the medulla, and when followed caudad they are found to be distributed chiefly to the tissues surrounding the newly formed bronchi; they are doubtless the tenth cranial nerves. On the right side of the figure the close

connection of this nerve with the near-by gill cleft is seen. Above the paired aortæ (*ao*) the sympathetic nerves (*sy*) will be noticed. The mesoblast surrounding the spinal cord (*sc*) and notochord (*nt*) is distinctly condensed (more so than the figure shows) to form what may be called the centrum (*c*) and neural arch (*na*) of the vertebræ. The arch, owing to the slight obliquity of the section, shows here only on one side. The spinal cord is not yet completely enclosed by the neural arches. The muscle plates (*mp*) are in close connection with the rudiments of the vertebræ just mentioned. The spinal cord (*sc*) is here differentiated into three areas—a dense, deeply stained area immediately around the neurocoel; a less dense area of cells surrounding the inner area and extending ventralward as a rounded projection on each side; and an outer layer, with few or no nuclei, surrounding the inner two layers except on the dorsal side.

In figure 20*i* the size and complexity of the figure are due, it will be easily understood, to the fact that the plane of the section passed through the curve of the body, thus practically cutting the embryo in two regions—an anterior, where the lungs (*lu*) and liver (*li*) are seen, and a posterior, where the Wolffian bodies (*wt*) are present. The spinal cord and the surrounding structures have almost the same characteristics at both ends of the figure, except that the primitive spinal column is rather more distinct in the posterior end of the section. The posterior cardinal veins (*pc*), Wolffian ducts (*wd*), and Wolffian bodies (*wt*) are also prominent structures of this end of the figure, the last being made up of a great number of tubules. The extreme anterior ends of the Wolffian bodies are seen in the other half of the section in the upper angles of the body cavity, dorsal to the lung rudiments (*lu*). Filling most of the body cavity (*bc*) and making up the greater part of the middle of the figure are the liver (*li*), now a very large organ; the stomach (*i'*), also quite large; the pancreas (*pan*), a small body lying near the stomach; and the lungs (*lu*), which here consist of several thick-walled tubes, surrounded by lobes of mesoblast. The other features of the figure need no special mention.

Figure 20*j* is through the base of the posterior appendages (*pa*), in which the cartilages are already being outlined by condensations of mesoblast. The intestine (*i*) is cut in two regions—at a more anterior point, where it is seen as a small, circular hole surrounded by mesoblast and hung by a narrow mesentery, and through the cloacal region, the larger and more ventral cavity, into which the Wolffian ducts (*wd*) open a short distance caudad to this section. The blood-vessels present a rather curious appearance. A short



distance anterior to this point the aorta has divided into three, or it might be said that it has given off two, large branches. These two branches, one on either side near the posterior cardinal vein, pass toward the ventral side of the embryo on each side of the cloaca and end at about the region represented by the present figure. The small portion of the aorta that remains after the giving off of the two branches just described continues, as the caudal artery (*ca*), into the tail; it is a small vessel just under the notochord, and gives off small, paired branches at regular intervals toward the vertebral region. The posterior cardinal veins (*pc*), posterior to the openings of the Wolffian ducts into the cloaca, unite to form a large caudal vein lying just ventral to the caudal artery.

### STAGE XVIII

FIGURE 21 (PLATE XXII)

This embryo, as may be seen, for example, by the form of the appendages, is slightly further developed than the one represented in figure 20. The figure is from a photograph of a living embryo as it lay in the egg, a portion of the shell and shell membranes having been removed. The embryo, which lies on its left side, is rather faintly outlined because of the overlying allantois. The allantois has been increasing rapidly in size, and is here so large that it extends beneath the cut edges of the shell at all points except in the region in front of the head of the embryo, where its border may be seen. Its blood-vessels, especially the one that crosses the head just back of the eye, are clearly shown in the figure, and in the living specimen, when filled with the bright red blood, they form a most beautiful demonstration. As in the chick, the allantois lies close beneath the shell membranes and is easily torn in removing them.

### STAGE XIX

FIGURE 22 (PLATE XXII)

Figure 22 is a photograph of a somewhat older embryo, removed from the egg and freed of the foetal membranes. The appendages show the position of both elbow and knee joints, and in the paddle-shaped manus and pes the digits may be faintly seen. The tail is very long and is spirally coiled, the outer spiral being in contact with the frontal region of the head. The jaws are completely formed, the upper projecting far beyond the lower. The elliptical outline of the eyes is noticeable, but the lids are still too little developed to be seen in this figure. The surface of the embryo is still smooth and white.

## STAGE XX

FIGURES 23-23*b* (PLATE XXII)

In this surface view (fig. 23) several changes are seen, though no very great advance in development has taken place. The outlines of the digits (five in the manus and four in the pes) are now well defined; they even project slightly beyond the general outline of the paddle-shaped part. The tail has begun to straighten out, and it now extends across the front of the face. The lower jaw has increased in length, but is still shorter than the upper. The eyelids, especially the upper, are beginning to be discernible in surface view. Though still without pigment, the surface of the body is beginning to show by faint transverse lines the development of scales; these lines are most evident in this figure in the middle region of the tail, just before it crosses the nose.

A sagittal section of the entire embryo (except the tail) of this age is shown in figure 23*a*. In the head region the section is nearly median, while the posterior part of the body is cut slightly to one side of the middle line. At the tip of the now well-developed snout is seen one of the nostrils (*an*), cut through the edge; its connection with the complicated nasal chamber (*n*) is not here seen, nor is the connection of the nasal chamber with the posterior nares (*pn*). The pharynx (*ph*) is anteriorly connected with the exterior through the mouth (*m*) and the nares, while posteriorly it opens into the œsophagus (*œ*); the trachea (*ta*), though distinct from the œsophagus, does not yet open into the pharynx. In the lower jaw two masses of cartilage are seen, one near the symphysis (*mk*) and one near the wall of the trachea, doubtless the rudiment of the hyoid. The deep groove back of the Meckel's cartilage (*mk*) marks the tip of the developing tongue, which here forms the thick mass on the floor of the mouth cavity. Dorsal to the pharynx a mass of cartilage (*se*) is developing in the sphen-ethmoid region. This being a median section, the ventricles of the fore- (*fb*), mid- (*mb*), and hindbrain (*hb*) are seen as large cavities, while the cerebral hemispheres (*ch*) appear nearly solid, only a small portion of a lateral ventricle showing. The pineal gland (*epi*) is cut a little to one side of the middle and so does not show its connection with the brain. At the base of the brain the infundibulum (*in*) is seen as an elongated cavity whose ventral wall is in close contact with a group of small, darkly staining alveoli (*p*), the pituitary body. Extending posteriorly from the pituitary body is a gradually thickening mass of cartilage (*bp*), which surrounds the anterior end of the notochord (*nt*) and may be called the basilar plate. In its anterior region, where the section is

nearly median, the spinal column shows its canal, with the enclosed spinal cord, while toward the posterior end of the figure the vertebræ are cut to one side of the middle line, and hence show the neural arches (*na*) with the alternating spinal ganglia (*sg*). Near the posterior end of the figure the pelvic girdle (*pl*) is seen. The largest organ of the embryo, as seen in this section, is the heart, of which the ventricle (*vn*) seems to be closely surrounded, both in front and behind, by the auricles (*au*). The liver (*li*) is the large, reticular mass back of the heart. Dorsal and anterior to the liver is the lung (*lu*), now of considerable size and development. The enteron is cut in several places (*oc*, *i*) and its walls are beginning to show some differentiation, though this cannot be seen under the magnification here used. One of the Wolffian bodies is seen as a huge mass of tubules (*wt*) extending from the pelvic region, where the mass is greatest, to the region of the lungs. The Wolffian tubules stain darkly and the whole structure forms a very striking feature of the section. Dorsal to the posterior end of the Wolffian body is a small, oval mass of very fine tubules (*k*), which do not stain so darkly as do the Wolffian tubules; this mass is apparently the beginning of the permanent kidney, the metanephros. Its tubules, though their origin has not been determined, seem to be entirely distinct from the tubules of the Wolffian body.

A single vertical section through the anterior part of the head of an embryo of this age has been represented in figure 23*b*. On the right side the plane of the section cut through the lens of the eye (*ln*); on the left side the section was anterior to the lens. The upper (*ul*) and lower (*ll*) eyelids are more evident here than in the surface view. Owing to the hardness of the lens, its supporting structures were torn away in sectioning. The vitreous humor is not represented in the figure. The superior (*ur*) and inferior (*lr*) recti muscles are well shown on the right side; they are attached to the median part of a Y-shaped mass of cartilage (*se*), which may be termed the sphenethmoidal cartilage. Between the branches of this Y-shaped cartilage the anterior ends of the cerebral hemispheres (*ch*)—better called, perhaps, the olfactory lobes—are seen. Between the lower end of the sphenethmoidal cartilage and a dorsally evaginated part of the pharynx are two small openings (*pn*); when traced forward these tubes are found to open into the convoluted nasal chamber, while a short distance posterior to the plane of this figure they unite with each other and open almost immediately into the pharynx. The rather complicated structures of the nasal passages of the alligator have been described by the writer in another paper (12). In the lower jaw the cartilage (*mk*) is seen on either

side and several bands of muscle are developing in the mesoblast. Two deep grooves give form to what may be called the rudimentary tongue (*tn*). In both jaws one or two tooth rudiments (*to*) may be distinguished as small invaginations of ectoderm.

#### STAGE XXI

FIGURE 24 (PLATE XXII)

In this stage the curvature of the body and tail is less marked than was seen in the last surface view. The body has increased greatly in size, so that the size of the head is relatively not so great. The size of the eye in relation to that of the head is much diminished also. The five anterior and four posterior digits are well formed, and their claws are of considerable size, though of course not present on all the digits. The outlines of scales may be traced from the tip of the tail to the skull; they are especially prominent along the dorsal profile. The skin is just beginning to show traces of pigment, which is, however, not shown in the photograph. The umbilical stalk is seen projecting with a loop of the intestine from the abdominal wall; this is shown more clearly in the next stage. The embryo now begins to exhibit some of the external characteristics of the adult alligator.

#### STAGE XXII

FIGURE 25 (PLATE XXIII)

This embryo needs no particular description. It has reached in its external appearance practically the adult condition, although there is still considerable yolk (not shown in the figure) to be absorbed, and the embryo would not have hatched for many days. Pigmentation, begun in the last stage, is now complete. The umbilical stalk is clearly seen projecting from a large opening in the body wall. The long loop of the intestine that extends down into the yolk sac is here evident, and it is hard to understand how it can all be drawn up into the body cavity when the umbilical stalk is withdrawn. No sharp shell-tooth at the tip of the snout, such as is described by Voeltzkow (18) in the crocodile, is here seen.

#### STAGE XXIII

FIGURE 26 (PLATE XXIII)

This figure shows the relative sizes of the just-hatched alligator and the egg from which it came. It also shows the position of the young alligator in the egg, half of the shell having been removed for

that purpose. The blotchy appearance of the unopened egg is due chiefly to stains produced by the decayed vegetation of the nest. At hatching the young alligator is about 20 cm. long, nearly three times the length of the egg; but the tail is so compressed that, though it makes up about half of the length of the animal, it takes up very little room in the egg.

#### SUMMARY

Owing to the fact that the embryo may undergo considerable development before the egg is laid, and also to the unusual difficulty of removing the very young embryos, the earlier stages of development are very difficult to obtain.

The mesoderm seems to be derived chiefly by proliferation from the entoderm, in which way all of that anterior to the blastopore arises. Posterior to the blastopore the mesoderm is proliferated from the lower side of the ectoderm in the usual way. No distinction can be made between the mesoderm derived from the ectoderm and that derived from the entoderm.

The ectoderm shows during the earlier stages a very great increase in thickness along the median longitudinal axis of the embryo.

The notochord is apparently of entodermal origin, though in the posterior regions, where the germ layers are continuous with each other, it is difficult to decide with certainty.

The medullary folds have a curious origin, difficult to explain without the use of figures. They are continuous posteriorly with the primitive streak, so that it is impossible to tell where the medullary groove ends and the primitive groove begins, unless the dorsal opening of the blastopore be taken as the dividing point.

The amnion develops rapidly, and entirely from the anterior end.

The blastopore or neurenteric canal is a very distinct feature of all the earlier stages up to about the time of closure of the medullary canal.

Preceding the ordinary cranial flexure there is a sort of temporary bending of the head region, due apparently to the formation of the head-fold.

During the earlier stages of development the anterior end of the embryo is pushed under the surface of the blastoderm, and is hence not seen from above.

Body torsion is not so definite in direction as in the chick, some embryos lying on the right side, others on the left.

Of the gill clefts, three clearly open to the exterior and probably a fourth also. A probable fifth cleft was seen in sections and in one surface view.

The first trace of the urinary system is seen as a dorsally projecting, solid ridge of mesoblast in the middle region of the embryo, which ridge soon becomes hollowed out to form the Wolffian duct.

The origin of the pituitary and pineal bodies is clearly seen; the latter projects backward.

No connection can be seen between the first rudiments of the sympathetic nerves and the central nervous system.

The lumen of the œsophagus is for a time obliterated as in other forms.

The choroid fissure is a very transitory but well-marked feature of the eye.

#### REFERENCES

1. ANDERSON, A.: An Account of the Eggs and Young of the Gavial (*G. gangeticus*). Proc. Zoöl. Soc., 1875.
2. BALFOUR, F. M.: The Early Development of the Lacertilia. Quar. Jour. Mic. Soc., 1879, vol. XIX, pp. 421-430.
3. BALFOUR, F. M.: Comparative Embryology, vol. II.
4. BRONN, H. G.: Klassen des Thier-Reichs (vols. on reptiles).
5. CLARKE, S. F.: The Habits and Embryology of the American Alligator. Jour. Morph., vol. v, pp. 182-214.
6. DENDY, ARTHUR: Outlines of the Development of Tuatara (*Sphenodon punctatus*). Quar. Jour. Mic. Soc., vol. XXXII, 1899, pp. 1-87.
7. EISLER, P.: Zur Kenntniss der Histologie des Alligatormagens. Archiv. f. Mik. Anat., vol. XXXIV, pp. 1-10, 1889.
8. HOFFMANN, C. K.: Beiträge zur Entwicklungsgeschichte der Reptilien. Zeit. f. wiss. Zoöl., vol. XXXX, 1884, pp. 214-246.
9. HOFFMANN, C. K.: Weitere Untersuchungen zur Entwicklungsgeschichte der Reptilien. Morph. Jahrb., vol. XI, 1886, pp. 176-219.
10. PARKER, W. K.: On the Structure and Development of the Skull in the Crocodile. London, 1883. Zoöl. Soc. London, 1883, vol. XI, pp. 263-310.
11. RATHKE, H.: Untersuchungen über die Entwicklung und den Körperbau der Krokodile. Braunschweig, 1866.
12. REESE, A. M.: The Nasal Passages of the Florida Alligator. Proc. Phila. Acad. Nat. Sc., 1901.
13. REESE, A. M.: The Breedings Habits of the Florida Alligator. Smithsonian Misc. Coll. (Quarterly Issue), vol. XLVIII, pp. 381-387, 1907.
14. ROESE, C.: Über die Zahnleiste und die Eischweile der Sauropsiden. Anat. Anz., 1892, vol. VII, pp. 248-264.
15. STRAHL, H.: Beiträge zur Entwicklung von Lacerta agilis. Archiv. f. Anat. u. Physiol., 1882, pp. 242-278.
16. STRAHL, H.: Beiträge zur Entwicklung der Reptilien. *Ibid.*, 1883, pp. 1-43.
17. STRAHL, H.: Über frühe Entwicklungsstadien von Lacerta agilis. Zoöl. Anz., vol. VI, 1883, pp. 347-350.
18. VOELTZKOW, ALFRED: Biologie und Entwicklung der äusseren Körperform von Crocodilus madagascariensis Grand. Abhandl. Senckenberg. Naturf. Gesell., vol. XXVI, pt. I, pp. 1-149, 1889.
19. WIEDERSHEIM, R.: Comparative Anatomy.

## LETTERING FOR ALL FIGURES

- a*, head-fold of amnion.  
*aa*, anterior appendage.  
*ac*, anterior cardinal vein.  
*al*, allantois.  
*an*, anterior nares.  
*ao*, aorta.  
*aop*, area opaca.  
*ap*, area pellucida.  
*ar*, aortic arch.  
*au*, auricle.  
*b*, bulbus arteriosus.  
*bc*, body cavity.  
*blp*, blastopore.  
*bp*, basilar plate.  
*bv*, blood vessel.  
*c*, centrum of vertebra.  
*ca*, caudal artery.  
*ch*, cerebral hemisphere.  
*cl*, cloaca.  
*cn*, cranial nerve.  
*cp*, posterior choroid plexus.  
*cv*, cardinal veins.  
*dc*, ductus Cuvieri.  
*e*, eye.  
*ec*, ectoderm.  
*ec'*, thickening of ectoderm.  
*en*, entoderm.  
*en'*, endocardium.  
*ent*, enteron.  
*ep*, epidermal layer of ectoderm.  
*epi*, pineal body.  
*es*, embryonic shield.  
*f*, fronto-nasal process.  
*fb*, forebrain.  
*fg*, foregut.  
*g<sup>1-5</sup>*, gill clefts.  
*gf<sup>1-6</sup>*, gill folds.  
*gl*, glomerulus.  
*h*, head-fold.  
*hb*, hindbrain.  
*ht*, heart.  
*i*, intestine.  
*i'*, stomach.  
*in*, infundibulum.  
*ir*, iris.  
*it*, iter.  
*k*, kidney (metanephros).  
*l*, remains of groove between secondary folds.  
*la*, larynx (cartilages of).  
*li*, liver.  
*ll*, lower lid of eye.  
*ln*, lens.  
*lr*, inferior rectus muscle of eye.  
*lu*, lungs.  
*lv*, lens vesicle.  
*m*, mouth.  
*ma*, manus.  
*mb*, midbrain.  
*mc*, medullary canal.  
*me'*, tip end of medullary canal.  
*md*, mandibular fold.  
*mes*, mesoderm.  
*mes'*, myocardium.  
*mf*, medullary fold.  
*mg*, medullary groove.  
*mk*, Meckel's cartilage.  
*mp*, muscle plate.  
*ms*, mesentery.  
*mv*, meatus venosus.  
*mx*, maxillary fold.  
*myc*, myocoel.  
*n*, nasal invagination or cavity.  
*na*, neural arch of vertebra.  
*nc*, neurenteric canal.  
*nl*, nervous layer of ectoderm.  
*nt*, notochord.  
*o*, ear vesicle.  
*oc*, optic cup.  
*oe*, oesophagus.  
*on*, optic nerve.  
*os*, optic stalk.  
*ov*, optic vesicle.  
*p*, pituitary body.  
*pa*, posterior appendage.  
*pan*, pancreas.  
*pc*, posterior cardinal vein.  
*pe*, pes.  
*pg*, primitive groove.  
*ph*, pharynx.  
*pl*, pelvis.  
*pn*, posterior nares.  
*pr*, pericardial cavity.  
*ps*, primitive streak.  
*pt*, pecten.  
*rt*, retina.  
*s*, somites.  
*sc*, spinal cord.  
*sc*, sphenethmoid cartilage.  
*sf*, secondary fold.

<i>sg</i> , spinal ganglion.	<i>u</i> , umbilical stalk.
<i>sm</i> , splanchnic mesoblast.	<i>ul</i> , upper lid of eye.
<i>sn</i> , spinal nerve.	<i>ur</i> , superior rectus muscle of eye.
<i>so</i> , somatic mesoblast.	<i>v''''</i> , first, second, and third cere-
<i>st</i> , stomodæum.	bral vesicles.
<i>sy</i> , sympathetic nervous system.	<i>va</i> , vascular area.
<i>t</i> , tail.	<i>vm</i> , vitelline membrane.
<i>ta</i> , trachea.	<i>vn</i> , ventricle of heart.
<i>tg</i> , thyroid gland.	<i>vv</i> , vitelline blood-vessels.
<i>th</i> , thickening and posterior limit of <i>sf</i> .	<i>wd</i> , Wolffian duct.
<i>tn</i> , tongue.	<i>wdo</i> , opening of Wolffian duct.
<i>to</i> , tooth anlage.	<i>wr</i> , Wolffian ridge.
<i>tr</i> , truncus arteriosus.	<i>wt</i> , Wolffian tubules.
<i>tv</i> , third ventricle of brain.	<i>y</i> , yolk.
<i>tv'</i> , third ventricle of brain.	

#### EXPLANATION OF FIGURES 1-26 ON PLATES I-XXIII

All of the figures, with the exception of the photographs and those copied by permission from S. F. Clarke, were drawn under a *camera lucida*.

The magnification of each figure, except those from Clarke, is indicated below.

The photographs were made by the author, and were enlarged for reproduction by the photographic department of the Smithsonian Institution. The other surface views were made, under the author's direction, by Miss C. M. Reese.

With the exception of Stage III, all of the figures of any one stage are given the same number, followed where necessary by a distinguishing letter, so that it is possible to tell at a glance which section and surface views belong together. The transverse sections are all cut in series from anterior to posterior.

FIGURE 1. Surface view of egg.  $\times 2/3$ .

1a. Egg with part of the shell removed to show the chalky band in the shell membrane.  $\times 2/3$ .

FIGURES 2 and 2a. Dorsal and ventral views respectively of the blastoderm before the formation of the notochord, medullary folds, etc. After Clarke.

2b-2f. Transverse sections of an embryo of the age represented in figures 2 and 2a.  $\times 43$ .

3 and 3a. Ventral and dorsal views respectively of an embryo a few days older than that represented in figures 2 and 2a. After Clarke.

3b-3m. Transverse sections of an embryo of the age shown in figures 3 and 3a.  $\times 43$ .

FIGURES 3n and 3o. Two sagittal section of an embryo of the same stage as figures 3 and 3a.  $\times 43$ .

4 and 4a. Dorsal and ventral views respectively of a slightly older embryo than the one shown in figures 3 and 3a. Figure 4a shows only the head region. After Clarke.

5 and 5a. Dorsal and ventral views respectively of an embryo of



almost the same age as the preceding, to show the further development of the medullary folds. After Clarke.

FIGURE 6. Dorsal view of an embryo only a day or two older than the preceding. After Clarke.

FIGURES 6a-6i. A series of transverse sections of this stage.  $\times 43$ .

FIGURES 7a-7h. A series of transverse sections of an embryo slightly older than the one shown in figures 4-6.  $\times 43$ . (No surface view of this stage is figured.)

8 and 8a. Dorsal and ventral views respectively of an embryo with five pairs of mesoblastic somites.  $\times 20$ . (Drawn by transmitted light.)

8b and 8c. Two sagittal sections of an embryo of this stage.  $\times 43$ .

FIGURES 8d-8j. A series of transverse sections of the embryo represented in figures 8 and 8a.  $\times 43$ .

9a-9m. A series of transverse sections of an embryo somewhat more advanced in development than the one represented in the last series.  $\times 43$ .

FIGURES 10 and 10a. Dorsal and ventral views respectively of an embryo with eight pairs of mesoblastic somites.  $\times 20$ . (Drawn chiefly by transmitted light.)

FIGURE 11. Dorsal view of an embryo with fourteen pairs of mesoblastic somites. The area pellucida and the developing vascular area are shown, the latter having a mottled appearance. The pushing of the head under the blastoderm is also shown.  $\times 20$ . (Drawn chiefly by transmitted light.)

FIGURES 11a-11k. A series of transverse sections of an embryo of this stage.  $\times 43$ .

FIGURE 12. Dorsal view of an embryo with about seventeen pairs of mesoblastic somites. Part of the area pellucida is represented. (Both transmitted and reflected light were used in making the drawing.)  $\times 13$ .

FIGURES 12a-12g. A series of transverse sections of an embryo of this stage.  $\times 43$ .

FIGURE 13. Surface view of an embryo with about twenty pairs of mesoblastic somites.  $\times$  (about) 15. (Drawn with both reflected and transmitted light.)

FIGURES 13-13f. A series of transverse sections of an embryo slightly more developed than the one shown in figure 13.  $\times 20$ .

FIGURE 13g. A sagittal section of an embryo of about the age of the one represented in figure 13.  $\times 20$ .

14. Head of an embryo with one pair of gill clefts; ventro-lateral view.  $\times 13$ .

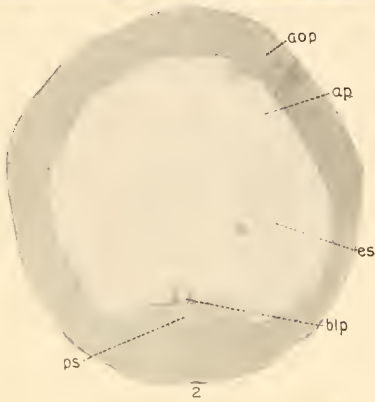
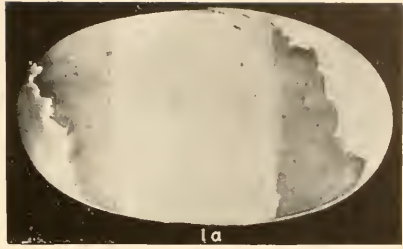
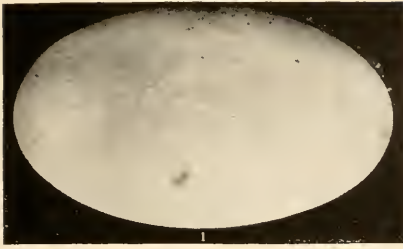
15. Profile view of the head of an embryo with three pairs of gill clefts.  $\times 13$ .

FIGURES 15a-15c. A series of transverse sections of an embryo of about the age of the one represented in figure 15.  $\times 20$ .

FIGURE 15f. A horizontal section through the anterior region of an embryo of the age of that shown in figure 15.  $\times 20$ .

16. Surface view in profile of an embryo with four pairs of gill clefts.  $\times$  (about) 12.

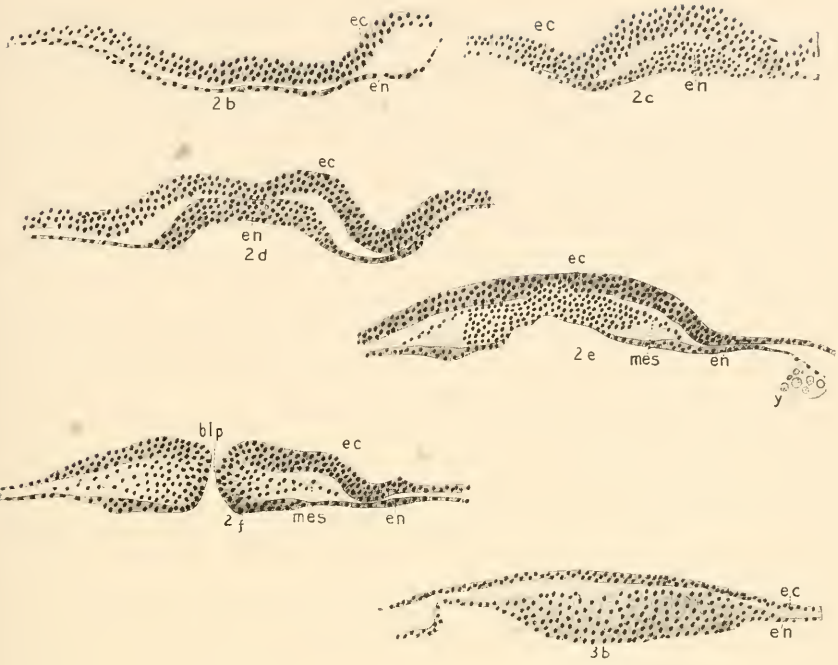
- FIGURES 16a-16f. A series of transverse sections of an embryo of the approximate age of the one represented in figure 16.  $\times 20$ .
- FIGURE 16g. A sagittal section of an embryo of the age (possibly slightly younger) of the one represented in figure 16.  $\times 20$ .
17. Surface view in profile of an embryo at the time of origin of the limbs.  $\times$  (about) 5.
- FIGURES 17a-17g. A series of transverse sections of an embryo of the age of the one represented in figure 17.  $\times 7$ .
- FIGURE 18. Surface view in profile of the head of an embryo slightly larger than, though of about the same state of development as, the one represented in figure 17. Reproduced here chiefly to show the gill clefts.  $\times$  (about) 3.
19. Surface view of an embryo somewhat more developed than the one just described.  $\times$  (about) 3.
- FIGURE 20. Surface view of an embryo older than the one represented in figure 19; with well-developed manus and pes.  $\times$  (about) 5.
- FIGURES 20a-20j. A series of transverse sections of an embryo of the age of the one represented in figure 20.  $\times 7$ .
- FIGURE 21. A photograph of a living embryo in the egg, showing the allantois, yolk mass, etc. The embryo is somewhat more developed than the one shown in figure 20.  $\times 2\frac{1}{3}$ .
22. A photograph of a still larger embryo, removed from the shell and freed from the fetal membranes.  $\times$  (about) 1.
23. A photograph of a still more advanced embryo, in which the digits are quite evident and the scales are beginning to show.  $\times$  (about) 1.
- 23a. A sagittal section of an embryo of the age of the one represented in figure 23; the tail has not been shown in this figure.  $\times$  (about) 3.
- 23b. A vertical section through the head of an embryo of about the size (perhaps slightly smaller) of the one shown in figure 23.  $\times$  (about) 3.
24. A photograph of an older embryo in which the pigmentation of the scales is evident, though not shown in the figure.  $\times$  (about) 1.
25. A photograph of an embryo in which the pigmentation and the development of the body form are practically complete. The allantois, unabsorbed yolk, etc., have been removed.  $\times$  (about)  $\frac{3}{4}$ .
26. A photograph of a just-hatched alligator, of an alligator egg, and of a young alligator in the egg just before hatching.  $\times$  (about)  $\frac{3}{7}$ .



DEVELOPMENT OF THE AMERICAN ALLIGATOR

1, 1a.—The Egg. 2, 2a.—Stage I

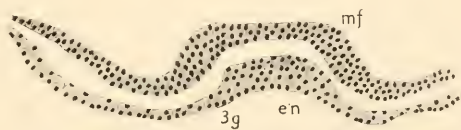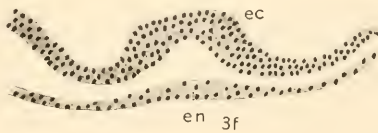
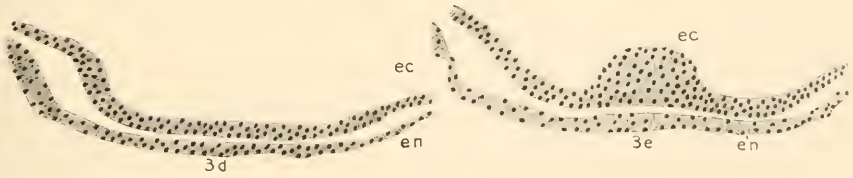
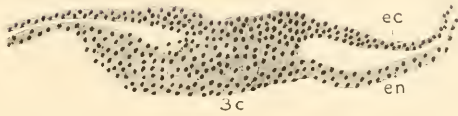
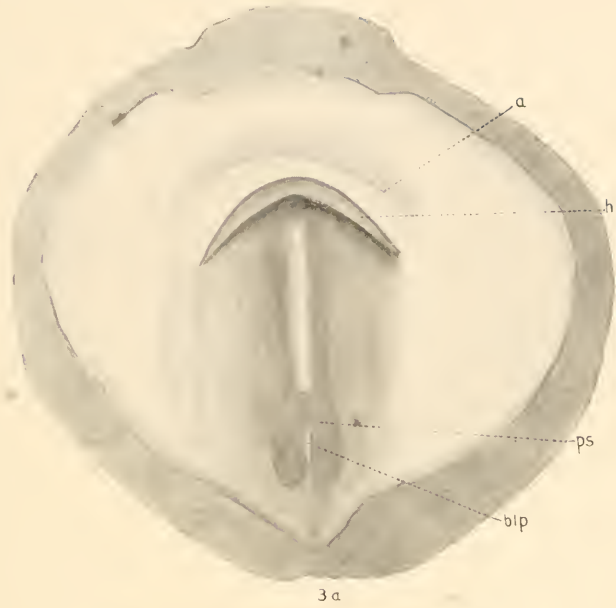




DEVELOPMENT OF THE AMERICAN ALLIGATOR

2b-2f.—Stage I. 3, 3b.—Stage II

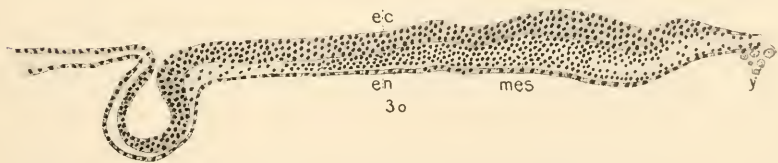
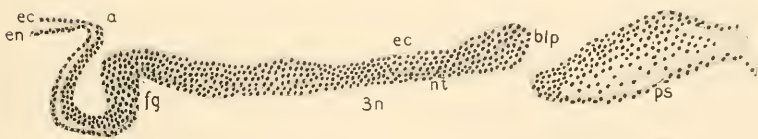
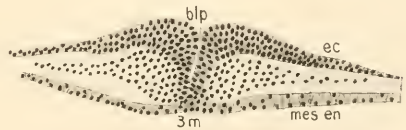
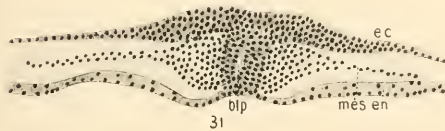
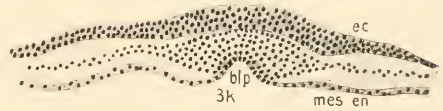
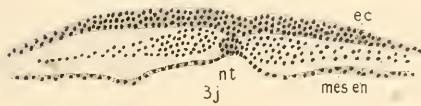
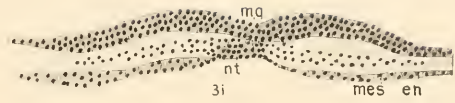
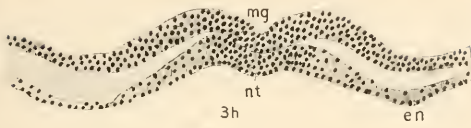




DEVELOPMENT OF THE AMERICAN ALLIGATOR  
3a, 3g.—Stage II



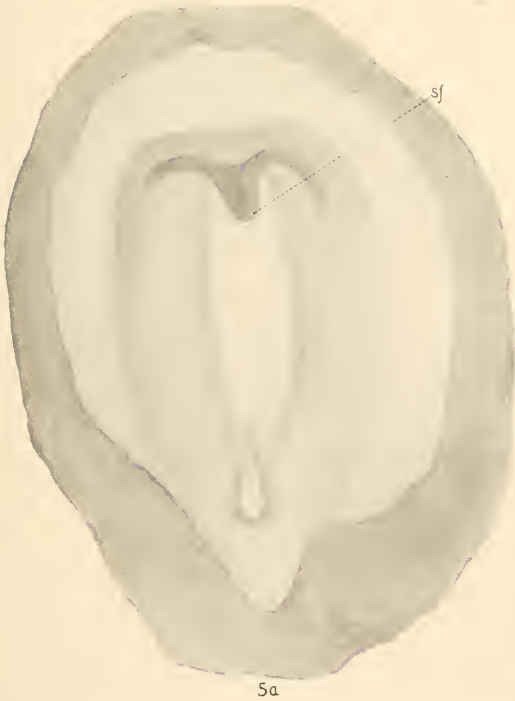
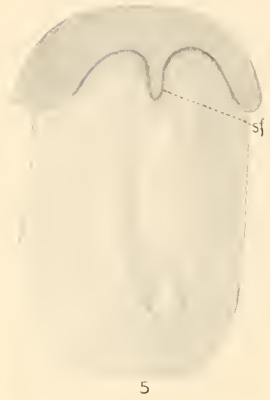
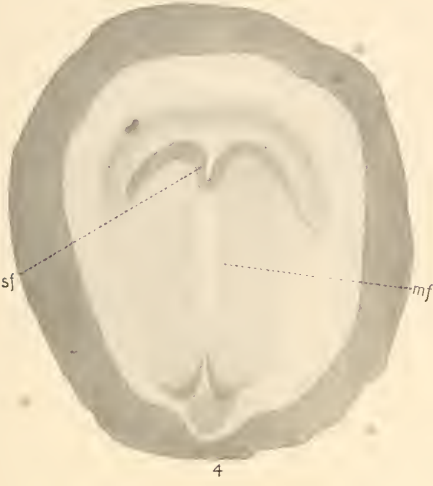

DEVELOPMENT OF THE AMERICAN ALLIGATOR

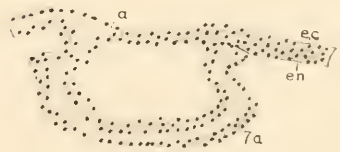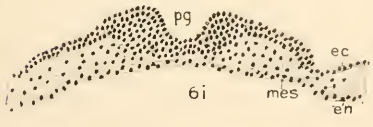
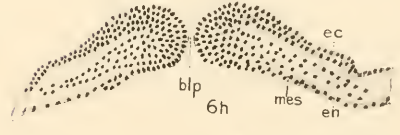
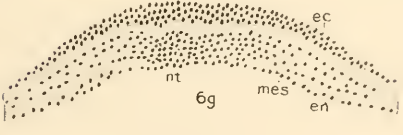
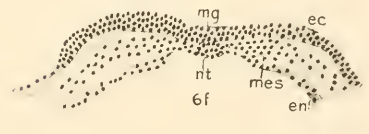
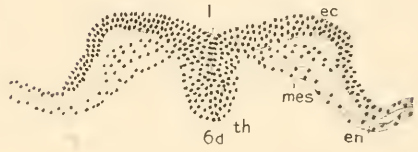
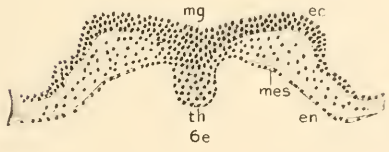
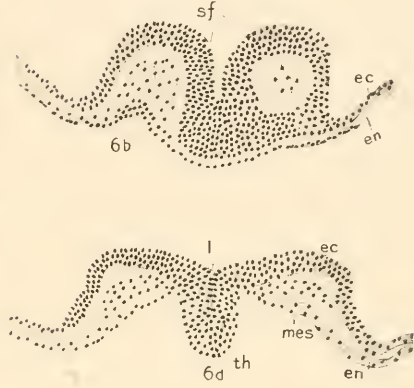
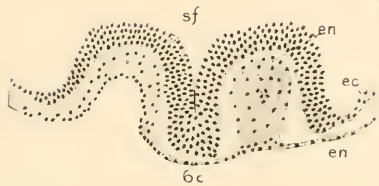
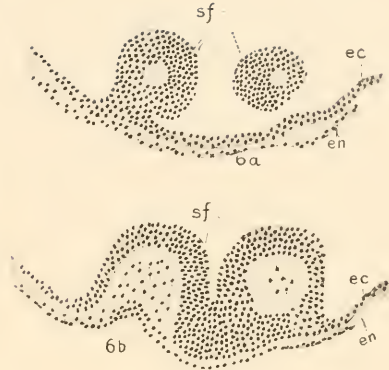
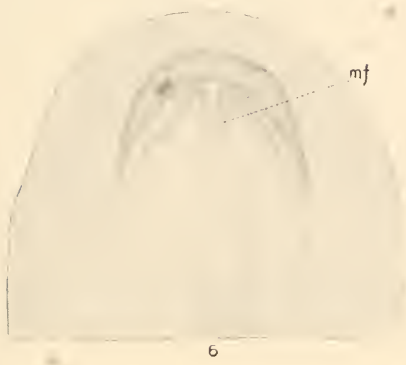
3h-3o.—Stage II





DEVELOPMENT OF THE AMERICAN ALLIGATOR  
Stage III

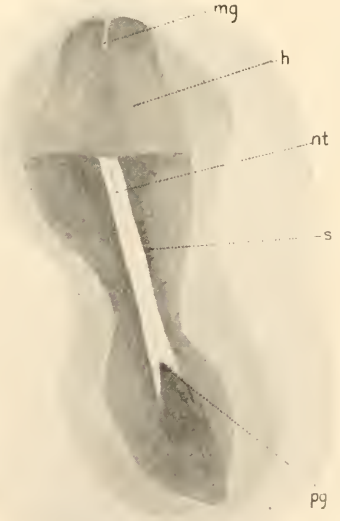
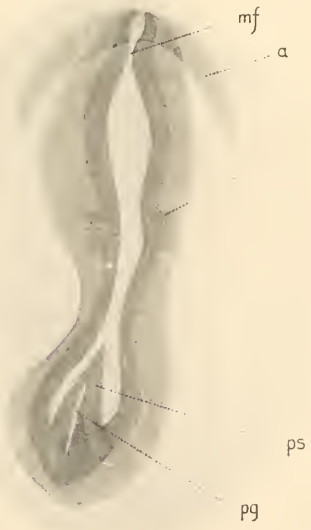
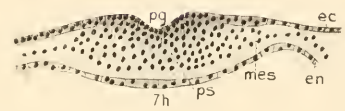
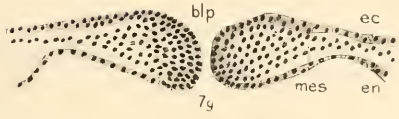
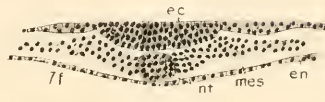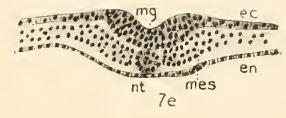
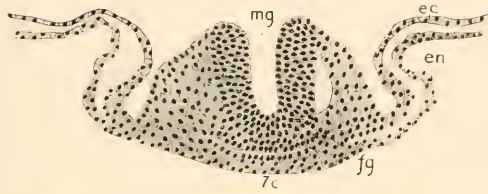
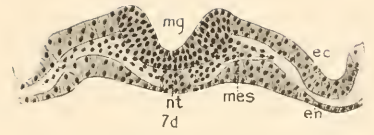
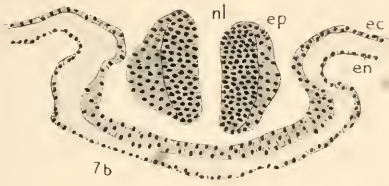




DEVELOPMENT OF THE AMERICAN ALLIGATOR

6-6i.—Stage III. 7a.—Stage IV





8

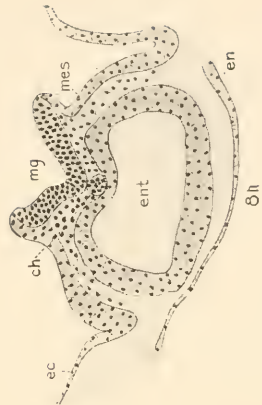
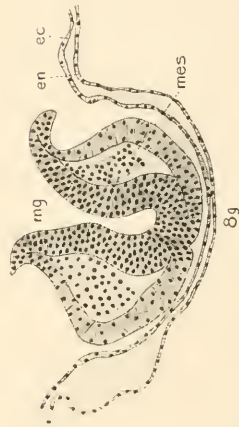
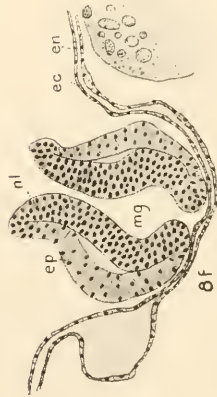
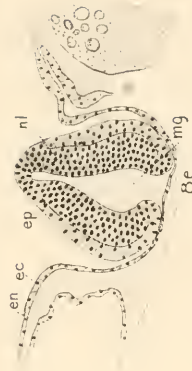
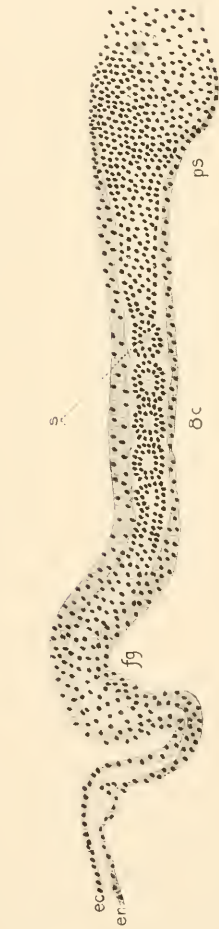
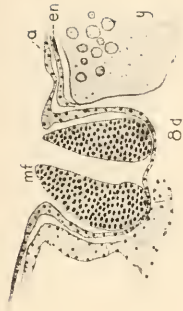
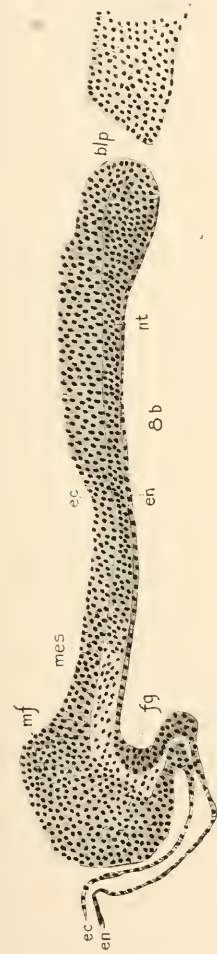
8a

DEVELOPMENT OF THE AMERICAN ALLIGATOR

7b-7h.—Stage IV. 8, 8a.—Stage V



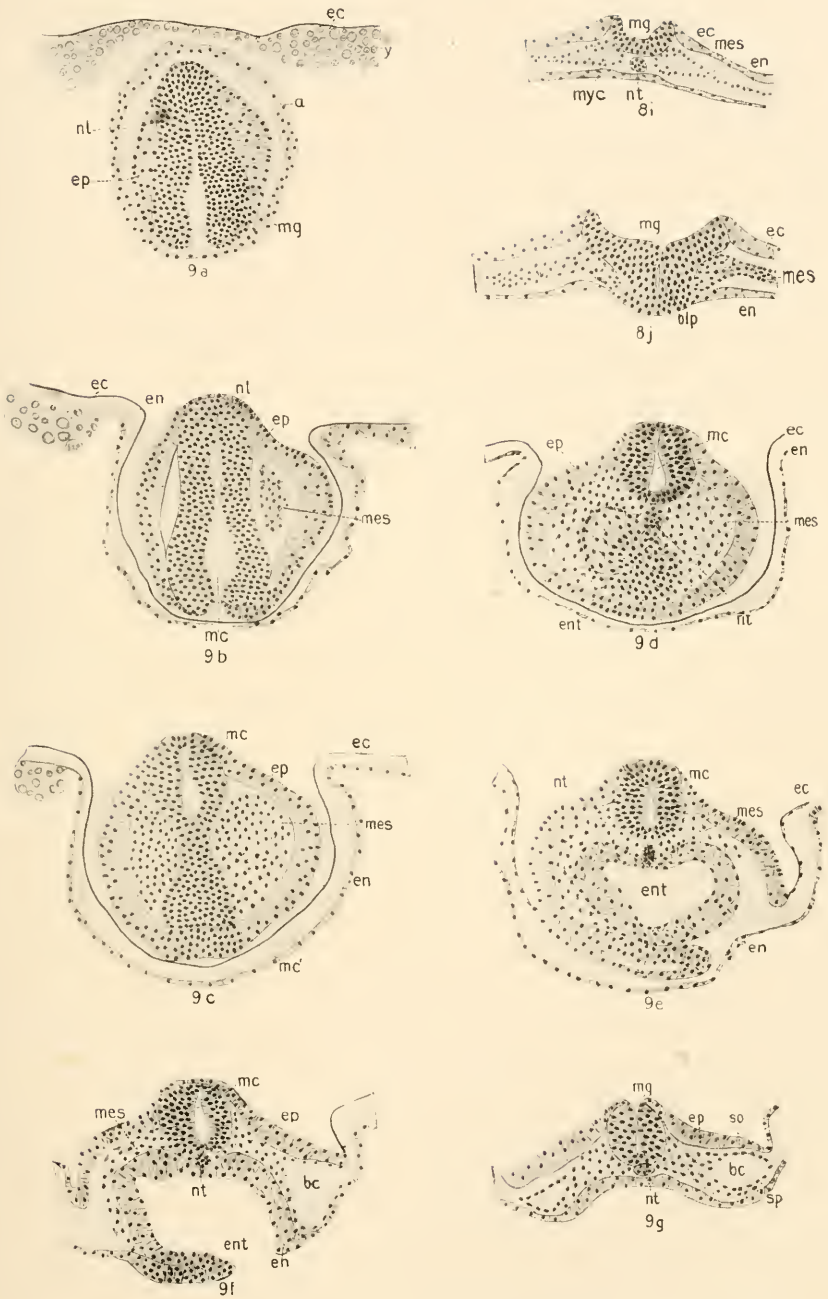




DEVELOPMENT OF THE AMERICAN ALLIGATOR

Stage Y

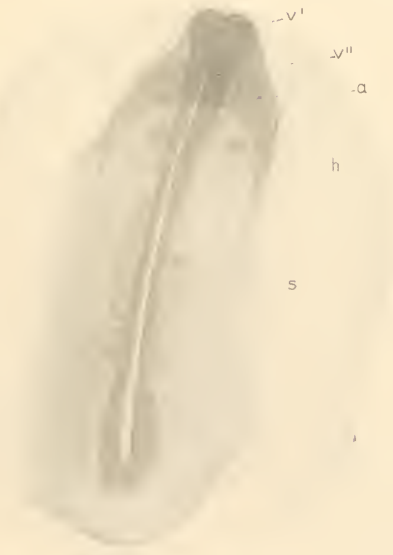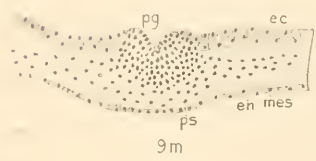
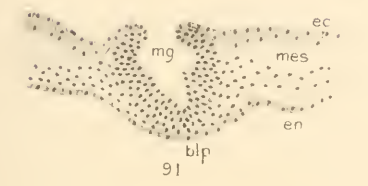
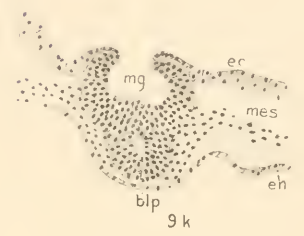
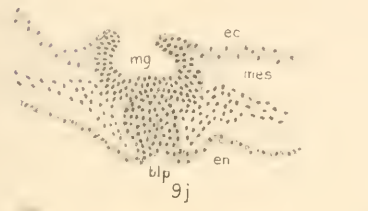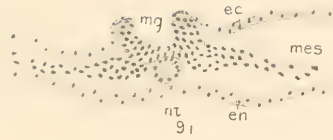
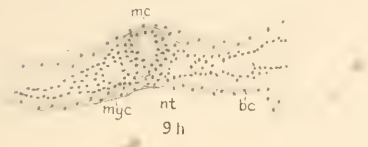




DEVELOPMENT OF THE AMERICAN ALLIGATOR

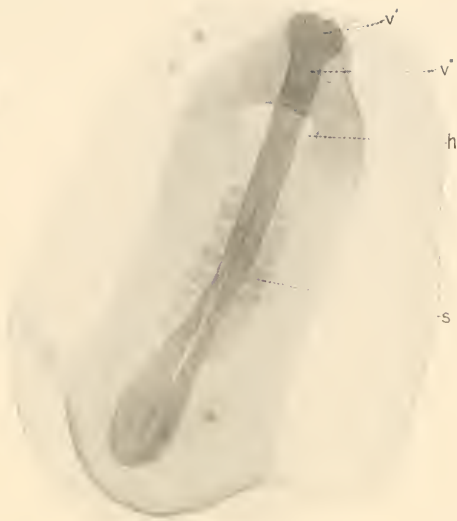8i, 8j.—Stage V. 9a-9g.—Stage VI



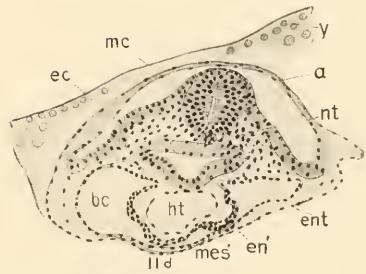
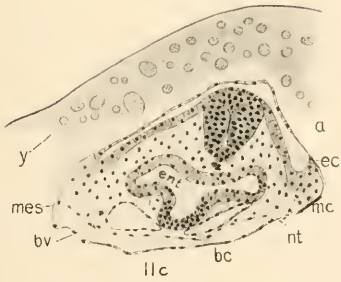
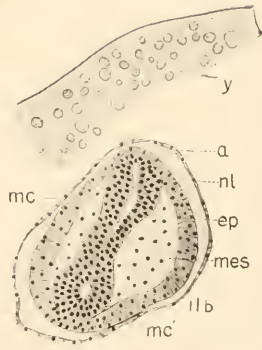
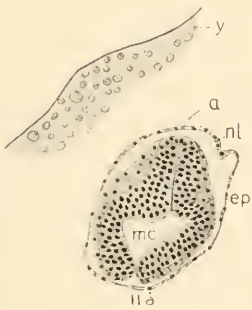


DEVELOPMENT OF THE AMERICAN ALLIGATOR  
*9h-9m.*—Stage VI. *1c.*—Stage VII





10a

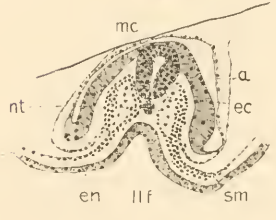
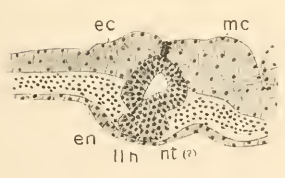
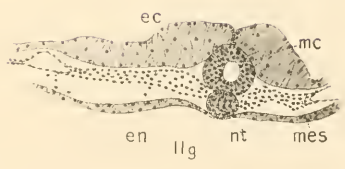
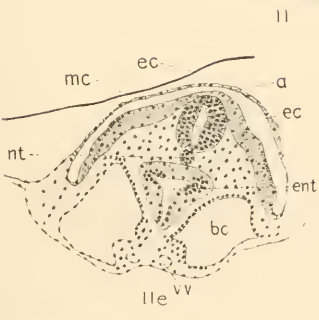
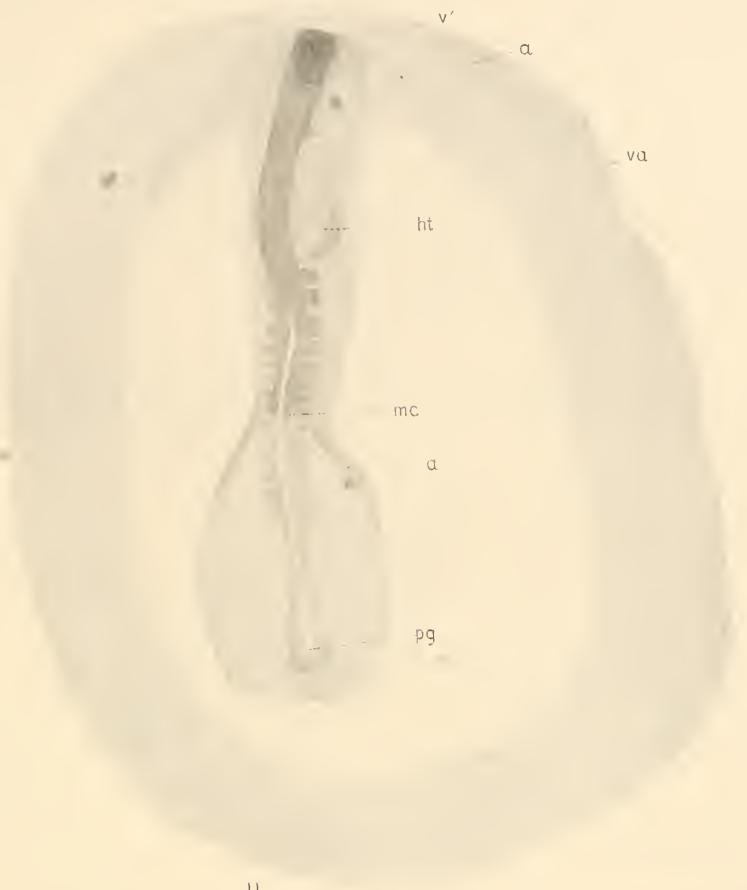

DEVELOPMENT OF THE AMERICAN ALLIGATOR

10a.—Stage VII. 11a-11d.—Stage VIII

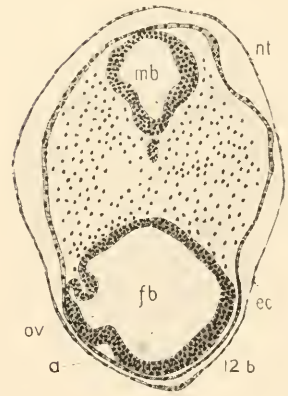
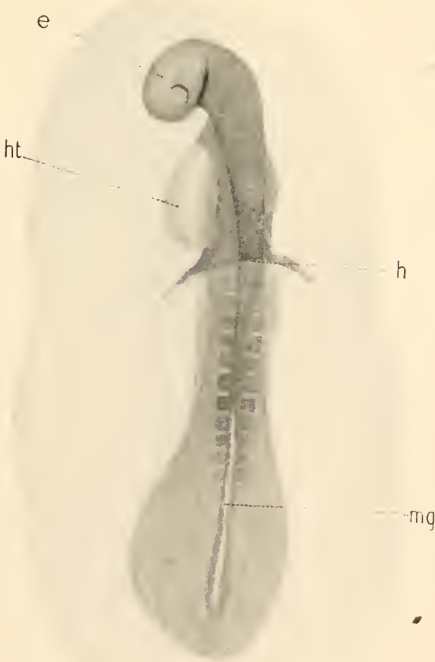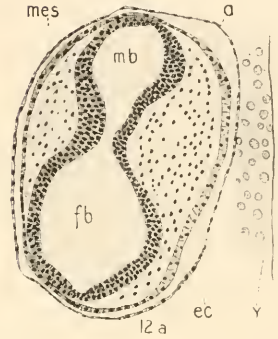
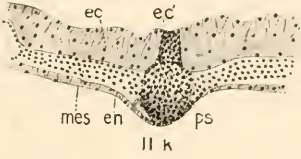
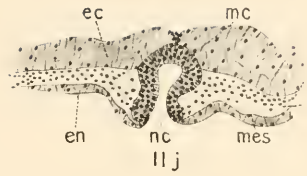
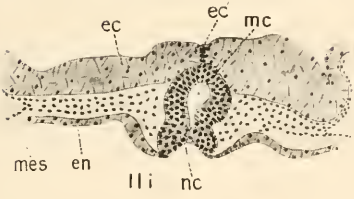






DEVELOPMENT OF THE AMERICAN ALLIGATOR  
Stage VIII

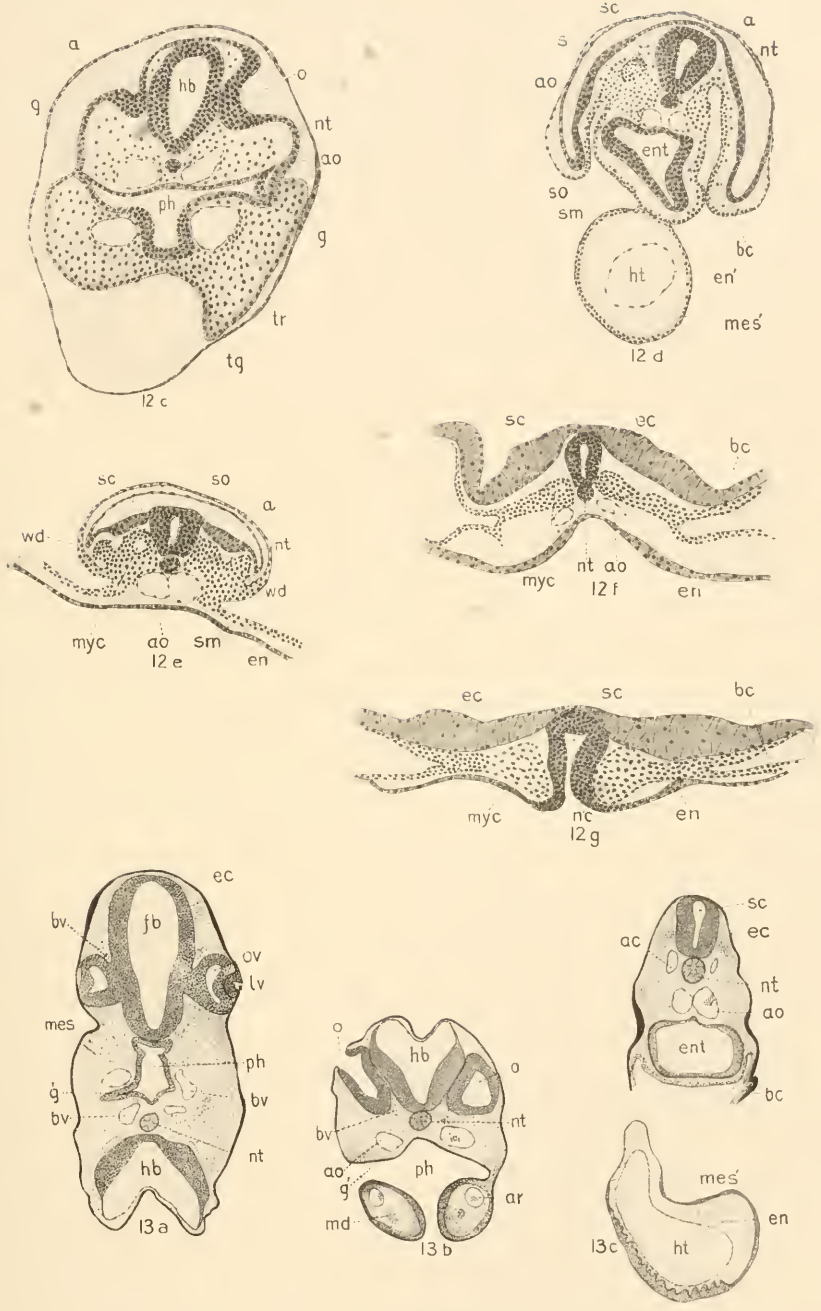




DEVELOPMENT OF THE AMERICAN ALLIGATOR

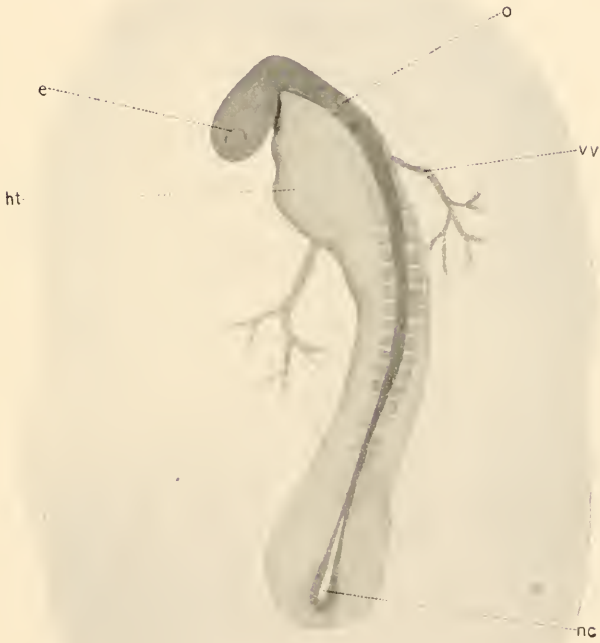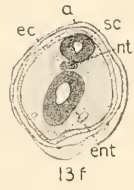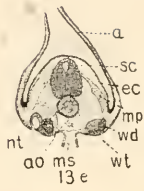
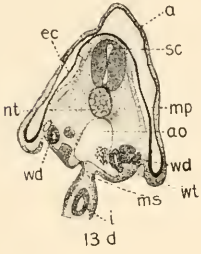
11i-11k.—Stage VIII. 12-12b.—Stage IX





DEVELOPMENT OF THE AMERICAN ALLIGATOR  
 12c-12g—Stage IX. 13a-13c.—Stage X

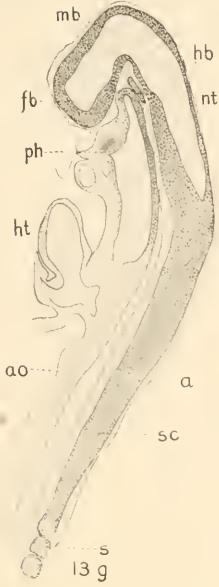




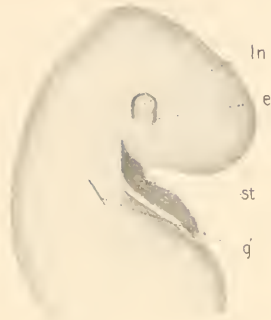
DEVELOPMENT OF THE AMERICAN ALLIGATOR  
Stage X



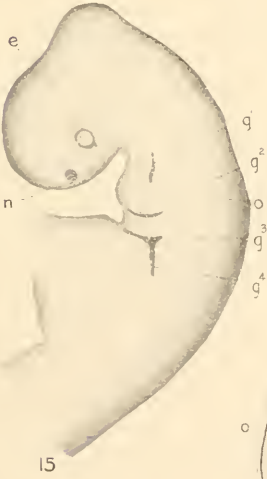



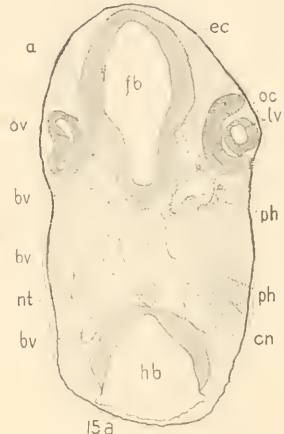
13g



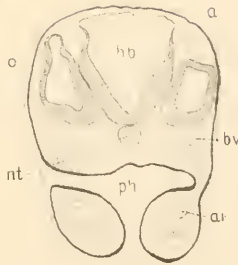
14



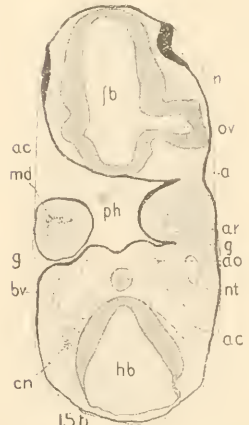
15



15a



15c

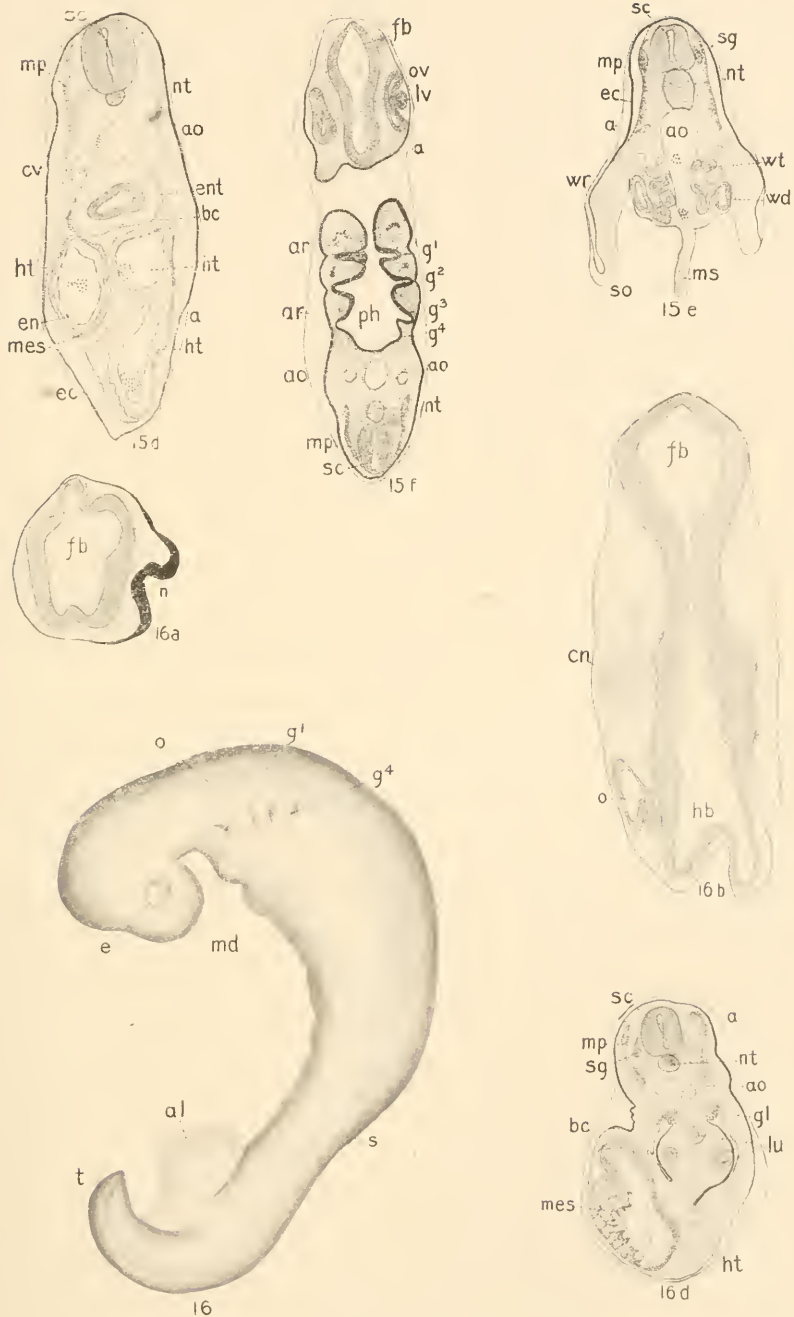


15b

DEVELOPMENT OF THE AMERICAN ALLIGATOR

13g.—Stage X. 14.—Stage XI. 15a-15c.—Stage XII

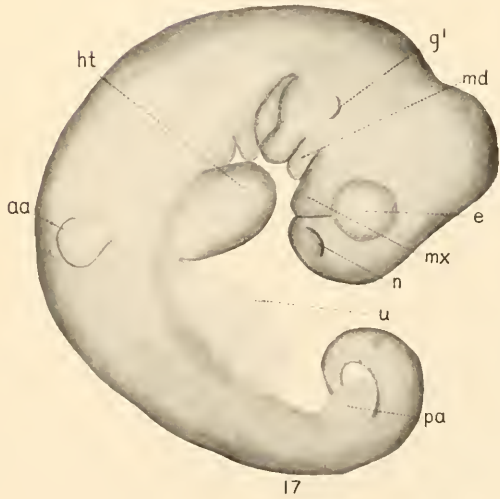
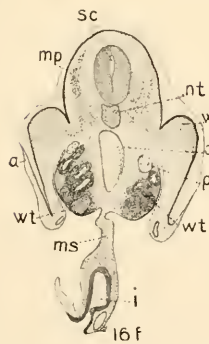
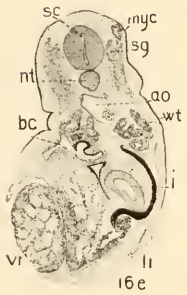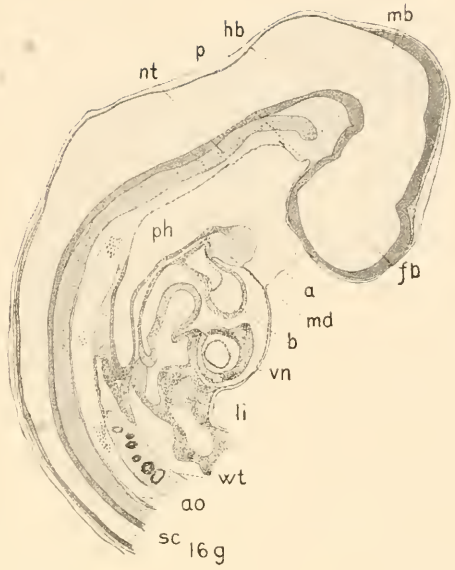
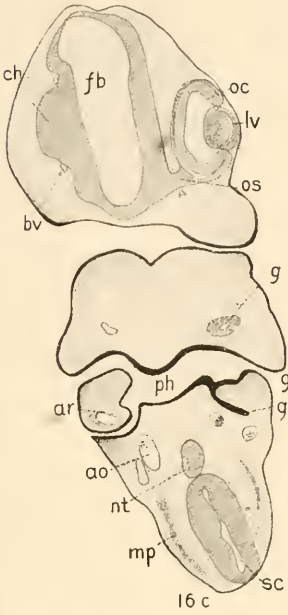




DEVELOPMENT OF THE AMERICAN ALLIGATOR

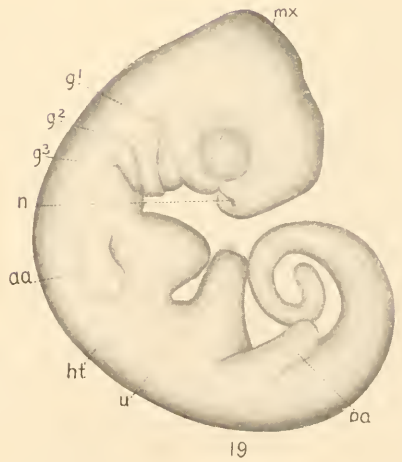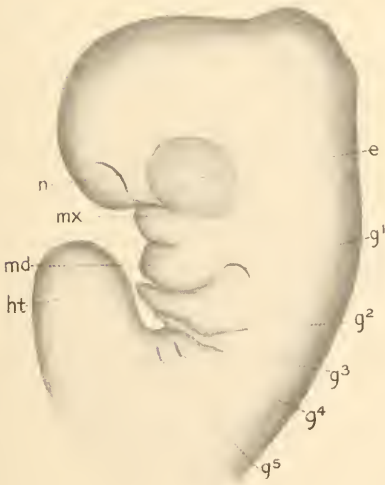
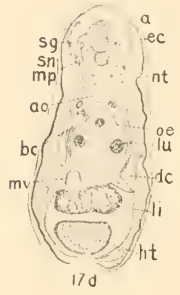
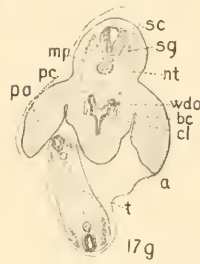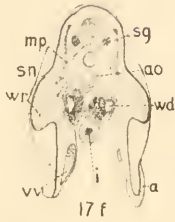
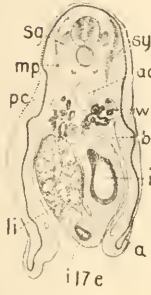
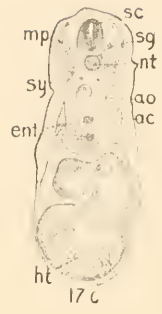
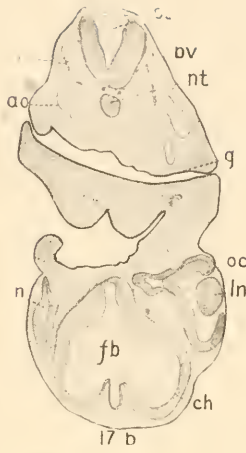
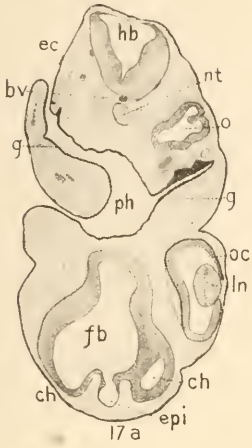
15d-15f.—Stage XII. 16-16d.—Stage XIII





DEVELOPMENT OF THE AMERICAN ALLIGATOR  
16c-16g.—Stage XIII. 17.—Stage XIV





18

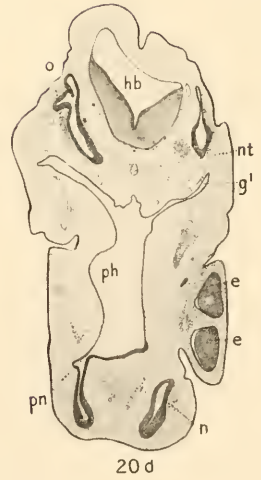
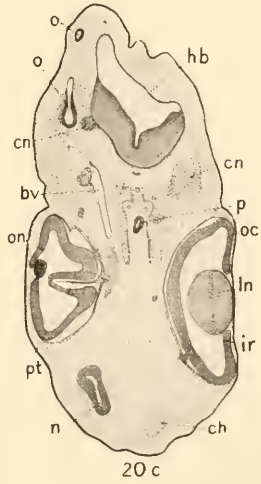
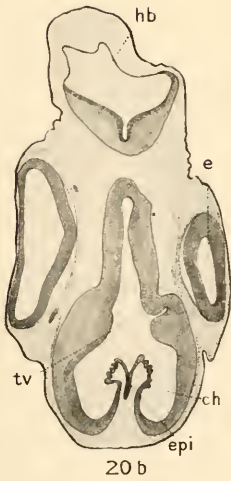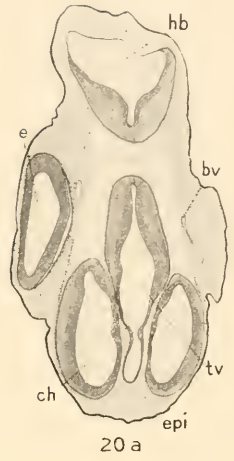
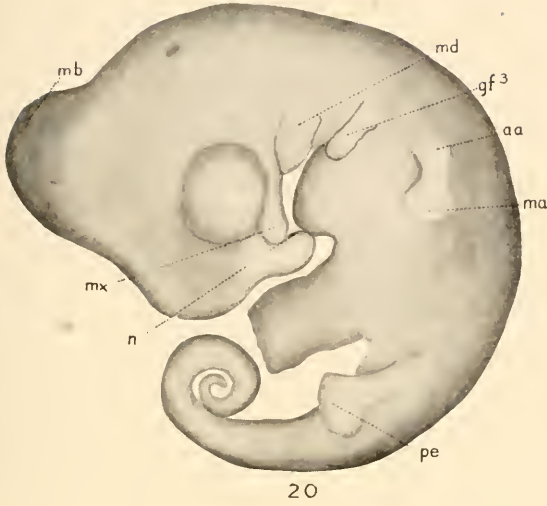19

DEVELOPMENT OF THE AMERICAN ALLIGATOR

17a-17g.—Stage XIV. 18.—Stage XV. 19.—Stage XVI

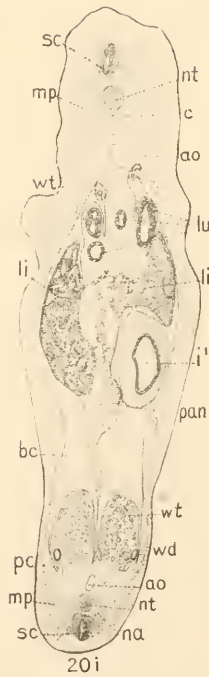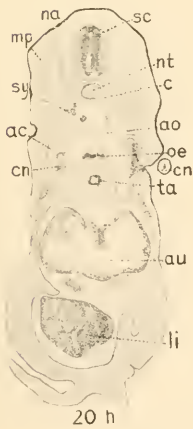
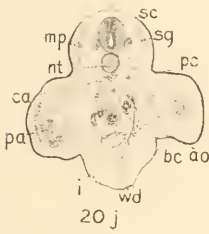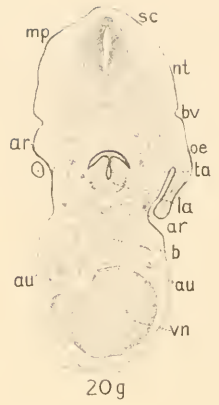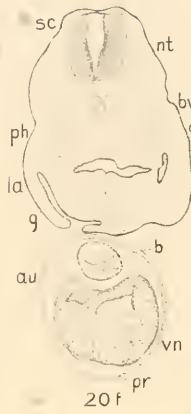



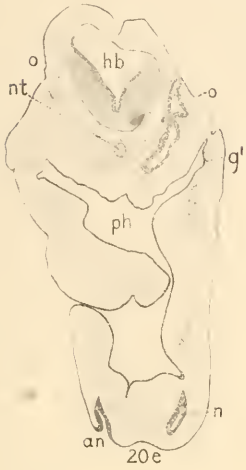


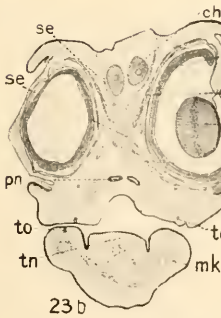
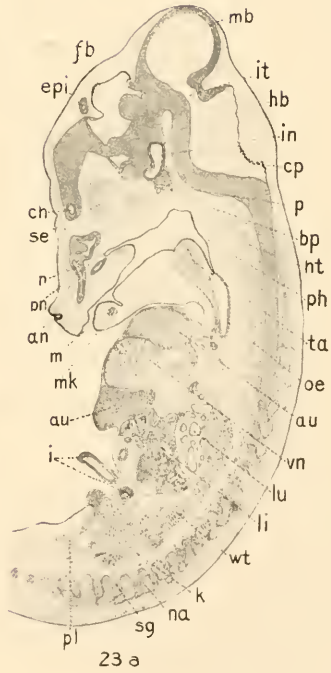
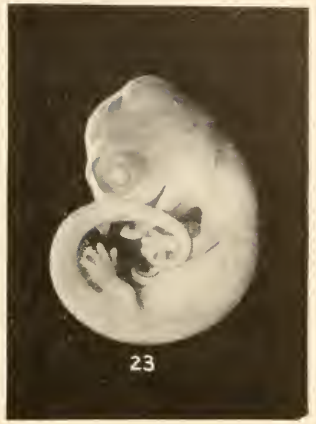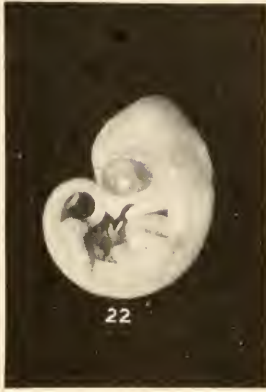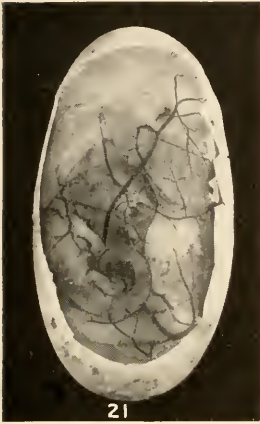DEVELOPMENT OF THE AMERICAN ALLIGATOR  
Stage XVII





DEVELOPMENT OF THE AMERICAN ALLIGATOR  
Stage XVII





DEVELOPMENT OF THE AMERICAN ALLIGATOR

21.—Stage XVIII. 22.—Stage XIX. 23-23b.—Stage XX. 24.—Stage XXI





25



26

DEVELOPMENT OF THE AMERICAN ALLIGATOR

25.—Stage XXII Alligator embryo. 26.—Stage XXIII Alligator just hatched and relative size of egg.