

THE BRACHIAL FLEXOR MUSCLES IN PRIMATES

By A. BRAZIER HOWELL and WILLIAM L. STRAUS, JR.

Department of Anatomy, Johns Hopkins University, Baltimore, Md.

The investigator who undertakes to dissect the musculature of a considerable number of mammals will at once find a diversity of conditions in the brachial flexor muscles that may well puzzle him. Recourse to the literature on the subject may shed but little light upon his particular problems, for the reason that there is considerable confusion and ambiguity in the manner in which authors dispose of this group.

The present writers found this state of affairs so unsatisfactory that they undertook an investigation of the brachial flexors that was sufficiently extensive to give them what they believe to be a proper understanding of conditions. No attempt has been made to study the situation found in a great number of genera, but fortunately their own dissections have chanced to illustrate a number of differing brachial details, which they believe to be sufficient for the purpose stated. Primates only are herein considered, except that the interesting condition in the opossum (*Didelphis*) is also mentioned, together with isolated details of representatives of one or two additional orders. The brachial flexors of these pertinent specimens will first be described, and a discussion will then follow.

Grateful acknowledgment is made to the officials of the United States National Museum for the loan of four of the specimens dissected, as well as for the numerous skeletons we have examined. In addition, six of the specimens used and now designated by Johns Hopkins University numbers were generously contributed, after their death, to that institution by the National Zoological Park. For ease of comparison the drawings have been made of uniform size, without regard to the real dimensions of the specimens. The humeral length, as given to indicate actual size, was taken from the head of the humerus to the lateral condyle.

DESCRIPTION OF THE SPECIMENS

Pan sp.—Johns Hopkins Anat. No. 38, male, with humeral length of 222 mm.; right side.

M. biceps brachii, capita longum et breve.—The caput longum arose from the supraglenoid tuberosity of the scapula as usual and passed over the bicipital groove, which is very deep in the chimpanzee. There was also an accessory, weaker head from the capsule of the joint. These two heads fused some 60 mm. below the head of the humerus. Caput breve, of about equal mass but broader than caput longum, arose with the coracobrachialis from the coracoid process. The two biceps divisions, longum and breve, fused some 70 mm. from insertion upon the radial bicipital process. The terminal tendon was about 25 mm. in length. There was quite a well-marked lacertus fibrosus.

M. coracobrachialis, partes superficialis et media.—The anomalous superficial portion took origin in common with, and upon the medial side of, the short biceps origin from the coracoid. It continued entirely superficial to all nerves and muscles of the brachium, except the dorsoepitrochlearis, to its insertion upon the medial epicondyle. It was slender but sharply defined, the distal half being nonmuscular and weakly tendinous. The musculocutaneous nerve passed between it and the coracobrachialis medius. The latter muscle constituted at first a deeper, broader layer of the common coracoid tendon. The most proximal point at which its fibers inserted upon the humerus was 10 mm. above the most distal part of the deltoid, and 15 mm. below the latissimus tendon; so no part of it could be considered as representing a coracobrachialis profundus (brevis). Insertion thence continued for 70 mm., or to a point 60 mm. above the condyle.

M. brachialis.—The medial belly of this muscle was partly divisible from the lateral along the line shown in Plate 1. The medial had the more extensive origin from the distal half of the humerus and quite to the epicondyle, and the insertion was broad and tendinous into the fossa upon the ulna just distal to the coronoid process. The partially separable lateral portion of the brachialis had a shorter origin adjoining and partly surrounding the deltoid insertion, the muscle beginning farther proximally on the lateral than it did on the medial side of the deltoid insertion. Most of this division was situated lateral to the biceps, but distally it twisted to the rear of the latter, the fibers being pennated upon a narrow, tendinous band, which fused with the anterior border of the main insertion of the brachialis medialis.

M. epitrochleo-anconeus.—This slip does not belong with the brachial flexors, for it is innervated by the ulnar nerve, as we have

repeatedly found. Yet it is so easily mistaken either for a part of the brachialis or of the coracobrachialis, according to variations in other details, that it will be mentioned. In this chimpanzee it was quite robust, arising from the entepicondyloid ridge and inserting fleshily upon the olecranon.

Pan sp.—Left side.

M. biceps brachii, capita longum et breve.—Origin of the caput longum had three separate attachments, two as on the right side and the third almost as tendinous as, and covering, the proprius origin. Also the tendinous part of the origins of both biceps divisions was markedly shorter (more fleshy) than on the right. Upon the latter side the broadest part of the biceps (at the distal third) was 36 mm.; upon the left, 60 mm. Other details were bilaterally similar.

M. coracobrachialis medius.—This had the usual origin from the deep part of the common coracoid tendon but was slightly broader than on the right and more fleshy. The medial part of the origin continued superficial to the musculocutaneous nerve, while the remainder, or more lateral part of origin, passed deep to the nerve. The latter therefore pierced the muscle, and at this point the two parts of the muscle were about of the same mass. The part located deep to the nerve was inserted narrowly (less than 1 cm.) immediately below the latissimus tendon, but the more medial portion was continued as a narrow, fibrous band distal to the other head. With the exception of this tendon there was a hiatus of some 18 mm. between the insertions of the two parts of the coracobrachialis, and the division superficial to the nerve thereafter inserted upon the humeral shaft for a distance of some 30 mm. In the vicinity of the elbow the median nerve passed superficial to all parts of the coracobrachialis.

The remainder of the flexor details were similar to those of the right side.

Hylobates lar.—Johns Hopkins Anat. No. 261, male, with humeral length of 215 mm.; right and left sides.

M. biceps brachii, capita longum et humerale.—In this gibbon the long head had a normal origin from the glenoid border of the scapula, except that the tendon was hollow, taking a stout probe for its full length, and this tendinous cylinder was naturally split along one side where the muscle fibers began. It inserted by a strong tendon upon the radius. The other head, termed humerale rather than breve for the reason that it differed markedly from the latter and that there is no absolute assurance that it was derived from the more usual breve, took origin not from the coracoid, but by tendon from the lesser tuberosity immediately adjoining the bicipital groove. Its tendon

was several centimeters long, and upon it was directly inserted the pectoralis major, without accessory attachment to the bone. The dorsomedial border of the proximal third of the fleshy portion of this biceps head was fused with the ventral border of the dorsoepitrochlearis and medial intermuscular septum, and a slender tendon, extending along the dorsomedial border of this biceps head, fused with the other slender tendon continuing distally from the dorsoepitrochlearis, attached to the epicondyle. Below the point of fusion the more dorsal fibers of the distal part of this biceps arose from the above common tendon. The two heads of the biceps fused at about the middle of the brachium, but the humeral head again separated at the point where the insertional part of the long head became tendinous, and the humeral head, passing medially upon the antibrachium, was inserted neither by a lacertus nor upon the ulna, but powerfully and fleshily into the substance of the flexor digitorum sublimis going to the fourth and fifth fingers, the fibers of the two muscles being uninterruptedly continuous. Thus the humeral biceps and the superficial digital flexor may act as one continuous, long muscle.

M. coracobrachialis medius.—No profundus (brevis) was present and the musculocutaneous nerve passed neither through the muscle nor between it and the bone. In other words, the nerve passed entirely medial and superficial to the coracobrachialis without crossing the brachium. The muscle arose broadly and almost entirely fleshily from the coracoid. The insertion was in no part upon the latissimus tendon, as has been stated by Kohlbrügge (1890), but began upon the bone of the humeral shaft immediately adjoining the termination of the latissimus tendon along its distal third, and thence for a distance of 48 mm.

M. brachialis.—This was represented almost entirely by the internal head, origin beginning 23 mm. above and medial to the deltoid termination, which continued unusually far down the arm in this animal. Insertion was as usual upon the ulna, broad, and partly fleshy.

There was no trace of an *epitrochleo-anconeus*.

Pithecus rhesus.—Carnegie Lab. Embryol., female, with humeral length of 131 mm.; left side.

M. biceps brachii, capita longum et breve.—In the macaque the attachments were found to be as usual, origin being from the glenoid border and the coracoid, respectively, and insertion tendinously upon the bicipital process of the radius. The bicipital groove was shallow, and both bellies were relatively much more slender than in the chimpanzee. Both heads were of equal size and separable to within a

short distance of insertion. The short head was more completely integral with the coracobrachialis origin than in *Pan* or man, many of its deeper fibers arising directly from the coracobrachialis tendon and the two not separating completely until after passing the latissimus tendon. There was no lacertus fibrosus.

M. coracobrachialis, partes profunda et media.—The pars profunda was entirely distinct from the media, arising fleshily, mostly from the posterior (medial) border of the common coracoid tendon but also partly deep to the tendon and from the coracoid proper. It curved around deep to the tendon to insert upon the surgical neck of the humerus, mostly proximal to the latissimus insertion, although a few fibers overlapped the latter for a couple of millimeters, both superficial and deep to its proximal border. The pars media was very slender and small, with the musculocutaneous nerve passing between all of it and the bone. Its fibers arose from an aponeurosis upon its deep surface, which in turn was a continuation of the coracoid tendon, and it inserted upon an area but 10 mm. long beginning 23 mm. below the latissimus tendon.

M. brachialis.—This muscle was not longitudinally divisible and was relatively much less robust than in *Pan*. Origin began from an oblique line that extended from above the termination of the deltoid on the lateral aspect of the arm to a point well below the deltoid on the medial aspect, and thence straight to the fleshy insertion, which was partly upon the joint capsule but chiefly upon the ulna.

There was no *epitrochleo-anconeus*.

Cebus variegatus.—Johns Hopkins Anat. No. 1, male, with a humeral length of 78 mm.; right side.

M. biceps brachii, capita longum et breve.—The two heads had their usual origins, and the tendon of the longum was completely within the shoulder capsule, although the bicipital groove was not particularly deep. Muscle fibers developed at about the level of the latissimus tendon. Fusion of the two heads took place at the distal third of the brachium, and the common, tendinous insertion was upon the radius. There was no trace of a lacertus fibrosus.

M. coracobrachialis, partes profunda et media.—The deep or short part was large and well developed, with fleshy origin from the coracoid deep to the common tendon, and insertion upon the surgical neck of the humerus behind the latissimus tendon. In a second specimen of *Cebus* (*C. apella*, Johns Hopkins Anat. No. 2) this part of the coracobrachialis was absent.

The coracobrachialis medius split from the common coracoid tendon just below the latissimus and inserted upon the humerus, beginning about 9 mm. below the latissimus and continuing for about

8 mm. thereafter, but there was intimate connection with the intermuscular septum and the medial head of the triceps. It ended far above the epicondylar ridge, and the musculocutaneous nerve crossed the brachium deep to all of it.

M. brachialis.—This was in no degree separable into two parts and was of the usual form, its origin embracing the deltoid. Medially it arose from the humerus between a point a few millimeters above the deltoid termination and 8 mm. above the entepicondylar foramen. Laterally it extended some 5 mm. above the deltoid insertion and distally as far as the lateral condyle. The insertion upon the ulna was by a strong tendon.

M. epitrochleo-anconeus.—This was possibly, though not certainly, represented by a few fibers, which bridged the ulnar nerve. In the second specimen it was absent.

Galago sp.—U.S.N.M. No. 251756, male, with humeral length of 33 mm.; right side.

M. biceps brachii, capita longum et breve.—The long head was as usual. Over the proximal half of the brachium the short head of the biceps and coracobrachialis medius, with common origin from the coracoid, constituted a single, bipennated muscle, the two thence continuing separately. Insertion of the short head was by means of (1) a lacertus fibrosus superficially over the medial antibrachium; (2) an aponeurosis passing medially between the pronator teres and flexor carpi radialis, this undoubtedly operating upon the ulna by means of the intermuscular septum; and (3) a slender, tendinous band passing from the lateral belly of the short biceps to the tendon of the long head inserting upon the radius.

M. coracobrachialis, partes profunda et media.—The short, deep head passed from the coracoid deep to the teres major insertion, the latter being entirely fleshy and broader, both proximally and distally, than the latissimus insertion. The musculocutaneous nerve crossed the humerus entirely deep to the media division, not immediately adjoining its insertion, but quite far above it. Insertion was upon an area of the humerus from the teres major tendon to the level of the entepicondylar foramen.

M. brachialis.—This muscle was not longitudinally separable, at least with any clarity, as was the case with *Tarsius*. Otherwise it was similar in both.

M. epitrochleo-anconeus.—Origin was from the entepicondylar ridge below the level of the foramen. It was smaller than in *Tarsius*.

Nycticebus sp.—U.S.N.M. No. 142235, male, with humeral length of 54 mm.; right side.

M. biceps brachii longum.—The single head of this biceps was quite robust. It arose by a sharply defined tendon from the glenoid border at the coracoid base, passed through a well-defined bicipital groove, and inserted upon the radius only. There was no lacertus fibrosus.

M. coracobrachialis, partes media et profunda.—Common origin was shortly tendinous from a coracoid process that was unusually long. Pars profunda was short and inserted upon the surgical neck on a level with the teres major insertion, which was very broad and which extended above the latissimus tendon at this point. Pars media was entirely superficial to the musculocutaneous nerve and was exceedingly long, inserting from the teres major practically to the epicondyle. Just above the latter point the muscle divided into two slips between which passed the median nerve, which then continued to the entepicondylar foramen. The manner in which this muscle passed upon either side of the median nerve was encountered in no other simian or prosimian dissected.

M. brachialis, partes lateralis et medialis.—This muscle was almost completely divisible. No part of the medial division originated above the deltoid insertion and it was much smaller than the lateral division, which took origin not only from the humerus but also from the aponeurotic investment of the deltoid along the oblique line of its insertion. Insertion of the brachialis was upon the ulna, as usual.

No trace of an *epitrochleo-anconeus* was encountered.

Tarsius (philippinensis?).—U.S.N.M. No. 218238, male, with humeral length of 29 mm.; right side.

M. biceps brachii, capita longum et breve.—These heads had the usual origins from the glenoid border and the coracoid, respectively, and both inserted upon the bicipital process of the radius; but they were entirely separable throughout their length. The same condition was encountered in *Tarsius saltator* (Johns Hopkins Anat. No. 169, female). Distally the long head was situated fairly anterior to the short one (there was no twisting), and the insertion of the latter was slenderly tendinous, but the former was chiefly fleshy and was the broader throughout its length. There was no sign of a lacertus fibrosus.

M. coracobrachialis, partes profunda et media.—The pars profunda may be said to have had no connection with the common coracoid tendon but arose independently and fleshily from the coracoid, thence extending directly to the surgical neck of the humerus and inserting as far as the distal border of the teres major tendon (in this animal quite separate from the latissimus tendon) and entirely deep to the tendon. The pars media split cleanly from the biceps breve some 6 mm. from the origin. The musculocutaneous

nerve passed entirely deep to the muscle, and insertion was upon the shaft from a point immediately beyond the latissimus tendon to a situation upon the epicondyloid ridge just short of the entepicondylar foramen, and hence not to the epicondyle proper.

M. brachialis, partes lateralis et medialis.—The brachialis was primitively and entirely separable throughout its length. The more medial head originated fleshily from the humeral shaft just beyond the pectoralis insertion, while origin of the lateral head was chiefly tendinous from the extreme proximal part of the surgical neck. Insertion was by two tendons upon the ulna.

In *Tarsius saltator* the brachialis could not be clearly separated into two parts, there being only slight indications of a longitudinal splitting. The insertion was by a single tendon upon the ulna.

M. epitrochleo-anconeus.—This small slip, innervated by the ulnar nerve, arose from the epicondyloid ridge below the level of the entepicondylar foramen, and its conformation was such that it would be extremely easy to mistake it for a condylar extension of the coracobrachialis medius.

Didelphis virginiana.—Johns Hopkins Anat. No. 117, male, with humeral length of 57 mm.; left side. An opossum was dissected in order to present the arrangement of the brachial flexors in a primitive marsupial.

M. biceps brachii, capita longum et breve.—The long head arose from the supraglenoid border of the scapula by a tendon that passed through the bicipital groove and that seemed to be at least partially within the capsule of the shoulder joint. The short head took origin by fibers partly muscular and partly tendinous, from the inner side of the tip of the coracoid process. This head crossed in front of the caput longum at the elbow and inserted upon the radius by a strong tendon. The long head, passing inward, united with the brachialis to insert by a tendon upon the ulna. It is thus apparent that the two heads were separate for their entire length. There was no lacertus fibrosus.

M. coracobrachialis profundus.—Since the medius division was entirely absent, the coracobrachialis was represented only by the short or profundus element. This was a large and well-developed muscle. Its origin was by a tendon from the inner and under aspects of the coracoid process. Broadening and developing muscle fibers, it inserted upon the medial side of the neck of the humerus above and behind the tendons of the teres major and latissimus dorsi.

M. brachialis.—This arose strongly from the outer side of the humerus as high as the level of the latissimus insertion and from

the anterior surface of the bone as high as the prominence marking the end of the deltoid ridge, continuing along the outer side of same for a few millimeters. These two origins were partially separable almost as far distally as the tendon. The insertion was in common with the long biceps head by a common tendon on the ulna.

There was no *epitrochleo-anconeus*, but just dorsal to the region where this muscle might be expected to occur there was a *M. anconeus internus*, which was served by the radial nerve and passed from the posterior portion of the epicondyle to the olecranon. The position of this slip, which is a triceps element, served in this case to distinguish it from a true *epitrochleo-anconeus*, originating from the anterior epicondyle; but in some mammals (rodents) this topographical difference seems not to exist, and identification is determinable on innervation alone.

In addition to the specimens described above, we have examined the brachial flexors of certain other primates: The Old-World monkeys *Pygathrix entellus* (U.S.N.M. No. 25215), *Papio hamadryas* (Johns Hopkins Anat. No. 149), and *Lasiopyga pygerythra* (Johns Hopkins Anat. No. 148); the New-World monkeys *Ateles geoffroyi* (Johns Hopkins Anat. No. 190), *Alouatta seniculus* (Johns Hopkins Anat. No. 13), *Saimiri sciureus* (Johns Hopkins Anat. No. 8), *Aotus zonalis* (2 specimens, Johns Hopkins Anat. Nos. 237 and 244), and *Oedipomidas geoffroyi* (Johns Hopkins Anat. No. 234); and the lemur *Perodicticus potto* (Johns Hopkins Anat. No. 283). These do not depart in any significant respect from the other specimens of Old and New World monkeys and lemurs described, and detailed accounts of them are therefore omitted. Certain arrangements in the musculature and nerves of these primates are, however, referred to in the succeeding discussion.

DISCUSSION

The intrinsic musculature of the brachium comprises only the so-called extensors of dorsal innervation—the triceps complex—and the so-called flexors of ventral innervation served by the musculocutaneous nerve. It is only with the latter group that we are at present concerned, although for convenience we have also mentioned the epitrochleo-anconeus. The latter is served by the ulnar nerve and is clearly a derivative of the antibrachial flexor carpi ulnaris element, although some authors have erroneously classified it with the triceps group. Its fibers have secondarily migrated above the elbow or else represent a primitive humeral origin of the ulnar flexor. It is not clear which of these interpretations should be regarded as the more probable.

The brachial flexor group as it now occurs in mammals comprises the so-called biceps brachii, coracobrachialis, and brachialis. As they are all served by the musculocutaneous nerve, they should be regarded as originally a single genetic complex, which later differentiated into the existing elements, and it is more difficult to assign to each its precise phylogenetic position than would be the case if the group were innervated by two or more nerve components.

It seems likely that the ideally primitive differentiation of this complex into separate elements was upon the plan of a single, long, or two-joint flexor from the shoulder to the antibrachium (coraco-antibrachialis), and two short or one joint flexors, a proximal one from the shoulder to the humerus (coracobrachialis) and a distal one from the humerus to the antibrachium (brachio-antibrachialis). As there is still controversy over the question of whether the present mammalian coracoid actually represents the primitive coracoid or the procoracoid, it seems futile to speculate seriously as to the exact point upon the primitive shoulder girdle from which arose the two ideally primitive flexors of the brachium that were attached thereto.

The long flexor and the more proximal of the short flexors above referred to were the precursors of the biceps and coracobrachialis. That the short biceps, from the coracoid, represents a more primitive arrangement than the long head, with its origin from the bicipital tubercle upon the glenoid border of the scapula, is indicated by the fact that the long head, as such, is apparently found only in those vertebrates higher than the reptiles.

Whatever was precisely the original arrangement of these two flexors, there accordingly seems to have been a later stage during which they were confined to an exclusive origin, both of them from the coracoid process of the scapula. At that time, therefore, they probably had much in common, and it is likely that the part representing the biceps inserted upon both radius and ulna, while that representing the coracobrachialis inserted upon the humeral shaft. Because of their community of origin, however, it is possible that some interchange of fibers took place as specialization occurred. In other words, some of the true biceps fibers, partially fused with the coracobrachialis, may secondarily have developed attachment to the humerus, thereby increasing the area of coracobrachialis insertion, while some of the true coracobrachialis fibers could conceivably have separated and taken on an elongated form that would later give them considerable resemblance to a biceps division. And their innervation would not help us to segregate them according to their actual derivation.

At least the assumption may be granted, however, that the brachial flexor now passing from the coracoid to the forearm (caput breve)

represents a portion of the original biceps element, from which was later derived that element (*caput longum*) almost invariably encountered in mammals, from the glenoid border to the forearm. Similarly it must be conceded, for convenience at least, that those elements passing from the coracoid to any part of the humerus represent the coracobrachialis.

Representing the third primitive flexor of the brachium is the brachialis, the more distal of the two short flexors. Although the mass may be either longitudinally divisible or single, and the origin may migrate up or down the humerus, it is always composed of fibers arising from the humeral shaft and inserting upon the ulna. In its idealistically primitive form its plan probably consisted of an origin from the entire humeral shaft, and insertion upon both anti-brachial bones.

M. biceps brachii.—As the long head of the biceps is absent in all vertebrates below the reptiles, we may presume that it was a later development from the short or coracoid head. This being the case, it is somewhat unexpected to find that in mammals the long head is by far the more conservative, apparently being always present. It arises from the bicipital tuberosity, or *tuberositas supraglenoidalis*, of the scapula at the lateral base of the coracoid process. It passes over the head of the humerus, either partially or completely deep to the shoulder capsule, and through the bicipital groove, or *sulcus intertubercularis*, between the greater and lesser tuberosities of the humerus. This groove is shallow or deep. The muscle ends invariably in a tendon, which inserts upon the bicipital or radial tuberosity of the radius, or the adjoining part of the ulna, or both. The insertion has fair but not complete group constancy. In marsupials the short head always goes to radius, the long head to ulna (Leche, 1900). Among primates, on the other hand, it is the rule for both heads to have a common tendon of insertion upon the radius alone. In many rodents there is but a single head, and where this is the case the tendency seems to be for the insertion to be ulnar; but in the seal and sea lion the single head has the radial attachment. At any rate the attachment of this head is always firmly upon the bone.

Among primates, apparently only the lorises (*Nycticebus*, *Loris*, and *Stenops*) normally have but a single biceps head, of the long variety (Owen, 1868; Murie and Mivart, 1872; Zuckerkandl, 1898; Howell and Straus), yet even in these animals a short or coracoid head may occasionally be present (see Murie and Mivart, 1872).

Where a second head is present this usually arises from the coracoid process and constitutes the regular *caput breve*. In reality there may be considered to be a common tendinous origin of this head and the coracobrachialis, from the superficial aspect of which

the tendon of the short biceps may usually separate quite high up at times (as in *Pithecus*), with some of the biceps fibers arising from the coracobrachialis tendon below the point of separation. More rarely the fission does not occur until quite at the middle of the brachium (as in *Galago*).

Usually there is fusion of the long and short heads of the biceps, most frequently at about the middle of the brachium or a bit below (as in *Pan*, *Papio*, *Pygathrix*, *Cebus*, *Aotus*, and *Perodicticus*), or occasionally this does not take place until within a short distance of the insertion (as in *Pithecus*, *Lasiopyga*, and *Ateles*), and rarely the two heads are entirely separate throughout their length (as in *Tarsius* and *Didelphis*). In man the two heads of the biceps usually fuse well above the tendon, but at least in some of those cases in which the two are separable as far as the tendon it is easily demonstrable that both heads are concerned with the formation of the radial bicapital tendon.

Whereas insertion of the longer biceps is invariably on bone, that of the shorter head is more variable, going in some cases to the radius, to the ulna, or having a variety of fascial attachments. The best known of the latter is represented by the lacertus fibrosus or semilunar fascia as of man. This takes the form of a tough fascial connection between chiefly the short biceps and the medial anti-brachium, concerned with certain of the antibrachial flexors. This we have found to be indubitably present in such primates as *Pan*, *Ateles*, *Aotus* (2 specimens), and *Galago*; absent in *Hylobates*, *Pygathrix*, *Papio*, *Pithecus*, *Lasiopyga*, *Cebus* (2 specimens), *Saimiri*, *Nycticebus*, *Perodicticus*, and *Tarsius* (2 specimens). From the condition typical of man there are found several fascial variations. In *Galago*, for instance, we found that there was not only a superficial lacertus as well as tendinous attachment of the short head to the radial insertion of the longum but in addition a fascial band that was intermediate in position between the other two and that passed deep between the pronator teres and flexor carpi radialis, probably operating directly upon the ulna by means of the intermuscular septum. On the other hand, in *Hylobates lar* the shorter biceps head, analogous and possibly homologous to the usual caput breve, diverged from the common biceps mass to fuse completely with the substance of the flexor digitorum sublimis, the fibers of the two being perfectly continuous and acting in some respects as a single muscle extending from shoulder to digits. It is easy to see how such a situation could have developed from a lacertus, or how insertion by means of the latter could shift to intermuscular septa and so reach the bone.

In a chimpanzee dissected by Grönroos (1903), the bicipital slip to the forearm fascia was fleshy, thereby contributing a "lacertus carnosus." Duvernoy (cited by Sommer) and Sommer (1907) found quite similar arrangements in their gorillas, as did Duckworth (1915) in *Lemur*. This condition, however, appears to be quite different from the arrangement in gibbons. In general, the lacertus fibrosus is much more frequently absent in prosimians, monkeys, and anthropoids than it is in man.

In man there may be accessory heads to the biceps, usually concerned with the caput longum, to the number of three. Very rarely are there this many, but it is not very unusual to find at least one. Such an extra head does not mean an extra muscle, of course, but only that one head of the biceps has more than one attachment at origin. These extra heads may arise in various ways; for example, very frequently from the capsule of the shoulder joint or from the shaft of the humerus itself.

We were fortunate in finding a condition of the former sort in the chimpanzee that we dissected. Upon the right side the origin of the caput longum had two attachments, one proper and the other from the capsule of the joint, both fusing some 60 mm. below the humeral head. Upon the left side there were two extra attachments to the capsule.

In one specimen of *Aotus* (Johns Hopkins Anat. No. 237) we found in the left arm what was apparently a humeral biceps head. This arose from the medial edge of the bicipital sulcus, immediately adjacent and lateral to the insertion of the coracobrachialis medius, beginning a few millimeters above the distal border of the latissimus dorsi tendon and continuing for a short distance below. This muscle was smaller than either of the two usual biceps heads, both of which had their customary attachments. The exact distal connections of this extra muscle could not be ascertained because of the fragile condition of the tissues of this specimen. Accessory biceps heads with origin very similar to that occurring in this *Aotus* appear to be not infrequent in man, as observed by us and others in the dissecting room. Thus among 37 arms (23 negro, 14 white), representing 20 bodies (12 negro, 8 white), in which this detail was particularly sought, we found an accessory humeral head occurring six times (5 negro, 1 white), and an accessory capsular head once (negro). Testut (1884) has reported the occurrence of a humeral biceps head in 31 out of a total of 299 subjects, all of which were presumably white. Our own figures in this connection suggest that accessory humeral heads may occur more frequently in negroes than in whites. Naturally, however, our data are as yet too meager for

any emphasis to be placed upon this point. These humeral heads, although fleshy, were usually rather weakly developed. Origin was always above the middle of the humerus lateral to and coextensive with the insertion of the coracobrachialis medius; while insertion was into the posteromedial aspect of the common biceps mass just above the elbow.

The occurrence of a humeral biceps head in *Aotus*, as mentioned above, should not be regarded as normal for the genus, however, for this extra muscular slip was not present in the other arm, nor in the upper extremities of an additional specimen (Johns Hopkins Anat. No. 244) that we investigated. Nor does the presence of accessory biceps heads in our chimpanzee represent the normal condition in this animal. In fact, accessory heads for the biceps would seem to occur quite infrequently in primates other than man and gibbons. Testut (1884) described an extra or capsular head in a *Cercopithecus* (= *Lasiopyga*). Chudzinski (cited by Kohlbrügge, 1897) found a humeral head in two out of five orang-utans that he studied. This extremely low frequency of extra heads in monkeys is worthy of note, especially in view of Grönroos's (1903) speculations concerning the evolution of the human biceps. This theory will be considered subsequently.

In some respects these accessory biceps heads may be largely fortuitous, although possibly atavistic,¹ but it is at least shown that this detail readily responds to variational stimuli. If it be in response to some need for a humeral attachment, then a continuation and strengthening of the stimulus might well result, finally, in the migration of a part, or indeed the whole, of the primitive coracoid head to the humerus. This, we are inclined to think, may be just what has happened in the case of *Hylobates*. In the specimen of the latter dissected by us the long head had, immediately adjoining, another head, which in all respects was comparable to a caput breve except for the fact that origin was strongly from the lesser tuberosity of the humerus immediately adjacent to the bicipital groove and not at all from the coracoid. This would appear to be the usual arrangement in the Hylobatidae. Though this assumed migration of the caput breve was complete in our gibbon, it appears to have been incomplete in other instances. For example, the rodent *Viscacha* was found by Parsons (1894) to have, in addition to a normal longum and breve, just such a humeral head, but from the greater instead of the lesser tuberosity. Kohlbrügge (1890) found similar conditions in *Hylobates leuciscus*, but in *H. syndactylus* the cora-

¹ The accessory biceps head in our chimpanzee, arising superficially from the capsule, and the comparable conditions occurring in man might be interpreted as indicating transitional stages in the migration of the long head from a coracoid to a supraglenoid origin.

coid head was vestigial, and in *H. agilis* entirely absent. The assumption of complete or partial migration of the coracoid head in *Hylobates* is strengthened by the fact that in the occasional instances in which both coracoid and humeral heads occur in the same specimen of gibbon, the former, according to data collected by Grönroos (1903), is usually weakly developed. But Grönroos did not consider the humeral head (which he termed caput tuberculo-septale) of the Hylobatidae as homologous with the usual coracoid head, but rather that the two are distinct structures, of which as a rule only one develops; for example, in man the coracoid and in the gibbon the "tuberculo-septal" head. This assumption is hardly justified by comparative anatomical facts, despite its ingenious application by Grönroos in attempting to explain the accessory biceps heads in man.

Really the most interesting and peculiar thing about the condition in *Hylobates* is that the pectoralis major is inserted directly upon the tendon of origin of this caput humerale of the biceps.² This is very significant. By this means flexion of the pectoralis not only acts through the biceps, but continuously as far as the wrist by virtue of biceps-flexor digitorum sublimis fusion. If the pectoral thus acted upon a biceps with long tendon from the scapula the effect might be much less efficient, because a longer tendon would give more slack than one firmly anchored to the lesser tuberosity. One should note that this action of the pectoral through the biceps is more effective when the gibbon arm is elevated sideways, thus putting the pectoral under tension, than when elevation is accomplished in the sagittal plane.

This does not exhaust the interesting details of the gibbon biceps, however. The dorsomedial border of the proximal third of the fleshy portion of the humeral head was fused with the ventral border of the dorsoepitrochlearis, and a slender tendon, running along the dorsomedial border of this biceps head, fused with the slender tendon continuing to the epicondyle from the dorsoepitrochlearis. It thus appears that when the pectoralis is acting upon the antibrachium through the humeral biceps, the fusion of the latter with the dorsoepitrochlearis prevents the biceps from springing forward unduly and thus weakening the action. Grönroos (1903) has also discussed the action of such a muscle complex; that is, from latissimus dorsi through latissimo-condyloideus (sive dorsoepitrochlearis) through caput tuberculo-septale (sive caput humerale) to

² Grönroos apparently doubted that the humeral head ever arises in *Hylobates* from the pectoralis major tendon, as some authors have stated, and in his specimens he interpreted the situation as fusion of the two structures. In our specimen, at least, there was no shadow of doubt that the pectoralis major was actually inserted upon, or into, the tendon of the humeral head.

flexor digitorum sublimis. He indicated that such an arrangement is important to the gibbons in making their tremendous leaps from branch to branch.

This curious and apparently unique specialization of the brachial flexors in the gibbon appears to us more as a secondary adaptation of purely functional significance, and we are of the opinion that little or no phylogenetic import should be attached to it. In this view we disagree completely with Grönroos, who concluded that the three great apes, the gibbons, and man all passed through a stage in which the biceps brachii possessed three heads—supraglenoid, coracoid, and tuberculoseptal. His ingenious theory, based chiefly upon the positions of supernumerary humeral biceps heads (which he regarded as remnants of the caput tuberculoseptale) appears to us as unconvincing, for consideration of the biceps morphology in the various groups of primates does not lend support to his views.

Mention should also be made of other theories concerning the phylogeny of the biceps. Humphry (1872) homologized the two heads of the biceps of man with the entire coracoradialis (caput longum) and the outer portion of the coracobrachialis longus (caput breve) of the urodele amphibian *Cryptobranchus japonicus*. Welcker (1878) found that in some mammals (as the tapir) the tendon of the caput longum lay outside of the capsule. In other forms the tendon exhibited various degrees of encapsulation. He likewise found a gradual ontogenetic migration within the capsule occurring in some forms (beaver, *Cebus*, man), and therefore came to the conclusion that the tendon of the caput longum has secondarily migrated within the capsule of the shoulder joint. This supports other comparative evidence that indicates that the supraglenoid origin of the long head is a relatively late phylogenetic acquisition. Fürbringer (1876) was inclined to the view that the caput longum is homologous with the entire coraco-antibrachialis of reptiles, the caput breve being derived from the coracobrachialis. Eisler (1895) secondarily derived the caput breve from both the coracoradialis and coracobrachialis longus of urodele amphibians. He did not definitely commit himself in respect to the caput longum, but listed three possible explanations: (1) It is a part of the coracoradialis proprius, which has gained attachment to the scapula; or (2) it is a part of the caput breve, which has become attached to the ligamentum humero-radiale (sive capsuloradiale), which is itself the degenerated tendon of the original coracoradialis proprius; or (3) it represents a combination of the two preceding processes. Lubosch (1899) regarded the caput longum as a derivative of the accessory or humeral head of the coraco-antibrachialis of reptiles.

Despite the differences in these theories there seems to be general agreement that the supraglenoid origin of the long head is a secondary occurrence. As stated earlier in this paper, we are personally inclined to favor the theory that derives both biceps heads from a primitive coraco-antibrachial flexor, the outer portion of which has migrated to the supraglenoid border, while the inner has retained its coracoid origin, possibly strengthened by additional fibers from the primitive coracobrachialis.

Attention must be given to the possible significance of the lacertus fibrosus. Grönroos regarded this as a vestigial structure, the remains of the fleshy ulnar extension of the supposedly primitive caput tuberculoseptale of the gibbons. The frequent absence of the lacertus fibrosus in the three great apes, together with the fact that supernumerary biceps heads apparently occur less frequently in these animals than in man, led him to the conclusion that the biceps muscle in all three anthropoids is more specialized than in man. It seems that he was probably correct in asserting that retention of the lacertus is more primitive than is its loss. There is, however, no reason for regarding the condition in the gibbons as other than an extreme specialization. The lacertus possibly represents a portion of the original ulnar insertion of the primitive coraco-antibrachial flexor. At least the conditions in our *Galago* are extremely suggestive of such an interpretation.

M. coracobrachialis.—In man, where ordinarily there occurs but one well-defined coracobrachialis element, inserting upon the middle of the humeral shaft, there is no difficulty met with, or at least any question that may occur does not greatly worry the human anatomist. But in many other mammals the conditions that occur in this muscle have been extremely puzzling, which is largely attributable to the loose manner in which the term "longus" has been used for an occasionally present distal extension.

Comparative anatomists usually follow Wood (1867) when differentiating parts of the coracobrachialis. This authority recognized a pars brevis, or coracocapsularis, arising from the coracoid and inserting upon the neck of the humerus above the tendon of the latissimus dorsi, a pars media or propria, inserting below the latissimus, and a pars longa. In regard to the last his statements were at times ambiguous, and he seems to have used the term indiscriminately to designate both the distal part of the pars media, when this extended down the shaft to a marked extent, and another structure, totally distinct in conformation. The latter has probably been found by few anatomists, and by the same token it is probably poorly understood, so that subsequent writers have readily fallen in with the same ambiguity of Wood's paper.

As it is likely that all parts of the present coracobrachialis are derivatives of one original component, the terms by which we designate the several divisions that may occur are not of paramount importance, but at least they should be uniformly applied. For the reason that there has been so much confusion in the treatment of the so-called long division, we prefer to abandon this term in favor of "superficialis."

Occasionally in man there occurs a coracobrachialis brevis, or "profundus," as we designate it (also termed coracocapsularis, coracobrachialis superior, coracohumeralis superior, and rotator humeri). Eisler (1895) saw it at least twenty times in nine years, and Wood reported that he had met with it four times. Among 39 arms (24 negro, 15 white), representing 20 individuals (12 negro, 8 white), examined carefully for this detail, we found a coracobrachialis profundus in three instances (2 negro, 1 white). In each case the nerve supply had unfortunately been destroyed before we saw the muscle. These three examples exhibited certain differences in their morphology, and it seems worth while to describe them in some detail.

In the left arm of an extremely muscular male negro a coracobrachialis profundus arose from near the tip of the coracoid process as a broad and fleshy slip, which inserted above and behind the latissimus dorsi tendon. The coracobrachialis proprius (or medius) exhibited its customary relations, and it was pierced as usual by the musculocutaneous nerve. Upon the right arm the profundus element was entirely absent.

The second example of this muscle was found in the right arm of a well-developed male negro. It arose from near the anterior end of the coracoid process and continued fleshily to insert above and behind the latissimus dorsi tendon; and likewise by a short, tendinous extension upon a second, long tendon, which arose from the surgical neck of the humerus and which continued distally to pass uninterruptedly into the medial intermuscular septum. The coracobrachialis proprius was quite normal and was pierced by the musculocutaneous nerve. There was no trace of a coracobrachialis profundus upon the left arm.

The third occurrence of this slip was upon the right arm of a male white. It was unusual in that it arose not from the coracoid tip, but broadly and fleshily from the medial border of this process for a considerable distance. It inserted above the latissimus dorsi tendon. The coracobrachialis proprius was normal and was pierced by the musculocutaneous nerve. The left arm exhibited no trace of a profundus element.

In primates the coracobrachialis profundus is a short and relatively broad, entirely fleshy slip arising either from the deep part

of the common coracoid tendon, or else from the coracoid proper posterior to the tendon. Insertion is invariably upon the neck of the humerus either entirely proximal to, and back of, the tendon of the latissimus dorsi, as we found, for example, in the potto (*Perodicticus*), or else overlapping the tendon by only a couple of millimeters, as we found in the macaque (*Pithecus*). Occasionally it is extremely slender, as in the spider monkey (*Ateles*) that we dissected.

According to Parsons (1898) this slip is present in some genera and absent in others of the marsupials, edentates, cetaceans, ungulates, rodents, carnivores, insectivores, and primates, and is always absent in bats. Parsons and other authors give long lists of the genera concerned, but there is no need to repeat these lists here. Among the primates, however, Parsons stated that it is present in more than 30 per cent of chimpanzees but is less frequent in gorillas and orangs, while it is always present in lemurs. Keith (cited by Parsons, 1898) reported it as rarely absent in cynomorphous monkeys.

A survey of the available literature reveals the fact that this muscle is present regularly in lemurs and *Tarsius*, is usually present in both catarrhine and platyrrhine monkeys, and occurs only very occasionally in anthropoid apes other than the chimpanzee.³

Apparently, then, this structure is present in some genera of all primate families but is absent in others, and so it is not a very important phylogenetic index; but whether its significance is purely functional it is difficult to say. Parsons (1898) suggested that the suppression of this muscle might be attributable to, or correlated with, the setting back of the shoulders. In general, however, it is usually present in the more primitive primates and tends toward complete disappearance in the so-called "higher" forms. The important point is that when it occurs at least most of its fibers are located entirely proximal to, and usually deep to (behind), the latissimus tendon. Therefore it is usually separated from the pars media by the latter tendon.

The coracobrachialis medius, or "proprius," always originates from the coracoid, and it can always be identified by this fact, together with the circumstance that it inserts upon the shaft of the humerus, although occasionally the relationship of its terminal fibers with those of the medial triceps is extremely close (as in *Cebus* and *Perodicticus*). Otherwise it is quite variable. Origin is usually

³ According to the data that we have collected from the literature and to which we have added the results of our own dissections, the coracobrachialis profundus (brevis) has been found in 1 out of 10 gorillas (10 per cent), 4 out of 13 chimpanzees (31 per cent), and 1 out of 10 orang-utans (10 per cent). It was not found among 8 gibbons. We ourselves have met this structure, but in various degrees of development, in *Pithecus*, *Papio*, *Lasiopyga*, *Cebus* (first specimen), *Saimiri*, *Ateles*, *Aotus* (two specimens), *Oedipomidas*, *Galago*, *Nycticebus*, *Perodicticus*, and *Tarsius* (two specimens), but not in *Pan*, *Hylobates*, *Pygathrix*, and *Alouatta*, nor in our second specimen of *Cebus*.

tendinous, the common tendon of this and the short head of the biceps being separable into two tendons a short distance from the coracoid. Occasionally fission takes place somewhat farther down the arm (as in *Saimiri*), or the tendon does not divide at all, the fleshy part of both biceps and coracobrachialis originating from the common tendon in a bipennated manner (as in *Perodicticus* and *Galago*), the two being separable only over the distal half of the brachium (as in *Galago*). Or, again, in many rodents that have this muscle in depauperate form the fibers of the coracobrachialis originate directly from the single tendon of the caput breve of the biceps. At times in man we have found the more proximal fibers of the coracobrachialis medius inserting not upon the bone, but directly upon a flat tendon (internal brachial ligament of Struthers) that arises from the upper part of the humeral shaft and eventually disappears at the point where the medius begins its osseous insertion. There was a suggestion of such an arrangement in our specimen of *Lasiopyga*. Testut (1884) has suggested that this long tendinous band may be a possible vestige of the coracobrachialis longus (of Wood). It appears to us, however, as extremely unlikely that this could represent the coracobrachialis longus (superficialis) as recognized by us. The band is applied to the deep surface of the coracobrachialis proprius, whereas the pars longa, when present, lies superficial to all the muscles of the brachium except the dorsoepitrochlearis. This feature of the pars longa will be discussed subsequently.

Another feature that is extremely variable is the position of the musculocutaneous nerve in relation to the muscle. This nerve may cross the brachium above and beneath the whole muscle, or pierce it, or pass entirely below it in a manner that appears indiscriminate, not only in closely related species but also in individuals of the same species. In illustration of such variation we may cite the conditions in 32 adult white and negro cadavers that we have examined in the dissecting rooms of the Johns Hopkins University Department of Anatomy. In all but five cases, both sides were dissected. Out of 59 arms, the musculocutaneous nerve pierced the coracobrachialis in 55 instances and passed below (superficial to) the muscle in 4 (on the left side in three cadavers and on the right in the other). In those in which piercing occurs there may be as little as approximately one-sixth of the muscle deep to or above the nerve, or practically all of it, but the average is about one-half of the entire muscle located above the nerve. This probably represents with a fair degree of accuracy the condition in man (subject to an unknown degree of racial variation). Apparently it is only very rarely that the nerve passes deep to the entire muscle mass in man, but in mammals below the anthropoids this is the usual condition. In fact Parsons, than

whom no one has had more extensive experience with the musculature of the lower mammals, has stated that he has never found the nerve piercing the muscle in anything but primates.

Judged from our own dissections and from a consideration of the data given by Kohlbrügge (1897) and Bolk (1902), this feature of piercing or nonpiercing is extremely variable in monkeys and lemurs. It seems to vary not only within a single genus but perhaps even within a species. We ourselves have found the musculocutaneous nerve piercing the coracobrachialis medius only in the left arm of our chimpanzee, in *Pygathrix*, *Lasiopyga*, and *Perodicticus*. In the right arm of the chimpanzee, as in both extremities of our *Hylobates*, the nerve passed entirely superficial to the muscle. No piercing of the muscle was found in any of our other specimens of monkeys or prosimians, in which the nerve passed entirely deep to (above) all the fibers of the coracobrachialis medius, between this muscle and the bone. This arrangement obtained regardless of the absence or presence of the coracobrachialis profundus. Apparently the nerve usually pierces the coracobrachialis medius in the great apes, though possibly with less frequency than in man, at least in the chimpanzee.

Many authors, however, have evidently considered that when the nerve pierces the muscle in primates the portion superficial to the nerve and the more distally situated is a pars longa. This treatment we regard as unfortunate. The feature of piercing or nonpiercing and the proportions of the muscle parts involved are too variable to carry much phylogenetic or taxonomic weight, although for convenience it is legitimate to term the part of the coracobrachialis medius distal to the nerve by some such appellation as the distal portion, and the deeper division the proximal one. The latter we regard as never homologous to the coracobrachialis profundus or brevis, in spite of the fact that where the latter occurs the musculocutaneous nerve usually, if not invariably, passes entirely deep to the pars media, for the part of the latter above the nerve, where piercing occurs, is almost always well segregated from the area of insertion of pars profunda. That this may not invariably be the case is indicated by the mention by Parsons (1898) that continuity has been observed between the two in *Gorilla*. Also, pars media may begin to insert higher than the distal border of the latissimus tendon, as in the gibbon; not, we found, upon the tendon itself, as stated by Kohlbrügge (1890), but just adjoining its termination.

The same may be said of the part of the coracobrachialis medius that lies distal to the point of piercing. This may reach barely to the middle of the humerus (as in *Aotus*), or it may continue well down the entepicondylar ridge, an arrangement that is often or usually the case in those mammals having an entepicondylar foramen (as in *Tarsius*, *Nycticebus*, and *Galago*). There is no justification

for calling this longer type of muscle a *pars longa*, for it is apparently strictly homologous with the shorter type. And here lies the ambiguity. It is usually impossible to tell whether an author, using the term *coracobrachialis longus*, has reference merely to the part of the muscle distal to the musculocutaneous nerve (where this pierces), to that part lying distal to the middle of the humerus (where this position is occupied), or to an entirely separate slip, as hereafter defined. Furthermore, when the *coracobrachialis* is distally extensive one should exercise great care in dissecting the insertion free from a possible *epitrochleo-anconeus*. Where the statement is made that the former continues quite to the epicondyle we are suspicious that the two have not been properly differentiated—an error very easy to make.

When the *coracobrachialis medius* is not pierced by the musculocutaneous nerve the muscular belly is usually not separable into two distinct parts. If piercing does occur, there may be complete separation or only partial.

The portion of the *coracobrachialis* termed *pars longa* has caused us much perplexity, as explained above, for the reason that it is often impossible to be sure of the exact conditions found by an author. It is certain that frequently nothing was meant but an unusually long *pars media*, while it seems equally apparent that such authors as Wood and Parsons applied the same term indiscriminately to two different structures. Our attention was focused on this point by finding upon the right side of a chimpanzee a rather slender anomalous muscle that arose from the coracoid dorsally adjacent to the short biceps origin, and in a position corresponding to the more usual dorsal border of the *coracobrachialis medius*. This muscle was superficial to all others but the *dorsoepitrochlearis*, and maintained this position, by a slender tendon, quite to the entepicondyle, thus passing superficial to the median nerve. Its exact homology we can not state. It is probably a derivative of the primitive *coracobrachialis*, but the question whether it is a relic of a muscle invariably present in some remote ancestor, or whether an anomalous variation without particular phylogenetic significance, can not now be answered, for the reason that although a precisely similar structure has been reported and figured in widely unrelated mammals, we do not know whether it is invariably present in all individuals of those species.⁴

⁴This superficial portion of the *coracobrachialis* was very probably included in the ground plan of the brachial flexors of tetrapod vertebrates. Thus Humphry (1872) states in regard to the *coracobrachialis* that "in Amphibians, Reptiles, and Monotremes there is commonly a third segment, an inferior *coracobrachialis*, which extends to the ulnar condyle; and the brachial artery with the median nerve passes between it and the middle *coracobrachialis*" (p. 158). Judged from its superficial position in respect to the median nerve, this muscle described by Humphry may well be considered as homologous to the superficial *coracobrachialis* of our chimpanzee.

The muscular slip described by Fick (1925) in his chimpanzee "Tschego" is very probably homologous to the muscle in our animal. [In Fick's animal it had a tendinous origin from the upper part of the coracobrachialis (medius) and passed over the brachial vessels and nerves to insert on the anterior border of the dorsoepitrochlearis (sive latissimo-tricipitalis).]

For the reason that the term "coracobrachialis longus" has been so loosely and ambiguously applied, we prefer to discard this name completely and to call this slip, clearly worthy of a distinctive appellation, a coracobrachialis superficialis, to designate a muscle from the coracoid to the medial epicondyle that bridges over and passes superficial to all the brachial nerves and other muscles, except the dorsoepitrochlearis. We can, for the present, be certain that it has been found only in those mammals for which adequate illustrations have been presented, or else in those rare instances when an author has stated specifically that the muscle is entirely superficial to the median nerve.

Parsons (1898) gave a considerable number of genera in which he found that "the longus is best developed," but on the same page mentioned that the only instance in which he had found the muscle superficial to the median nerve was in the tree porcupine *Sphingurus*, for which he gave a good illustration. Likewise Wood (1867) had a figure of *Ornithorhynchus*, which seems to have had a similar arrangement. But the same author presented another figure in which this muscle is indubitably assigned to man, in which he stated that this "slip is not uncommonly found." There would seem to be some serious question here. Le Double (1897) lists but one certain instance of its occurrence in man, and it is almost certain that had it been found in any instance by a student of the department of anatomy of the Johns Hopkins University Medical School during the past 15 years the fact would have been called to the attention of one of the staff. During this time several hundred cadavers have been dissected, and no gross anatomist now on the faculty has ever seen it in man.

M. brachialis.—Whether the ideally primitive brachialis actually consisted of a single muscle going to both radius and ulna or of two slips, the evidence seems to point to the probability that the condition of two distinct slips is more primitive than that of complete fusion, as now often found in man and other mammals. The insertion in mammals is usually upon the ulna, occasionally upon the radius, and rarely on both antibrachial bones (Leche). In such a basically primitive primate as *Tarsius* there was in one specimen (*T. philippinensis*?) a lateral head from the surgical neck of the humerus entirely distinct from a medial head, arising just distal to

and partly medial to the deltoid insertion. In *Galago* the origins were similar, but the two heads were not clearly separable, which may have been partly attributable to the poor condition of the alcoholic specimen. Broadly speaking, this is the general condition in many of the lower mammals, such as insectivores and rodents. A more advanced type, as typified in anthropoid apes and some of the monkeys, is either for the lateral head to originate a trifle above the termination of the deltoid insertion, and for the medial head to begin just below this point, or else for the origin of the two to form a V partly embracing the end of the deltoid. Very often, both in man and other primates, the brachialis is partly separable longitudinally (for example, in *Pan*, *Papio*, *Saimiri*, *Aotus*, and *Nycticebus*) downward from the apex of the deltoid insertion. It is clear that its logical treatment should call for the recognition of a pars lateralis and a pars medialis. Each part is served by branches of the musculocutaneous nerve, but frequently the lateral head receives in addition a fine twig of the radial nerve, indicating that with this head of the brachialis there may at times be incorporated some relatively slight element originally derived from the extensor complex. Occasionally the muscle may be represented almost entirely by the medial head, as in our gibbon (*Hylobates*).

In some human cases the brachialis may likewise be almost completely separated into distinct superficial and deep layers as far as the tendon. It is the lateral portion of this deep layer that is frequently innervated by the radial nerve. At times it is separable from the remainder of the muscle as a more or less distinct slip that joins the main tendon just before insertion on the ulna. It is not uncommon to find this lateral portion of the brachialis fused superficially with the inner border of the brachioradialis. This union may be so intimate as completely to bridge over the radial nerve. These variations suggest that the fibers of the extensor element incorporated with the pars lateralis of the brachialis are derived from the brachioradialis rather than from the adjacent triceps complex. This view is shared by Paterson (1919).

The only other primate in which we have encountered any radial innervation of the brachialis is *Pygathrix*. In this animal brachialis and brachioradialis were completely fused superficially, bridging over the radial nerve. The lateral portion of the brachialis was innervated by both musculocutaneous and radial twigs, but the part served by the latter element was not differentiated as a separate slip.

In our dissections all nerves were traced to their emergence from the plexus, without, however, particular attention being paid to their finer variations. A few of the more interesting details may here be mentioned.

We found some variation in the exact manner in which the coracobrachialis is innervated. In some animals (as *Galago* and *Nycticebus*) the entire muscle (both profundus and medius) was served by branches directly from the musculocutaneous nerve. Sometimes, however, the nerve to the coracobrachialis profundus was derived not from the musculocutaneous nerve proper but from another portion of the plexus. Such an arrangement occurred in *Papio*, in *Tarsius* (*philippinensis?*),⁵ and in *Aotus* (No. 237). In both the *Papio* and the *Tarsius* the profundus was innervated by a branch from the lateral head of the median nerve just below the point where the musculocutaneous nerve diverged from the lateral cord of the plexus. According to Kohlbrügge (1897) both Westling and Höfer likewise found the coracobrachialis innervated by the median nerve in their orangs. This does not indicate a heterotopic innervation from the median nerve proper, but implies that certain fibers normally carried in the trunk of the musculocutaneous may at times continue for a space with those of the median. In the *Aotus*, on the other hand, the profundus received a nerve branch from the plexus proximal to the origin of the musculocutaneous nerve. It is, of course, well known that in man the nerve to the coracobrachialis frequently does not issue from the musculocutaneous nerve, but instead has an independent origin from the seventh (or seventh and sixth) cervical nerves. This indicates that these nerve fibers, usually carried with the musculocutaneous, at times become independent proximal to the formation of that trunk. This is just the opposite to the arrangement in *Papio* and *Tarsius* (*philippinensis?*). Bolk (1902) also found a separate nerve for the coracobrachialis medius in the orang-utan and *Midas rosalia*, and for the coracobrachialis profundus in *Cynocephalus babuin*. In the specimen of spider monkey (*Ateles geoffroyi*) we found that at the upper third of the brachium the median nerve sent a branch to join the terminal division of the musculocutaneous nerve, which then ended in the substance of the brachialis muscle. At the same point was the sole origin, from the median, of the lateral antibrachial cutaneous nerve. In this case, therefore, the musculocutaneous nerve carried no cutaneous fibers. This arrangement may possibly be the rule for the spider monkey, for Bolk likewise found in *Ateles belzebuth* that the n. cutaneus antibrachii lateralis arose only from the median nerve, the musculocutaneous nerve terminating in the brachialis muscle. A branch from the median to musculocutaneous was also encountered in the baboon (*Papio*), the langur (*Pygathrix*), and the guenon (*Lasiopyga*). In these animals the anastomosis took place in the distal third of the upper arm.

⁵ In *Tarsius saltator* the coracobrachialis profundus was innervated by a branch issuing directly from the trunk of the musculocutaneous nerve.

Anastomosis of the median and musculocutaneous nerves is not uncommon in man, but in such cases the branch is commonly from the musculocutaneous distalward to the median (Spalteholz) and more rarely vice versa, as we found in *Ateles*, *Papio*, *Pygathrix*, and *Lasiopyga*.

Bolk described anastomoses of the median and musculocutaneous nerves in many of the primates that he dissected. In some instances (as in *Colobus ursinus*, *Macacus niger*, *Cynocephalus babuin*, *C. mormon*, and *Mycetes seniculus*) the connecting branch passed from median to musculocutaneous, as we found also in *Ateles geoffroyi* and *Papio hamadryas*; in one (*Lepilemur mustelinus*) it passed in the opposite direction as is usual in man. In *Semnopithecus nasicus* both median and musculocutaneous supplied a fine branch, which joined together and innervated the coracobrachialis medius; while in *Cercopithecus albigularis* there was a twofold anastomosis of median and musculocutaneous, the upper forming a purely motor nerve to the brachialis muscle, the lower becoming the lateral cutaneous nerve of the forearm. Anastomoses of musculocutaneous and median have also been discussed by Kohlbrügge (1897) in some detail.

We found that all the brachial nerves of *Hylobates lar* were gathered within a single sheath. This led to the first impression that the musculocutaneous nerve was not present as a separate structure, the nerves to the brachial flexors seeming to issue from the median. Fortunately, however, our specimen was dissected while fresh, so that upon splitting the common sheath the separate flexor nerves could be readily demonstrated. In an embalmed specimen this arrangement might easily have led to an erroneous interpretation. Apparently the fibers of the musculocutaneous nerve in *Hylobates* exhibit considerable variability in their degree of independence of the median nerve. Kohlbrügge (1890), for example, found no separate musculocutaneous nerve in either *Hylobates syndactylus* or *H. agilis*. In both of these animals the nerves to the three brachial flexors arose as separate branches of the lateral head of the median nerve. Bolk (1902), on the other hand, found in *Hylobates mülleri*, a common trunk in the upper arm representing the united musculocutaneous, median, and ulnar nerves. Only near the elbow did this trunk divide into median and ulnar. Prior to this point there were given off from the common trunk the separate branches to the brachial flexors. In our *Hylobates lar* at least the association of the flexor nerves in the brachium was not so intimate as that described by Bolk. This author likewise found no separate musculocutaneous nerve in his chimpanzee, the brachial flexors being served

by branches issuing directly from the median. The same arrangement occurred in the chimpanzees studied by Gratiolet and by Sutton (cited by Bolk). In our chimpanzee the musculocutaneous nerve was quite a distinct entity in each arm, and the formation and proximal distribution of the entire brachial plexus agreed quite closely with the conditions usually obtaining in man. According to Bolk, if the musculocutaneous nerve does not pierce the coracobrachialis but lies medial to it, and if no blood vessels lie between it and the median nerve, there is no factor present that may hinder the ontogenetic union of the two nerve trunks. These ideal conditions for union were realized in both his chimpanzee and his gibbon. In the latter animal he regarded the union of median and ulnar nerves as an expression of the result of the narrow spatial relationships in the vessel-nerve canal on the medial side of the arm; that is, in the sulcus bicipitalis. These hypotheses are quite ingenious and exceedingly plausible, but this particular subject needs further and more detailed investigation.

We have usually obtained the innervation of the epitrochleoanconeus, and this has always been by the ulnar nerve. Hence, this slip has no relationship with the triceps group. It should never be confused, as is usually done, with the anconeus internus sometimes found (as in *Didelphis*). This triceps element is situated more upon the extensor side of the epicondyle than is the epitrochleoanconeus, at least in primates.

CONCLUSIONS

Among the primates the brachial flexors as a whole exhibit no very distinct phylogenetic trend. The variations are individual rather than generic.

There is to be noted, among the so-called higher primates, a tendency for the two heads of the biceps brachii to fuse more completely and more proximally. Supernumerary biceps heads should probably be regarded as atavistic in some instances. In others they may represent nothing more than fortuitous variations. The *lacertus fibrosus* is present more frequently in man than in other forms. Since this is probably a primitive feature, man is to be regarded as relatively unspecialized in respect to this character.

The coracobrachialis, in its most complete expression, is composed of three parts, which we prefer to call superficialis, media, and profunda. The first of these is present only in very rare instances. Among the gibbons, great anthropoids, and man the pars profunda tends toward complete disappearance. Similarly, the pars media exhibits a tendency to terminate its insertion farther proximally than

in the more primitive primates. The musculocutaneous nerve usually passes between *media* and *profunda* in prosimians and monkeys, but in the great anthropoids and man its customary course is one whereby it pierces the *media*.

Most constant of all the brachial flexors is the *brachialis*. In its primitive condition it was evidently entirely separable into two heads, and traces of this original condition are found even among the more advanced primates.

The *epitrochleo-anconeus*, while topographically a member of the brachial flexor group, is really a portion of the *flexor carpi ulnaris* complex. This is indicated by its constant innervation by the ulnar nerve, and never by the musculocutaneous, which is the nerve of the true brachial flexors. This small muscle apparently occurs haphazardly among the various groups of primates.

Most striking, perhaps, are the contrasting specializations of the biceps muscle in the *Lorisinae*, among the lemurs, and in the *Hylobatidae*, among the catarrhines. In all other primates this muscle normally is composed of the usual mammalian coracoid and long heads. The lorises (*Nycticebus*, *Loris*, and *Stenops*), however, normally possess but one head, of the long variety, the coracoid head being absent. A quite different and most complicated arrangement obtains in the gibbons (*Hylobatidae*). This in principle consists of the normal absence of the coracoid head and its replacement by one arising from the humerus. The long head is present. There are exhibited most intimate connections with surrounding muscles, such as the *pectoralis major*, *dorsoepitrochlearis*, and the forearm flexors. This produces a mechanical arrangement which is well adapted to the extreme mode of brachiation exhibited by the gibbons. This unique anatomical arrangement is clearly an extreme functional adaptation peculiar to the gibbon. In no sense can it be regarded as representing a stage in the evolution of the biceps of man and the anthropoid apes. Though this curious structure of the gibbon's biceps seems undoubtedly to be adaptive, it is apparently not a necessary outcome of the brachiating mode of locomotion, for such able and constant brachiators as *Ateles*, *Colobus*, *Pan*, and *Pongo* exhibit no trace of such an arrangement.

BIBLIOGRAPHY

- BOLK, L.**
 1902. Beiträge zur Affen-anatomie. III, Der Plexus cervico-brachialis der Primaten. Petrus Camper, vol. 1, pp. 371-566.
- DUCKWORTH, W. L. H.**
 1915. Morphology and anthropology. Ed. 2, vol. 1, 304 pp. Cambridge.
- EISLER, P.**
 1895. Die Homologie der Extremitäten. Abh. Naturf. Ges. Halle, vol. 19, pp. 89-344.
- FICK, R.**
 1925. Beobachtungen an der Muskeln einiger Schimpansen. Zeitschr. f. Anat. und Entwicklungsg., vol. 76, pp. 117-141.
- FÜRBRINGER, M.**
 1876. Zur vergleichenden Anatomie der Schultermuskeln. Morph. Jahrb., vol. 1, pp. 636-816.
- GRÖNROOS, H.**
 1903. Die Musculi biceps brachii und latissimo-condyloideus bei der Affengattung *Hylobates* im Vergleich mit den entsprechenden Gebilden der Anthropoiden und des Menschen. Abh. Kön. Preuss. Akad. Wiss., Berlin, 102 pp.
- HUMPHRY, G. M.**
 1872. Observations in myology, including the myology of *Cryptobranch*, *Lepidosiren*, dog-fish, *Ceratodus* and *Pseudopus pallasii*, with the nerves of *Cryptobranch* and *Lepidosiren* and the disposition of muscles in vertebrate animals. 192 pp. Cambridge and London.
- KOHLBRÜGGE, J. H. F.**
 1890. Versuch einer Anatomie des Genus *Hylobates*. Zool. Ergeb. einer Reise in Niederländisch Ost-Indien. Vol. 1, pp. 211-354. Leiden.
 1897. Muskeln und periphere Nerven der Primaten, mit besonderer Berücksichtigung ihrer Anomalien. Verh. Kon. Akad. van Wetenschappen te Amsterdam (Tweede Sectie), vol. 5, no. 6, pp. 1-246.
- LECHE, W.**
 1900. Mammalia. Bronn's Klassen und Ordnungen des Thier-Reichs. Vol. 6, pt. 5, 1,169 pp. Leipzig.
- LE DOUBLE, A. F.**
 1897. Traité des variations du système musculaire de l'homme et de leur signification au point de vue de l'anthropologie zoologique. 2 vols. Paris.
- LUBOSCH, W.**
 1899. Ein coracoantibrachialis beim Menschen. Beitrag zur Morphologie des M. biceps brachii. Morph. Jahrb., vol. 27, pp. 309-316.
- MURIE, J., and MIVART, St. G.**
 1872. On the anatomy of the Lemuroidea. Trans. Zool. Soc. London, vol. 7, pp. 1-113.
- OWEN, R.**
 1868. On the anatomy of vertebrates. Vol 3, Mammals, 915 pp. London.

PARSONS, F. G.

1894. On the myology of the sciuromorphic and hystricomorphic rodents. Proc. Zool. Soc. London, 1894, pp. 251-296.
1898. The muscles of mammals, with special relation to human myology. II, The muscles of the shoulder and fore-limb. Journ. Anat. and Physiol., vol. 32, pp. 721-752.

PATERSON, A. M.

1919. The anatomy of the peripheral nerves. 165 pp. London.

SOMMER, A.

1907. Das Muskelsystem des Gorilla. Jen. Zeitschr. f. Naturw., vol. 42, pp. 181-308.

SPALTEHOLZ, WERNER.

- [No date.] Hand-atlas of human anatomy. Vol. 3, Viscera, brain, nerves, sense-organs. (English translation, ed. 5.) Philadelphia and London.

TESTUT, L.

1884. Les anomalies musculaires chez l'homme expliquées par l'anatomie comparée. Leur importance en anthropologie. 844 pp. Paris.

WELCKER, H.

1878. Die Einwanderung der Bicepssehne in das Schultergelenk. Nebst Notizen über Ligamentum interarticulare humeri und Lig. teres femoris. Arch. f. Anat. und Physiol., 1878, Anat. Abth., pp. 20-42.

WOOD, J.

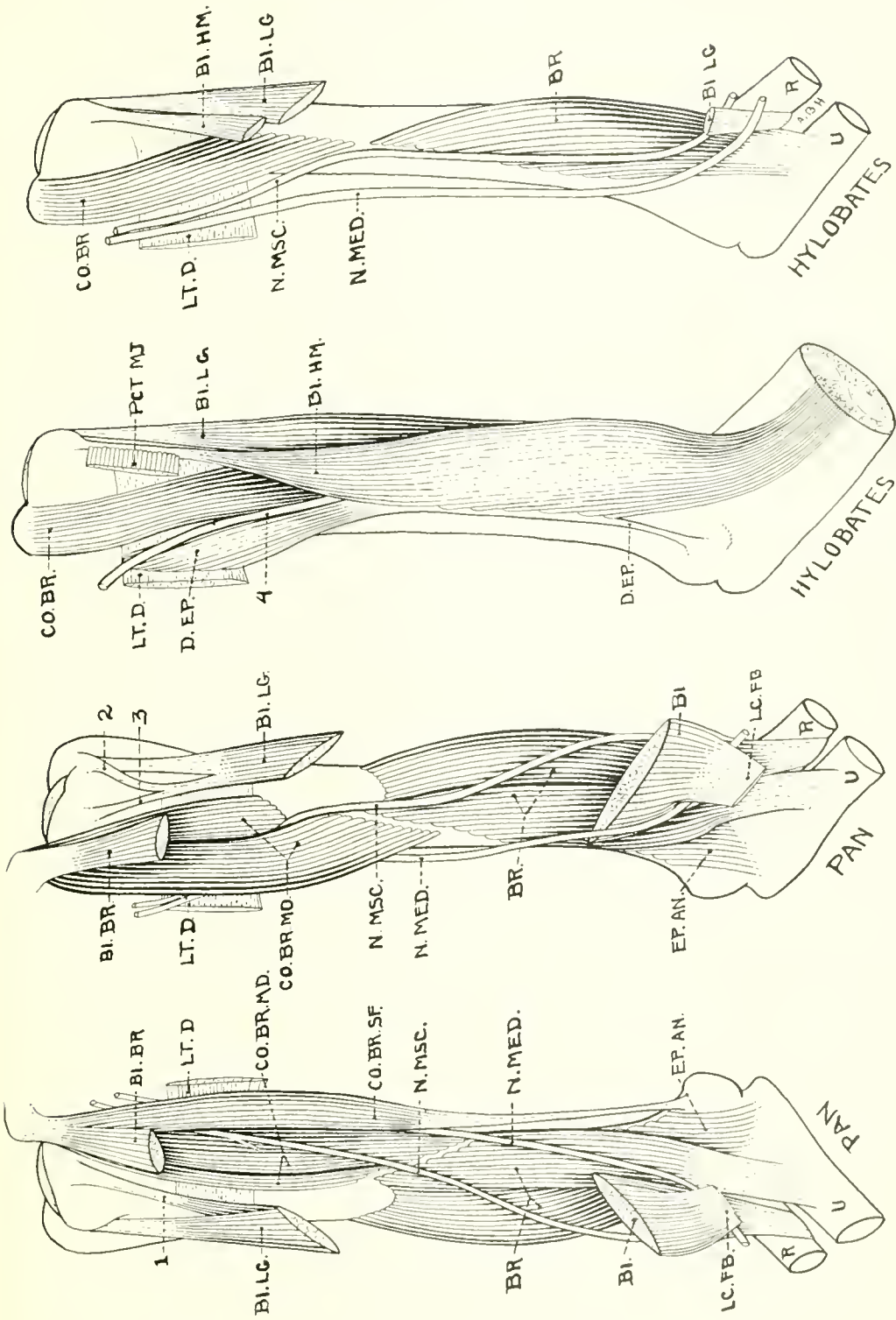
1867. On human muscular variations and their relation to comparative anatomy. Journ. Anat. and Physiol., vol. 1, pp. 44-59.

ZUCKERKANDL, E.

1898. Zur Anatomie von *Chiromys madagascarensis*. Denkschr. Kais. Akad. Wiss., Wien, Math.-Naturw. Cl., vol. 68, pp. 89-200.

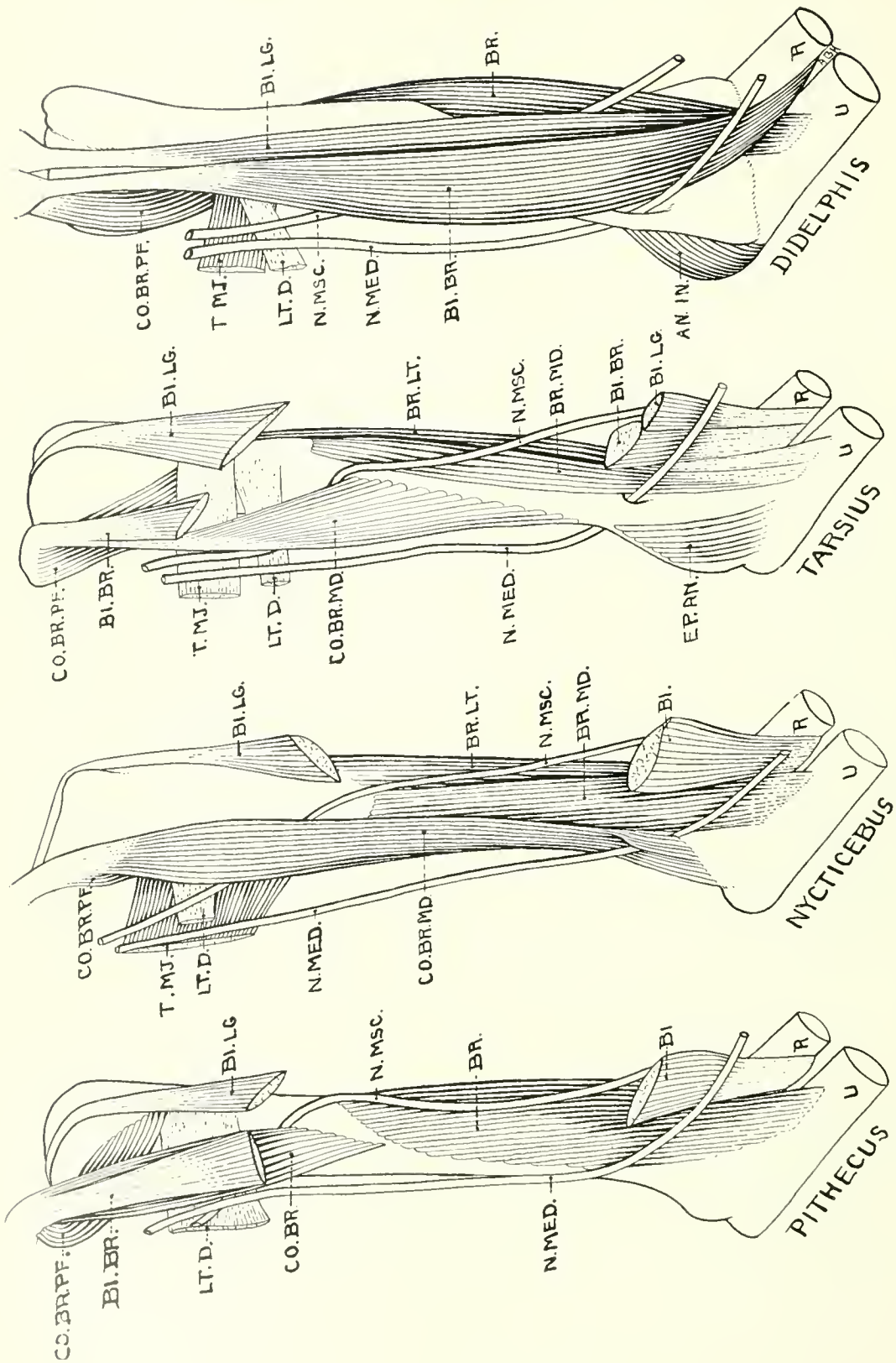
ABBREVIATIONS USED IN PLATES

- AN. IN.—anconeus internus.
BI. BR.—biceps breve.
BI. LG.—biceps longum.
BI. HM.—biceps humerale.
BR. LT.—brachialis lateralis.
BR. MD.—brachialis medialis.
CO. BR. MD.—coracobrachialis medius.
CO. BR. PF.—coracobrachialis profundus.
CO. BR. SF.—coracobrachialis superficialis.
D. EP.—dorsoepitrochlearis.
EP. AN.—epitrochleo-anconeus.
LC. FB.—lacertus fibrosus.
LT. D.—latissimus dorsi.
N. MED.—nervus medianus.
N. MSC.—nervus musculocutaneus.
N. ULN.—nervus ulnaris.
PCT. MJ.—pectoralis major.
R.—radius.
T. MJ.—teres major.
U.—ulna.
1, 2, 3.—accessory heads of the biceps brachii.
4.—common sheath of the flexor nerves.



MUSCLES OF PRIMATES

Brachial flexors of *Pan* (right and left arms) and *Hylobates* (superficial and deeper aspects of left arm). For key to abbreviations see page 31.



MUSCLES OF PRIMATES AND OPOSSUM

Brachial flexors of *Pithecus*, *Nycticebus*, *Tarsius*, and *Didelphis* (all left-arm views, but the first and last have been transposed). For key to abbreviations see page 31.