

ON THE SKULL AND THE BRAIN OF TRICERATOPS,
WITH NOTES ON THE BRAIN-CASES OF IGUANODON
AND MEGALOSAURUS.

By OLIVER P. HAY,
Of Washington, District of Columbia.

Two circumstances recently stimulated the writer to make a study of the skull of the Ceratopsia. One of these was the sight of a nearly complete brain-case of a specimen that has been identified as *Triceratops serratus* (Cat. No. 2416, U.S.N.M.); the other was the appearance of Hatcher's monograph entitled *The Ceratopsia*, which was published in 1907 as Monograph 49 of the U. S. Geological Survey.

Inasmuch as some statements are made in Hatcher's monograph regarding the structure of the skull of the Ceratopsia from which the writer must dissent, it is desirable to express admiration for that important work. For the first time there is brought together all that is known about these bizarre reptiles. They form a difficult subject of investigation, and no one writing about them can expect either to avoid errors or to exhaust the subject. Therefore, every student of the group needs to look with charity on the shortcomings of others. We are under the highest obligations to Hatcher, Marsh, and Lull, as authors of *The Ceratopsia*.

The principal difficulty in the way of explaining the brain-case of the Ceratopsia is found in the thorough coossification of most of the component bones. Such is the condition of the brain-case referred to in the first paragraph of the present paper. This specimen (Plate 1, fig. 1; Plate 2, fig. 1) was collected for Professor Marsh in 1889 by O. A. Peterson, on Lance Creek, Converse County, Wyoming. It is not mentioned in *The Ceratopsia* under *T. serratus*, but Hatcher's figs. 32 and 34 were taken from casts which represent the brain that once filled that specimen. In the legend under these figures the number of the specimen is given as 2065, but this is the accession number in Marsh's collection, not that of the U. S. National Museum.

As stated, most of the bones are united so as to abolish all traces of the sutures. However, the anterior, or orbitosphenoidal, segment has remained free from that behind, as will be shown.

The writer will first consider that unpaired bone which was regarded by Marsh and Hatcher as the supraoccipital.^a This question needs to be answered: How can that bone be the supraoccipital which overlies, as this one does, the midbrain instead of the medulla oblongata and the cerebellum? Furthermore, it appears quite improbable that the supraoccipital alone of the bones of the occipital segment would fail to coossify with the others. However, what seems to be an unanswerable argument against the identification of this bone as the supraoccipital is the fact that the latter bone in reptiles takes an essential part in the formation of the internal ear, including on each side, as it does, always some part of the posterior semicircular canal. It may be said that its right and left borders are thereby firmly anchored to those other bones that enclose portions of the semicircular canals, the opisthotic and the prootic. Now, if the bone called supraoccipital by Marsh and Hatcher is such, the semicircular canals would have to make a loop about 100 mm. long in order to reach the supraoccipital.

The fact appears to be that this bone has been wrongly identified. The true supraoccipital is that bone which forms the roof over the medulla oblongata, and which in the specimen here studied and in all others known is ankylosed to the exoccipitals on each side. Whether or not the latter join each other over the foramen magnum can not now be determined. In *Camptosaurus* the supraoccipital forms a considerable part in the boundary of the foramen magnum, but in crocodiles no part. As shown by Hatcher's fig. 8, the lower border of the bone called supraoccipital rests on the side walls of the brain-case, his alisphenoid, as far forward as the "alisphenoid buttress for the postfrontal;" but these are almost exactly the relations that the parietal has in the alligator. Unfortunately, in the specimen before us the bone regarded by the writer as the parietal is missing, except a part of the left side, whose broken edge is seen in fig. 1, Plate 2, *pa.* From No. 4286, *T. sulcatus*, described below, it appears that the suture between the parietal and the alisphenoid would run along the lower border of the broken surface just referred to, but it would probably strike the outer surface of the brain-case much below the upper border of the broken surface shown in the figure mentioned.

It would appear that the editor of *The Ceratopsia* himself, who lettered the figures of Hatcher's work, was now and then either in doubt regarding the identity of the supraoccipital and the parietal or was led instinctively to their correct determination. Fig. 107, on p. 121, represents as supraoccipital a portion of the bone called exoccipital in fig. 6; while that bone which in the former figure is denominated parietal is represented in fig. 6 as being the supraoccipital.

^a Marsh, *Dinosaurs of North America*, p. 210; Hatcher, *The Ceratopsia*, pp. 16, 17, figs. 7, 8.

Nevertheless, in the text the foramen magnum is said to be wholly in the exoccipitals and the median expanding bar of bone is said to articulate with the supraoccipital. Also, the supraoccipital is correctly represented on Plates 33 and 37 of *The Ceratopsia*.

Of course, the question at once comes up regarding the composition of the frill. It has always been interpreted as consisting of the squamosals on the right and left borders and of the coalesced parietals in the middle part. There seems to be no doubt that the bones called squamosals are such. For the middle portion we must seek some other bone or bones than the parietal. It seems to the writer that the required elements are to be found in the supratemporals, bones found in many lizards and in some other reptiles. For those of the lizard, see Parker.^a Or, it seems possible that the middle bone of the frill may have developed from the coalescence of nuchal bones such as are found in the crocodiles.

On each side of the frill of *Triceratops*, between the squamosal and the so-called parietal, there is an elongated excavation which terminates farther in front in a foramen, and this excavation has been called the supratemporal fossa. Now, it is easy to see that in the alligator the hinder free borders of the parietal and squamosals might grow backward over the animal's neck and make such a frill as we have in *Triceratops*; but in this case the supratemporal fossæ would be left in their original position. It is difficult to understand how these bones became modified in such a way as to transfer the supratemporal fossæ behind the paroccipital processes of the exoccipitals.

It appears to the writer that the supratemporal fossæ have either been abrogated or not yet recognized as such. Marsh described an opening in the midline, slightly behind the great postorbital horn cores, and called it the pineal foramen; although he did not show that it opened into the brain and did conclude that it opened into a large sinus extending above the brain-case into the cavities of the horn cores. Hatcher and Lull likewise say that this foramen communicates with large sinuses in the postfrontal bones and in the horn cores. Furthermore, Lull^b writes that the sinus underlying the horn core can be explored through the so-called pineal, or postfrontal, foramen, and that the latter communicates with those of the horn cores and with the space within the skull behind the orbit. By the latter expression is understood by the present writer the space occupied by the temporal muscles, the space called by Hatcher the temporal fossa.^c Probably in all cases this postfrontal foramen divides below

^a Trans. Phil. Soc. London, CLXX, pp. 595-640.

^b Bull. Amer. Mus. Nat. Hist., XIX, p. 691.

^c *The Ceratopsia*, p. 125.

into two, one for each side. Hatcher^a says that in *Torosaurus latus* there is a pair of these foramina, separated by a thick partition of bone that marks the median line of the skull.

Now, to the writer it seems perfectly clear that the foramen in question represents the supratemporal fossæ of the alligator and of various other reptiles. The bone rising up and dividing the fossa into two, either at the surface or deeper down, will almost certainly be found to be the true parietal. Through the enormous thickening of the postfrontals the parietal has been crowded from the upper surface of the skull of *Triceratops* and the two supratemporal fossæ have been pushed into one at the midline.

As regards the fossæ in the frill, they may be explained as gaps between the squamosal and the supratemporal of each side. Hatcher^b tells that these openings communicated with the temporal fossæ and with the cavities at the bases of the horn cores. These passages must represent the posttemporal fossæ. Possibly through them passed branches of the temporal arteries to spread themselves over the upper surface of the frill.

Hatcher has, in my opinion, erred in his interpretation of the braincase of the Ceratopsia. His errors have arisen partly from the nearly complete or complete absence of sutures in the skulls examined and partly from his not having recognized the differences between the reptilian skull and that of the mammals, a group with which he was more familiar. The latter cause of error is shown in his failure to mention the prootic bone, one of the most constant in the reptilian skull, and in his speaking of all of the bones of the skull in front of the exoccipitals as the alisphenoid, as if it corresponded to the sphenoid of human anatomy. Again, on page 39 of *The Ceratopsia*, the organ of hearing is misunderstood because it did not present mammalian characters.

The specimen before me (Cat. No. 2416, U.S.N.M.) appears to agree quite closely with Hatcher's fig. 8 representing the same parts of *T. flabellatus*, although the latter is about a third larger than No. 2416. Now, in both skulls there are undoubtedly present the basioccipital, the basisphenoid, the presphenoid, exoccipitals, prootics, alisphenoids, and orbitosphenoids. In fact, it appears that the braincase of the Ceratopsia was the most complete of any known reptile.

Inasmuch as the sutures between the bones are mostly effaced, we are able to determine their limits only approximately, guided partly by the orifices for the nerves, partly by the courses of the sutures in living reptiles, but especially by aid from the fine skull of *Camptosaurus* now being studied by Mr. Charles W. Gilmore, who has generously allowed the writer to examine it.

^a *The Ceratopsia*, p. 151.

^b *Idem*, p. 125.

The identification of these bones and foramina may begin with the foramen ovale, that opening through which the fifth nerve escapes from the brain cavity. This has been correctly identified by Hatcher.^a In Cat. No. 2416 this foramen has, on the inner surface of the brain-case (Plate 2, fig. 1, 5), a diameter of about 12 mm., and it is of a somewhat squarish form. On the outer surface (Plate 1, fig. 1, 5², 3) the diameter is about 16 mm. The bone here has a thickness of about 28 mm. It may be here remarked that the foramina of this skull are usually really short canals, having inner and outer ends. In the passage for the fifth nerve, not far from its inner end, there is given off a large canal which is directed forward, emerging on the outer surface of the skull about 30 mm. in front of the foramen ovale (Plate 1, fig. 1 5¹). Through this canal passed forward the ophthalmic branch of the fifth nerve. Hatcher writes that the anterior opening is the foramen rotundum, and conveyed the maxillary branch; but the structures here are identical with those in the alligator. Out of the external end of the foramen ovale (Plate 1, fig. 1, 5², 3) issued the second and the third branches of the fifth nerve.

Now, the foramen ovale is situated between the prootic and the alisphenoid bones. In the alligator the larger part of it is in the prootic; and the same is the case in *Camptosaurus*. Hence, in *Triceratops* the suture between the prootic and the alisphenoid may be provisionally drawn through the front of the foramen, carrying the suture up to the parietal.

On the inner surface of the brain-case (Plate 2, fig. 1, 6), a little below the foramen ovale, there is seen the posterior orifice of a canal 4 mm. in diameter, for the transmission of the sixth nerve, just as may be seen in the alligator. The canal runs the length of the basisphenoidal bone, emerging at its anterior end. In Hatcher's fig. 8 it is indicated by the letter *z* and explained as being an undetermined foramen.

In Hatcher's figure just quoted there is indicated by the letters *eam* a small foramen just behind the foramen ovale. This is explained with a query as being the internal auditory meatus. Being on the outside of the brain-case it can not be that meatus. In fig. 24 the same foramen is said to be the external auditory meatus. The meatus properly so-called is a part of the external ear and this reptile probably had no such organ. The foramen in question is that for the escape of the seventh, or facial, nerve (Plate 1, fig. 1, 7). It has the same position as in the alligator and, as in the latter animal, goes straight through the prootic bone. Outwardly it opens between two descending ridges of bone, which enclose a smooth groove, along which the nerve passed downward. A similar groove is seen in the alligator and in *Camptosaurus*.

^a The *Ceratopsia*, p. 17, fig. 8, *fo*.

On the inner surface of the brain-case, behind the foramen just described, is a large oval opening (Plate 2, fig. 1, 10) whose greater axis, 18 mm. long, is directed upward and backward. Hatcher (p. 16) has called this the foramen lacerum posterius. It is the common mouth of two short canals which emerge, the one behind the other, on the outer surface of the skull (Plate 1, fig. 1, *fen* and 10). Between the two exterior openings there is a great ridge of bone 10 mm. thick, that ascends from the basioccipital process to the paroccipital process of the exoccipital. In the alligator a corresponding ridge forms the lateral boundary of the lower part of the exoccipital, and it is probable that in *Triceratops* the ridge is on the exoccipital. The anterior of the two exterior openings mentioned is the larger. It is funnel-shaped, the mouth of the funnel having a horizontal diameter of about 20 mm. and a vertical diameter of 15 mm. The hinder canal likewise expands as it approaches the surface, and forms a triangular foramen whose diameters are about 10 mm. and 15 mm. In the figure referred to last this opening is hidden by the ridge of bone described. The line from 10 is directed to it.

Hatcher^a has identified the anterior of these foramina as the outer end of the foramen lacerum posterius, the hinder as the place of exit of the tenth and eleventh nerves. However, on page 37 he writes that he has interpreted the anterior branch from the internal foramen lacerum posterius as having conveyed the tenth nerve to the brain. He there states further that some anatomists may regard the anterior of the two outer foramina as the external auditory meatus, its internal opening as the internal auditory meatus.

There is no doubt in the mind of the writer that the anterior of the outer foramina in question is the fenestra ovalis, the opening into the vestibule of the internal ear. In life it was probably partly or wholly closed by the expanded end of the stapes. So far as known to the writer, this bone has not yet been found in any member of the Ceratopsia. It was quite certainly a long slender rod, which extended from the fenestra ovalis to the outer surface of the skull, running first below the paroccipital process, then behind the quadrate, reaching the skin in the notch found in the lower border of the frill. It could hardly have been less than a foot in length. A very similar stapes is found in the alligator and in most other reptiles.

The hinder of the two external foramina discussed above is the proper foramen lacerum posterius, or jugular foramen (Plate 1, fig. 1, 10), and it transmitted the ninth, tenth, and eleventh nerves of its side, besides also the jugular vein. The foramen credited by Hatcher to the eleventh nerve is the anterior condyloid foramen and probably transmitted a vein. The foramen for the twelfth nerve (Plate 1, fig. 1, 12) is correctly identified.

^a The Ceratopsia, p. 16, fig. 8.

We must now investigate further that opening on the inner surface of the brain-case (Plate 2, fig. 1, 8, 10) from which diverge the two short canals considered above, the one to the fenestra ovalis, the other to the foramen lacerum posterius. On comparison with the alligator there can be no doubt that we have here a confluence of the opening for the auditory nerve and that for the transmission of the ninth, tenth, and eleventh nerves, the lower part of the foramen having been devoted to the auditory, the upper part to the other nerves. In the alligator the latter nerves pass out through a long fissure, which is separated from the foramen for the auditory nerve by only a narrow process of bone. Had the cartilage of this process not become ossified the two openings would have appeared in the dried skull as a single one, as it does in *Triceratops*.

Hatcher thought that the foramen for the facial nerve, his internal auditory meatus, communicated with the small cavities which he represented in his fig. 31 and indicated by the numeral III. The cavities shown there are quite certainly sections of the anterior and posterior semicircular canals, the larger section being the commissure of the two canals. The anterior section belongs in the prootic bone, the posterior in the opisthotic portion of the exoccipital, while the larger section is in the line of union of the two bones. The supraoccipital bone must have descended nearly to the level of these sections. Communication with these canals was had from within the skull by means of the foramen transmitting the eighth nerve, from without by means of the fenestra ovalis. In all these respects we have here the normal reptilian condition, and we have no reason for thinking that the *Ceratopsia* were deficient in hearing.

Now, the fenestra ovalis lies between the prootic bone and that part of the exoccipital that had its origin from the opisthotic. The suture between the prootic and the exoccipital may then be drawn through the fenestra ovalis and carried upward to the supraoccipital, as it runs in the alligator and in *Camptosaurus*.

Slightly behind and about 28 mm. below the foramen ovale, that exit for the fifth nerve, is the mouth of the canal for the internal carotid artery (Plate 1, fig. 1, *car*). The other end of the canal is found in the pituitary fossa (Plate 2, fig. 1, *car*). The hinder opening appears to be in the posterior end of the basisphenoid bone. A long shallow groove (Plate 2, fig. 1, *car. g*) on the underside of the basioccipital process leads forward to it. From the front end of the pituitary fossa a short canal (Plate 2, fig. 1, *op. f*; Plate 1, fig. 1, *op. f*) runs forward and opens on the outer surface of the bone. The outer opening is indicated in Hatcher's fig. 8 by the letters *pf*. It seems probable that this canal conveyed to the orbit the ophthalmic branch of the internal carotid artery, a vessel that in man escapes through the optic foramen.

The optic foramina (Plate 1, fig. 1, 2; Plate 2, fig. 1, 2) have been correctly identified by Hatcher. Behind each of these openings is another (Plate 1, fig. 1, 3; Plate 2, fig. 1, 3) which he has correctly called the sphenoidal fissure. Through it passed to the orbit the third nerve and possibly the fourth. This fissure, or rather foramen, lies in the boundary between the orbitosphenoid and the alisphenoid bones. Indeed, in our specimen the suture between the two bones has remained open, so that the limits of the orbitosphenoidal segment may be traced. Each optic foramen is in the orbitosphenoid of its side, near its hinder edge. The bones of the two sides meet above the olfactory lobes and the suture is closed, but over the cerebral hemisphere there is a fontanel, which was closed by either the frontals or the postfrontals. As shown by Hatcher's fig. 27, *al*, the orbitosphenoids met over the olfactory lobe. The cerebral hemispheres and the olfactory lobes of *T. serratus* rested on what must be regarded as the presphenoid bone (Plate 1, fig. 1, *pre*; Plate 2, fig. 1, *pre*). This is a triangular plate which, just in front of the optic foramina, descends 50 mm. below the floor of the brain-case, while anteriorly its free border rises to the place of exit of the olfactory nerves. Its lower hinder angle is thin, but the bone thickens toward the brain. Its hinder border appears to have joined the basisphenoid by a suture not closed at the death of the animal. Hatcher's fig. 27 shows the presphenoid of *T. horridus*. The lower line leading from *al* is directed to it. In our specimen of *T. serratus* the sutures between the presphenoid and the two orbitosphenoids are obliterated, as they were in *T. horridus*. The upper surface of each orbitosphenoid is very rough, for sutural union probably with the frontals, although Hatcher's description (p. 18) and his figs. 9, 24, and 27 represent the postfrontals as pushing themselves below the frontals in this region.

Above the optic foramen, opening into the upper part of the brain-case and near the hinder border of the orbitosphenoid, are two smaller foramina (Plate 1, fig. 1, 4, *v.*; Plate 2, fig. 1, 4, *v.*), the one behind the other. From each, on the outer surface of the bone, a groove is directed forward for a short distance. It seems probable that the hinder of these gave exit to the fourth, or trochlear, nerve. The anterior must have transmitted a blood-vessel. The olfactory nerves (Plate 2, fig. 1, 1) left the brain-case through a single orifice; at least, no bony partition separated them as was the case with *T. horridus*. However, near the anterior end of the olfactory canal there is seen a longitudinal ridge on the upper midline, which formed a partial division of the olfactory lobe. The parietal formed most of that part of the roof of the brain-case which covered the optic lobes. Anteriorly it joined the united orbitosphenoids (Plate 2, fig 1, *pa*).

On the lower surface of that bone which the writer regards as the supraoccipital (Plate 2, fig. 1, *soe*), near its anterior end, apparently between it and the parietal, and placed right and left of the mid-line, are found two deep excavations. The mouth of each of these measures about 20 mm. fore and aft and about 15 mm. transversely. The depth amounts to 15 mm. The diameters diminish toward the upper ends of the excavations. The one on the left side (Plate 2, fig. 1, *ceb. f*) appears to have reached the external surface of the bone, forming a foramen. Whether the one on the other side reached the surface is uncertain, on account of some crushing. Into these excavations there penetrated probably portions of the brain. These will be considered below.

Near the upper border of each orbitosphenoid there is found another excavation similar to those just described, having a somewhat larger base, but not entering so deeply into the bone. The base measures 20 mm. fore and aft and 15 mm. transversely. From the front of each excavation a foramen (Plate 2, fig. 1, *v*) pierces the bone, as already mentioned.

Professor Marsh^a published a figure of a cast of the brain-case of the specimen here described. This has been reproduced by Hatcher.^b This figure represents a side view of the brain. Another figure giving a view of the lower surface of the brain of this specimen is published by Hatcher.^c In that figure the letters VIII on the left side ought to be changed to VII; VIII should be connected with the anterior part of the mass indicated by X; and XI ought to be erased.

In order to represent more accurately the brain of this specimen, a new cast has been prepared by Mr. William Palmer, of the National Museum, under the superintendence of Mr. Gilmore and the writer. The parts of this brain, as represented by the cast, are indicated in the legend affixed to each figure of Plate 3. Attention must be specially called to certain structures found on the upper surface and which filled the excavations already mentioned. The hinder pair of these is shown on Plate 3, figs. 1, 3, *ceb. p*. These bodies are near the boundary between the cerebellum and the optic lobes. They are probably parts of the former. Andrews^d interprets a strong development of brain substance in the same region in *Iguanodon* as the cerebellum; but that development formed a conspicuous band which culminated in the midline above. In *Triceratops* the lateral masses are far removed from each other. Marsh's figure of the brain does not adequately represent these masses.

On the upper surface of the anterior end of the brain there is seen another pair of processes (Plate 3, fig. 1, 3 *cer. h*), not rising,

^a Dinosaur of North America, pl. LXXVII, fig. 4.

^b The Ceratopsia, p. 39.

^c Idem, p. 37, fig. 32.

^d Ann. Mag. Nat. Hist., 6th ser., XIX, p. 587, pl. xvi.

however, to such a height as the hinder pair. These probably represent the cerebral hemispheres. As mentioned above, there is a foramen placed at the front of each cerebral excavation. It probably transmitted blood-vessels; for certainly no nerve left that part of the brain.

The extensive space between the cerebellar processes and the cerebral hemispheres was probably mostly occupied by the optic lobes (Plate 3, fig. 1, *op. l*). Doubtless, an exact model of the brain would show here and farther in front a deep longitudinal cleft; also transverse clefts in front of the cerebellum and behind the cerebral hemispheres.

In Marsh's figure of the cast of the brain the olfactory lobe seems to be too long. In the figure here shown (Plate 3, figs. 1, 3, *olf. l*) it is a little too short. Its length is 55 mm. Where it escaped from the olfactory canal its divisions are seen to have been directed to the right and left, respectively.

THE BRAIN-CASE AND THE BRAIN OF TRICERATOPS SULCATUS.

In the U. S. National Museum there are important parts of a skull that has been identified as that of *T. sulcatus*. The specimen is Cat. No. 4286, U.S.N.M. It was collected by Mr. Hatcher in the so-called Laramie beds of Converse County, Wyoming, for the U. S. Geological Survey. Hatcher has presented a figure of the horn cores.^a The brain-case, including the occipital condyle, has been sawed from the horn cores along a horizontal plane that passed somewhat above the cerebral hemispheres. Afterwards the brain-case has been divided along the median plane, thus exposing the brain cavity.

The sutures of this brain-case have been mostly, if not altogether, obliterated. The general structure is the same as that of *T. serratus*, but there are some minor differences of some importance. The orbitosphenoidal segment (Plate 2, fig. 2, *orbs*) is not so extensively developed, since nearly the whole of the olfactory lobe lay in front of the orbitosphenoids. The supraoccipital bone (Plate 2, fig. 2, *soc*) is thicker than in *T. serratus*. A part of the parietal is present. Whether or not it was consolidated with the supraoccipital is uncertain, but there seems to be an open suture. In front of its articulation with the supraoccipital a median sinus (Plate 2, fig. 2, *sin*) descends and is separated from the brain cavity by bone only 5 mm. thick. This represents probably the hinder of the two sinuses shown in fig. 33 of *The Ceratopsia* and indicated by the letter X. It seems to be bounded below by the parietal, and by possibly a part of the frontals. It is doubtful whether or not the orbitosphenoids of this species met above the olfactory lobe.

The presphenoid lacks much of being as large as it is in *T. serratus*. The basisphenoid (Plate 1, fig. 2, *bas*; Plate 2, fig. 2, *bas*) descends

^a *The Ceratopsia*, p. 134, fig. 113.

a distance of 65 mm. below the surface of the brain, just behind the pituitary fossa. The bone in the region of this fossa has been damaged and replaced by white plaster. The fossa probably occupied the white area indicated by *pit. f.* in Plate 2, fig. 2. Its supposed hinder end is indicated there by a dotted line.

The writer has not been able to see the opening for the sixth nerve in this specimen. Possibly it pierced the bone farther forward than in *T. serratus*, at a point where the bone is damaged.

This specimen furnishes no certain evidence regarding the opening of the temporal fossa into the so-called post-temporal foramen. The upper parts of both temporal fossæ have been filled with plaster, in order to strengthen the specimen. On each side there is a passage from the temporal fossa into the cavity, or sinus, into which the so-called post-temporal foramen opens. On one side this opening seems to be partially artificial. On the other side it seems to be natural, but is possibly the result of accident. Here the opening is about large enough to permit the passage of one's finger.

THE BRAIN-CASE OF IGUANODON.

Hulke^a has described a brain-case believed to belong to *Iguanodon*. The same specimen has been redescribed by Dr. C. W. Andrews, of the British Museum of Natural History.^b A few remarks will be made on these descriptions.

Hulke has designated a part of the axis of the skull as equivalent to the basisphenoid and the presphenoid.^c It is evident that the presphenoid is present. The basisphenoid appears to extend forward to the notch above the letters *ii*. That part of the axis beyond this notch is quite certainly the orbitosphenoid. It includes the optic foramen.

Judging from Hulke's and Andrews's accounts of this skull the ophthalmic branch of the fifth nerve left the common stem after the latter had passed wholly through the brain-case, and it then ran forward in a groove on the outer surface of the bone. In *Triceratops* the beginning of the canal that transmits this branch is deeply buried in the bone.

What Andrews regards as a foramen for transmitting a branch of the internal carotid artery into the brain cavity the present writer holds to be the exit of the seventh nerve. The nerve descended along the groove described by Andrews. What in Andrews's figure appears to be a foramen placed 18 mm. above the optic foramen may correspond to what in *Triceratops* is thought to be an opening for the

^a Quart. Journ. Geol. Soc., XXVII, 1871, p. 199.

^b Ann. Mag. Nat. Hist., 6th ser., XIX, p. 585.

^c Quart. Journ. Geol. Soc., XXVII, 1871, pl. XI, figs. 1, 2, *bps*.

escape of the fourth nerve, as shown at the numeral 4 in the figures of Plates 1 and 2.

Andrews describes three closely placed foramina as being the fenestra ovalis, the exit of the glossopharyngeal nerve, and that of the jugular vein. One of these is certainly the fenestra ovalis, another may be the fenestra rotunda. The glossopharyngeal nerve and jugular vein may have passed out in company with the pneumogastric nerve. Andrews's statement regarding the forking of the passage by which the pneumogastric nerve leaves the brain cavity agrees with what is found in *Triceratops*.

As regards the cast of the brain cavity, the figure of which is furnished by Andrews, it seems to the writer that what is indicated as the root of the eighth nerve is really that of the seventh, while that indicated as the root of the ninth is in fact the root of the eighth. From what one sees in *Triceratops* one would expect to find the root of the ninth between the one just referred to and that of the tenth.

THE BRAIN-CASE OF MEGALOSAURUS.

Von Huene ^a has written an interesting account of the brain-case of *Megalosaurus*. This brain-case is short and high. That part of the lateral wall farthest in front is regarded by V. Huene as the alisphenoid. A notch at its lower end he rightly interprets as the point of exit of the optic nerve. To the present writer it appears that the region in front and above this notch is the orbitosphenoid. That portion of the wall that lies in front of the foramen ovale, rising to the parietal, must be interpreted as the alisphenoid.

V. Huene records the presence of a "meatus auditorius externus." Now, this meatus is a part of the external ear, and as this reptile probably did not possess such an organ, the foramen in question must have some other function. To the present writer it looks as if this foramen might be the outlet of the depression marked Z in V. Huene's fig. 1. This may be the summit of an excavation that contained such a process of the brain as has been described on page 103 as occurring in *Triceratops*.

What V. Huene calls the jugular foramen is almost certainly the inner and outer passages into the internal ear. On the inside of the brain-case this foramen admitted the auditory nerve; on the outside it was closed by the base of the stapes. The jugular vein doubtless escaped in company with the ninth and tenth nerves. V. Huene figures a foramen lying some distance above the one just mentioned and regards it as admitting to the inner ear the branches of the auditory nerve. The structures of the inner ear must lie lower down in the wall of the brain-case. Excavation of the bone lower down would certainly expose the semicircular canals. It is probable that the

^a Neues Jahrb. Min., etc., 1906. I, p. 1, pl. 1, text figs. 1-4.

opening referred to corresponds to what the present writer has interpreted as the foramen for the fourth nerve. In V. Huene's fig. 3 there is represented an opening, marked T?, and thought by him to be the outlet for the nerve mentioned. It appears possible that this is only the anterior end of a canal that begins at the foramen assigned by V. Huene to the eighth nerve.

The Eustachian canal is mentioned by V. Huene as probably penetrating the vestibule (Vorraum) of the inner ear. This can not be true. The Eustachian canal opens into the middle ear, that portion lying outside of the fenestra ovalis and containing the stapedial rod.

Of the three foramina behind the foramen lacerum posterius the one marked by XIII' probably gave exit to the hypoglossal nerve; the ones marked XIII'' and *car* probably transmitted veins. It is not probable that the internal carotid artery found its way into the brain cavity at a point so far in the rear. It certainly entered at the pituitary fossa.

DESCRIPTION OF PLATES.

PLATE 1.

External view of the rear of the skull of two species of Triceratops.

Fig. 1. *Triceratops serratus*. $\times \frac{3}{8}$

2. *Triceratops sulcatus*. $\times \frac{3}{8}$.

als, alisphenoid, on the crest of the alisphenoidal buttress to the post-occipital; *bas*, basisphenoidal process, broken away in fig. 1; *boc. p.*, basioccipital process, complete in fig. 1, mostly missing in fig. 2; *car*, foramen for carotid artery, not seen in fig. 2; *fen*, fenestra ovalis; *oc*, occipital condyle, partly broken away in fig. 1, in fig. 2 the suture between the basioccipital and the exoccipital is seen below *oc*; *op. f.*, foramen supposed to be for ophthalmic artery; *orbs*, orbitosphenoid; *par. p.*, paroccipital process, broken away in both specimens; *pre*, presphenoid, small and not lettered in fig. 2; *v.*, opening for supposed vein; 1, 2, 3, 4, foramina for cephalic nerves of corresponding numbers; 5, external opening for ophthalmic branch of the 5th nerve; 5², 5³, foramen for exit of second and third branches of 5th nerve; 6, 7, 10, 12, foramina for exit of corresponding cephalic nerves.

PLATE 2.

Longitudinal section of the rear of the skull of two species of Triceratops, showing the brain cavity:

Fig. 1. *Triceratops serratus*. $\times \frac{3}{8}$.

2. *Triceratops sulcatus*. $\times \frac{3}{8}$.

a. c. f., anterior condyloid foramen; *als*, alisphenoid; *bas*, basisphenoid, partly broken away in fig 1; *boc. p.*, basioccipital; *boc. p.*, basioccipital process; *car. l.*, foramen for left carotid artery entering pituitary fossa, not seen in fig. 2; *car. g.*, groove for right carotid artery; *ccb. f.*, foramen? at extremity of a cerebellar process; *oc*, occipital condyle; *op. f.*, foramen for exit of left ophthalmic artery from pituitary fossa; *orbs*, orbitosphenoid; *pa*, parietal; *pit. f.*, pituitary fossa; *pre*, presphenoid, not lettered in fig. 2; *pro*, prootic; *sin.*, base

of air sinus; *soc*, supraoccipital; *v*, opening for supposed vein; *x*, cavity in basioccipital; 1, 2, 3, 4, 5, 6, 7, 8, 9, 10, 12, exits for nerves of corresponding numbers.

PLATE 3.

Brain-casts of two species of *Triceratops*.

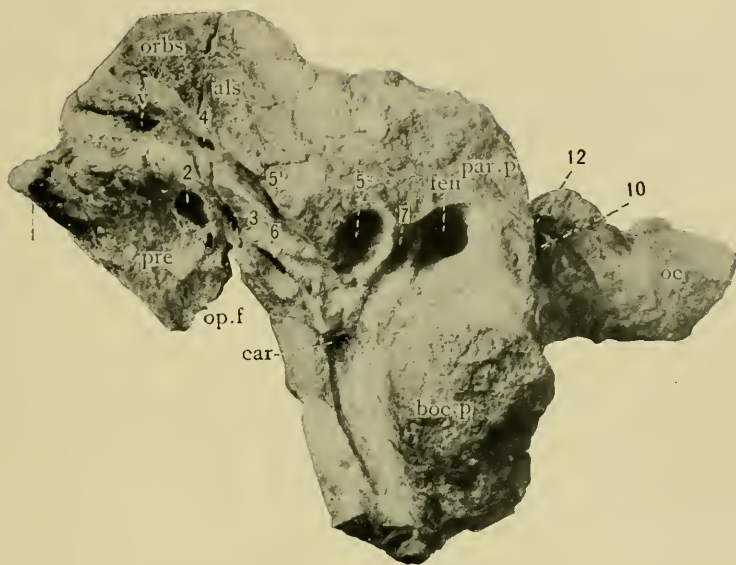
Fig. 1. *Triceratops serratus*. Upper surface. $\times \frac{3}{8}$.

2. *Triceratops serratus*. Lower surface. $\times \frac{3}{8}$.

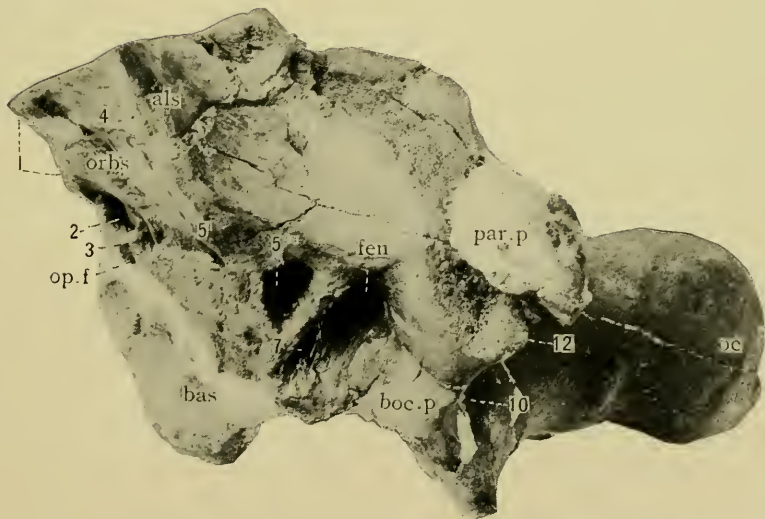3. *Triceratops serratus*. Right side. $\times \frac{3}{8}$.

4. *Triceratops sulcatus*. Right side. $\times \frac{3}{8}$.

car, entrance of carotid artery into pituitary fossa; *ceb. p* process of cerebellum; *cer. h*, cerebral hemisphere; *med*, medulla oblongata; *olf. l*, olfactory lobe; *op. a*, base of supposed ophthalmic artery; *op. l*, optic lobes; *pit*, pituitary body, largely restored in fig. 2; *v*, veins: 2, 3, 4, optic, oculomotor, and trochlear nerves; 5, ophthalmic branch of 5th nerve; 5^{2, 3}, maxillary and mandibular branches of 5th nerve; 6, 7, 8, abducent, facial, and auditory nerves; 10, pneumogastric nerve, with probably the glossopharyngeal and the spinal accessory; 12, hypoglossal nerve.



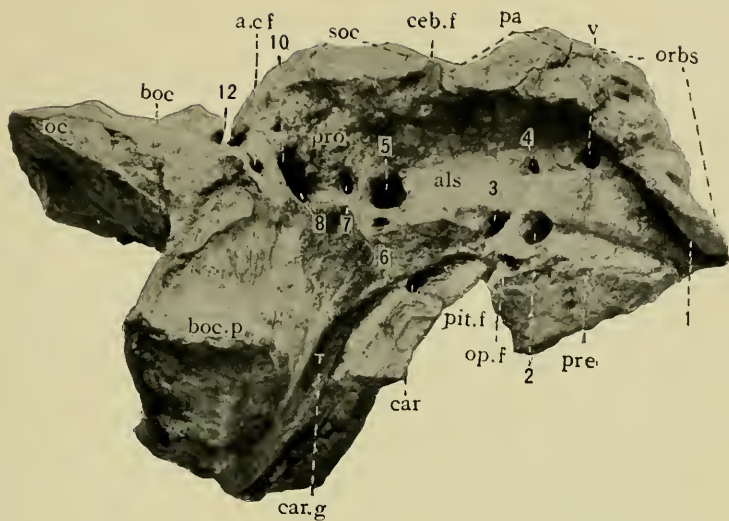
1



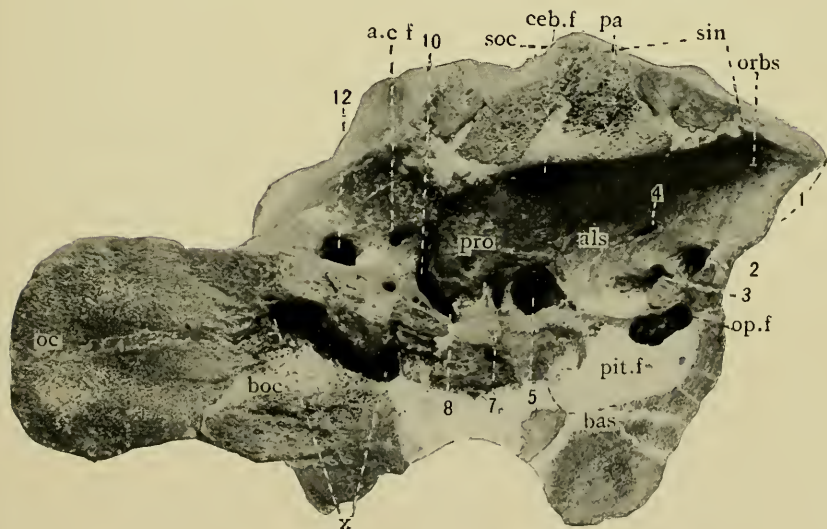
2

SKULLS OF TRICERATOPS.

FOR EXPLANATION OF PLATE SEE PAGE 107.




1



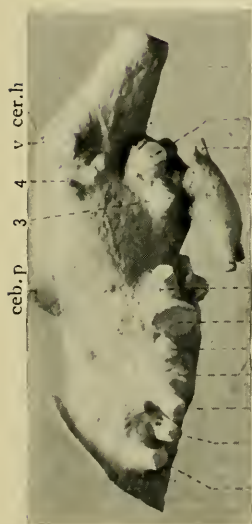
2

SKULLS OF TRICERATOPS.

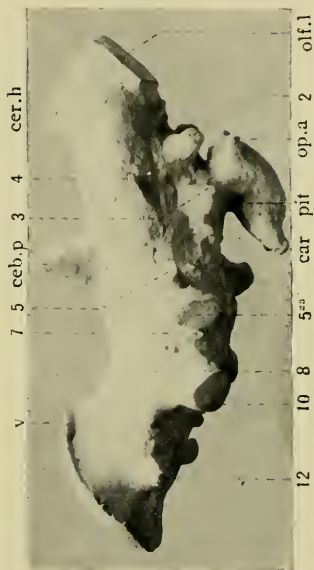
FOR EXPLANATION OF PLATE SEE PAGE 107.




1



3



4



2

BRAIN CASTS OF TRICERATOPS.

FOR EXPLANATION OF PLATE SEE PAGE 107.

