

J. med. Primatol. 4: 114-119 (1975)

Positive Contrast Peritoneography and Herniography in Primate Animals

With Special Reference to Indirect Inguinal Hernias

A.E. JAMES, jr., R.M. HELLER, jr., M. BUSH, C.W. GRAY
and KOOK SANG OH

National Zoological Park, Washington, D.C. and Department of Radiology and Radiological Science, The Johns Hopkins Medical Institutions, Baltimore, Md.

Abstract. In a number of primate animals contrast medium was injected intraperitoneally to diagnose hernias as well as evaluate the normal anatomical relationships. The technical considerations are discussed. Contrast herniography and peritoneography appear useful under certain clinical circumstances.

Key Words
Inguinal hernias
Herniograms
Peritoneograms
Contrast media
Processus vaginalis

In 1967, DUCHARME *et al.* [1] initiated the procedure known as herniography or positive contrast peritoneography in human subjects to determine the presence of a hernia, hydrocele or patent processus. We have utilized this technique in 12 nonhuman primates to demonstrate the anatomy in the inguinal region and to document whether abnormalities were unilateral or bilateral.

Materials and Methods

Positive contrast peritoneography is performed after the animal has urinated, or has been catheterized, in order to prevent inadvertent injection of the urine-distended bladder. Anesthesia is most commonly administered by an intramuscular injection of CI 744 (Parke, Davis & Co., Detroit, Mich.), 1-2 mg/lb, but any appropriate short-acting anesthetic is satisfactory.

After routine skin preparation, with the animal supine, a 1½-inch 19-gauge needle is inserted vertically slowly in the midline 2.5-4 cm below the umbilicus, checking by aspiration for air, urine or blood, which are manifestations of improper needle placement. The tip of the needle is then moved gently from side to side to be certain that we have not entered the retroperitoneum or a solid abdominal organ. If the initial attempt at place-

ment of the needle tip is unsatisfactory, another needle is used at a slightly different midline site, or injection is made at the lateral edge of the rectus sheath [2].

If the needle tip appears to be in the peritoneal cavity, 2 ml/kg of 30% meglumine diatrizoate is injected (Hypaque; Winthrop Laboratories, New York, N.Y.). The needle is removed and the animal placed prone on a radiographic table and gently turned from side to side for about 2 min. The head of the table is then raised to 35° to allow the contrast material to flow ventrally over the internal inguinal rings. An alternative technique in smaller primates is to grasp the upper arms and hold the animal upright. Following this, a single posterior-anterior radiograph of the pelvis and upper thighs is made and processed immediately. If the inguinal area on one side is not satisfactorily outlined, the animal is rolled to that side and back into the prone position several times and a second radiograph is obtained.

The meglumine diatrizoate is rapidly absorbed from the peritoneal cavity and excreted by the kidneys [4]. A delayed radiograph at 45 min is obtained to demonstrate the renal collecting system and to delineate changes indicative of infection, obstruction or tumor.

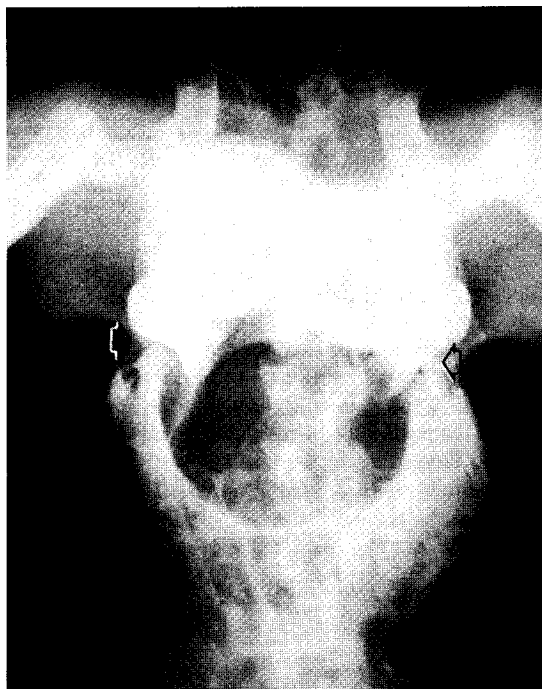


Fig. 1. The normal peritoneogram. Contrast material outlines the peritoneal cavity of a male rhesus monkey (*Macaca mulatta*). The arrows demonstrate an indentation at the site of the inferior epigastric vessels. Contrast material is seen inferior to the epigastric vessels in the pelvic peritoneal cavity. No hernia is present.

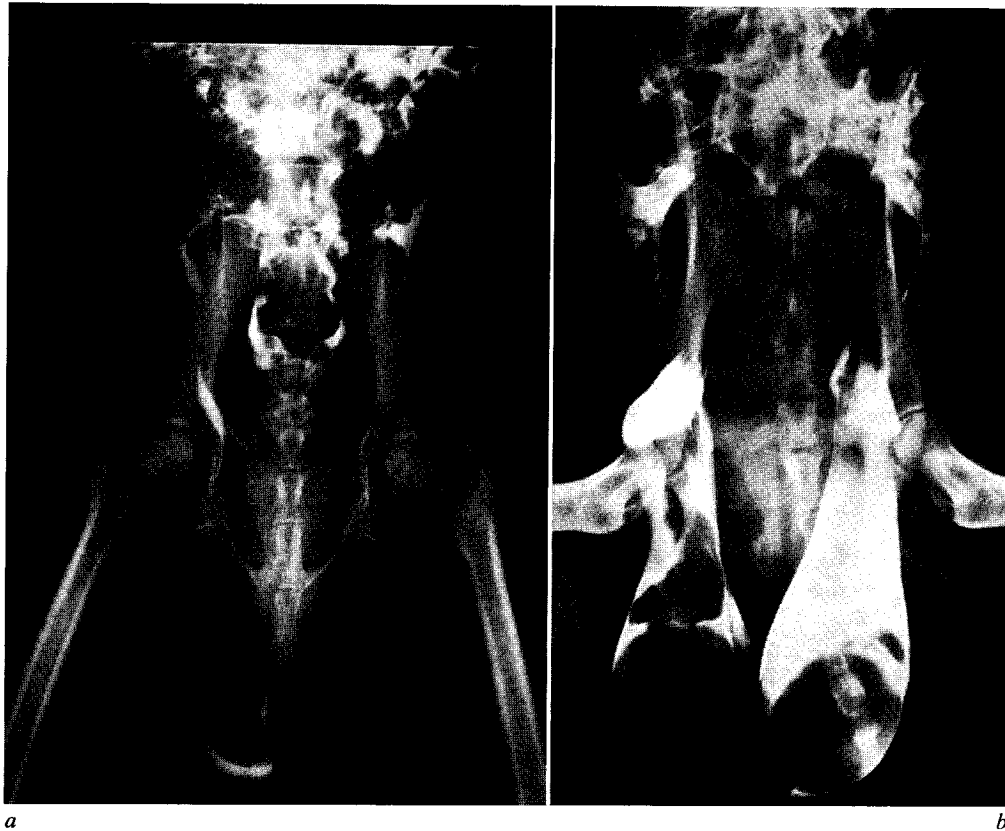


Fig. 2. a A right patent processus vaginalis is demonstrated. This herniogram in a male sooty mangabey (*Cercocebus torquatus*) shows contrast material in the right patent processus vaginalis surrounding the spermatic cord. Contrast material has drained into the scrotum and surrounds the right testis. A hernia or patent processus cannot be excluded on the left side without repositioning the animal to permit the contrast to outline that region of the pelvic peritoneum. *b* A peritoneogram demonstrating bilateral processus vaginalis. A patent processus vaginalis is present on both the left and right of a male chimpanzee (*Pan troglodytes*). The distended bladder has displaced contrast material from the central portion of the pelvis.

Diagnostic Criteria in Primate Animals

The inguinal herniogram or positive contrast peritoneogram is considered technically satisfactory when the contrast material outlines the peritoneum both medial and lateral to the so-called 'epigastric notch' formed by the inferior epigastric vessels (fig. 1).

The processus vaginalis is a sleeve of peritoneum that has its origin lateral to the inferior epigastric vessels at the inguinal ring and its termination in the scrotum. The

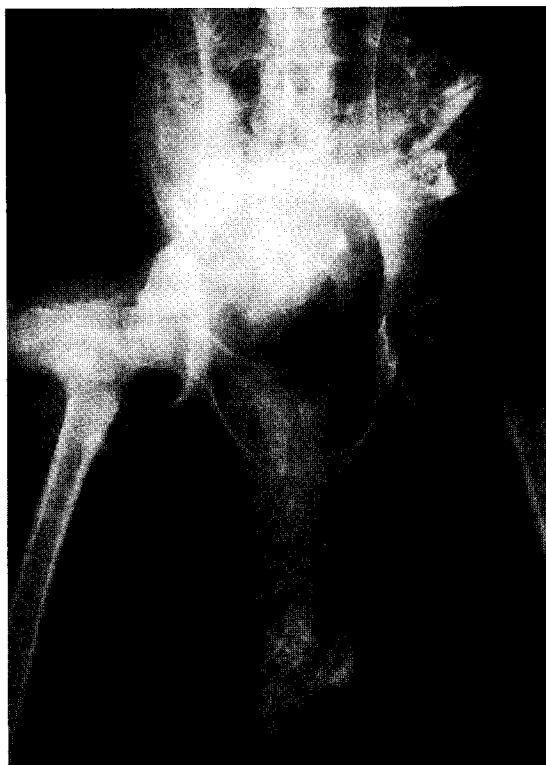

Fig. 3. A peritoneogram demonstrating an inguinal hernia. This herniogram in a male baboon (*Chueropithecus papio*) shows small bowel in the scrotum outlined by contrast material. This is indicative of a right inguinal hernia. No comment can be made about the left side because of inadequate placement of contrast material in this region.

entire processus vaginalis (fig. 2a, b) or only a portion of it may remain patent in the adult primate animal especially in the rhesus monkey. A cystic collection of fluid may occur at any point along the processus vaginalis and produce a hydrocele.

A hernia is present when bowel enters the patent processus vaginalis, distending it to form a hernial sac. When both contrast material and bowel are contained within the sac, the diagnosis of indirect inguinal hernia can be made (fig. 3). When bowel gas is present in the scrotum, and contrast material does not enter the patent processus, the usual cause is complete occlusion of the inguinal ring by bowel loops. A herniogram can then be obtained if the hernia is manually reduced. This is not always necessary when the diagnosis of hernia is confirmed on the initial radiograph. However, we still proceed with the study if there is suspicion of a hernia on the opposite side because we prefer to repair both sides in one operation due to anesthesia risks.

Technical problems in herniography include injection into the bowel, bladder, blood vessels or retroperitoneal structures. Mistakes occur due to failure to identify contrast in the retrovesical space posterior to the inguinal region which surrounds the rectum or vagina. This is easily clarified by a lateral view of the pelvic region.

Discussion

The initial event that produces weakness of the abdominal wall in the male primate is movement of the testicle from behind the peritoneum to the scrotum [3, 5]. As the testicle descends, it carries with it a double layer of peritoneum, the funicular process which in man is obliterated in the last month of fetal life. Failure of obliteration of the persistent peritoneal sac predisposes to development of an indirect inguinal hernia.

Using positive contrast peritoneography on 100 human patients, the accuracy of the herniogram is 97%, compared to 59% with physical examination [6]. Routine contralateral surgical exploration disclosed a hernia or patent vaginal process on the opposite side in 44% of infants and children. This meant that exploration of the opposite groin was unnecessary in 56% [6].

We use positive contrast peritoneography to define which animal has bilateral inguinal hernias and do not routinely explore both sides if the study shows a unilateral inguinal hernia. We have observed no significant complications from this procedure despite injection into the anterior abdominal wall, the bladder, and small bowel. This is probably due to the low toxicity of the meglumine diatrizoate and its rapid absorption.

References

- 1 DUCHARME, J.C.; BERTRAND, R., and CHACAR, R.: Is it possible to diagnose inguinal hernia by X-ray? A preliminary report on herniography. *J. canad. Ass. Radiol.* 18: 448-451 (1967).
- 2 EDWARD, J.G.: Strangulated inguinal hernia in a monkey. *Vet. Res.* 61: 387-388 (1949).
- 3 NETTER, F.H. and IASON, A.H.: Inguinal and femoral hernias. *Ciba Clin. Symp.* 18: 35-61 (1966).
- 4 OH, K.S.; DORST, J.P.; WHITE, J.J.; HALLER, J.A.; HELLER, R.M.; JAMES, A.E.; JOHNSON, B.A., and STRIFE, J.L.: Positive-contrast peritoneography and herniography. *Radiology* 108: 647-654 (1973).

- 5 SNYDER, W.H., jr. and GREANEY, E.M., jr.: Inguinal hernia; in MUSTARD, RAVITCH, SYNDER, WELCH and BENSON Pediatric surgery, pp. 692-707 (Year Book, Chicago 1969).
- 6 WHITE, J.J.; HALLER, J.A., jr., and DORST, J.P.: Congenital inguinal hernia and inguinal herniography. Surg. Clin. N. Amer. 50: 823-837 (1970).

Request reprints from: A. EVERETTE JAMES, jr., Department of Radiology and Radiological Science, The Johns Hopkins Medical Institutions, Baltimore, MD 21205 (USA)