

11/20/80

## Bone Lesions in Three Tree Kangaroos

Suzanne Kennedy, DVM; Richard J. Montali, DVM; A. Everette James, Jr., ScM, JD, MD;  
Mitchell Bush, DVM

THIS REPORT deals with 3 cases of proliferative disease of the bone in Matschie tree kangaroos (*Dendrolagus matschiei*) at the National Zoological Park. The osseous lesions had similar radiographic manifestations but dissimilar causes. One kangaroo had tuberculous osteomyelitis of the vertebral column and radius; the 2nd had a chondrosarcoma of the vertebral column and femur; and the 3rd had bilateral ulnar periosteal proliferation due to trauma. Clinical signs included partial or total disuse of one or more limbs in each case. Radiographic lesions involved an extremity in each case and the vertebral column in 2 cases. The difficulties in arriving at an accurate clinical diagnosis are discussed.

### Case Reports

**Case 1**—A 6-year-old, 6.8-kg, female Matschie tree kangaroo had a swelling at the base of the tail. Lethargy and weakness were the only other clinical signs of illness. The animal was restrained with 0.25 ml of the combination tiletamine hydrochloride and zolazepam,<sup>a</sup> in a 1:1 mixture, given intramuscularly for examination and radiography of the tail, which showed destruction of the 3rd, 4th, and 5th coccygeal vertebrae, with periosteal reaction and sclerotic bone changes (Fig 1A). A fracture was suspected.

After 12 days, a purulent exudate drained from 3 sinus tracts on the dorsum of the swelling. Survey radiography showed chronic cystic changes in the caudal lung field and calcific changes in the alveoli (Fig 2). Systemic treatment for osteomyelitis and chronic pulmonary disease was started with 35 mg gentamicin sulfate<sup>b</sup> and 1 g ampicillin<sup>c</sup> daily for 10 days. At this time, a central corneal ulcer and iritis were noticed in the right eye. Treatment began with chloramphenicol ophthalmic ointment<sup>d</sup> and atropine sulfate<sup>e</sup> twice daily.

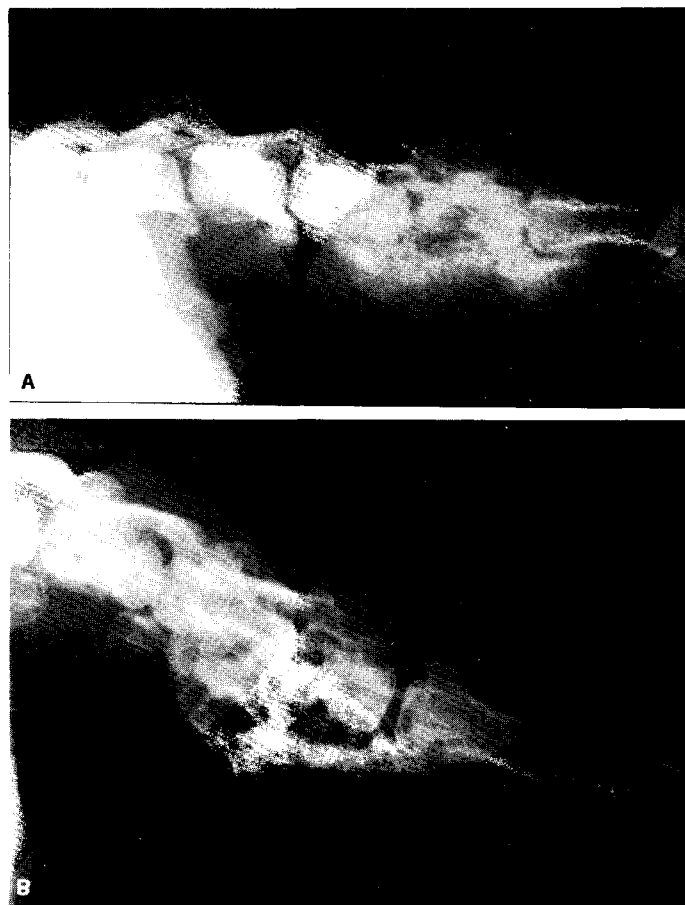


Fig 1—Lateral radiographs of coccygeal vertebrae (case 1).

A—The periosteal reaction and sclerotic bone change is most likely due to an inflammatory condition inasmuch as several adjacent vertebrae are involved.

B—Five months later, demineralization of the osseous structures is evident and periosteal reaction is decreased.

From the Offices of Animal Health (Kennedy, Bush) and Pathology (Montali), National Zoological Park, Smithsonian Institution, Washington, DC 20008, and the Department of Radiology and Radiological Sciences, Vanderbilt University Medical School, Nashville, TN 37232 (James). Dr. Kennedy's present address is Department of Environmental Practice, College of Veterinary Medicine, University of Tennessee, PO Box 1071, Knoxville, TN 37901.

<sup>a</sup> Telazol, Parke, Davis & Co, Detroit, Mich.

<sup>b</sup> Gentocin, Schering Corp, Kenilworth, NJ.

<sup>c</sup> Polyflex, Bristol Laboratories, Syracuse, NY.

<sup>d</sup> Chloromycetin Ophthalmic Ointment, 1%, Parke, Davis & Co, Detroit, Mich.

<sup>e</sup> Atropine Sulfate 1% Ophthalmic Ointment, Pharmaderm, Inc, Hicksville, NY.

After the 10 days of medication, there was no improvement. Culture of fluid removed from the anterior chamber of the right eye was negative for bacteria and fungi. Cultures of the tail lesion on fungus selection agar<sup>f</sup> and Sabouraud media were negative for fungi. *Pseudomonas aeruginosa* was cultured from the tail lesion and was sensitive to gentamicin, neomycin, and

<sup>f</sup> Mycosel, Baltimore Biological Laboratory, Baltimore, Md.

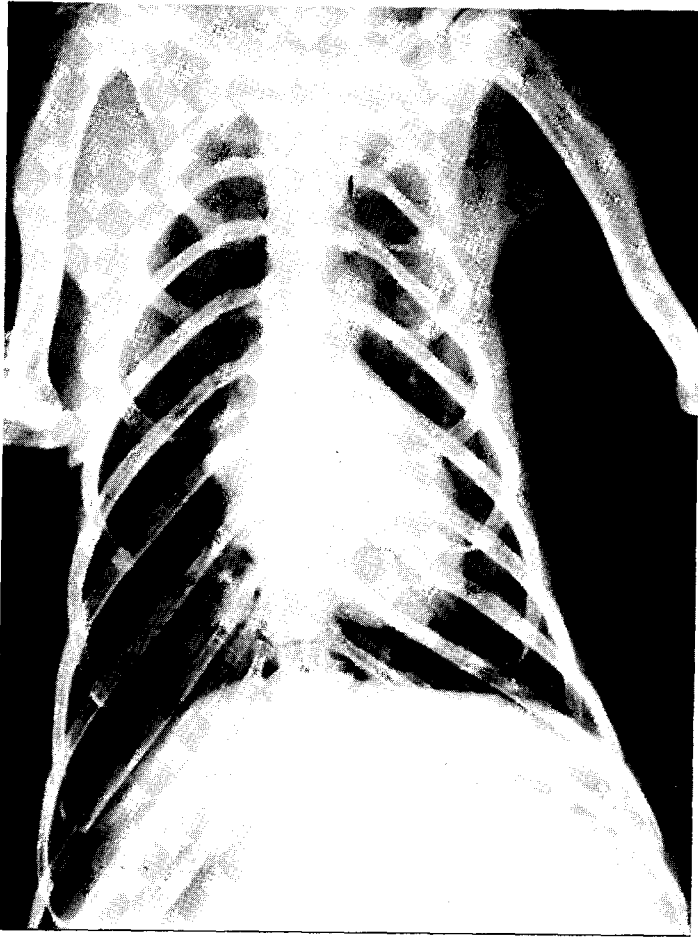


Fig 2—Ventrodorsal thoracic radiograph (case 1), showing chronic cystic changes in the caudal lung field and what appears to be calcific changes in the alveoli. These changes are consistent with chronic tuberculous lesions and other forms of chronic bronchiectasis.

polymyxin B. Systemic treatment was continued with gentamicin sulfate and ampicillin for 5½ weeks. The right eye was treated daily with a preparation of neomycin sulfate and dexamethasone<sup>‡</sup> for 2 weeks.

Progressive lameness developed in the left front limb. Radiography revealed a cystic demineralization pattern in the distal third of the radius and early destruction of the endosteal cortex (Fig 3). Biopsies of the radius and coccygeal vertebrae revealed granulomatous inflammation characterized by infiltrates of lymphocytes and plasma cells. Proliferative cartilaginous elements were within bony spicules from the coccygeal vertebrae. Ziehl-Neelsen stain for acid-fast bacilli, azure eosin, methenamine silver, and Brown-Brenn stains were negative for organisms.

After 3 months of hospitalization, the tree kangaroo was returned to its exhibit. For 1 month, the eye and tail lesions appeared to be stable. Two months later, the animal became weak and incoordinated. Radiographically, there was decreased periosteal reaction and sclerotic changes of the coccygeal vertebrae (Fig 1B), which suggested diminished inflammatory reaction. The following values were obtained from a lumbar spinal tap: WBC, 867/mm<sup>3</sup> (polymorphonuclear cells, 16%;

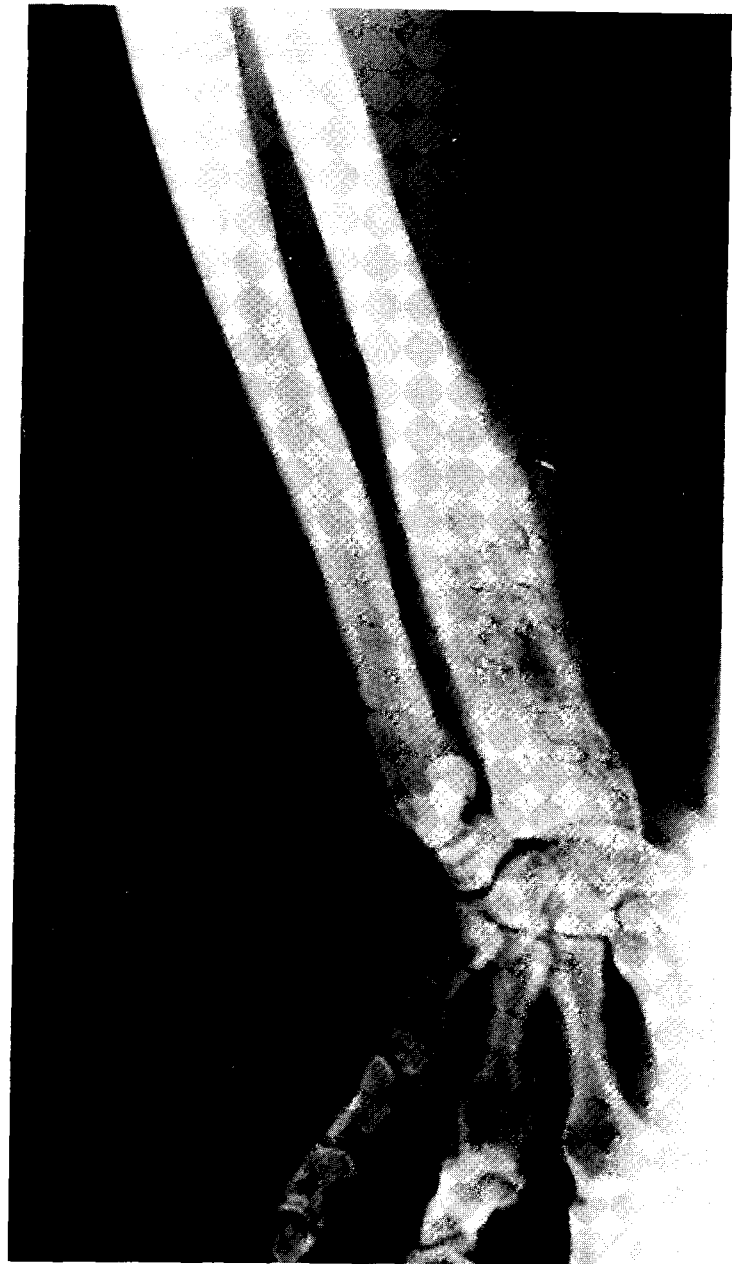

Fig 3—Anteroposterior radiograph of the left forelimb (case 1), showing sclerotic and destructive process expanding the cortex of the radius. A mixed linear periosteal reaction is at right angles to the cortex of the bone. The small radiolucencies mixed with overall radiopacity creates a "stippled" appearance.

lymphocytes, 83%; and monocytes, 2%); RBC, 10/mm<sup>3</sup>; and total protein, 580 mg/dl. Over the next 2 weeks, the animal's condition worsened and it was euthanatized.

During the course of the illness, the white blood cell count averaged 10,475/mm<sup>3</sup>, with lymphocytosis and an occasional increase in number of nonsegmented neutrophils. The total protein values ranged from 8.2 to 9.3 g/100 ml. Five months before the animal became ill, the total protein was 7.3 g/100 ml.

At necropsy, white nodules were seen throughout the lungs and in enlarged deep inguinal, mesenteric, and gastric lymph nodes. A greenish exudate was found within the meninges at the base of the brain. Micro-

<sup>‡</sup> Neo Decadron, Merck, Sharp & Dohme, West Point, Pa.

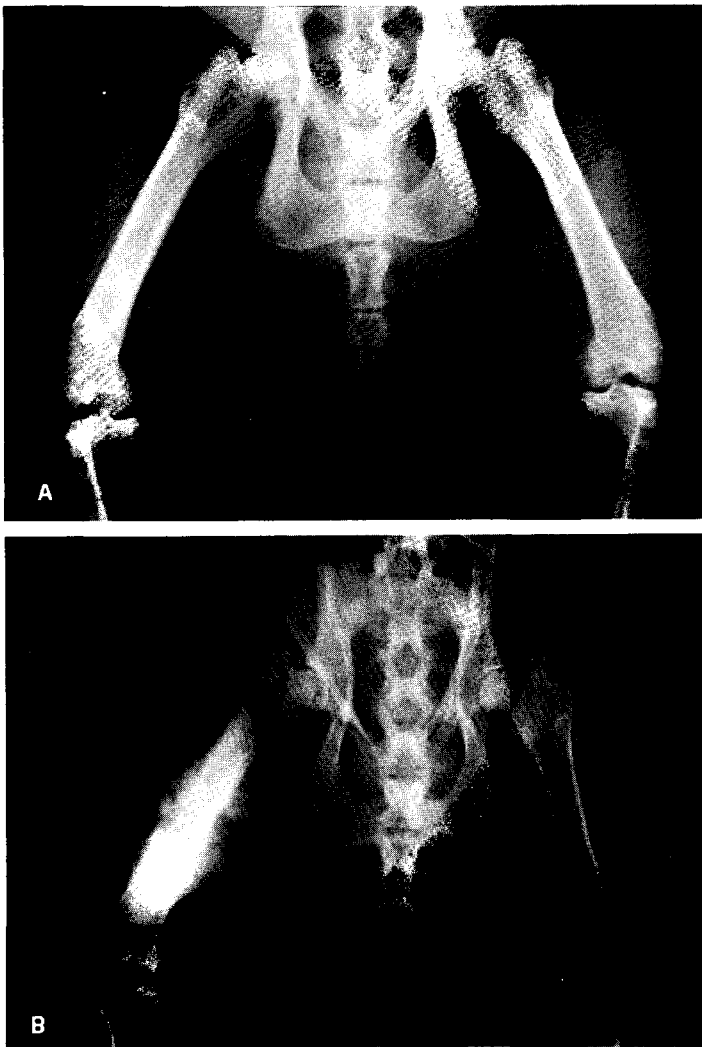


Fig 4—Ventrodorsal radiographs of pelvis and femurs (case 2).  
 A—In the distal two-thirds of the left femur, notice irregularity of the endosteal portion of the cortex. Within the medullary cavity is a sclerotic reaction. Mineralization is irregular and there is slight suggestion of periosteal involvement.  
 B—Four months later, there is a marked periosteal reaction involving the diaphysis, with destruction of most of the cortex.

scopically, pyogranulomas with giant cells were observed in all of these tissues. Sagittal section of the coccygeal vertebrae revealed numerous sinus tracts that contained caseous material. The eye had evidence of marked pyogranulomatous inflammation of the uveal tract and granulomatous inflammation around the optic nerve.

Acid-fast organisms were in the lungs and eye lesions but were not evident in the brain and lymph node lesions. Fungus selection agar<sup>7</sup> cultures of the bone biopsy specimens taken 4 months earlier had an acid-fast, branching filamentous organism identified as *Mycobacterium avium*, serotype I, by Veterinary Services Laboratory, Ames, Iowa.

**Case 2**—A 1½-year-old, 6-kg, female Matschie tree kangaroo developed paresis of the left hindlimb. The animal was restrained with 160 mg ketamine HCl<sup>8</sup>

given intramuscularly, and was tuberculin tested with 0.1 ml of mammalian old tuberculin (OT) in the left eyelid and left half of the abdomen, and 0.1 ml avian OT in the right eyelid and right half of the abdomen. Twenty-four hours later, the avian tuberculin injection site on the right half of the abdomen was raised and reddened. Seventy-two hours later, both the eyelid and abdominal site for avian OT were interpreted as positive. The mammalian tuberculin sites were both negative. Ten months earlier, this animal had been tested with avian OT and was negative.

Radiography of the vertebral column was normal, but there was an irregularity of the endosteal portion of the cortex in the lower two-thirds of the left femur, with increased medullary density (Fig 4A). The distal half of the last coccygeal vertebra was completely lysed. The tail had been bitten 9 months earlier and had become a chronic problem during the intervening months from repeated traumatic incidences. The paresis disappeared without treatment during 9 days of hospitalization, and the kangaroo was confined to a large pen.

Four days later, the animal was paralyzed. Proprioceptive responses were absent in both hindlimbs. The knee-jerk reflex was depressed. Deep pain reflex could be elicited only by firmly pinching the skin between the toes with a hemostat. There was sensation along the back with a needle prick (panniculus reaction), and the animal could urinate and defecate normally. Dexamethasone<sup>1</sup> (1 mg) was given intramuscularly daily for 4 days, with decrease of dose to 0.5 mg for 3 days, then 0.25 mg for 3 more days.

The paralysis progressed over the next 7 days, until all reflexes were absent in the hindquarters. Severe muscle atrophy followed within several weeks.

A biopsy of the left femur showed cartilaginous metaplasia with little inflammation. Special stains, including acid-fast, Gram, and methenamine silver, were negative, as were bacterial and fungal cultures. Values for routine hematology and a spinal tap were within normal limits.

The kangaroo was euthanatized 3 months after onset of illness. Postmortem radiography of the left femur showed a “sunburst” pattern of the periosteum, characteristic of osteosarcomas<sup>1</sup> (Fig 4B). The periosteal changes had occurred over 6 weeks. Until then, the cortex had been intact radiographically and there was only minimal periosteal elevation. The dorsal laminae of T<sub>13</sub>, L<sub>1</sub>, and L<sub>2</sub> were sclerotic and had undefined edges.

Necropsy revealed a hard mass involving the mid-shaft of the left femur. Its cut surface was irregular, glistening-white, and had areas that radiated from the cortex. A similar mass involving vertebrae T<sub>13</sub>, L<sub>1</sub>, and L<sub>2-3</sub> protruded into the spinal canal and compressed the spinal cord. A few scattered, pearl-like nodules ranging from 1 to 5 mm in diameter were in the lungs.

Microscopically, the masses consisted of irregular sheets and islands of pleomorphic, cartilage-like cells in

<sup>1</sup> Azium, Schering Corp, Kenilworth, NJ.

<sup>7</sup> Combiotic, Pfizer, Inc, NY.

<sup>8</sup> Betadine Solution, The Purdue Frederick Co, Norwalk, Conn.

<sup>9</sup> Nitrofurazone 0.2% Soluble Dressing, Wolins Pharmacal Corp, Melville, NY.

<sup>8</sup> Ketaset, Bristol Laboratories, Syracuse, NY.

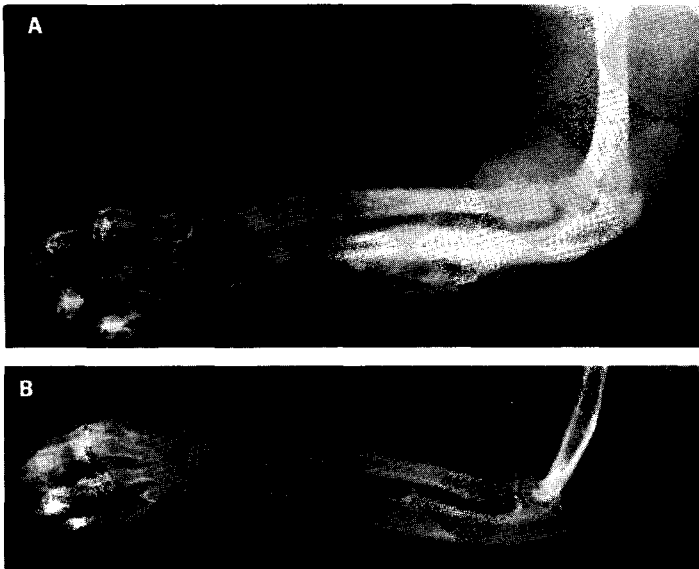


Fig 5—Lateral radiographs of left radius and ulna (case 3).  
 A—Marked periosteal reaction is evident in the midshaft of the ulna. The remainder of the bony cortex is irregular and thickened.  
 B—Four months later, the ulna has almost completely remodeled.

varying stages of differentiation. Enchondral bone formation occurred in some of the neoplastic cartilaginous areas. Metastases were in the lungs and kidneys. Although, radiographically, the tumor had some features of an osteosarcoma, it was classified as a chondrosarcoma because of its histologic appearance. Whether the femur or vertebral column was the primary site of the chondrosarcoma could not be determined.

Severe myelomalacia in compressed areas of the spinal cord was characterized by foci of glial cells and axonal degeneration.

**Case 3**—A 5-month-old, 2.3-kg, female Matschie tree kangaroo was admitted with a swollen left front limb. This animal was walking on the knuckles of its left paw and could not extend its digits completely when grasping food to eat. The animal was given 50 mg ketamine HCl intramuscularly for restraint. Radiography showed marked periosteal reaction of the ulna and soft tissue enlargement around the humerus (Fig 5A). A healing bite wound was found on the forearm.

Serosanguineous fluid withdrawn from the soft tissue swelling around the humerus was sterile on culture. A drainage site was made, and clear orange fluid drained for 2 weeks. The animal was treated with 200,000 units procaine penicillin G and 0.25 g dihydrostreptomycin sulfate<sup>1</sup> twice a day for 4 days, then the dose was halved for 4 more days.

Repeat radiography of the left ulna showed little change after a week. Biopsy of the involved bone showed cartilaginous metaplasia with inflammation. The biopsy material did not grow on culture and was negative for acid-fast stains.

Tuberculin tests with mammalian and avian old tuberculin were negative. The WBC count was normal and the alkaline phosphatase was 1,690 units/L. The animal was released in 3 weeks with all soft tissue swelling resolved and the biopsy site healed.

Ten days later, the animal was readmitted with multiple draining fistulas of the left arm. The right arm also was swollen. Radiographically, the left ulna had not changed. Periosteal bone formation was evident in both arms. Serosanguineous fluid aspirated from the soft tissue swelling of the right arm was sterile on culture. The skin over the right forearm had what appeared to be scars from a bite wound.

Treatment for the infected left arm was 10 mg gentamicin sulfate subcutaneously daily for 4 days. The fistulas were flushed with organic iodide<sup>2</sup> daily and wrapped with a nitrofurazone<sup>1</sup> bandage. The fistulas took nearly 4 weeks to heal completely, at which time the animal was returned to its exhibit.

Radiographs taken 6 weeks after the 1st examination showed regression and remodeling of the original periosteal bone proliferation. Radiographs taken 4 months later showed a nearly normal left ulna except for cortical thinning at the site of the most severe periosteal reaction and a sharp projection of cortical bone into the interosseous space (Fig 5B). Further problems were not encountered for over a year, though use of the left paw is still impaired and the animal walks on its knuckles. It was concluded that the periosteal reaction was a result of trauma.

## Discussion

Differential diagnoses for the 1st case were fungal or bacterial osteomyelitis of hematogenous origin because of the ocular and pulmonary involvement. Tuberculosis was not considered initially. Reports of tuberculosis in marsupials are sporadic. As of 1958, 18 cases of tuberculosis had been reported in marsupials in which the *Mycobacterium* had been typed. Ten of these cases were caused by *M bovis*, 2 by *M tuberculosis*, and 6 by *M avium*.<sup>2</sup> Most of these cases of tuberculosis involved lungs, liver, and lymph nodes. One case was described in a wallaby (*Wallabia* sp) that had a tuberculous abscess in the spinal cord caused by *M avium*.<sup>3</sup> Of 4 cases of tuberculosis of the bone in Bennett's wallabies (*Protemnodon rufogrisea frutica*), 3 involved the spinal column and 1 involved the tibia and fibula.<sup>4</sup> In 1976, a long-nosed rat kangaroo (*Potorous tridactylus*) at the National Zoological Park developed arthritis of a hock joint, which contained acid-fast organisms.<sup>5</sup>

Radiographically, tuberculous osteomyelitis can be difficult to distinguish from pyogenic osteomyelitis, particularly when the tuberculous infection is complicated with opportunistic bacteria. This was the case with the 1st tree kangaroo, which had a secondary infection with *Pseudomonas* in the coccygeal vertebrae.

Tuberculosis and white muscle disease were considered in the differential diagnosis when the 2nd kangaroo developed hindlimb paresis. Degenerative myopathy due to vitamin E deficiency has been known in marsupials since 1940.<sup>6</sup> However, white muscle disease was eliminated as a diagnosis when flaccid paralysis occurred. The paralysis corresponded to that seen with 3 wallabies with spinal tuberculous lesions.<sup>4</sup> In those cases, results of cervical skin testing were negative. In the 2nd tree kangaroo, positive skin tests reinforced the diagnosis of tuberculosis.

Tuberculosis was an unlikely diagnosis in the 2nd kangaroo, inasmuch as the radiographic lesions progressed in the femur, suggesting neoplastic changes. The radiographic appearance of the chondrosarcoma suggested the sunburst pattern of an osteosarcoma. Chondrosarcomas are classically described as osteolytic lesions, with or without defined sclerotic margins that contain a "snowflake" type of calcified chondroid matrix.<sup>7</sup> They usually develop at the metaphysis of a long bone, though occasionally they develop in the diaphysis. Endosteal cortical thickening is characteristic of these tumors. Large central chondrosarcomas will eventually invade through the cortex, defying radiologic classification,<sup>7</sup> as was the case with the 2nd kangaroo.

Marsupials seem to have a high incidence of tumors. This past year at the National Zoological Park, a perineal squamous cell carcinoma was seen in a Tasmanian devil (*Sarcophilus harrisii*) and a hepatocellular carcinoma in a New Guinea native cat (*Dasyurops maculatus*). Neoplasms have been reported in other dasyurid marsupials, but none involved bone.<sup>8</sup>

Though tuberculosis was included as a differential diagnosis for the 3rd kangaroo, it was considered unlikely due to the animal's young age. Because the periosteal reaction progressively diminished and remodeling of the ulnae occurred after 6 months, neoplasia was unlikely. The inability of this animal to extend its digits was probably a result of radial nerve damage incurred at the time of the original trauma.

All 3 kangaroos had similar clinical signs, with radiographic lesions of a long bone. Two of the kangaroos had radiographic lesions involving the vertebral column. Considering that all 3 animals had been housed in the same exhibit and became ill within a 2-year period, a common cause, such as tuberculosis was considered. Though the cause was different for each case, tuberculosis should always be considered in marsupials with neurologic signs of unknown origin, bone lesions, or evidence of granulomatous disease until a definitive diagnosis can be made.

## References

1. Morgan JP: *Radiology in Veterinary Orthopedics*. Philadelphia, Lea and Febiger, 1972.
2. Leslie IW: Tuberculosis in a wallaby caused by the avian type tubercle bacillus. *Br Vet J* 114:358-360, 1958.
3. Tilden EB, Williamson WM: Unusual tuberculosis lesion in a wallaby. *JAVMA* 131:526-527, 1957.
4. Hime JM, Jones DM: Bone tuberculosis in wallabies (*Protemnodon rufogrisea fruticosa*). *J. Small Anim Pract* 13:91-96, 1972.
5. Montali RJ, Bush M, Thoen CO, et al: Tuberculosis in captive exotic birds. *JAVMA* 169:920-927, 1976.
6. Goss LJ: Muscle dystrophy in tree kangaroos associated with feeding of cod liver oil and its response to alpha-tocopherol. *Zoologica* 25:523-524, 1940.
7. Edeiken J, Hodes PJ: *Roentgen Diagnosis of Diseases of Bone*, ed 2. Baltimore, Williams & Wilkins Co, 1973, vol 2.
8. Attwood HD, Woolley PA: Spontaneous malignant neoplasms in dasyurid marsupials. *J Comp Pathol* 83:569-581, 1973.





