

Laparoscopy in Zoological Medicine

Mitchell Bush, DVM; David E. Wildt, PhD; Suzanne Kennedy, DVM; Stephen W. J. Seager, DVM

SUMMARY

The technique of laparoscopy was adapted and utilized in zoological medicine for various mammals, birds, and reptiles for reproductive and diagnostic studies as well as clinically related research. It was concluded that since anesthesia was routinely required for most manipulative procedures in zoo animals, and since laparoscopy adds little additional risk, the use of this technique provides an additional diagnostic aid when indicated.

Laparoscopy was found to be effective for evaluating reproductive status, particularly ovarian anatomy and function, direct visual biopsy of internal organs, sex determination in selected birds, and as a surgical means of fertility control.

ATTEMPTS have been made for over a century to visualize abdominal contents as a diagnostic aid, using hollow tubes and modified telescopes. These procedures became practical only after the development of improved lenses and sophisticated fiber optic light systems. Because of these technical improvements, laparoscopy (or endoscopy) is widely used in human medicine for surgical procedures including oviductal ablation for fertility control and general diagnostic evaluation of the abdominal cavity.^{1,2} Reports on the use of laparoscopy in veterinary medicine are limited.^{3,4} This technique has been

used mainly as a research tool for the study of the female reproductive organs and activity in sheep,⁵ pigs,^{6,7} dogs,^{4,8} cats,⁴ cows,^{9,10} horses,¹¹ and primates.^{12,13} The diagnostic and surgical application of laparoscopic methods in veterinary medicine is still developing. This report deals with the uses of laparoscopy for various diagnostic and surgical procedures, as a research tool for reproductive studies, and as a management aid in the field of zoological medicine. Our success with this technique illustrates the potential of laparoscopy and laparoscopic photography as teaching aids for the study of internal organ structure and function.

Materials and Methods

Aseptic techniques and sterilized instruments were used. Methods of sterilization of laparoscopic equipment depended on the manufacturer's recommendations. The laparoscopic telescope generally should not be autoclaved. Instruments were immersed in a germicidal solution* or were gas sterilized. When the former procedure was utilized, the equipment was rinsed with sterile water or physiologic saline solution prior to insertion into the body cavity. In over 250 laparoscopic procedures in zoo animals, this method of chemical cleaning did not cause any adverse effects.

The laparoscope (Fig 1A) is a telescope containing multiple lenses (up to 30), which produces a 180-degree viewing field with extensive depth of vision. Diameter and length of the laparoscope vary from approximately 2 to 10 mm and 15 to 35 mm, respectively. A light projector (Fig 1A) was used to generate the illumination for visualization. The light source was a heavy-duty projector with a 150-W diagnostic and 1,000-W photographic lamp. Light from the projector was transferred to the laparoscope by means of a flexible fiber optic cable (Fig 1A).


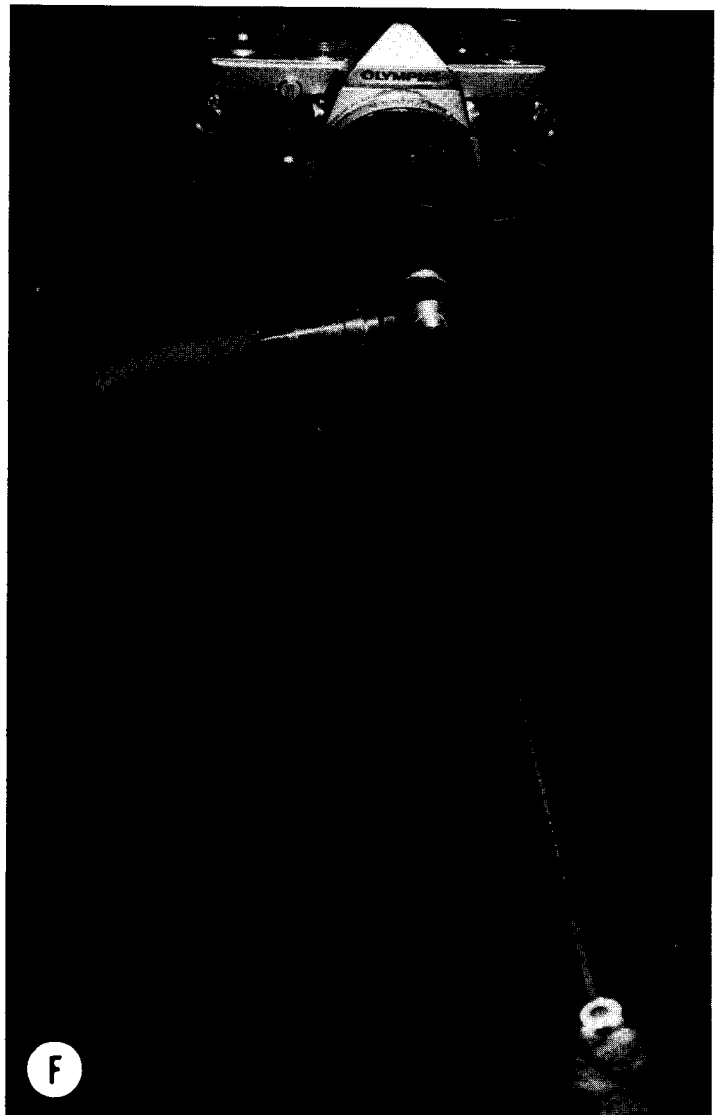
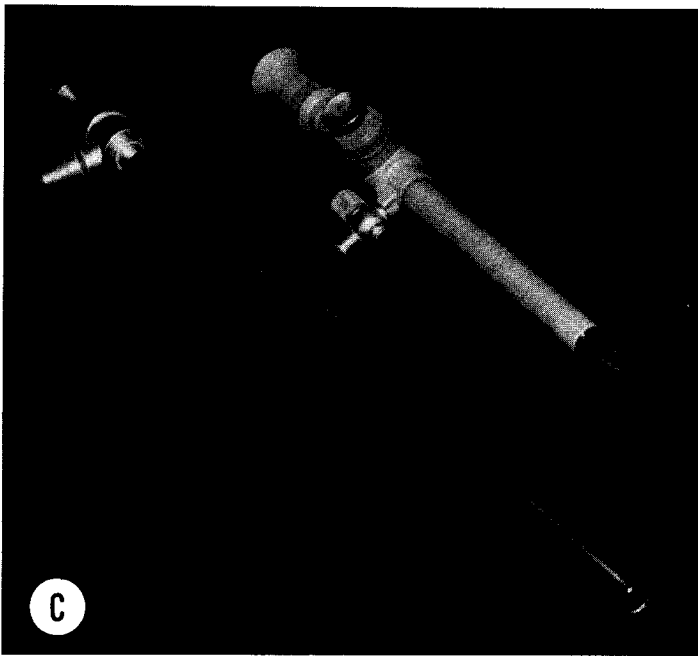
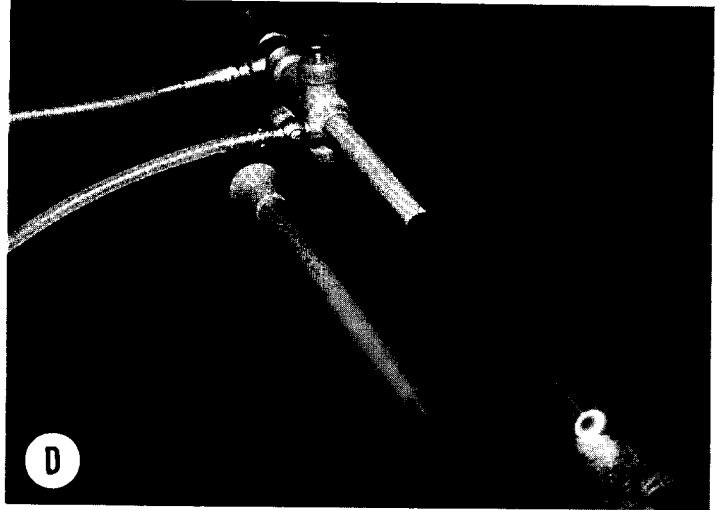

Laparoscopic examination of mammals requires general anesthesia. The abdomen was clipped and the skin was washed and prepared for aseptic surgery. The animal was placed in a supine position. Pneumoperitoneum was created to facilitate introduction of the various instruments and to ensure adequate visualization. Either 100% CO₂ or 5% to 10% CO₂ and air was used to establish and maintain

From the Office of Animal Health, National Zoological Park, Smithsonian Institution, Washington, DC 20008 (Bush, Kennedy); and the Institute of Comparative Medicine, Baylor College of Medicine, Houston, TX 77030 (Wildt, Seager). Dr. Kennedy's current address is Department of Environmental Practice, College of Veterinary Medicine, University of Tennessee, PO Box 1071, Knoxville, TN 37901.

The authors thank Dr. B. Whitlock and staff of the Houston Zoological Gardens, Dr. W. Boever and staff of the St Louis Zoological Park, and Dr. R. Harrison of the Delta Regional Primate Research Center.

Aspects of this work performed in the Institute of Comparative Medicine were partially funded by a grant from the Ralston Purina Company, St Louis, Mo.

* Nolvasan (chlorhexidine), Fort Dodge Laboratories, Inc, Fort Dodge, Iowa.



pneumoperitoneum. The gas was regulated by an insufflator that recorded the rate, amount, and pressure. From the insufflator, the gas was transmitted by tubing to a Verres needle (Fig 1B) that was inserted into the abdomen on one side of the median line. The Verres needle contains a spring that advances a blunt probe into the needle's lumen to prevent damage to adjoining viscera after the abdominal wall is penetrated. A valve at the hub of the needle controls the flow of gas. The Verres needle can also be used as a blunt probe for minor manipulations during laparoscopy. Gas was infused until the abdomen was distended, making the skin slightly tense to the touch, but not compromising respiration. The intraabdominal pressure from the gas should be no greater than 30 mm of mercury.

After insufflation, the animal was tilted to a head-down position of approximately 30 degrees to displace the intestines cephalad. A skin incision (1 to 2 cm) was made at the site of insertion, usually midline at the umbilicus. The trocar with cannula (Fig 1C) was inserted through the skin incision and the abdominal wall at an angle of 30 degrees, angling caudally. Elevating the skin posteriorly with forceps and using a slight rotating motion on the trocar aided the insertion procedure. The trocar was then removed from the cannula and the laparoscope was inserted through the cannula (Fig 1D) for viewing of the abdominal contents (Fig 2).

In the supine position, the contents of the pelvic canal can be viewed, including the bladder, ovaries and uterus of the female (Fig 3) and the vas deferens of the male. To view the remaining abdominal contents, the animal was placed in a level or slightly head-up position to facilitate viewing abdominal organs anteriorly. Adequate visualization can be made of the liver and gallbladder (Fig 4), spleen, stomach, and intestines. To view the kidneys, the animal was placed in a level position and rotated laterally so that the kidney to be viewed was slightly dorsal. This allowed adequate visualization and access to the desired kidney.

Additional specialized instruments used during some laparoscopic examinations or surgery included grasping forceps, scissors, or biopsy forceps (Fig 1E). These instruments were inserted to one side of the median line through an accessory abdominal cannula near the site of desired use to allow various manipulations and surgical or electro-surgical procedures.

To perform procedures such as biopsy of liver, spleen, or ovary, the biopsy forceps was inserted through the accessory cannula to the desired organ and the selected site was biopsied. The biopsy site was observed afterward to ensure that excessive bleeding did not occur (Fig 5, 6, and 7). In the event of problem hemorrhage, the biopsy forceps can be attached to an electro-surgical unit to allow coagulation of the bleeding site. For kidney biopsy, a biopsy needle was inserted through a surgically prepared skin site

in the paralumbar area. The needle was directed into the desired part of the kidney while under direct laparoscopic visual observation (Fig 8).

At the end of the laparoscopic examination, the pneumoperitoneum was relieved by removing the laparoscope and evacuating the gas slowly through the open cannula. If the gas was relieved too rapidly, there could have been a potential for vascular collapse, with sudden redistribution of abdominal pressure and blood flow; also, there was a greater tendency for fat or omentum to herniate through the incision site. The cannulas and Verres needle were withdrawn, and the incision and puncture site were closed by a routine 2-layer suture method.

Laparoscopy in birds is facilitated by the presence of air sacs, which eliminate the need for insufflation. Birds usually require anesthesia prior to the examination. The anesthetic of choice for examinations is a dissociative anesthetic such as ketamine hydrochloride,^b which may be supplemented with a gaseous anesthetic such as halothane^c or nitrous oxide, or both. For most routine examinations, the bird is placed in right lateral recumbency, with the wings dorsal and the left limb placed anterior or posterior to expose the area behind the last rib. The positioning of the bird depends on the species of bird being examined and the organ to be visualized, since different species of birds have varying anatomic relationships. The 2.5-mm laparoscope (arthroscope) is the instrument of choice for avian laparoscopy (Fig 9). The trocar and cannula are inserted with a controlled pressure in birds weighing > 1 kg, but in smaller birds or when hepatomegaly is suspected, careful dissection should be used to enter the abdominal cavity. Using this procedure, we have successfully laparoscoped birds weighing as little as 50 g. In birds, the control of skin hemorrhage is important; 1 to 2 drops of blood entering the abdominal cavity could obliterate the viewing field. In avian laparoscopy, the organs routinely visible are the air sacs, heart, lungs, liver, spleen, kidneys, adrenal glands, gonads, and intestines (Fig 10-13). To view all of these structures, it is necessary to view through the air sacs or to puncture an air sac. Adverse effects have not been observed in over 200 cases from puncturing the air sacs to facilitate examination. When the examination is completed, the small incision site usually requires no suturing. Occasionally mild subcutaneous emphysema develops, but this subsides in 2 to 3 days.

The laparoscope has also been used to examine selected reptilian species, including the snake and turtle. Examination of both of these species requires general anesthesia, which is induced with halothane and nitrous oxide. The site for insertion of the trocar and cannula in the snake depends on the anatomic area where viewing is required.

^b Ketaset, Bristol Laboratories, Syracuse, NY.

^c Fluothane, Ayerst Laboratories, New York, NY.

Legends for Illustrations on Facing Page

Fig 1A—Light source, with fiber optic cable conducting light to a 10-mm laparoscope. A 5-mm laparoscope and a 2.5-mm laparoscope, or arthroscope, are pictured also.

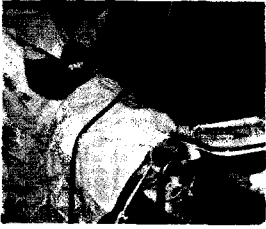B—Two Verres needles. The top needle has the blunt probe retracted for penetrating the abdominal wall and the 2nd needle has the blunt end protruding, as occurs when abdomen has been penetrated. The valves at the base of the needle control insufflating gas flow.

C—The trocar cannula and the 10-mm laparoscope.

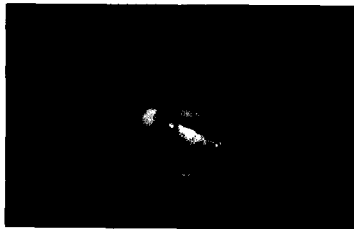D—The trocar is removed and the laparoscope is inserted through the cannula. The fiber optic light cable is attached to the laparoscope and the hose from the insufflator is attached to the cannula.

E—Three accessory instruments (forceps for grasping, for biopsy, and for cutting) and the accessory trocar and cannula used for inserting them into the abdomen.


F—Camera attached to laparoscope.



2




3



4




5



6



7



8



9



10



11



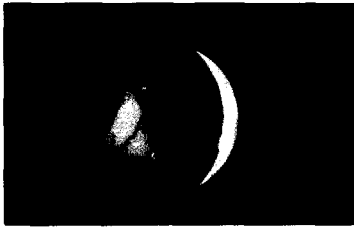12



13



14

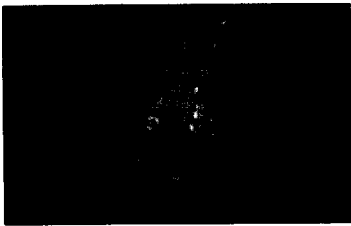

15

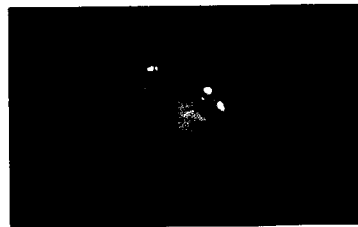


16

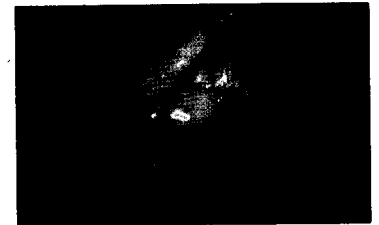Fig 2—Laparoscopic examination on a female cheetah (*Acinonyx jubatus*). The Verres needle is being used for minor intraabdominal manipulations.
Fig 3—Reproductive organs of the baboon (*Papio* sp), illustrating the vascular simplex uterus, with bladder in the background. The Verres needle is being used to lift the left ovary, which contains a corpus luteum.
Fig 4—The liver and gallbladder of an adult male clouded leopard (*Neofelis nebulosa*).
Fig 5—Biopsy forceps removing a specimen of tissue from the liver of a crab-eating fox (*Cerdocyon thous*).
Fig 6—Site on cheetah's liver following biopsy.
Fig 7—Lion (*Panthera leo*) ovary following biopsy.
Fig 8—Biopsy needle being inserted into kidney of a cheetah.
Fig 9—Arthroscope inserted into the abdominal cavity of a black-headed caique (*Pionites melanocephala*).
Fig 10—Pale adrenal gland, pigmented testicle, and reddish brown kidney in a salmon-crested cockatoo (*Cacatua moluccensis*).
Fig 11—Spleen of a bare-throated tree partridge (*Arborophila brunneopectus*).
Fig 12—Testicle of an adult sandhill crane (*Grus canadensis*).
Fig 13—Ovary of an adult blue peafowl (*Pavo cristatus*).
Fig 14—Lung and liver of an adult male box turtle (*Terrapene carolina*).
Fig 15—Testicle and seminiferous tubules of an adult box turtle.
Fig 16—Television camera attached to laparoscope for color videotaping of an internal examination.




17



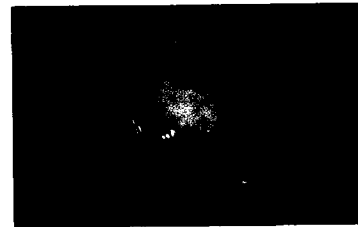
18



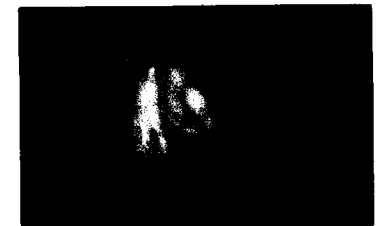19




20



21



22



23



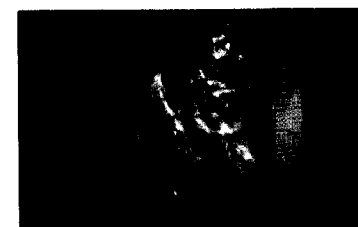
24




25




26



27



28



29A



29B



29C

Fig 17—Quiescent ovary of an adult cheetah. The fimbriated portion of the reproductive tract has been removed with the manipulatory probe and lies above and behind the ovary, as viewed.

Fig 18—Ovary of an adult cheetah containing 2 slightly raised preovulatory follicles, which are generally clear in appearance and contain small, distinct vascular patterns on their surface.

Fig 19—Ovary of an adult cheetah containing a distinct ovulation site (corpus hemorrhagicum) on the medial pole.

Fig 20—Quiescent ovary of an adult jaguar (*Panthera onca*).

Fig 21—Ovary of adult jaguar containing mature corpora lutea. One corpus luteum is located dorsally and 2 are located on the ventral portion of the ovary.

Fig 22—Elongated uterine horn of a jaguar and its anatomic relationship to the medial portion of the left ovary. A manipulatory forceps is being used to hold up the uterine horn.

Fig 23—Ovary of an adult Bengal tiger (*Panthera tigris*) containing mature yellowish appearing corpora lutea.

Fig 24—Adhesion in the gorilla (*Gorilla gorilla*) between intestine and abdominal wall.

Fig 25—Liver of a vulturine guineafowl (*Acryllium vulturinum*) with avian tuberculosis. White granulomas are on the surface of the liver.

Fig 26—Aspergillosis on the air sac in an Argus pheasant (*Argusianus argus grayi*).

Fig 27—Liver of an adult cheetah with chronic, progressive liver disease.

Fig 28—Ovary of adult lion containing multiple cystic-appearing follicles.

Fig 29A—Vas deferens of a male crab-eating fox (*Cerdocoyon thous*).

B—Vas deferens being cauterized prior to resection.

C—Severed vas deferens of the fox.