

***Parelaphostrongylus tenuis* in captive reindeer and sable antelope—**

Donald K. Nichols, DVM, Richard J. Montali, DVM, Lyndsay G. Phillips, DVM, Thomas P. Alvarado, DVM, Mitchell Bush, DVM, and Larry Collins, MS, Departments of Pathology and Animal Health, National Zoological Park, Smithsonian Institution, Washington, DC 20008 and the Conservation and Research Center, Front Royal, VA 22630

THE NATIONAL ZOOLOGICAL PARK (NZIP) maintains a facility known as the Conservation and Research Center (CRC) for research and captive propagation of exotic animal species. The CRC is located on 3,150 acres of land in the Shenandoah Valley near Front Royal, Va. The facility was opened in 1974, at which time the first exotic hoofstock were moved from NZIP to CRC.

In 1982, cerebrospinal parelaphostrongylosis was diagnosed in 3 male and 3 female reindeer (*Rangifer tarandus tarandus*; reindeer No. 1 through 6) from the herd kept at CRC. Apparent lameness in one or more limbs and progressive hindlimb ataxia and weakness developed in the 6 affected reindeer. Head tilt and/or paraplegia also was seen in one or more of these 6 reindeer. Repeated hemograms and results of serum biochemical analyses of each animal and evaluation of a CSF sample collected from the first affected reindeer were normal for reindeer at the NZIP clinical pathology laboratory. Dexamethasone and fluids were administered parenterally to all 6 reindeer. Reindeer 4, 5, and 6 also were given SC injections of levamisole (5.5 to 11.0 mg/kg of body weight). Five of the 6 reindeer died or were euthanatized as a result of the disease; the 6th reindeer, with neurologic signs, died due to other causes.

Complete necropsies were performed on the affected reindeer. Brains and spinal cords were removed, examined, and placed in 10% neutral-buffered formalin. Spinal cords were sectioned transversely along the entire length at 2- to 4-cm intervals. Selected sections from the visceral organs,

brain, and each segment of the spinal cord were processed routinely and examined microscopically.

Foci of hemorrhage were visible on the surface of the leptomeninges and/or within the spinal cords in 5 of the 6 reindeer; the spinal cord of reindeer 5 was palpably softer in these areas. In reindeer 3, two nematodes, 5- to 6-mm long, were seen and were removed from the subdural space of the thoracic spinal cord. On the basis of external morphologic features, these parasites were identified as 4th-stage larvae of *Parelaphostrongylus tenuis*. Microscopic lesions in the CNS of the 6 reindeer were consistent with those described in reindeer and caribou (*Rangifer tarandus terraenovae*) with *P. tenuis* infections.¹⁻³ Sections of *P. tenuis* larvae were seen in the white matter of the lumbar spinal cord from reindeer 4.

The remainder of the reindeer herd at CRC was moved to pastures that were considered less likely to contain infective forms of *P. tenuis*. Further disease problems due to this parasite were not seen in the remaining reindeer.

In November 1984, a 4.5-year-old female sable antelope (*Hippotragus niger*; antelope 1) at CRC was seen stumbling and standing away from the rest of the herd. The next day, she was recumbent and unable to stand. Supportive treatment with dexamethasone, vitamins, and oxytetracycline was ineffective. Hemograms and results of CSF analysis were normal for sable antelope at the NZIP laboratory. The antelope was euthanatized 4 days after the onset of illness.

The following month (December 1984), a 5-year-old female sable antelope (antelope 2) from the same herd developed mild hindlimb ataxia. This animal was treated with ivermectin (0.6 mg/

kg of body weight, IM) and dexamethasone (1 mg/kg, IV). Supportive therapy similar to that given to antelope 1 was administered during the next 3 weeks; 21 days after the onset of ataxia, this animal's clinical condition acutely worsened and the animal could not stand. A CSF sample was collected and the antelope was euthanatized. Evaluation of the CSF indicated only iatrogenic blood contamination. Hematologic and serum biochemical findings during the course of the illness were normal for sable antelopes at the NZIP clinical pathology laboratory.

Complete necropsies were performed on both sable antelope, as described for the reindeer. A moderate amount of clotted blood was found subdurally around the cerebellum and medulla of antelope 1, but the remainder of the CNS was normal grossly. In antelope 2, multifocal meningeal hemorrhages were seen along the cervical and thoracic segments of the spinal cord. The cord was sectioned in these areas and focal cavitations and hemorrhages were seen in the

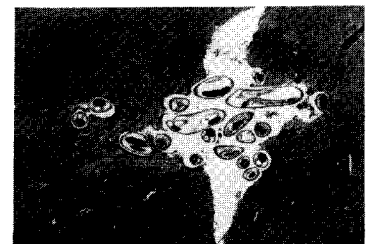


Fig 1—Photomicrograph of the medulla of a sable antelope (antelope 1), indicating numerous sections of immature *Parelaphostrongylus tenuis*. H&E stain; $\times 14$.

gray matter. Microscopically, immature forms of *P. tenuis* were seen in sections of the medulla from antelope 1 (Fig 1). Other microscopic lesions in the CNS were similar in both antelope and consisted of lymphocytes, plasma cells, and occasionally eosinophils around blood vessels and in de-

Supported by a Senior Research Project Assistantship from the Friends of the National Zoo.

The authors would like to thank Chris H. Gardiner for his assistance in identifying the parasites.

generated tracts in the spinal cords and brains. Tracts were sometimes hemorrhagic and contained swollen axons (Fig 2). Perivascularitis also was seen in the meninges.

Parelaphostrongylus tenuis is a protostrongylid nematode that normally parasitizes the CNS of white-tailed deer (*Odocoileus virginianus*). Terrestrial gastropods (snails and slugs) are obligate intermediate hosts for *P tenuis*, and mammals are infected with this parasite by accidentally ingesting *P tenuis*-infected gastropods on vegetation.⁴ In aberrant ruminant hosts, *P tenuis* often causes severe CNS damage. Neurologic disease resulting from *P tenuis* infections has been described in many species of domestic and nondomestic ruminants, including reindeer.¹⁻¹⁸

A large percentage of white-

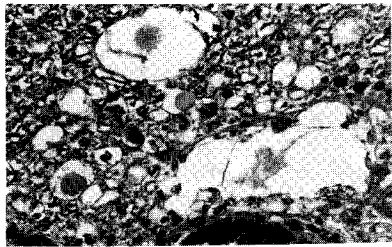


Fig 2—Photomicrograph of the lumbar spinal cord from a sable antelope (antelope 1), indicating axonal swelling and necrosis in the white matter compatible with infection by *P tenuis*. H&E stain; $\times 224$.

tailed deer from areas of Virginia near Front Royal (location of the CRC) are infected with *P tenuis*.^{19,20} When the NZP research and propagation program was initiated at the CRC in 1974, white-tailed deer often were seen in pastures mixing with exotic hoofstock. Although proper fencing eliminated this problem, white-tailed deer still browsed extensively along some of the fence lines. Gastropod intermediate hosts probably became infected with *P tenuis* at these fence lines, crossed into the pastures, and were ingested by the exotic hoofstock, resulting in *P tenuis* infections in the reindeer and sable antelope.

Clinical histories and pathologic findings in the animals of the present report closely resembled those described in other aberrant hosts.¹⁻¹⁸ Because only a few larvae

can inflict major damage in aberrant hosts,⁴ a definitive diagnosis of *P tenuis* infection by identifying the parasite (grossly or microscopically) within the CNS can be difficult. In the reindeer herd at CRC, *P tenuis* was identified in only 2 reindeer and diagnoses in the remaining 4 reindeer were based on clinicoepidemiologic and microscopic findings. Likewise, *P tenuis* was identified in sable antelope 1 and was strongly suspected in sable antelope 2 on the basis of microscopic findings.

A retrospective search of the pathologic records at NZP since 1975 indicated 2 other animals from CRC with clinical signs of illness and microscopic lesions (Fig 3) indicative of cerebrospinal nematodiasis, a 15-month-old bongo antelope (*Tragelaphus eurycerus*) in 1975 and a 19-month-

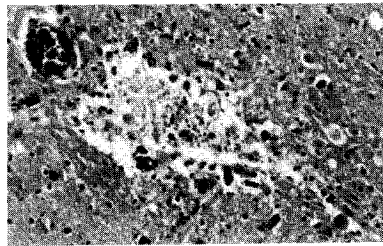


Fig 3—Photomicrograph of the medulla of a bongo antelope, indicating microcavitation, with gray matter necrosis and mild hemorrhage consistent with cerebrospinal nematodiasis. H&E stain; $\times 140$.

old scimitar-horned oryx (*oryx dammah*) in 1980. Only a tentative diagnosis of *P tenuis* infection could be made for the oryx and bongo antelope, because parasites were not identified in the CNS of either animal.

Clinical signs of illness in the reindeer, sable antelope, bongo antelope, and oryx, began in November, December, June, or July. Infective larvae of *P tenuis* can survive the winter in gastropods.²¹ Therefore, as long as weather conditions are favorable for gastropod activity, animals probably can become infected.

Treatment of reindeer 4, 5, and 6 with levamisole and treatment of sable antelope 2 with ivermectin were ineffective. The best method of controlling *P tenuis* infections is

to eliminate exposure of potentially susceptible animals to white-tailed deer and/or *P tenuis*-infected gastropods.⁴

The susceptibility of different aberrant hosts to *P tenuis* differs markedly with species, age, and the initial number of infecting parasites.^{2,10,12-16,22} Moose (*Alces alces*), reindeer, and caribou are exquisitely sensitive to this parasite.^{2-4,10} Because parelaphostrongylosis is a density-dependent disease²³ and because the number of white-tailed deer probably will increase, the incidence of *P tenuis* infections in domestic and non-domestic animals probably will increase as well. Zoos and wildlife parks especially should be cautious when introducing exotic hoofstock to areas with white-tailed deer.

1. Behrend DF, Witter JF. *Pneumostrongylus tenuis* in white-tailed deer in Maine. *J Wildl Manage* 1968;32:963-966.
2. Trainer DO. Caribou mortality due to the meningeal worm (*Parelaphostrongylus tenuis*). *J Wildl Dis* 1973;9:376-378.
3. Anderson RC. Neurologic disease in reindeer (*Rangifer tarandus*) introduced into Ontario. *Can J Zool* 1971;49:159-166.
4. Anderson RC, Prestwood AK. Lungworms. In: Davidon WR, Hayes FA, Nettles VF, et al, eds. *Diseases and parasites of white-tailed deer*. Tallahassee, Fla: Tall Timbers Research Station, 1981;266-317.
5. Alden C, Woodson F, Mohan R, et al. Cerebrospinal nematodiasis in sheep. *J Am Vet Med Assoc* 1975;166:784-786.
6. Jortner BS, Trout HF, Collins T, et al. Lesions of spinal cord parelaphostrongylosis in sheep. Sequential changes following intramedullary larval migration. *Vet Pathol* 1985;22:137-140.
7. Nielson SW, Aftosis J. Spinal nematodiasis in two sheep. *J Am Vet Med Assoc* 1964;144:155-158.
8. Guthery FS, Beasom SL, Jones B. Cerebrospinal nematodiasis caused by *Parelaphostrongylus tenuis* in angora goats in Texas. *J Wildl Dis* 1979;15:37-42.
9. Mayhew IG, deLaHunta A, Georgi JR, et al. Naturally occurring cerebrospinal parelaphostrongylosis. *Cornell Vet* 1976;66:56-72.
10. Smith HJ, Archibald RMG. Moose sickness, a neurological disease of moose

infected with the common cervine parasite, *Elaphostrongylus tenuis*. *Can Vet J* 1967; 8:173-177.

11. Stackhouse LL. Cerebral nematodiasis in two New Hampshire moose. *J Am Vet Med Assoc* 1977;171:987-988.

12. Carpenter JW, Jordan HE, Ward BC. Neurologic disease in wapiti naturally infected with meningeal worms. *J Wildl Dis* 1973;9:148-153.

13. Woolf A, Mason CA, Kradel D. Prevalence and effects of *Parelaphostrongylus tenuis* in a captive wapiti population. *J Wildl Dis* 1977;13:149-154.

14. Nettles VF, Prestwood AK, Nichols RG, et al. Meningeal worm-induced neurologic disease in black-tailed deer. *J Wildl*

Dis 1977;13:137-143.

15. Nettles VF, Prestwood AK, Smith RD. Cerebrospinal parelaphostrongylosis in fallow deer. *J Wildl Dis* 1977;13:440-444.

16. Kistner TP, Johnson GR, Rilling GA. Naturally occurring neurologic disease in a fallow deer infected with meningeal worms. *J Wildl Dis* 1977;13:55-58.

17. Brown TT, Jordan HE, Demorest CN. Cerebrospinal parelaphostrongylosis in llamas. *J Wildl Dis* 1978;14:441-444.

18. Tyler GV, Hibler CP, Prestwood AK. Experimental infection of mule deer with *Parelaphostrongylus tenuis*. *J Wildl Dis* 1980;16:533-540.

19. Prestwood AK, Smith JF. Distribution of meningeal worm (*Pneumostrongy-*

lus tenuis) in deer in the southeastern United States. *J Parasitol* 1969;55:720-725.

20. Dudak D. *The incidence and degree of infection of P tenuis in the white-tailed deer of western Virginia*. MS thesis. Virginia Polytechnic Institute, Blacksburg, Va, 1964.

21. Anderson RC. The ecological relationships of meningeal worm and native cervids in North America. *J Wildl Dis* 1972;8:304-310.

22. Davidson WR, Crum JM, Blue JL, et al. Parasites, diseases, and health status of sympatric populations of fallow deer and white-tailed deer in Kentucky. *J Wildl Dis* 1985;21:153-159.

23. Kerns PD. *Pneumostrongylus tenuis* in deer in Minnesota and implications for moose. *J Wildl Manage* 1967;31:299-303.