

A Comparative Study of
the Appendicular Musculature of
Penguins (Aves: Sphenisciformes)

DONALD O. SCHREIWEIS

SMITHSONIAN CONTRIBUTIONS TO ZOOLOGY • NUMBER 341

SERIES PUBLICATIONS OF THE SMITHSONIAN INSTITUTION

Emphasis upon publication as a means of "diffusing knowledge" was expressed by the first Secretary of the Smithsonian. In his formal plan for the Institution, Joseph Henry outlined a program that included the following statement: "It is proposed to publish a series of reports, giving an account of the new discoveries in science, and of the changes made from year to year in all branches of knowledge." This theme of basic research has been adhered to through the years by thousands of titles issued in series publications under the Smithsonian imprint, commencing with *Smithsonian Contributions to Knowledge* in 1848 and continuing with the following active series:

Smithsonian Contributions to Anthropology
Smithsonian Contributions to Astrophysics
Smithsonian Contributions to Botany
Smithsonian Contributions to the Earth Sciences
Smithsonian Contributions to the Marine Sciences
Smithsonian Contributions to Paleobiology
Smithsonian Contributions to Zoology
Smithsonian Studies in Air and Space
Smithsonian Studies in History and Technology

In these series, the Institution publishes small papers and full-scale monographs that report the research and collections of its various museums and bureaux or of professional colleagues in the world of science and scholarship. The publications are distributed by mailing lists to libraries, universities, and similar institutions throughout the world.

Papers or monographs submitted for series publication are received by the Smithsonian Institution Press, subject to its own review for format and style, only through departments of the various Smithsonian museums or bureaux, where the manuscripts are given substantive review. Press requirements for manuscript and art preparation are outlined on the inside back cover.

S. Dillon Ripley
Secretary
Smithsonian Institution

SMITHSONIAN CONTRIBUTIONS TO ZOOLOGY • NUMBER 341

A Comparative Study of
the Appendicular Musculature of
Penguins (Aves: Sphenisciformes)

Donald O. Schreiweis



SMITHSONIAN INSTITUTION PRESS

City of Washington

1982

ABSTRACT

Schreiweis, Donald O. A Comparative Study of the Appendicular Musculature of Penguins (Aves: Sphenisciformes). *Smithsonian Contributions to Zoology*, number 341, 46 pages, 19 figures, 1982.—The gross anatomy of all the appendicular muscles is compared in 14 species, representing the 6 living genera of Sphenisciformes. Particular emphasis is placed on the interrelationships indicated by variations in the taxa. *Eudyptes pachyrhynchus* is used as a type for which all the appendicular muscles are described and most are illustrated. The salient features of other taxa, as they differ from the condition found in *E. pachyrhynchus*, are given. Similarities and differences are compared quantitatively in respect to 47 items in the wing and 41 in the leg, using the method of Hudson et al. (1966:9–11). The results are given in the form of cumulative scores of differences and correlation coefficients.

The results of the comparison of the wing musculature support those for the leg. The cumulative scores and correlation coefficients give closely parallel results.

The Sphenisciformes constitute a rather uniform group of birds. The results of this study support the present classification of the order, in which 14 species are grouped into 6 genera. A tentative phylogeny of penguins is projected on the basis of variations in the wing and leg muscles.

OFFICIAL PUBLICATION DATE is handstamped in a limited number of initial copies and is recorded in the Institution's annual report, *Smithsonian Year*. SERIES COVER DESIGN: The coral *Montastrea cavernosa* (Linnaeus).

Library of Congress Cataloging in Publication Data

Schreiweis, Donald O.

A comparative study of the appendicular musculature of penguins (Aves: Sphenisciformes)

(Smithsonian contributions to zoology ; no. 341)

Bibliography: p.

Includes index.

Supt. of Doc. no.: SI 1.27:341

1. Penguins—Anatomy. 2. Wing—Muscles. 3. Leg—Muscles. 4. Anatomy, Comparative.

I. Title. II. Series.

QL1.S54 no. 341 [QL696.S473] 591s 81-607820 [598.4'41] AACR2

Contents

	<i>Page</i>
Introduction	1
Materials and Methods	1
Acknowledgments	2
Muscles of the Pectoral Appendage	2
Muscles of the Pelvic Appendage	14
Position of the Flexor Tendons Passing the Intertarsal Joint	21
Discussion and Conclusions	25
Appendix: Interesting Features of the Appendicular Muscles	29
Literature Cited	31
Abbreviations on Illustrations	33
Figures 1-19	34
Index	45

A Comparative Study of the Appendicular Musculature of Penguins (Aves: Sphenisciformes)

Donald O. Schreiweis

Introduction

Penguins are an ancient group of birds that had become flightless and highly specialized for underwater locomotion by the Eocene. Simpson (1975:35) considered penguins related to Procellariiformes, basing this relationship on the structure of the skull and mandible. In the oldest known fossil penguins, the structure of the mandible, the shape of the foramen magnum, and the arrangement of palatal bones are similar to the procellariiform type. Sibley and Ahlquist (1972) recently concluded that the egg-white protein patterns of penguins were more like those of the Procellariiformes than those of any other group, although they also resembled several other groups of aquatic birds. The descriptive myology of penguins presented in this paper may help to resolve the problem of phylogeny when comparable studies on other water birds become available.

Although the appendicular muscles have been studied in a few sphenisciform birds by various investigators, no one has made a concerted attempt to work out in detail the similarities and differences between the various genera and species. Such differences and similarities may serve as a basis for a study of functional morphology,

as well as a study of phylogenetic and systematic relationships among these taxa.

A detailed study of all appendicular muscles, using descriptive and numerical methods, was made on a series of 28 specimens, representing 6 genera and 14 species. The pectoral musculature is unlike that of any other group of birds. Most of the muscles in the wing are reduced to tendons, a condition not encountered in any other group, while the leg muscles deviate less from the general avian pattern. The more interesting features of the appendicular muscles of penguins are summarized in the appendix.

MATERIALS AND METHODS.—The classification followed is that of Falla and Mougín (1979). I dissected the following species: *Aptenodytes patagonicus* (2); *A. forsteri* (2); *Pygoscelis papua* (2); *P. adeliae* (3); *P. antarctica* (2); *Eudyptes pachyrhynchus* (2); *E. chrysochome* (2); *E. chrysolophus schlegeli* (1); *E. c. chrysolophus* (2); *Megadyptes antipodes* (1); *Eudyptula minor minor* (1); *E. m. albosignata* (1); *Spheniscus demersus* (2); *S. humboldti* (1); *S. magellanicus* (2); *S. mendiculus* (2).

Fresh specimens were initially injected in all parts with a 1:10 solution of formalin. After several weeks, specimens were opened and washed in tap water for 3 to 5 days to remove most of the formalin. Subsequently, all were stored in 65% ethyl alcohol.

To facilitate study of the musculature in most

Donald O. Schreiweis, Premedical Studies Program, Saint Louis University, Saint Louis, Missouri 63103.

specimens, the coracoid was separated from the clavicle proximally and from the sternum distally, and the femur was disarticulated at the acetabular joint. The extremities of the limb bones were exposed by partially dissecting the joint capsules without complete disarticulation. Each muscle was exposed from origin to insertion by cutting bellies or tendons of certain muscles at prescribed points.

Descriptions of the origin, belly, and insertion of each muscle are given for *Eudyptes pachyrhynchus*. The positional (anatomical) axes utilized are those related to the functional axes: for the wing, the extended position of underwater flight; for the leg, the normal standing position. The location of muscle attachments (e.g., "at about 0.63 tibiotarsus") were obtained by measuring the point of attachment from the proximal end of the bone holding the calipers parallel to the long axis of the bone. These measurements were then divided by the length of the bone.

Following each description, a comparison of the muscle is given for other species as these differ from *E. pachyrhynchus*. Included in the comparison are remarks concerning observations made by other workers. In many instances, observations made in this study clarify those of earlier workers.

Numerical comparisons were made using the method of Hudson et al. (1966:9-11). Tables of quantitative data are available from the author on request. Anatomical nomenclature follows that of the *Nomina Anatomica Avium* (Baumel et al., 1979).

ACKNOWLEDGMENTS.—I wish to express my appreciation and thanks to Dr. George E. Hudson under whose guidance and direction this study was completed. He made available many of the specimens and, through him, various specimens were loaned from other institutions. I also wish to thank Drs. Herbert L. Eastlick, C. M. McNeil, and Richard A. Parker of Washington State University, who critically read the manuscript and offered suggestions.

Specimens examined for this study are part of an extensive alcoholic collection at Washington State University, representing all living orders of

birds. Dr. Richard L. Zusi of the National Museum of Natural History, Smithsonian Institution, loaned 12 specimens. Dr. Dean Amadon of the American Museum of Natural History loaned one specimen each of *Eudyptes pachyrhynchus* and *Spheniscus humboldti*. Mr. Warwick M. Howe of the New Zealand Department of Internal Affairs supplied one specimen each of *Eudyptes pachyrhynchus*, *Megadyptes antipodes*, and *Eudyptula minor albosignata*. Mr. T. H. Barry of the South African Museum supplied a specimen of *Spheniscus demersus*.

This study was supported in part by a grant-in-aid (GB-6088) from the National Science Foundation.

Muscles of the Pectoral Appendage

M. LATISSIMUS DORSI

The latissimus dorsi consists of three distinct parts: latissimus dorsi cranialis, latissimus dorsi caudalis, and latissimus dorsi metapatagialis.

Latissimus dorsi cranialis

(LAT. DOR. CRAN.)

FIGURES 1, 2, 8

DESCRIPTION.—This large flat muscle (Figure 1) arises from the dorsal spines of about the last cervical and first five thoracic vertebrae. The origin is aponeurotic. Fleishy fibers of this muscle converge as they pass forward and outward, and terminate on a long, narrow tendon. The tendon is about one-fourth the length of the humerus. It passes through a fibrous pulley (Figure 8) much like a thread passes through the eye of a needle. This pulley, unique to the Spheniscidae, is attached to the axillary border of the scapula just behind the glenoid fossa. Insertion is on the posterior border of the humeral shaft, near the distal border of the pneumatic fossa.

COMPARISON.—An accessory slip from the cranial edge of the latissimus dorsi cranialis occurs in *Aptenodytes* and *Pygoscelis*. This accessory slip

inserts on the dorsal surface of the dorsal head of the triceps scapularis.

Latissimus dorsi caudalis

(LAT. DOR. CAUD.)

FIGURES 1, 2, 8

DESCRIPTION.—The latissimus dorsi caudalis (Figure 2) is distinct and separated by a wide interval from the latissimus dorsi cranialis. It arises by means of a delicate aponeurosis from the inferior edge of the ilium and the abdominal muscles immediately posterior to the last thoracic rib. Fleshy fibers on the band-like belly pass forward toward the shoulder and terminate on a long tendon which, after passing through the fibrous pulley mentioned above, is inserted on the posterior border of the humeral shaft adjacent to the insertion of the latissimus dorsi cranialis. The tendons of the latissimus dorsi cranialis and latissimus dorsi caudalis are partly fused.

COMPARISON.—The latissimus dorsi cranialis and latissimus dorsi caudalis are fused along their contiguous borders in *Aptenodytes* and *Pygoscelis*. All other genera have these two parts widely separated.

Latissimus dorsi metapatagialis

(LAT. DOR. MET.)

FIGURE 1

DESCRIPTION.—This muscle is quadrilateral in form. It arises by a narrow aponeurosis from the dorsal spines of thoracic vertebrae 4, 5, and 6. Insertion is along a broad line on the skin of the lateral line of the trunk. The belly of the latissimus dorsi metapatagialis is much wider than that of the latissimus dorsi caudalis and nearly as wide as the belly of the latissimus dorsi cranialis.

COMPARISON.—The latissimus dorsi metapatagialis exhibits a wide range of development in penguins. In *Aptenodytes* this muscle is very wide (1.01 scapula), reaching from the base of the neck to the lumbar region. It is narrowest in *Pygoscelis*

and *Eudyptula* and intermediate in *Eudyptes*, *Spheniscus*, and *Megadyptes*.

M. RHOMBOIDEUS SUPERFICIALIS

(RHOM. SUP.)

FIGURES 1, 2, 7

DESCRIPTION.—This wide, flat muscle (Figure 2) arises by means of a narrow aponeurosis from the dorsal spines of the last one or two cervical vertebrae and the first three or four thoracic vertebrae. The fibers pass transversely and slightly forwards; they are inserted on about the anterior half of the vertebral border of the scapula and the scapular process of the clavicle.

COMPARISON.—This muscle is very similar in all species. In *Eudyptes chrysocome*, Watson (1883: 76) found this muscle arising from the dorsal spines of the three anterior thoracic vertebrae and the last two cervical vertebrae. In this penguin, as well as in *Pygosceles taeniatus* (= *Pygoscelis papua*) and *Spheniscus minor* (= *Eudyptula minor*), he found the insertion to be confined to the cranial two-thirds of the vertebral border of the scapula. The insertion is not this extensive in any of the penguins studied. Gervais and Alix (1877:444) found the rhomboideus superficialis in *Eudyptes chrysolophus* attached to the dorsal spines of the last two cervical vertebrae, as well as to the dorsal spines of thoracic vertebrae 1 through 5. Such a wide origin was not present in any specimen of penguin studied.

M. RHOMBOIDEUS PROFUNDUS

(RHOM. PRO.)

FIGURES 2, 3, 7

DESCRIPTION.—The rhomboideus profundus (Figure 3) arises from the dorsal spines of about five or six thoracic vertebrae (thoracic vertebrae 2–7) by means of an aponeurosis. Fleshy fibers pass transversely and somewhat obliquely backwards to a fleshy insertion on about the caudal three-fourths of the vertebral border of the scapula

ula. *Rhomboideus superficialis* covers about the cranial two-thirds of the *rhomboideus profundus*.

M. SERRATUS PROFUNDUS

(SERR. PRO.)

FIGURE 7

DESCRIPTION.—The serratus profundus consists of four large, flat fleshy fascicles superimposed on one another. These fascicles arise from the last two cervical and first two thoracic ribs, dorsal to the uncinat processes. The fascicles pass posterodorsally and insert on about the caudal half of the costal surface of the scapula near the vertebral border.

COMPARISON.—The small cranial fascicle is usually absent in *Spheniscus* and *Megadyptes*. *Aptenodytes*, *Pygoscelis*, *Eudyptes*, and *Eudyptula* generally possess four fascicles. The caudal fascicle is sometimes absent. Watson (1883:79) reports four muscular plates in *Eudyptes chrysocome* and *P. papua*, which arise from the second, third, fourth, and fifth ribs. In *Aptenodytes patagonicus* and *Eudyptula minor* he found only three digitations, the first from the second rib, the second from the third and fourth ribs, and the third from the fifth rib. In no instance was the origin from the third, fourth, and fifth ribs in any penguin examined in this study. Schoepss (1829:97) has the serratus profundus arising from the transverse processes of the first and second dorsal vertebrae, as well as from the caudal border of the second rib. Gervais and Alix (1877:443) found five fleshy slips in *Eudyptes chrysolophus* of which the most cranial arises from the transverse process of the last cervical vertebra, the second from the first rib beneath the transverse process, and the other three from the following ribs dorsal to the uncinat processes. None of the specimens in this study had five slips, nor has any other worker reported this many muscular slips for the serratus profundus.

M. SERRATUS SUPERFICIALIS CRANIALIS

(SERR. SUP. CRAN.)

FIGURE 7

DESCRIPTION.—This muscle arises by means of two fleshy fascicles from the last cervical and first thoracic ribs. The fascicles fuse near the origin. The fibers pass obliquely anterior and dorsal. Insertion is mostly fleshy on the axillary border of the scapula. The insertion partially separates the origin of the *subscapularis caput laterale* from that of the *subscapularis caput mediale*.

COMPARISON.—My observations agree with those of Schoepss (1829:96), who found this muscle in *S. demersus* attached to the outer surfaces of the last cervical rib and to the lower part of the first true rib. Gervais and Alix (1877:443) describe this muscle as arising from the third and fourth ribs in *E. chrysolophus*. Watson (1883:78) gives the origin as the second, third, and fourth vertebral ribs. In one specimen of *Pygoscelis antarctica*, I found the origin to be from the last cervical and first two thoracic ribs.

M. SERRATUS SUPERFICIALIS CAUDALIS

(SERR. SUP. CAUD.)

FIGURES 3, 7

DESCRIPTION.—This muscle (Figure 7) has three fascicles arising from thoracic ribs 2, 3, and 4, a little below the uncinat processes. The fibers pass nearly at a right angle to the long axis of the scapula. Insertion is mostly fleshy on the ventrolateral border of about the posterior fifth of the scapula.

COMPARISON.—The origin of this muscle is generally from the second, third, and fourth thoracic ribs. Variations to this pattern occur. One specimen of *A. patagonicus* has only two fascicles, which arise from the third and fourth thoracic ribs. This pattern is also present in one specimen of *Pygoscelis adeliae*. The posterior fascicle in one specimen of *P. antarctica* arises from both the fourth and fifth thoracic ribs. *Megadyptes* has only two fascicles,

which arise from the second and third thoracic ribs. Watson (1883:78) found this muscle arising by two digitations from the fourth and fifth ribs in *P. papua*. Schoepss (1829:94) reports this muscle arising from four ribs in penguins. Watson (1883:78) never found the serratus superficialis caudalis arising from more than three ribs, and I found it arising from three ribs in all except one specimen in which the posterior slip arose from both the fourth and fifth ribs.

M. SCAPULOHUMERALIS CAUDALIS

(SCAP. HUM. CAUD.)

FIGURES 1-3, 5-7

DESCRIPTION.—The scapulohumeralis caudalis (Figure 3) has an extensive origin from about the posterior two-thirds of the dorsal and lateral surfaces of the scapula. The fibers pass obliquely forward and end on a strong tendon, which is inserted on the posterior border of the humerus (0.33 humerus).

COMPARISON.—The scapulohumeralis caudalis is a very uniform muscle in the Spheniscidae. The cranial end of the origin shows only slight variation between genera of penguins, ranging from 0.33 scapula in *Aptenodytes* to 0.44 scapula in *Eudyptula*.

M. PECTORALIS

This muscle consists of three slips: pectoralis thoracica, pectoralis proptagialis (which is not present in penguins), and pectoralis pars subcutanea abdominalis.

Pectoralis thoracica

(PECT. THO.)

FIGURES 2-7

DESCRIPTION.—The pectoralis thoracica (Figure 4) is a very powerful muscle which arises from the lateral edge of the sternum posterior to the coracobrachialis caudalis, the trabecula lateralis

of the sternum, the interosseus membrane between this process and the corpus sterni, a line along the entire length of the sternal keel ventral to the origin of the supracoracoideus, the lateral surface of the clavicle below the shoulder joint, the cranioventral edge of the membrana sternocoraco-clavicularis, and the aponeurosis covering the supracoracoideus. The belly is composed of three distinct parts. Fibers of the clavicular part pass caudolaterally. Those of the caudolateral part pass craniolaterally, while those of the large middle part pass obliquely at increasing angles from the sternum. The clavicular fibers end on a specialized part of the tendon of insertion, which ends on about the proximal fifth of the cranial border of the humeral shaft, joining the tendon of the proptagialis near the proximal end of the humerus. The remaining fibers insert by means of a wide, curving tendon on the proximal third of the cranioventral edge of the humerus.

COMPARISON.—The pectoralis thoracica shows no significant variations in the Spheniscidae. Reid (1835:140) described the muscle in *Aptenodytes patagonicus* as arising from “the cartilages of the ribs, and from the anterior part of the coracoid bone” in addition to the origin given above. Such is not the case in any of the penguins examined in this study or in the study by Watson (1883:81).

Pectoralis pars subcutanea abdominalis

(PECT. SUB. ABD.)

FIGURE 4

DESCRIPTION.—Pars subcutanea abdominalis is a wide, flat, ribbon-like muscle that arises from the skin along the flank. The caudal end of the origin is opposite the region of the acetabulum. The muscle passes cranially and somewhat dorsally to insert on the dorsal border of the pectoralis thoracica caudal to the insertion of the latter on the humerus.

COMPARISON.—The maximum width of this muscle relative to the humeral length shows some variation between genera of penguins. It is nar-

rowest in *Aptenodytes* and *Eudyptes*, and intermediate in *Megadyptes*, *Spheniscus*, and *Pygoscelis*. Watson (1883:81) describes the pectoralis pars subcutanea abdominalis as inserting on the anterior margin of the humerus. This is not the case in any species of penguin examined in this study.

M. SUPRACORACOIDEUS

(SUP. COR.)

FIGURES 1-3, 5

DESCRIPTION.—The supracoracoideus (Figure 5) arises from the entire surface of the sternum not occupied by the pectoralis thoracica, from the proximal part of the trabecula lateralis of the sternum, from the keel of the sternum, and from the basal end of the coracoid. It also has a considerable attachment to the membrana sterno-coraco-clavicularis. From these origins the fibers converge to a stout, flattened tendon which, after passing through the canalis triosseus, inserts (Figures 1-3) on an oblique ridge on the proximodorsal part of the humerus between the insertions of the deltoideus major and deltoideus minor. The supracoracoideus is very well developed in comparison to the pectoralis thoracica, a fact noted by every anatomist who has worked on any member of the group.

COMPARISON.—The small, separate anterior part of the supracoracoideus described by Schoepss (1829:124), Gervais and Alix (1877:447), and Watson (1883:82) is the long head of the deltoideus minor and will be described later with that muscle. The supracoracoideus is a very strong, bipennate muscle in penguins and is very similar in all.

M. CORACOBRACHIALIS CRANIALIS

(COR. BRA. CRAN.)

FIGURES 5, 6

DESCRIPTION.—This muscle (Figure 5) is small and embedded in a very dense investment of fascia. It arises from the cranioventral surface of

the distal apex of the coracoid. The belly is very weak. Insertion is tendinous on the extreme proximal end of the cranioventral humeral shaft and is covered by the pectoralis thoracica.

COMPARISON.—The coracobrachialis cranialis is present in all species of penguins studied and shows the same relative degree of development. It is not described in the major treatises on penguin myology.

M. CORACOBRACHIALIS CAUDALIS

(COR. BRA. CAUD.)

FIGURES 3, 5-7

DESCRIPTION.—The coracobrachialis caudalis has a fleshy origin from a short, narrow line along the cranial third of the cranioventral edge of the corpus sterni and from about the proximal third of the lateral surface of the coracoid (Figure 6). The belly is large and tapered to a point at each end. Insertion is by a strong tendon on the dorsal surface of the internal tuberosity of the humerus (Figure 3).

COMPARISON.—This muscle shows remarkable uniformity in penguins.

M. STERNOCORACOIDEUS

(STER. COR.)

FIGURE 7

DESCRIPTION.—This muscle has a fleshy origin from the cranioventral sternal spine and the cranial border of the sternum. The sternocoracoideus is a strong, triangular muscle. Insertion is fleshy on a large triangular area of the proximal end of the dorsal surface of the coracoid.

COMPARISON.—A very uniform muscle among penguins but of varying length. It is longest in *Pygoscelis* and shortest in *Spheniscus*. The remaining genera are of intermediate length. This muscle is not described by Watson (1883).

M. SUBCORACOIDEUS

(SUBCOR.)

FIGURE 7

DESCRIPTION.—The subcoracoideus is a large, powerful muscle arising fleshy from the dorsal surface of the caudal end of the spina externa of the sternum and partly tendinous from the adjacent cranial edge of the corpus sterni. As it passes toward the shoulder, it is further attached to the dorsomedial surface of the coracoid and adjacent membrana sterno-coraco-clavicularis. Near the shoulder joint the subcoracoideus fuses with the subscapularis. Insertion is by a common, short but strong, tendon at the proximal end of the bicipital crest of the humerus. The tendon is strongly attached to the adjacent joint capsule.

COMPARISON.—The subcoracoideus is very similar in all penguins.

M. SUBSCAPULARIS

(SUBSCP.)

FIGURES 2, 3, 5-7

DESCRIPTION.—The subscapularis is divided into two heads, which are partially separated by the serratus superficialis cranialis (Figure 7). The subscapularis caput mediale (SUBSCP. (CAP. MED.)) arises fleshy from about the proximal third of the costal surface of the scapula, from a very small area on the medial surface of the scapular process of the clavicle, and a small cranial part from the medial surface of the coracoid distal to the subcoracoideus. Hudson et al. (1969:464) refer to that part of the subscapularis arising from the coracoid, clavicle, and adjacent scapula as a cranial head of the subcoracoideus. Only the slightest indication of a division of this muscle mass exists in penguins. Because of the very intimate association with the caput mediale, I have chosen to consider it a part of the latter. The fibers of the caput mediale almost at once unite with those of the subcoracoideus and subscapularis caput laterale (SUBSCP. (CAP. LAT.)). The caput laterale

(Figure 3) arises fleshy from about the cranial two-fifths of the lateral surface of the scapula. Insertion of the subscapularis is by means of a tendon common to it and the subcoracoideus. This tendon inserts on the proximal end of the bicipital crest of the humerus. The caput mediale is smaller than the caput laterale.

COMPARISON.—The caput mediale reaches farthest distally on the scapula in *Megadyptes* and is shortest in *Pygoscelis*; the remaining genera are intermediate. Gervais and Alix (1877:445) state that the caput laterale (*petit rond*) inserts above the caput mediale (*sous-scapulaire*). Every specimen in this study and those studied by Watson (1883:85) have the caput laterale and caput mediale inserted by means of a common tendon.

M. PROPATAGIALIS

(PROPAT.)

FIGURES 1-4

DESCRIPTION.—The propatagialis (Figure 1) arises fleshy from the dorsal apex of the coracoid, the craniolateral edge of the clavicle, and the intervening coracoclavicular ligament. Its belly is stout and partly separable into two layers. Insertion is by means of a very heavy tendon along nearly the entire length of the cranial edge of the humerus. The tendon continues along the cranial border of the ventral surface of the radius and contributes to the formation of the alar aponeurosis. Beyond the wrist, the tendon becomes progressively less distinct.

COMPARISON.—The propatagialis exhibits little variation among penguins. No indication of a division into superficial and deep layers is present in *Eudyptula*, *P. antarctica*, *P. adeliae*, and one specimen of *E. pachyrhynchus*. Watson (1883:88) describes a deep and superficial part to this muscle. The superficial part (*deltoideus posterior* of Gervais and Alix) corresponds to the deltoideus major in Watson's opinion. Schoepss (1829:82, 86) figures a cranial and a caudal belly for the tensor patagii longus of penguins. The caudal belly of his description most definitely corresponds to the del-

toideus major. Meckel (1828:337-343) also describes two bellies for the tensor longus, one of which can with difficulty be separated from the pectoralis major. These obviously correspond to the two partial layers described above for *E. pachyrhynchus*. Watson describes an accessory slip to the tensor patagii. This slip corresponds to the long head of the deltoideus minor.

M. DELTOIDEUS MAJOR

(DELT. MAJ.)

FIGURES 1, 2

DESCRIPTION.—The deltoideus major (Figure 2) is a very thin, triangular muscle. It arises fleshy from the distal apex of the clavicle, the dorsal surface of the coracoscapular ligament, and the acromial process of the scapula. The fibers converge distally onto a short tendon, which inserts on the caudodorsal edge of the humerus very close to the insertion of the latissimus dorsi.

COMPARISON.—The belly is triangular in most genera. It is strap-like in *Spheniscus*. The belly is shortest in *Aptenodytes* and *Megadyptes*, and longest in *Eudyptes*; intermediate in the remaining genera. The tendon is shortest in *Eudyptes* and *Spheniscus* and is longest in *Megadyptes* and *Pygoscelis*. *Aptenodytes* and *Eudyptula* are intermediate. Descriptions by other workers are very confused.

M. DELTOIDEUS MINOR

(DELT. MIN.)

FIGURES 2, 3, 6

DESCRIPTION.—This muscle has two distinct heads in the Spheniscidae. The short dorsal head (Figure 3) arises fleshy from the acromial process of the scapula and from the coraco-scapular ligament. The short head fuses with the long head almost from the origin of the former. The long ventral head (Figure 6) arises from the caudal third of the membrana sterno-coraco-calvicularis, from the cranial edge of the manubrial spine, and from a long, narrow line along most of the ven-

tromedial edge of the coracoid. The fibers converge on a short, strong tendon, which inserts in common with the short head on the external tuberosity of the humerus deep to the propatagialis.

COMPARISON.—In most penguins the origin also arises from the clavicular process of the coracoid inside the canalis triosseum. *Eudyptula* and most *Eudyptes* lack this part of the origin.

M. TRICEPS BRACHII

DESCRIPTION.—The triceps brachii consists of two distinct parts, a triceps scapularis from the scapula and clavicle and a triceps humeralis from the caudal surface of the humerus.

Triceps scapularis

(TRI. SCAP.)

FIGURES 1-3

The triceps scapularis is very large and composed of a dorsal and ventral head. The much larger dorsal head (Figure 1) arises fleshy from the acromial process of the scapula, the adjacent joint capsule, and a long, narrow line on the medial and dorsal surfaces of the clavicle dorsal to the origin of the propatagialis. This head is partially divided into a superficial and deep layer. At about 0.35 humerus the dorsal head ends on a strong tendon common to it and the ventral head. The smaller ventral head (Figure 2) arises fleshy from the axillary border of the scapula immediately behind the glenoid fossa. This belly is firmly attached to the fibrous loop through which the tendons of the latissimus dorsi caudalis pass. The ventral head ends on the common tendon at 0.37 humerus. The triceps scapularis tendon almost immediately fuses with the tendon of the ventral head of the triceps humeralis. The resulting tendon is attached to the caudal surface of the dorsal head of the triceps humeralis and can be traced to the elbow. At the elbow two very large sesamoids develop in relation to the two parts of the triceps tendon. Distal to these sesamoids

moids two tendinous slips are evident, one from each of the sesamoids. These short, strong tendons insert on the dorsoposterior edge of the ulna proximal to 0.17 ulna.

Triceps humeralis

(TRI. HUM.)

FIGURES 1-6

The triceps humeralis is less massive than the triceps scapularis but is also composed of two heads. The shorter ventral head (Figure 3) arises fleshy from the region of the pneumatic foramen of the humerus. Its fibers end on a tendon at about 0.46 humerus. The very long, slender dorsal head (Figure 1) arises fleshy from the caudal border of the humerus distal to about 0.39 humerus. Its proximal end lies dorsal to the distal end of the ventral head. Fibers of the dorsal head pass caudodistally, ending on the common tendon of the triceps scapularis and triceps humeralis. A few of the distal fibers end on the inner sesamoid of the elbow.

COMPARISON.—In all specimens studied there was some exchange of fleshy fibers between the two heads of the triceps humeralis. Watson (1883:91) describes such interchange of fibers for *Eudyptes chrysolophus*. The dorsal head of the triceps humeralis is longest in *Aptenodytes*, *Eudyptula*, and *Spheniscus*; shortest in *Pygoscelis*; intermediate in *Eudyptes* and *Megadyptes*.

M. BICEPS BRACHII

This muscle is generally absent in the Spheniscidae. A vestigial biceps brachii was present in a single specimen of *Megadyptes antipodes*. It arose by a short delicate tendon from the dorsal surface of the humerus deep to the pectoralis thoracica. A very small, fleshy belly was present near the distal end of the humerus. Insertion was by a delicate tendon on the deep surface of the propatagialis tendon over the brachialis. Filhol (1885) does not describe this muscle for any of the penguins he studied, including *M. antipodes*.

M. BRACHIALIS

(BRACH.)

FIGURES 1-6

DESCRIPTION.—The brachialis (Figure 3) arises fleshy from the cranioventral border of the humerus distal to about 0.59 humerus. The belly is quadrilateral and well developed for this part of the wing. Insertion is mainly fleshy on the proximal border of the radius, extending onto the ventral surface and slightly onto the dorsal surface.

COMPARISON.—The brachialis is very well developed in all penguins. There has been a fair amount of controversy over the correct designation for this muscle. Gervais and Alix (1877:450) consider this muscle not homologous with the brachialis anticus (M. brachialis inferior of Gadow and Selenka, 1891) of other birds because of its insertion on the radius. Nor do they consider it representative of a biceps, since it does not insert on the interosseus border of the radius.

Schoepss (1829:141) describes a muscle in *Spheniscus demersus* that arises from the lower part of the cranial border of the humerus and inserts on the radial border of the ulna near the ligamentous capsule of the elbow joint. Watson (1883:92) failed to recognize the presence of this muscle in any species of penguin that he dissected. Gervais and Alix (1877:450) omit all reference to it in their description of *E. chrysolophus*. Such a muscle slip arising from the brachialis is sometimes present in penguins. Of the 26 specimens examined in this study, only 8 specimens of seven species had such a muscle slip. This slip occurred in one specimen each of *Aptenodytes forsteri* (1 S), *A. patagonicus* (1 S), *Eudyptes chrysolophus schlegeli* (2 W), *E. c. chrysolophus* (1 S), *E. pachyrhynchus* (1 S), *Spheniscus demersus* (2 W), *S. mendiculus* (1 W), and *S. magellanicus* (2 W). This small slip of muscle is a definite part of the brachialis. It separates from the caudal border of the brachialis and inserts by means of a short tendon on the radial border of the ulna near the proximal end. The presence of this slip in some specimens reinforces

the idea that the entire muscle is indeed the brachialis of other birds. It has shifted its point of insertion, a result of the extreme dorsoventral compression of the sphenisciform wing.

M. FLEXOR CARPI ULNARIS

(F. CAR. UL.)

FIGURES 4-6

DESCRIPTION.—The flexor carpi ulnaris (Figure 4) is entirely tendinous. It arises from the distal apex of the epicondylus medialis humeri, immediately distal to the origin of the flexor digitorum superficialis. The tendon passes along the caudal border of the ventral surface of the ulna. Insertion is near the middle of the ventral surface of the os ulnare.

COMPARISON.—Similar in all penguins studied. Watson (1883:93) also found this muscle to be similar in all penguins he studied.

M. FLEXOR DIGITORUM SUPERFICIALIS

(F. DIG. SUP.)

FIGURES 4-6

DESCRIPTION.—This muscle (Figure 4) is entirely replaced by tendon. It arises from the distal edge of the epicondylus medialis humeri immediately proximal to the flexor carpi ulnaris. The tendon passes along the ventral surface of the ulna adjacent to the flexor carpi ulnaris. Just before reaching the wrist, it divides into two branches. One of these is very short and inserts on the cranioventral edge of the os ulnare, while the other passes obliquely across the carpometacarpus to the anterior border of the wing and fuses with the tendon of the flexor digitorum profundus. Insertion is on the cranioventral edge of phalanx 2, digiti majoris.

COMPARISON.—The flexor digitorum superficialis is similar in all penguins studied. A small fleshy belly is present in only one of the specimens examined (*A. patagonicus*).

M. FLEXOR DIGITORUM PROFUNDUS

(F. DIG. PROF.)

FIGURES 4-6

DESCRIPTION.—The flexor digitorum profundus (Figure 4) is represented by a single tendon, which arises from the interosseous borders of the radius and ulna. The tendon is indistinct and fused with the interosseous membrane proximal to about 0.75 radius. After passing the wrist, the tendon continues along the ventral surface of os metacarpale majus, the proximal phalanx of digiti majoris, and finally inserts along the cranioventral edge of the proximal and distal phalanges of digiti majoris. The tendon fuses with the flexor digitorum superficialis near the base of the proximal phalanx of digiti majoris.

COMPARISON.—The flexor digitorum profundus is similar in all penguins studied. A very small belly is present in one wing of *Eudyptula minor*, but absent in the other wing of this specimen. None of the other specimens have fleshy fibers associated with the flexor digitorum profundus.

M. ULNIMETACARPALIS VENTRALIS

DESCRIPTION.—When present, the ulnimetacarpalis ventralis is usually entirely tendinous and arises from the ventral surface of the ulna near the cranial border. Insertion is on the tendon of the propatagialis near the wrist.

COMPARISON.—The ulnimetacarpalis ventralis is absent in all specimens of *Aptenodytes*, *Eudyptula*, and *Spheniscus*. In *Eudyptes chrysolophus schlegeli* a very small belly is present. The ulnimetacarpalis ventralis is present but entirely tendinous in one specimen of *E. pachyrhynchus* and one specimen of *E. c. chrysolophus*. One specimen of *Pygoscelis papua* has an ulnimetacarpalis ventralis that arises like that in *E. pachyrhynchus*. The insertion in *P. papua* is on the tendon of the flexor digitorum profundus at about 0.33 carpometacarpus. In *Megadyptes* the origin is from the adjacent edges of the radius and ulna near the distal end of these bones. It is entirely tendinous and inserts on the caudoven-

tral edge of the carpometacarpus near the proximal end of the fused pollex. Schoepss (1829:152) describes this muscle in *S. demersus* as having an origin from the inner border of the ulna and inserting into the inner side of the base of the first radial phalanx. Neither Watson (1883:97) nor I found this muscle in specimens of *S. demersus*. Gervais and Alix (1877) and Filhol (1885) gave no reference to such a muscle in penguins.

M. EXTENSOR METACARPI RADIALIS

(E. META. RAD.)

FIGURES 1-3

DESCRIPTION.—This is a small, weak, proximally situated muscle (Figure 1) arising tendinous from the cranial border of the dorsal surface of the humerus immediately proximal to the brachialis. The origin is strongly attached to the tendon of the propatagialis. The muscular fibers are short and end on a strong tendon which, after passing through a shallow groove near the dorsocranial border of the radius, inserts on the proximal end of the carpometacarpus near the cranial border. Insertion is in common with the extensor longus alulae.

COMPARISON.—The muscle is longest in *Eudyptula* (0.21 radius) and shortest in *Pygoscelis* (0.02 radius). In the remaining genera it is of intermediate length. Schoepss (1829:145) reports that this muscle arises from the humerus by two distinct heads in penguins. I failed to find this arrangement in any species of penguin, nor has any other worker reported two heads of origin in penguins.

Watson (1883:94) reports a separate insertion for the extensor metacarpi radialis longus (extensor metacarpi radialis) and extensor metacarpi radialis brevis in all the specimens that he dissected. Such an arrangement was not present in any specimen examined in this study. Gervais and Alix (1877:499) and Filhol (1885:176) are in agreement with my findings.

M. SUPINATOR

(SUPIN.)

FIGURES 1-3

DESCRIPTION.—This very weak, triangular muscle (Figure 1) arises by means of a short, delicate tendon from the heavy tendon of the extensor digitorum communis, which arises from the dorsal surface of the distal end of the humeral shaft. The muscular fibers pass distally and cranially to insert on the dorsal surface of the radius proximal to 0.29 radius.

COMPARISON.—The supinator is longest in *Spheniscus*, intermediate in *Pygoscelis* and *Eudyptula*, and shortest in *Megadyptes*, *Aptenodytes* and *Eudyptes*. This muscle is absent in one specimen of *P. antarctica*. It lacks muscular fibers in two specimens of *P. adeliae*.

M. EXTENSOR DIGITORUM COMMUNIS

(E. DIG. COM.)

FIGURES 1-3

DESCRIPTION.—This muscle (Figure 1) is represented by a strong tendinous band, which arises from the cranial edge of a wide tendinous sheet from the epicondylus lateralis humeri. There is no branch to the region of the fused pollex. Insertion is on the craniodorsal surface of os metacarpale major near the distal end, and on both phalanges of digiti majoris nearly to the tip of the wing. The tendon is completely fused with the tendon of the extensor longus digiti majoris near the middle of the major metacarpal.

COMPARISON.—A very small, fleshy belly is present in only two of the specimens examined, one of *Eudyptes pachyrhynchus* and one of *Spheniscus humboldti*. In one specimen of *P. papua* the tendon sends a small branch to the region of the fused pollex. This branch ends in the fascia over the pollex.

M. EXTENSOR METACARPI ULNARIS

(E. META. UL.)

FIGURES 1-3

DESCRIPTION.—The extensor metacarpi ulnaris (Figure 1) is entirely tendinous. It arises from the caudal edge of the tendinous sheet in common with the extensor digitorum communis. The tendon passes along the craniodorsal edge of the ulna and, after crossing the wrist, inserts on the caudal edge of the major metacarpal at about 0.40 carpometacarpus.

COMPARISON.—In most specimens the insertion is confined to the major metacarpal. Watson (1883:96) found this muscle in *Eudyptes crestatus* to insert only on the cranial border of os metacarpale minus. None of the specimens examined in this study have this arrangement. In all other specimens, he found the muscle inserting on the caudal border of the major metacarpal. Schoepss (1829:150) reports the insertion on both the major and minor metacarpals. Such an arrangement is occasionally present. I have found an insertion on both metacarpals in *Megadyptes antipodes* (1S), *Aptenodytes forsteri* (1S), *Eudyptula minor* (1S), *Eudyptes c. chrysolophus* (1S), and *Spheniscus mendiculus* (1S).

M. ECTEPICONDYLO-ULNARIS

(ECT.-ULN.)

FIGURE 3

DESCRIPTION.—The ectepicondylo-ulnaris is entirely tendinous. It arises from the middle of the tendinous sheet in common with the extensor digitorum communis and extensor metacarpi ulnaris. The tendinous sheet arises from the dorsal surface of the distal end of the humerus. Insertion is on the cranial border of about the proximal half of the ulnar shaft.

COMPARISON.—This muscle is shortest in *Eudyptes* and longest in *Eudyptula* and *Pygoscelis*. There is a small belly in *A. patagonicus* (1S), *Eudyptes chrysolophus schlegeli* (2W), *P. papua* (1S),

Eudyptula m. albosignata (1W), *S. demersus* (1W), and *S. humboldti* (1W); tendinous in all others.

The ectepicondylo-ulnaris (anconaeus) muscle described by Reid (1835:142) and "l'anconé externe" described by Gervais and Alix (1877:449) is either a ligament of the elbow joint or a part of the triceps tendon. The structure described by these authors cannot be homologized with any muscle in other birds. They completely omit reference to the tendon that I call "ectepicondylo-ulnaris." Watson (1883:92) did not find this muscle in any species of penguin he dissected, and Filhol (1885:175) reports the muscle to be absent in *Eudyptes crestatus*.

M. EXTENSOR LONGUS ALULAE

(E. LON. AL.)

FIGURES 1-3

DESCRIPTION.—The extensor longus alulae (Figure 2) arises by means of two heads; a small radial head from the caudodorsal surface of the radius beginning at about 0.43 radius and a larger ulnar head from about the proximal half of the cranial border of the ulnar shaft. The two bellies fuse about midway the forearm, and the common belly extends obliquely across the radius ending on a tendon at about 0.80 radius. After crossing the wrist, this tendon fuses with that of the extensor metacarpi radialis. Insertion is on the proximal end of the carpometacarpus near the cranial border of this bone.

COMPARISON.—The radial head is absent in both wings of *E. m. minor* and one wing of *E. m. albosignata*. Whether the absence of the radial head in *Eudyptula* is significant cannot be determined on the basis of only two specimens. All other species are similar to *Eudyptes*.

M. EXTENSOR LONGUS DIGITI MAJORIS

(E. LON. DIG. MAJ.)

FIGURES 2, 3

DESCRIPTION.—This muscle (Figure 2) is re-

placed by a tendon that arises from the distal half of the caudal surface of the radius between about 0.53 radius and 0.82 radius. The tendon then passes between the distal ends of the radius and ulna, crosses the wrist, and fuses with the tendon of the extensor digitorum communis about midway of the major metacarpal. There is no trace of a distal head.

COMPARISON.—The extensor longus digiti majoris is absent in one specimen of *A. forsteri* and one of *A. patagonicus*. It is small but partly fleshy in one specimen of *A. forsteri* and very small and tendinous in the other specimen of *A. patagonicus*. In one specimen of *Eudyptes pachyrhynchus* there are a few fleshy fibers associated with this muscle. It is entirely tendinous in all other penguins studied.

Watson (1883:97) described the extensor longus digiti majoris as being a very slender muscle arising from the contiguous borders of the radius and ulna and inserting into the outer side of the second or terminal radial phalanx. Such an arrangement does not occur in any of the specimens examined in the current study. There is a connection to the posterior edge of the major metacarpal, as well as to the extensor digitorum communis in *Eudyptula*. Gervais and Alix (1877:451) describe the extensor longus digiti majoris in *Eudyptes chrysocome* as a very small fleshy bundle that arises from the distal half of the interosseus space between the radius and ulna.

My findings are in agreement with those of Meckel and Schoepss. According to Meckel (1828:344), this muscle is represented entirely by tendon. Schoepss (1829:159) found that its origin was confined to the distal end of the radius.

M. ULNIMETACARPALIS DORSALIS

(UL. META. DOR.)

FIGURES 1-3

DESCRIPTION.—The ulnometacarpalis dorsalis (Figure 1) arises by means of a strong, flat tendon near the distal end of the caudodorsal edge of the ulna. The belly is single and one of the strongest

distal to the elbow. Insertion is fleshy along an extensive area of the caudal edge of the minor metacarpal. The belly ends at about 0.83 carpometacarpus.

COMPARISON.—Watson (1883:96) indicated the insertion as confined to the proximal half of the ulnar metacarpal bone in *Eudyptes chrysocome* and *Spheniscus demersus*. The shortest belly is in *Megadyptes* (0.76 carpometacarpus). The ulnometacarpalis dorsalis is a very uniformly developed muscle in the Spheniscidae.

M. ABDUCTOR DIGITI MAJORIS

(ABD. DIG. MAJ.)

FIGURES 4, 5

DESCRIPTION.—This very weak muscle (Figure 5) arises from the ventral surface of the major metacarpal near the cranial border of this bone and from the adjacent fused pollex. The belly is flat and bipennate. Its fibers converge distally on a short, flat tendon. Insertion is on the base of the proximal phalanx of the major digit.

COMPARISON.—The abductor digiti majoris is longest in *Eudyptula* (0.18–0.54 carpometacarpus) and shortest in *Aptenodytes* (0.32–0.78 carpometacarpus). The muscle is present and fleshy in all specimens studied. However, Watson (1883:100) reported that the muscle is represented by a tendon in all penguins he studied, except in *Aptenodytes longirostris* (= *A. patagonicus*), *P. papua*, and *Eudyptes chrysocome*, in which there was a “distinct but weak muscular belly.” According to Meckel (1828:350) and Schoepss (1829:170) this muscle is entirely absent in Sphenisciformes. Gervais and Alix (1877:452) found it represented by a tendon in *E. chrysocome*.

M. INTEROSSEUS DORSALIS

(INT. DOR.)

FIGURES 1, 2

DESCRIPTION.—The interosseus dorsalis (Figure 1) is entirely tendinous. It arises from the caudal

border of the major metacarpal and the cranial border of the minor metacarpal. The tendinous sheet that replaces the belly gives rise to a small tendon near the distal end of the carpometacarpus. Insertion is on the middle of the dorsal surface of the base of the distal phalanx of the major digit.

COMPARISON.—A small, very weak belly is present in one specimen of *A. patagonicus* and one of *S. mendiculus*. Watson (1883:101) reports the muscle entirely absent in one specimen of *A. patagonicus* and *Eudyptula minor*. In *P. papua* he found it represented by a tendon without a muscular belly. According to Schoepss (1829:172) this muscle is absent in *S. demersus*. Gervais and Alix (1877:453) found "the muscle, seldom fleshy."

M. INTEROSSEUS VENTRALIS

(INT. VEN.)

FIGURES 1, 2, 4, 5

DESCRIPTION.—The interosseus ventralis (Figure 5) is a weak, fleshy, bipennate muscle that arises from the caudal border of the major metacarpal and the cranial border of the minor metacarpal on the ventral side of the carpometacarpus. The muscular fibers end on a slender tendon that passes to the dorsal surface and then inserts along the entire caudal border of the distal phalanx of the major digit.

COMPARISON.—The belly is longest in *Aptenodytes*, *Megadyptes*, and *Eudyptula*; shortest in *Pygoscelis*.

M. FLEXOR DIGITI MINORIS

(F. DIG. MIN.)

FIGURES 4, 5

DESCRIPTION.—This muscle (Figure 5) has a fleshy origin from the ventral surface proximally and the caudal surface distally of the minor metacarpal. The tendon is mainly on the ventral surface of the belly. Insertion is mostly tendinous on

the proximally projecting tubercle on the caudal edge of the minor digit.

COMPARISON.—The belly is longest in *Aptenodytes* and *Eudyptes*; shortest in *Megadyptes*. The location of the distal end of the muscle is very uniform, at 0.92 and 0.94 carpometacarpus.

The following muscles are absent in the sphenisciform wing: *M. serratus superficialis metapagialis*, *M. scapulohumeralis cranialis*, *M. expansor secundariorum*, *M. pronator superficialis*, *M. pronator profundus*, *M. entepicondylo-ulnaris*, *M. abductor alulae*, *M. flexor alulae*, *M. adductor alulae*, and *M. extensor brevis alulae*.

Muscles of the Pelvic Appendage

M. ILIOTROCHANTERICUS CAUDALIS

(IL. TROC. CAUD.)

FIGURES 2, 10, 11

DESCRIPTION.—The ilioprochantericus caudalis (Figure 10) arises fleshy from most of the preacetabular ilium (ala preacetabularis). The belly is very large. Its fibers converge caudally and end on a short broad tendon that inserts on the proximocranial edge of the external surface of the femoral trochanter. The iliofemoralis externus is fused to the ilioprochantericus caudalis except for its extreme distal end and tendon of insertion.

COMPARISON.—The ilioprochantericus caudalis is widest in *Aptenodytes*, *Pygoscelis*, and *Eudyptula*; narrowest in *Spheniscus*, *Megadyptes*, and *Eudyptes*.

According to Watson (1883:103), this muscle "arises from the whole of the external surface of the iliac bone as far back as the posterior border of the acetabulum, as well as from the adjoining hollowed surface formed by the fifth, sixth, and seventh lumbo-sacral vertebrae." In no instance did I find the ilioprochantericus caudalis attached to the lumbo-sacral vertebrae, nor has such an arrangement been reported by any other worker.

M. ILIOTROCHANTERICUS CRANIALIS

(IL. TROC. CRAN.)

FIGURES 10-12

DESCRIPTION.—This muscle (Figure 12), much smaller than the ilioprochantericus caudalis, arises partly fleshy from about the caudal two-thirds of the ventrolateral edge of the preacetabular ilium. Carnially the belly is strongly adherent to a fibrous septum, which separates it from the ilioprochantericus caudalis. The ilioprochantericus cranialis is fused to the ilioprochantericus medius, the two muscles being barely distinguishable. Insertion is by means of a short, flat tendon on the lateral surface of the femoral trochanter, in common with the ilioprochantericus medius.

COMPARISON.—Only in *Eudyptula* is the origin separate from that of ilioprochantericus medius. In this genus the insertion, though separate, is just distal to that of the ilioprochantericus medius. Watson (1883:104) observed a tendency in *Aptenodytes* for the ilioprochantericus cranialis to divide into two distinct portions, an upper and a lower, with a cellular interval lying between them. He failed to recognize these as representing the ilioprochantericus cranialis and ilioprochantericus medius. According to Gervais and Alix (1877:454), the ilioprochantericus cranialis in *Eudyptes chrysolophus* attaches to the external border of the ilium, “*et, sur la face interne du femur, au dela du trochanter.*”

M. ILIOTROCHANTERICUS MEDIUS

(IL. TROC. MED.)

FIGURES 10-12

DESCRIPTION.—The ilioprochantericus medius (Figure 12) arises fleshy from the ventrolateral edge of the preacetabular ilium immediately caudal to the ilioprochantericus cranialis. The ilioprochantericus medius and ilioprochantericus cranialis are fused and nearly indistinguishable. Insertion is in common with the ilioprochantericus cranialis on the lateral surface of the femoral

trochanter. The femorotibialis medius partly covers this insertion.

COMPARISON.—Watson (1883:104), referring to the ilioprochantericus medius, states, “Of this muscle the Penguins do not possess the slightest trace.” In *Aptenodytes* he observed a tendency for the ilioprochantericus cranialis “to divide into two distinct portions, an upper and a lower, a cellular interval lying between them.” His two portions of the ilioprochantericus cranialis probably represent the ilioprochantericus cranialis and ilioprochantericus medius. The bellies are fused to some degree in all penguins. In *Eudyptula* the origins are separate.

M. ILIOFEMORALIS EXTERNUS

(ILFEM. EXT.)

FIGURES 10, 11

DESCRIPTION.—The iliofemoralis externus (Figure 11) is very weakly developed. It arises fleshy from the lateral dorsal ridge of the ilium immediately caudal to the ilioprochantericus caudalis. The origin is situated cranial to the acetabulum, an arrangement unusual among birds. The bellies of iliofemoralis externus and ilioprochantericus caudalis are almost completely fused, but the extreme distal end of the belly and the tendon of insertion are not fused to ilioprochantericus caudalis. The short, flat tendon of insertion passes over the ilioprochanterici tendons before inserting on the femoral trochanter. The tendon barely reaches the ischiofemoralis, which covers the distal end of the insertion of iliofemoralis externus.

COMPARISON.—The belly of this muscle is separate from that of ilioprochantericus caudalis in only one specimen (*Megadyptes antipodes*) examined. Gervais and Alix (1877:454) found the insertion to be in common with the ilioprochantericus caudalis, but the insertions were separate in all penguins that I examined.

M. ILIOFEMORALIS INTERNUS

(ILFEM. INT.)

FIGURE 14

DESCRIPTION.—The iliofemoralis internus is a small muscle arising fleshy from the ventral edge of the preacetabular ilium just medial to the ilioprochantericus medius. It passes caudadistally to insert fleshy on the medial surface of the femur near the proximal end of the femorotibialis internus.

COMPARISON.—This muscle is very uniformly developed, showing no significant variations in penguins. However, Meckel (1828:353) thought it to be absent in the Spheniscidae.

M. AMBIENS

FIGURES 10-14

DESCRIPTION.—The ambiens (Figure 13) is a large muscle, arising mostly fleshy from the ventral border of the acetabulum. The flattened belly lies on the medial side of the thigh, and terminates on a strong, flat tendon at about 0.86 femur. The tendon passes in a shallow groove (Figure 14) on the cranial surface of the patella, then through the patellar tendon to the lateral side of the knee. The tendon ends opposite the proximal part of the fibula by inserting (Figure 12) on the tendon of origin of the cranial head of the perforated flexors.

COMPARISON.—The ambiens is shortest in *Pygoscelis* and *Eudyptula*, and is longest in *Aptenodytes*.

M. ILIOTIBIALIS CRANIALIS

(ILTIB. CRAN.)

FIGURES 1, 9, 13

DESCRIPTION.—The iliotibialis cranialis (Figure 9) is a very powerful muscle, making up the anterior limit of the thigh. The origin is aponeurotic from the caudal end of the fused thoracic spinous ridge and fleshy from the cranial and cranioventral edges of the ilium. There is a strong

tendinous connection with the aponeurosis of the iliotibialis. Insertion (Figure 13) is fleshy on the medial and cranial surfaces of the patella and patellar tendon.

COMPARISON.—No major differences were noted other than variations in relative width, the belly being broadest in *Eudyptula* and *Megadyptes*.

M. ILIOTIBIALIS

(IL. TIB.)

FIGURES 2, 9, 13

DESCRIPTION.—The iliotibialis (Figure 9) is a weakly developed, thin sheet of muscle that arises by means of an aponeurosis from the spinous processes opposite the acetabulum. This aponeurosis is attached to the belly of the iliotibialis cranialis cranially and the biceps femoris caudally. The postacetabular part of the iliotibialis is absent. The belly is thin along its cranial margin and much thicker along its caudal border. The center of this muscle is aponeurotic distally. Insertion is tendinous on the crista cnemialis cranialis of the tibia in common with the femorotibialis medius and femorotibialis externus. The iliotibialis tendon forms a part of the patellar tendon.

COMPARISON.—The iliotibialis is a uniformly developed muscle in all species examined. According to Garrod (1873:643), the postacetabular portion of this muscle is absent in penguins, which is consistent with my observations. Watson (1883:112) reports the presence of this portion, although reduced to a minimum size, in every species he examined.

M. FEMOROTIBIALIS EXTERNUS

(FEM. TIB. EXT.)

FIGURE 12

DESCRIPTION.—The femorotibialis externus (Figure 12) is a very small muscle. It arises from the caudolateral surface of the femur beginning

at about 0.65 femur. Insertion is in common with the caudal margin of the patellar tendon.

COMPARISON.—In most penguins the femorotibialis externus can be partially separated at either its proximal or distal end. *Eudyptes pachyrhynchus* and *Megadyptes antipodes* have the most distinct femorotibialis externus. The muscle is not distinguishable in *Eudyptula* and is either absent or very vague in *Aptenodytes* and *Pygoscelis*.

M. FEMOROTIBIALIS MEDIUS

(FEM. TIB. MED.)

FIGURES 10, 11, 13, 14

DESCRIPTION.—The femorotibialis medius (Figure 10) consists of a large fleshy mass which arises from a very extensive area on the lateral and cranial surfaces of the femoral shaft from the trochanter to the distal condyles. The belly is strong and notched proximally by the insertion of the ilirotrochantericus cranialis and ilirotrochantericus medius. Insertion is mostly fleshy on the proximal surface of the patellar tendon.

COMPARISON.—The femorotibialis medius is similar in all forms examined.

M. FEMOROTIBIALIS INTERNUS

(FEM. TIB. INT.)

FIGURES 13, 14

DESCRIPTION.—This long, slender muscle (Figure 14) arises from the whole length of the medial surface of the femoral shaft, extending proximally to the insertion of the iliofemoralis internus. The belly is not divided into superficial and deep parts. Insertion is by a short, flat tendon on the cranial cnemial crest of the tibia.

COMPARISON.—The femorotibialis internus is similar in all forms examined.

M. CAUDO-ILIO-FEMORALIS

This muscle complex is composed of two muscles: M. caudofemoralis and M. iliofemoralis,

which are separate for most of their extent but have a common insertion.

M. CAUDOFEMORALIS

(CAUD. FEM.)

FIGURES 9, 10

DESCRIPTION.—The caudofemoralis (Figure 10) arises from about the cranial half of the pygostyle and from the last one or two free coccygeal vertebrae. The caudal end of the origin is tendinous. The flat, spindle-shaped belly passes craniodistally toward the femur. Just before fusing with the iliofemoralis it forms a short tendon. Insertion is in common with the iliofemoralis on the caudal surface of the femur between about 0.50 and 0.76 femur.

COMPARISON.—The caudofemoralis is very similar in all penguins examined in this study and by other workers.

M. ILIOFEMORALIS

(IL. FEM.)

FIGURES 9, 10

DESCRIPTION.—The iliofemoralis (Figure 10) arises from the ventrolateral surface of the crista iliaca dorsolateralis. The origin is mainly tendinous but includes a small fleshy area posteriorly. The belly is a broad, thin sheet, distinctly narrower at the distal end. Insertion is in common with the caudofemoralis as described above.

COMPARISON.—The origin of the iliofemoralis varies somewhat among genera. It is entirely fleshy in *Spheniscus*, mostly fleshy in *Aptenodytes*, mainly tendinous in *Eudyptes*, and entirely tendinous in *Pygoscelis*, *Eudyptula*, and *Megadyptes*.

I was unable to find the variation that Watson (1883:106) described for the insertion of the caudo-ilio-femoralis. He reported that the insertion is confined to the middle third of the femoral shaft in *S. demersus* and *S. magellanicus*, to the lower third in *Eudyptes chrysolophus*, and to the lower two-thirds in *Aptenodytes*. The means for the distal

end of this muscle's insertion ranged from 0.71 to 0.79 femur.

M. FLEXOR CRURIS LATERALIS

(FL. CR. LAT.)

FIGURES 9, 10

DESCRIPTION.—This very powerful muscle (Figure 9) arises mainly fleshy from the extreme caudal tip of the dorsal border of the ilium and from the transverse processes of about the first through sixth free caudal vertebrae. It inserts by means of a flat tendon in common with the flexor cruris medialis on the medial surface of the tibia between the middle and internal heads of the gastrocnemius. The insertion extends from about 0.16 to about 0.31 tibiotarsus. The accessory head is absent.

COMPARISON.—This muscle is very uniformly developed in the Spheniscidae. There is some difference in the relative width of the belly. It is widest in *Aptenodytes* and *Pygoscelis*, and narrowest in *Eudyptes* and *Eudyptula*. The accessory head is absent in all penguins.

M. FLEXOR CRURIS MEDIALIS

(FL. CR. MED.)

FIGURES 10, 11, 13, 14

DESCRIPTION.—The flexor cruris medialis (Figure 11) arises fleshy from the caudoventral edge of the ischium and the extremity of the pubis, including the cartilaginous extension of that bone. The belly passes obliquely craniodistally and, after being joined by a slip from the external oblique muscle, is inserted fleshy on the caudo-medial surface of the tibia just distal to the caput tibia. Insertion is in common with the flexor cruris lateralis. In a more typical bird, such as *Gallus*, the flexor cruris medialis becomes tendinous before joining the flexor cruris lateralis to contribute to their common insertion. The fleshy fibers of the slip from the external oblique muscle insert on an extensive length of the distal part of the

caudal border of the flexor cruris medialis and onto the medial surface of that muscle just before its insertion.

COMPARISON.—In *Megadyptes*, the slip from the external oblique muscle inserts along nearly the entire length of the caudal border of the flexor cruris medialis. In the other genera this union is not as extensive.

The origin of this muscle is most extensive in *Eudyptula* and least extensive in *Aptenodytes*. The belly is widest in *Aptenodytes*, intermediate in *Pygoscelis*, and narrowest in the remaining genera.

M. ILIOFIBULARIS

(ILFIB.)

FIGURES 9, 10

DESCRIPTION.—The iliofibularis (Figure 9) is a very well developed muscle. It arises fleshy from the entire dorsolateral crest of the ilium posterior to the iliotibialis. The cranioproximal edge of the belly is fused to the caudal edge of the iliotibialis. The belly is not covered by the iliotibialis. Proximal to the knee the converging fibers form a very strong, laterally compressed tendon, which passes through the biceps loop and continues distally to insert (Figure 10) on a well-defined tubercle on the caudolateral surface of the fibula. The insertion extends between about 0.30–0.35 tibiotarsus. The tendon appears to be composed of several tendinous fascicles.

COMPARISON.—The iliofibularis is a very uniformly developed muscle in penguins.

M. ISCHIOFEMORALIS

(ISCH. FEM.)

FIGURES 10, 11

DESCRIPTION.—The muscle (Figure 11) arises from most of the lateral surface of the area occupied by the flexor cruris medialis and from the ventral edge of the caudal part of the dorsolateral crest of the ilium medial to the iliofibularis. The fibers pass cranially, converging on a stout tendon

that inserts on the femoral trochanter caudal to the insertions of the ilirotrochantericus cranialis and medius.

COMPARISON.—Except for some variation in length, this is a very uniformly developed muscle. It is longest in *Aptenodytes* and shortest in *Eudyptula*.

M. OBTURATORIUS MEDIALIS

(OBT. MED.)

FIGURES 12, 13

DESCRIPTION.—The obturatorius medialis (Figure 13) is an elongate oval muscle. It arises from the inner surface of most of the ischium caudal to the obturator foramen and from most of the medial surface of the pubis. Anteriorly the muscle enters the obturator foramen and passes to the outside of the pelvis, where the fibers end on a strong tendon that inserts on the caudal edge of the femoral trochanter just caudal to the insertion of the ischiofemoralis. Insertion is in common with the obturatorius lateralis and is partly fleshy.

COMPARISON.—The width is about 0.25 the length of the muscle in *Aptenodytes*. In *Spheniscus* it is about 0.44 the length of the muscle.

M. OBTURATORIUS LATERALIS

(OBT. LAT.)

FIGURE 12

DESCRIPTION.—The obturatorius lateralis is a small quadrilateral muscle that arises from the lateral surface of the pelvis adjacent to the obturator foramen. Insertion is on the caudal border of the femoral trochanter in common with the obturatorius medialis.

COMPARISON.—This muscle is very similar in all forms examined.

M. PUBO-ISCHIO-FEMORALIS

(PUB.-IS.-FEM.)

FIGURES 9-13

DESCRIPTION.—This very powerful muscle (Figure 12) arises mainly fleshy from almost the entire

length of the lateral surface of the pubis caudal to the acetabulum, from part of the cartilaginous extension of this bone, and from a less extensive area on the ventrolateral edge of the ischium. The belly is clearly divided into lateral and medial heads, especially anteriorly. The fibers pass craniodistally to insert on the caudal border of the femoral shaft distal to about 0.37 femur. The insertion is mostly fleshy, but a few of the caudal fibers insert by means of a tendon immediately above the internal condyle of the femur. This muscle is firmly fused to the gastrocnemius pars medialis for a considerable length.

COMPARISON.—Although the pubo-ischio-femoralis shows no major variations in penguins, there is a slight variation in the relative width of the belly; it is widest in *Aptenodytes*, *Pygoscelis*, and *Spheniscus*, narrowest in *Megadyptes*. There is also some variation in the length of origin along the pubis. It is longest in *Aptenodytes* and shortest in *Eudyptes*.

M. TIBIALIS CRANIALIS

(TIB. CRAN.)

FIGURES 10, 11, 13-16

DESCRIPTION.—The tibialis cranialis (Figure 10) arises by two distinct heads. The lateral head arises by means of a strong tendon from the cranial surface of the lateral condyle of the femur. The medial head has a fleshy origin from a very small part of the lower border of the patella, the intermuscular septum, which separates the tibialis cranialis from the gastrocnemius pars medialis, and from the cranial cnemial crest of the tibia. The medial head is also tendinous from a very narrow area on about the proximal fourth of the cranial border of the tibia. The heads unite and form a single tendon opposite the tibiotarsus. The tendon passes beneath a heavy fibrous loop (Figure 15) just above the distal malleoli, traverses the intertarsal joint, and inserts on a tubercle of metatarsus III at about 0.34 tarsometatarsus. It sends a smaller branch laterally to metatarsus II.

COMPARISON.—Watson (1883:118) describes a single insertion on metatarsus III in penguins. Only in *S. mendiculus* did he find a branch to metatarsus II. I found a branch to metatarsus II in most penguins. Only in *Pygoscelis papua* (1S), *P. antarctica* (1S), *Eudyptes chrysolophus schlegeli* (1S), and *E. chrysocome* (1S) did I find a single insertion on metatarsus III.

M. EXTENSOR DIGITORUM LONGUS

(EXT. DIG. L.)

FIGURES 9, 12, 14, 15

DESCRIPTION.—This muscle (Figure 12) occupies the cranial surface of the tibiotarsus immediately caudal to the tibialis cranialis. The origin is fleshy from a small area on the distal border of the patella and from about the proximal half or less of the craniomedial surface of the tibia. The weak bipennate belly tapers distally; ending on a tendon that passes under the retinaculum extensorium tibiotarsi in common with the tibialis cranialis and through a bony canal on the distal end of the tibiotarsus, crosses the intertarsal joint, slides under the retinaculum extensorium tarsometatarsi, and expands into an aponeurotic triangle that, upon reaching the base of the three digits, divides sending a branch to each digit (Figure 15). The middle branch bifurcates more or less vaguely near the base of digit III; these are connected by an aponeurosis.

First digit: There is no branch to the first digit.

Second digit: The branch to the second digit inserts mainly on the distal end of phalanx 1 and the bases of the second and third phalanges.

Third digit: The medial branch inserts mainly on the distal end of phalanx 1 and proximal end of phalanx 2. The long lateral branch gives off a branch laterally to the base of phalanx 3, then continues distally. It inserts mainly on the bases of the second, third, and ungual phalanges.

Fourth digit: The branch to the fourth digit inserts mainly on the bases of the second, third, fourth, and fifth phalanges.

COMPARISON.—This is a very uniformly developed muscle in penguins.

M. FIBULARIS LONGUS

(FIB. LONG.)

FIGURES 9-11, 15, 18

DESCRIPTION.—The fibularis longus (Figure 9) occupies the cranial and craniolateral surfaces of the shank. It arises tendinous from the cranial surface of the cranial cnemial crest of the tibia, by a strong aponeurosis from a long narrow line on the craniolateral border of the tibia, and partly fleshy from about the middle third of the lateral border of the fibula. The muscular fibers end on a tendon above the intertarsal joint at about 0.78 tibiotarsus. Just above the malleolus, the tendon gives off a very broad flattened expansion to the lateral side of the proximal end of the tibial cartilage. This expansion is strongly attached to the lateral surface of the lateral malleolus. After passing the intertarsal joint, the tendon divides into a cranial and a caudal branch. The cranial tendon passes down the lateral side of metatarsus IV and the fourth digit, ending on the penultimate phalanx of digit IV. The caudal branch (Figure 18) passes obliquely caudodistally and unites with the tendon of the flexor perforatus digiti III.

COMPARISON.—No significant variations were noted in penguins.

M. FIBULARIS BREVIS

(FIB. BREV.)

FIGURES 9-12

DESCRIPTION.—The fibularis brevis (Figure 12) is a very slender muscle that arises from about the distal half of the fibula and the adjacent border of the tibia. Its tendon passes caudodistally across the lateral malleolus and, after crossing the intertarsal joint, inserts on the lateral edge of the tarsometatarsus.

COMPARISON.—No significant differences occur

in the Spheniscidae. The fibularis brevis is an extremely weak muscle in penguins. Watson (1883:119) has this muscle arising from the upper two-thirds of the fibula. The most extensive origin occurs in *Megadyptes*, in which it arises from most of the length of the fibula. In most of the other penguins, the origin is confined to the distal two-thirds of the fibula.

M. GASTROCNEMIUS

(GAS.)

FIGURES 9-13

DESCRIPTION.—The gastrocnemius forms the superficial musculature of most of the medial and posterior surface of the shank and arises by three distinct heads: pars lateralis, pars intermedia, and pars medialis.

Pars lateralis (P. LAT.: Figures 9, 12, 13): This head (Figure 9) arises by a strong tendon from the femur just above the proximolateral edge of the external condyle and partly fleshy from the length of the biceps loop. The belly broadens over the caudolateral surface of the shank and ends on a tendon at about 0.74 tibiotarsus. This tendon joins that of the pars medialis just above the tibial cartilage.

Pars intermedia (P. INT.: Figures 12, 13): The intermediate head of the gastrocnemius (Figure 12) has a tendinous origin from the caudal edge of the proximal end of the medial condyle of the femur. Proximally the belly is strongly fused to the pubo-ischio-femoralis. Distally the belly of the pars intermedia joins the pars medialis at about 0.40 tibiotarsus. This union is partly fleshy.

Pars medialis (P. MED.: Figures 10-13): The medial head of the gastrocnemius (Figure 13) arises mainly fleshy from the cranial cnemial crest of the tibia, from the medial edge of the patella, and from the aponeurosis, separating it from the tibialis cranialis. The common tendon of the intermediate and medial heads joins the tendon of the lateral head just above the tibial cartilage forming a very strong tendon that, after passing the intertarsal joint, divides into two stout branches.

The heavier intermediate branch has a broad insertion near the proximal end of metatarsus II; the lateral branch inserts more distally on the caudolateral border of metatarsus IV, a little below the middle.

COMPARISON.—Very little variation was noted in the gastrocnemius, although the length of the belly shows some variation. It is longest in *Megadyptes* and much shorter in the other genera.

M. PLANTARIS

(PLAN.)

FIGURE 14

DESCRIPTION.—The plantaris is a short, flat muscle that arises fleshy from about the proximal third of the caudal border of the tibia. About halfway down the shank, the belly ends on a flattened tendon, which rapidly tapers to a small oval form. Insertion is on the proximal end of the medial side of the tibial cartilage.

COMPARISON.—The belly is longest in *Megadyptes* and shortest in *Aptenodytes* and *Pygoscelis*.

Position of the Flexor Tendons Passing the Intertarsal Joint

DESCRIPTION.—Removal of the gastrocnemius tendon from the posterior surface of the joint capsule exposes a bundle of three tendons on the caudolateral side. The most cranial of these is a flexor perforatus digiti III, which forms a sheath around the flexor perforans et perforatus digiti III medially and the flexor perforatus digiti IV laterally. The remaining four tendons traverse separate canals. On the caudomedial side is a canal for the flexor perforans et perforatus digiti II. Cranial and slightly lateral there is a canal for the flexor perforatus digiti II. Lateral to the flexor perforatus digiti II is a canal for the flexor hallucis longus. The most cranial canal encloses the tendon of the flexor digitorum longus.

COMPARISON.—Most penguins adhere to the above pattern. However, some species of *Eudyptes*, *Spheniscus*, and *Eudyptula* have the flexor perforans

et perforatus digiti III caudal to the flexor perforatus digiti IV.

M. FLEXOR PERFORANS ET PERFORATUS DIGITI II

(F. P. ET P. D. II)

FIGURES 9, 18

DESCRIPTION.—This muscle (Figure 9) has a very broad origin extending from the gastrocnemius pars lateralis to the cranial cnemial crest, tendinous from the external condyle of the femur, the joint capsule, the underlying biceps loop, and the cranial cnemial crest. The belly is strongly attached to the gastrocnemius pars lateralis near the extreme proximal end of this muscle and to the flexor perforans et perforatus digiti III and the fibularis longus. The belly ends a little above the middle of the shank on a flat tendon, which narrows as it passes distally. Near the base of the second digit the tendon perforates that of the flexor perforatus digiti II before inserting mainly on the distal end of phalanx 1 and proximal end of phalanx 2. There is also a strong attachment to the base of phalanx 1.

COMPARISON.—This muscle in *Eudyptes chrysolophus* has an additional origin from the tibia and fibula, according to Gervais and Alix (1877:460). I failed to find such an origin in any specimen examined. They also describe two fleshy sheets comprising this muscle. Such an arrangement occurred in several specimens of *Spheniscus*, *Aptenydytes*, and *Pygoscelis*, but shows intraspecific variation.

M. FLEXOR PERFORANS ET PERFORATUS DIGITI III

(F. P. ET P. D. III)

FIGURES 9, 18

DESCRIPTION.—This muscle (Figure 9) arises partly fleshy from the head of the fibula, fleshy from a narrow line on the lateral surface of the fibula, to a point just distal to the iliofibularis insertion, partly tendinous from the lateral edge of the cranial cnemial crest, the lateral side of the

joint capsule, and from the patellar tendon. The belly is larger than that of the flexor perforans et perforatus digiti II. Just distal to the middle of the shank, the belly ends on a tendon that is broad proximally. Near the base of the third digit, the tendon perforates that of the flexor perforatus digiti III and, in turn, is perforated by the tendon of the flexor digitorum longus near the proximal end of phalanx 2. Insertion is on the distal end of phalanx 2 and proximal end of phalanx 3 by two branches that result from the perforation by the flexor digitorum longus.

COMPARISON.—The flexor perforans et perforatus digiti III is very similar in all penguins.

M. FLEXOR PERFORATUS DIGITI II

(FLEX. PER. D. II)

FIGURES 11, 18

DESCRIPTION.—This muscle arises fleshy from the intercondylar space in common with the medial and lateral heads of flexor perforatus digiti III and flexor perforatus digiti IV. The belly separates from the common muscle mass at approximately the middle of the shank. At about 0.75 tibiotarsus, the belly terminates on a tendon that, after being perforated by the flexor perforans et perforatus digiti II near the base of phalanx 1 digit II, is inserted on the base of the proximal phalanx.

COMPARISON.—The belly is longest in *Aptenydytes* and shortest in *Eudyptes*. Except for this difference in length, the flexor perforatus digiti II is very similar in all penguins.

M. FLEXOR PERFORATUS DIGITI III

(FLEX. PER. D. III)

FIGURES 9-11, 14, 18

DESCRIPTION.—The flexor perforatus digiti III (Figure 10) arises from the regio intercondyloidea of the femur by means of a broad, flat tendon. This tendon is strongly attached to the cranial surface of the flexor perforatus digiti IV belly. It

also arises in common with the flexor perforatus digiti II and flexor perforatus digiti IV from the head of the fibula and lateral condyle of the femur by means of a short tendon. The belly is notched slightly proximally. A tendinous sheet extends between these two parts of the belly. The flexor perforatus digiti III is the longest of the perforated flexors. Near the distal end of the tibiotarsus, the tendon forms a sheath around the more caudally situated tendons of the flexor perforans et perforatus digiti III and flexor perforatus digiti IV. Near the middle of the tarsometatarsus, the tendon is very strongly attached to the caudal branch of the fibularis longus tendon. Near the base of phalanx 1, the tendon is perforated by that of the flexor perforans et perforatus digiti III. Insertion is on the distal end of phalanx 1. There is no vinculum between the tendons of the flexor perforatus digiti III and flexor perforans et perforatus digiti III.

COMPARISON.—The flexor perforatus digiti III is a very uniformly developed muscle except for some variation in the length of the belly. There is no vinculum between the tendons of the flexor perforatus digiti III and flexor perforans et perforatus digiti III in any penguin examined.

M. FLEXOR PERFORATUS DIGITI IV

(FLEX. PER. D. IV)

FIGURES 10, 11, 18

DESCRIPTION.—The flexor perforatus digiti IV (Figure 10) has a fleshy origin from the regio intercondyloidea of the femur. It also arises by a short tendon from the head of the fibula and lateral condyle of the femur in common with the flexor perforatus digiti II and flexor perforatus digiti III. This short tendon passes medial to the tendon of insertion of the iliofibularis. The belly gives rise to a tendon at about 0.63 tibiotarsus. Near the base of the fourth digit, the tendon dilates before dividing into four branches (Figure 18). The lateral branch (branch 1) fuses with the medial branch (branch 4) near the middle of phalanx 1 before inserting on the proximal end

of phalanx 2. The two middle branches (branches 2 and 3) fuse near the base of phalanx 2 and insert on the base of phalanx 3. The flexor digitorum longus tendon to the fourth digit passes between branches 1 and 4 and then between branches 2 and 3.

COMPARISON.—The insertion of the flexor perforatus digiti IV exhibits several variations. In *Eudyptes*, *Spheniscus*, and *Megadyptes*, the tendons exhibit the same pattern as that described for *E. pachyrhynchus*. Branch 1 remains separate in *Eudyptula* and inserts on the distal end of phalanx 1 and proximal end of phalanx 2, while branches 2 and 4 fuse near the distal half of phalanx 1 before inserting on the proximal end of phalanx 2. In *Eudyptula*, branch 3 remains separate and inserts on the base of phalanx 3, the tendon of the flexor digitorum longus to the fourth toe passing lateral to branch 3. In *Pygoscelis*, branches 1 and 4 fuse before inserting on the base of phalanx 2. Branch 2 remains separate and inserts on the proximal end of phalanx 3. Branch 3 likewise remains separate but inserts on the base of phalanx 4. The flexor digitorum longus tendon to the fourth digit passes between branches 1 and 4 and then between branches 2 and 3. None of the branches fuse in *Aptenodytes*. Branches 1 and 4 insert on the base of phalanx 2; while branches 2 and 3 insert on the bases of phalanx 3 and phalanx 4, respectively. The flexor digitorum longus tendon passes medial to branch 1 and lateral to branches 2, 3, and 4. The belly is longest in *Megadyptes* and shortest in *Pygoscelis* and *Eudyptes*.

M. FLEXOR HALLUCIS LONGUS

(F. HAL. L.)

FIGURES 10-12, 14, 15, 18

DESCRIPTION.—The flexor hallucis longus (Figure 12) arises fleshy from the regio intercondyloidea of the femur in common with the perforated flexors. Its belly is large in relation to the size of the hallux. About midway the tibiotarsus, the short belly ends on a broad, flat tendon, which tapers as it passes distally toward the intertarsal

joint. The tendon trifurcates opposite the tarso-metatarsus just before fusing with the flexor digitorum longus. On the medial side, there is a fibrous connection between the tendons of the flexor hallucis longus and flexor digitorum longus immediately proximal to the trifurcation. This connection has some resemblance to a vinculum. Of the three very short branches of the flexor hallucis longus, the one that fuses with the flexor digitorum longus tendon to the fourth digit is the strongest. The branch to the third digit is very weak. In addition to these three tendons, a fourth very delicate tendon arises from the medial edge of the flexor hallucis longus opposite the trifurcation. It inserts on the base of the ungual phalanx of the hallux.

COMPARISON.—This muscle shows very little variation among penguins. In several specimens of *Pygoscelis*, I was unable to find the branch to the hallux. Poor preservation may account for this omission. The belly is longest in *Spheniscus* and shortest in *Aptenodytes*.

M. FLEXOR DIGITORUM LONGUS

(F. DIG. L.)

FIGURES 9-12

DESCRIPTION.—This powerful deeply situated muscle (Figures 12, 14) arises from most of the caudal and medial borders of the tibia distal to the popliteus, from the interosseus membrane, and the adjacent border of the fibula. The belly gives rise to a strong tendon near the distal end of the tibiotarsus. The tendon trifurcates near the proximal end of the tarsometatarsus. The three branches, after uniting with those of the flexor hallucis longus, insert on the bases of the ungual phalanges of digits 2, 3, and 4. There is a short fibro-elastic branch to the base of each phalanx except phalanx 1.

COMPARISON.—No important variations were noted.

M. POPLITEUS

DESCRIPTION.—This small, quadrilateral muscle has a fleshy origin from the proximal end of

the caudomedial border of the fibula. Insertion is fleshy near the proximal end of the caudal surface of the tibial shaft. The muscle broadens before reaching its insertion and is fleshy throughout.

COMPARISON.—The popliteus is a very uniformly developed muscle in penguins.

M. EXTENSOR HALLUCIS LONGUS

(EXT. HAL. L.)

FIGURES 15, 16

DESCRIPTION.—The origin of this small muscle (Figure 15) is fleshy from the dorsal and medial surfaces of the rudimentary metatarsus I and from the ligament that connects the first to the second metatarsal. The belly ends near the proximal end of phalanx 1. The tendon of insertion is separated from the surrounding connective tissue with difficulty. It traverses the dorsal surface of the hallux and is inserted along most of the length of phalanx 1 and on the base of the ungual phalanx.

COMPARISON.—The origin extends onto metatarsus III in a specimen of *A. forsteri* (1 S), *P. antarctica* (1 S), *E. pachyrhynchus* (1 S), and *M. antipodes* (1 S).

M. EXTENSOR BREVIS DIGITI III

(EXT. BREV. D III)

FIGURES 15, 16

DESCRIPTION.—The origin (Figure 16) is fleshy from most of the cranial surface of metatarsus III and the groove between metatarsus II and metatarsus III. The broad belly terminates on a short, flat tendon that inserts on the base of the first phalanx of digit III. The broad tendon is grown into the joint capsule.

COMPARISON.—This muscle varies only in length. The belly is shortest in *Pygoscelis* and longest in *Aptenodytes* and *Eudyptula*.

M. EXTENSOR BREVIS DIGITI IV

(EXT. BREV D. IV)

FIGURES 14-16

DESCRIPTION.—The origin (Figure 16) is fleshy from the cranial and medial surfaces of metatarsus IV and the lateral edge of metatarsus III. Its belly is wide and occupies most of the cranial surface of metatarsus IV. Insertion is by a short tendon on the medial edge, proximal end, of phalanx 1, digit IV. The tendon passes through a groove between metatarsus III and metatarsus IV. There is no bony canal.

COMPARISON.—The belly of extensor brevis digiti IV is longest in *Eudyptula* and shortest in *Aptenodytes*.

M. ABDUCTOR DIGITI II

(ABD. DIG. II)

FIGURES 13-18

DESCRIPTION.—This muscle (Figure 16) arises fleshy from most of the cranial and craniomedial borders of metatarsus II. The belly is wide proximally and narrow distally. It ends on a short, strong tendon at about 0.66 tarsometatarsus. Insertion is on the dorsomedial edge of the base of phalanx 1, digit II.

COMPARISON.—The abductor digiti II is a uniformly developed muscle in penguins. In some specimens there is a division in the belly distally. This division tends to be most obvious in *Aptenodytes*.

M. FLEXOR HALLUCIS BREVIS

DESCRIPTION.—The flexor hallucis brevis is present in only five of the six specimens of *Pygoscelis* examined. In these it has a fleshy origin from a very small area on metatarsus II at the base of metatarsus I and from most of the plantar surface of metatarsus I. The belly is very small. Insertion is by a short tendon on the base of the distal phalanx.

COMPARISON.—This muscle is absent in all specimens of *Eudyptes* examined. Watson (1883:126) was unable to find this muscle in any of the specimens examined in his study. Meckel (1828) does not describe this muscle for penguins. Reid (1835:145) and Gervais and Alix (1877:461) describe this muscle in *A. patagonicus* and *E. chrysolophus*, respectively. The muscle is apparently present in only a small percentage of penguins. The high frequency of its occurrence in *Pygoscelis* suggests that this muscle may be characteristic in this genus and, hence, of taxonomic importance. A larger sample is needed for verification.

M. LUMBRICALIS

DESCRIPTION.—The lumbricalis arises from the cranial surface of the deep flexor tendon just distal to the point of trifurcation. The muscle is very vague and appears mostly fibrous. Insertion is on the joint pulley near the base of digit III.

COMPARISON.—The lumbricalis is very weak in penguins, and most specimens have only a very small vestige when present. Poor preservation may account for its absence in several specimens.

M. ABDUCTOR DIGITI IV

(ABD. DIG. IV)

FIGURES 17, 18

DESCRIPTION.—The origin (Figure 18) is fleshy from most of the caudal border of metatarsus IV. The belly is wider proximally and narrow distally. Insertion is by a short tendon on the lateroplantar edge of the base of the first phalanx of digit IV. The tendon is strongly fused with the connective tissue over the joint.

COMPARISON.—This is a uniformly developed muscle in penguins.

The following muscles are absent in the sphenisciform leg: M. extensor proprius digiti III, M. abductor digiti II, and M. adductor digiti IV.

Discussion and Conclusions

The pectoral musculature of penguins is unlike that of any other group of birds. A number of

wing muscles are absent, most remarkably the biceps. The biceps is absent only in penguins. Several other wing muscles, the expansor secundariorum, scapulohumeralis cranialis, and serratus superficialis metapatagialis, are also absent in penguins. The pronator superficialis and pronator profundus are likewise absent, a loss associated with the inability of the wing to be rotated at the elbow. Somewhat surprising, because of the lack of a well-developed patagial wing fold, is the presence of a well-developed propatagialis muscle whose tendon inserts along much of the length of the wing and is strongly attached to the alar aponeurosis. Beddard (1898:397) and Watson (1883:88) have this tendon passing all the way to the extremity of the last phalanx. The latissimus dorsi is peculiar in that its two parts end in long, slender tendons that pass through a fibrous loop from the scapula. The latissimus dorsi metapatagialis varies greatly in development. It is an extremely wide muscle in *Aptenodytes* and very narrow in *Pygoscelis* and *Eudyptula*. With the exception of *Pygoscelis*, the development seems to be related to the size of the bird. The insertion of this muscle in penguins is on the skin along the lateral line of the trunk instead of near the humeral feather tract as in most birds. Most of the muscles acting across the shoulder joint are very well developed, a reflection of the peculiar action of the wings during underwater flight. The pectoralis thoracica is so large that it meets its fellow in the midline over the carina, a condition similar to that in Tinamous (Watson, 1883:397). The supracoracoideus is very strongly developed in relation to the pectoralis. These two muscles are the prime movers of the wing during underwater flight. Although the short head of the deltoideus minor is very small and weak, the long head is large and aids the supracoracoideus in raising the wing. The deltoideus major, on the other hand, is a very weak muscle.

Only nine muscles distal to the shoulder have fleshy fibers. The triceps has a peculiar arrangement in penguins. Both the triceps scapularis and triceps humeralis consist of two heads. One head of the triceps scapularis arises from the clavicle

and acromial process of the scapula; the other head arises fleshly from the dorsolateral border of the scapula in much the same position as the aponeurotic anchor (George and Berger, 1966:335) arises in many other birds. The triceps humeralis has both a dorsal and ventral head arising from the humerus. The brachialis is peculiar in penguins in that it inserts on the radius as a consequence of the extreme dorsoventral compression of the wing, an adaptation to underwater flight. Occasionally a small slip separates from the caudal edge of the muscle and inserts on the ulna in a position reminiscent of other birds. The extensor metacarpi radialis is a small, weak muscle showing no indication of a division. Its tendon fuses with that of the extensor longus alulae. These two muscles act as extensors of the wrist, counteracting the powerful flexor, the ulnometacarpalis dorsalis, of the wrist.

Three muscles arising from the carpometacarpus control flexion and extension of the phalanges. Extension is mediated by the very weak abductor digiti majoris and interosseus ventralis muscles. Flexion is the function of the strong flexor digiti minoris.

The arrangement of the muscles of the leg is less characteristic than that of the wing. Gervais and Alix (1877:465) and Watson (1883:137) perceived it as being similar to the arrangement that characterizes the palmipedes (swimming birds) in general. There are a number of deviations from the arrangement found in these birds. The similarities can be accounted for by adaptations to similar modes of life. The iliotrochantericus cranialis and iliotrochantericus medius are fused. In penguins the iliofemoralis externus is very weak and fused to the iliotrochantericus caudalis except at the extreme distal end. This muscle is absent in *Podiceps*, but present in most other swimming birds, such as *Gavia*, *Sula*, and *Chen* (Hudson, 1937:13). The ambiens is a very strong, broad muscle approaching the condition reported by Hudson (1937:15) for *Gavia*. It is also well developed in other swimming birds but is absent in grebes (Watson, 1883:129). The caudal part of the iliotibialis is absent in penguins, but shows a

wide range of variation among other groups of swimming birds. The caudo-ilio-femoralis is well developed in all penguins, and both parts are present. The insertion of this muscle is far distal on the femur. The absence of the caudal part of the iliotibialis leaves the iliofibularis uncovered superficially.

A slip of muscle from the external oblique inserts on an extensive area of the caudal border of the flexor cruris medialis, an arrangement found in no other group of birds. The flexor cruris medialis shares a common insertion with the flexor cruris lateralis. The insertion is by means of a fleshy sheet medially and tendinous sheet on the lateral side. The accessory flexor cruris lateralis is absent in all penguins.

The weak condition of the short muscles of the hallux and the delicate nature of the tendon from the flexor hallucis longus are most likely related to the vestigial nature of the hallux. The flexor hallucis brevis is absent in most penguins examined. It is present in only five of the six specimens of *Pygoscelis*. It has, however, been described in *Aptenodytes patagonicus* (Reid, 1835:145) and *Eudyptes chrysolophus* (Gervais and Alix, 1877:461). Watson (1883:126) was unable to find any trace of this muscle in the penguins he examined.

The absence of the adductor digiti II and weak condition of the lumbricalis are also specialized features of the leg myology of penguins.

Data in the present study were treated numerically by two methods, cumulative scores of difference using weighted data and correlation coefficients giving equal weight to all characters. The two methods give closely parallel results. This is evident in most interspecific and intergeneric comparisons. Low scores of difference are usually associated with high positive correlation coefficients and high scores with high negative correlation coefficients.

In comparing various taxa, wing scores are usually larger than leg scores. The mean for all wing scores is 15.46 points and of leg scores 11.39 points. Only in the genus *Eudyptes*, does the mean score for the leg exceed the wing score: 8.97 for the legs compared to 8.10 for the wings. Many

other groups of birds show just the opposite, the wings being least variable, e.g., in Galliformes (Hudson and Lanzillotti, 1964), Lari and Alcae (Hudson et al., 1969), Ciconiiformes (Vanden Berge, 1970), Strigiformes and Caprimulgiformes (Hoff, 1966), and Tinamous (Hudson et al., 1972). The greater difference in wings compared to legs is not surprising in view of the great modification of the wing for underwater propulsion and differences in absolute size in different genera. In the largest penguins, *Aptenodytes* and *Pygoscelis*, the latissimus dorsi cranialis and caudalis have increased so tremendously in width that their adjacent borders have fused. This numerical comparison indicates that the antarctic-subantarctic genera *Aptenodytes* and *Pygoscelis* exhibit the least interspecific variation, suggesting that species in these genera are very closely related. The two genera, although quite different, are more closely related to each other than to other genera, as Peters (1931:29-31) indicates by placing *Pygoscelis* immediately after *Aptenodytes*; they are not necessarily more primitive than other genera as his classification indicates. They are perhaps less "primitive," being very specialized in structure and behavior to endure the severe environment of the antarctic region. Most likely these genera evolved from forms inhabiting temperate regions. Fossil evidence (Simpson, 1971) suggests that the Sphenisciformes evolved in temperate regions and have moved into the more inhospitable antarctic regions. Selective pressures most likely limit the amount of variation possible, thus accounting for the similarity between these antarctic-subantarctic species.

All correlation coefficients are low, i.e., below 0.60. Correlation coefficients of 0.60 or higher are generally used in biological work to indicate close relationship between two entities; two specimens of the same species would therefore be expected to have a correlation coefficient of 0.60 or higher. Conversely, as the coefficient approaches -1 , entities exhibit less similarity and hence a more distant relationship. Low correlation coefficients support the presently recognized genera.

Eudyptula m. minor and *E. m. albosignata* are very

similar to each other. The scores of difference for the wings, however, are higher than might be expected for subspecies so strongly correlated. This discrepancy may be a reflection of the very small sample used in this study.

Spheniscus is a rather heterogeneous assemblage, though the species of *Spheniscus* clearly constitute a definite group. Of the four species comprising the genus, *S. demersus* and *S. humboldti* (0.47) and *S. humboldti* and *S. mendiculus* (0.43) show the strongest correlation. *Spheniscus demersus* and *S. mendiculus* are somewhat less well correlated. *Spheniscus magellanicus* is most different. The similarity between *Eudyptes chrysolophus schlegeli* and *S. humboldti* suggests the possibility that *Spheniscus* represents a radiation of penguins from the Australian-New Zealand area into the South American-South African area. The derivation of *Eudyptes* from *Spheniscus* seems unlikely, since the fossil record (Simpson, 1946) indicates that penguins arose in the Australian-New Zealand area.

With myological data and geographical distribution, it is possible to construct a tentative phylogeny of sphenisciform birds. In such a phylogeny (Figure 19) three main divisions may be recognized: (1) *Aptenodytes*, *Pygoscelis*; (2) *Eudyptes*, *Megadyptes*; and (3) *Spheniscus*. *Eudyptula* represents

a small division with similarities to both the *Spheniscus* and *Eudyptes* assemblages. This is very similar to the phylogeny devised by Zusi (1975) based on osteology.

Separation of species within each division is also possible (Figure 19). Of the *Spheniscus* group, *S. magellanicus* is most different, having diverged along a separate pathway. *S. humboldti*, *S. demersus*, and *S. mendiculus* are relatively closely related. Penguins of the *Eudyptes*-*Megadyptes* lineage show greater divergence. *Megadyptes* has diverged significantly from the early members of this group, as has *E. chrysolophus schlegeli*. The remaining members of this group, being somewhat more closely related, have perhaps diverged more recently or occupied habitats with similar selective factors.

The antarctic-subantarctic assemblage is composed of two distinct genera, *Aptenodytes* and *Pygoscelis*. Within these genera, species exhibit rather close affinities. *A. forsteri* and *A. patagonicus* share a correlation of 0.54. *P. papua* shares a correlation of 0.60 with *P. antarctica* and a correlation of 0.62 with *P. adeliae*. The last two species share a correlation of only 0.56. These relationships suggest that *P. papua* is closest to the original species of *Pygoscelis*, while *P. adeliae* and *P. antarctica* have diverged to a greater degree.

Appendix

Interesting Features of the Appendicular Muscles

The following list considers the myological features of appendicular muscles that show important differences among various groups of birds. Muscles discussed in the text but not listed here exhibit no unusual modification in penguins. List is arranged in the same order as the muscles are discussed in the text.

MUSCLES OF THE PECTORAL APPENDAGE

- LATISSIMUS DORSI CRANIALIS.** Accessory slip from cranial edge of triceps scapularis present in *Aptenodytes* and *Pygoscelis*; absent in other genera.
- LATISSIMUS DORSI CAUDALIS.** Arises from thoracic ribs in penguins. Additional origin from spinous processes in *Aptenodytes* and *Pygoscelis*.
- LATISSIMUS DORSI METAPATAGIALIS.** Extreme intergeneric variation in width. Insertion on skin along lateral line of the trunk instead of near the humeral feather tract as in most birds.
- SERRATUS SUPERFICIALIS CRANIALIS.** Two fleshy fascicles. Very extensive insertion on the scapula.
- SERRATUS SUPERFICIALIS METAPATAGIALIS.** Absent in all penguins.
- SCAPULOHUMERALIS CRANIALIS.** Absent in all penguins.
- PECTORALIS PARS SUBCUTANEA ABDOMINALIS.** Cranial part present and very large; caudal part absent.
- SUPRACORACOIDEUS.** Very well developed in relation to the pectoralis thoracica.
- CORACOBRACHIALIS CRANIALIS.** A very weak (vestigial) muscle; not previously described for penguins.
- SUBCORACOIDEUS.** Belly large, single.
- SUBSCAPULARIS, CAPUT LATERALE.** Very large, much larger than caput mediale; caput mediale has origin from coracoid, clavicle, and adjacent scapula (= cranial head of subcoracoideus, Hudson, et al., 1969:464).
- PROPATAGIALIS.** Belly single, tendon extends length of wing and contributes to alar aponeurosis.
- DELTOIDEUS MAJOR.** A very weak, flat, usually triangular muscle in penguins.
- DELTOIDEUS MINOR.** Short head very small and weak; long head large, not connected to supracoracoideus.
- TRICEPS SCAPULARIS.** Two distinct heads of origin, one from clavicle and acromial process of scapula, other from lateral border of scapular shaft.
- TRICEPS HUMERALIS.** Two heads of origin, one from the pneumatic fossa, the other from about the distal 0.60 of the caudal border of the humeral shaft.
- BICEPS BRACHII.** Generally absent in penguins; rarely, a vestigial biceps is present.
- EXPANSOR SECUNDARIORUM.** Absent in all penguins.
- BRACHIALIS.** Inserts on proximal end of radius instead of on ulna as in other birds.
- PRONATOR SUPERFICIALIS.** Absent in all penguins.
- PRONATOR PROFUNDUS.** Absent in all penguins.
- ENTEPICONDYLO-ULNARIS.** Absent in all penguins.
- FLEXOR CARPI ULNARIS.** Represented by a tendon in all penguins.
- FLEXOR DIGITORUM SUPERFICIALIS.** Represented by a single tendon in all penguins.
- ULNIMETACARPALIS VENTRALIS.** Absent in penguins, except as an infrequent vestige in less than one-sixth of the specimens examined.
- EXTENSOR METACARPI RADIALIS.** Belly small, weak, single.
- SUPINATOR.** A very small, weak, fan-shaped muscle, inserts on dorsal surface of radius.
- EXTENSOR DIGITORUM COMMUNIS.** Represented by a tendinous band in penguins.
- EXTENSOR METACARPI ULNARIS.** Represented by a tendon in all penguins; insertion usually on the major metacarpal.
- ECTEPICONDYLO-ULNARIS.** Replaced by a tendon, occasionally a few fleshy fibers are present.
- EXTENSOR LONGUS ALULAE.** Two fleshy heads of origin; tendon fused with extensor metacarpi radialis at wrists; radial head absent in most *Eudyptula* wings.
- EXTENSOR LONGUS DIGITI MAJORIS.** Represented by a tendon in all penguins; no distal head.
- ULNIMETACARPALIS DORSALIS.** Belly large, single.
- ABDUCTOR ALULAE.** Absent in all penguins.
- FLEXOR ALULAE.** Absent in all penguins.
- ADDUCTOR ALULAE.** Absent in all penguins.
- EXTENSOR BREVIS ALULAE.** Absent in all penguins.
- ABDUCTOR DIGITI MAJORIS.** Flat, weak; arises from the ventral surface of the major metacarpal near cranial border.

INTEROSSEUS DORSALIS. Represented by a tendon in all penguins.

FLEXOR DIGITI MINORIS. Belly well developed.

MUSCLES OF THE PELVIC APPENDAGE

ILIO-TROCHANTERICUS CRANIALIS. Fused to ilioprochantericus medius, the two muscles are barely distinguishable.

ILIOFEMORALIS EXTERNUS. Very weak; fused to ilioprochantericus caudalis except extreme distal end of belly and tendon of insertion; origin cranial to acetabulum.

AMBIENS. Belly very strong; inserts on the tendon of origin of the cranial head of the perforated flexors.

ILIO-TIBIALIS. Cranial part present; postacetabular portion absent.

FEMOROTIBIALIS EXTERNUS. Completely separate in some taxa; partially fused with the femorotibialis medius in others; not separable in others.

FEMOROTIBIALIS MEDIUS. Origin partly covers common insertion of ilioprochantericus cranialis and ilioprochantericus medius.

FEMOROTIBIALIS INTERNUS. No division of belly distally.

CAUDO-ILIO-FEMORALIS. *M. caudofemoralis* and *M. iliofemoralis* well developed; insertion far distal on femur.

FLEXOR CRURIS LATERALIS. Origin fleshy from transverse processes of about the first six free caudal vertebrae, no attachment to ilium; accessory portion absent in all penguins.

FLEXOR CRURIS MEDIALIS. Insertion fleshy, in common with flexor cruris lateralis; a tendinous sheet on the lateral side of common insertion (on medial side in a more typical bird, e.g., *Gallus*).

ILIOFIBULARIS. Belly not covered by ilioprochantericus; tendon of insertion appears to be composed of two or more fibrous fascicles fused together and compressed laterally.

ISCHIOFEMORALIS. Extensive origin including much of ventral edge of the caudal part of the dorsolateral crest of the ilium.

OBTURATORIUS MEDIALIS. Insertion in common with obturatorius lateralis on caudal border of femoral trochanter.

OBTURATORIUS LATERALIS. Single; origin nearly surrounds foramen obturatorium.

PUBO-ISCHIO-FEMORALIS. Belly clearly divided into lateral and medial heads, especially cranially.

TIBIALIS CRANIALIS. Tendon of insertion sends a very weak branch laterally to metatarsus II.

EXTENSOR DIGITORUM LONGUS. Tendon forms aponeurotic triangle opposite tarsometatarsus.

FIBULARIS LONGUS. Tendon sends branch along lateral side of metatarsus IV and digit IV, ending on the penultimate phalanx.

FIBULARIS BREVIS. An extremely weak muscle.

GASTROCNEMIUS. All three heads well developed; tendon branches near the proximal end of the tarsometatarsus; does not ensheath flexor tendons over tarsometatarsus; pars intermedia strongly fused to pubo-ischio-femoralis.

MUSCLES OF THE FLEXOR TENDONS

FLEXOR PERFORANS ET PERFORATUS DIGITI II. Very broad proximally.

FLEXOR PERFORANS ET PERFORATUS DIGITI III. No vinculum between tendon of flexor perforans et perforatus digiti III and flexor perforatus digiti III; belly notched slightly proximal with a tendinous sheet extending between these two parts.

FLEXOR PERFORATUS DIGITI IV. The tendon of insertion shows four patterns of branching and attachment in different taxa.

FLEXOR HALLUCIS LONGUS. The tendon trifurcates opposite the tarsometatarsus, the three short branches fuse to those of the flexor digitorum longus; a fibrous connection on the medial side resembles a vestigial vinculum; branch to hallux very delicate, ending on the ungual phalanx; belly large in relation to size of hallux.

POPLITEUS. Muscle fleshy throughout.

EXTENSOR HALLUCIS LONGUS. Very weak; origin from rudimentary metatarsus and phalanx 1, tendon strongly attached to length of phalanx 1, ending on ungual phalanx.

EXTENSOR PROPRIUS DIGITI III. Absent in all penguins.

EXTENSOR BREVIS DIGITI IV. Tendon does not pass through a bony canal.

FLEXOR HALLUCIS BREVIS. Absent in *Aptenodytes*, *Eudyptes*, *Megadyptes*, *Eudyptula*, and *Spheniscus*; present in five of six specimens of *Pygoscelis* examined, minute.

ADDUCTOR DIGITI II. Absent in penguins.

LUMBRICALIS. Weak when present; most specimens have a very small vestige of this muscle.

ADDUCTOR DIGITI IV. Absent in all penguins.

Literature Cited

- Baumel, J. J., A. S. King, A. M. Lucas, J. E. Breazile, and H. E. Evans, editors
1979. *Nomina Anatomica Avium*. 637 pages. London: Academic Press.
- Beddard, F. E.
1898. *The Structure and Classification of Birds*. 548 pages. New York: Longmans, Green, and Co.
- Falla, R. A., and J.-L. Mougín
1979. Sphenisciformes. In E. Mayr and G. W. Cottrell, editors, *Check-list of Birds of the World*, second edition, 1:121-134. Cambridge, Mass.: Museum of Comparative Zoology.
- Filhol, H.
1885. Observations anatomiques, relative à diverses espèces de Manchots. *Memoires sur la Passage de Venus*, 3 (2):35-339.
- Gadow, H., and E. Selenka
1891. Vögel, 1: Anatomischer Theil. In H.G. Bronn, *Die Klassen und Ordnungen des Thier-Reichs.*, 6(4): 1008 pages. Leipzig.
- Garrod, A. H.
1873. On Certain Muscles of the Thigh of Birds, and Their Value in Classification. *Proceedings of the Zoological Society of London*, 1:626-644.
- George, J. C., and A. J. Berger
1966. *Avian Myology*. 500 pages. New York: Academic Press.
- Gervais, P., and E. Alix
1877. Osteologie et Myologie des Manchots. *Journal de Zoologie (Paris)*, 6:424-472
- Hoff, K. M.
1966. A Comparative Study of the Appendicular Muscles of Strigiformes and Caprimulgiformes. Ph.D. dissertation, Washington State University, Pullman.
- Hudson, G. E.
1937. Studies on the Muscles of the Pelvic Appendage in Birds. *American Midland Naturalist*, 18:1-108.
- Hudson, G. E., and P. J. Lanzillotti
1964. Muscles of the Pectoral Limb in Galliform Birds. *American Midland Naturalist*, 71:1-113.
- Hudson, G. E., R. A. Parker, J. Vanden Berge, and P. J. Lanzillotti
1966. A Numerical Analysis of the Modifications of the Appendicular Muscles in Various Genera of Gallinaceous Birds. *American Midland Naturalist*, 76:1-73.
- Hudson, G. E., K. M. Hoff, J. Vanden Berge, and E. C. Trivette
1969. A Numerical Study of the Wing and Leg Muscles of Lari and Alcae. *Ibis*, 111:459-524.
- Hudson, G. E., D. O. Schreiweis, S. Y. C. Wang, and D. A. Lancaster
1972. A Numerical Study of the Wing and Leg Muscles of Tinamous (Tinamidae). *Northwest Science*, 46: 207-255.
- Meckel, J. F.
1828. System der vergleichenden Anatomie. *Halle*, 3: 289-392.
- Peters, J. L.
1931. *Check List of the Birds of the World*. Volume 1. Cambridge: Harvard University Press.
- Reid J.
1835. Anatomical Description of the Patagonian Penguin (*Aptenodytes patachonica*). *Proceedings of the Zoological Society of London*, 132-148.
- Schoepss, C. G.
1829. Beschreibung der Flugmuskeln der Vögel. In J. F. Meckel, *Archiv für Anatomie und Physiologie*, 72-176. Leipzig.
- Sibley, C. G., and J. E. Ahlquist
1972. A Comparative Study of the Egg-White Proteins of Non-Passerine Birds. *Peabody Museum of Natural History Bulletin*, 39: 276 pages, 37 figures.
- Simpson, G. G.
1946. Fossil Penguins. *Bulletin of the American Museum of Natural History*, 87:9-99.
1971. A Review of the Pre-Pliocene Penguins of New Zealand. *Bulletin of the American Museum of Natural History*, 114:319-378.
1975. Fossil Penguins. In B. Stonehouse, editor, *Biology of Penguins*, pages 19-41. New York: Macmillan Publishing Company.
- Vanden Berge, J. C.
1970. A Comparative Study of the Appendicular Musculature of the Order Ciconiiformes. *American Midland Naturalist*, 84:289-364.
- Watson, M.
1883. Report on the Anatomy of the Spheniscidae Collected during the Voyage of H.M.S. *Challenger*. In *Report on the Scientific Results of the Voyage of H.M.S. Challenger during the Years 1873-76: Zoology*, 7(18): 244 pages. Edinburgh: Neil and Company.
- Zusi, R.
1975. An Interpretation of Skull Structure in Penguins. In B. Stonehouse, editor, *Biology of Penguins*. pages 59-84. New York: Macmillan Publishing Company.

Abbreviations on Illustrations

Arabic numbers and lower case letters on illustrations denote tendons that have been cut; each number or letter corresponds to the superscript of corresponding muscle; roman numeral denotes number of digit or muscle related to that digit.

ABD. DIG. II	Abductor digiti II	GAS. (P. LAT.)	Gastrocnemius pars lateralis
ABD. DIG. IV	Abductor digiti IV	GAS. (P. MED.)	Gastrocnemius pars medialis
ABD. DIG. MAJ.	Abductor digiti majoris	IL. FEM.	Iliofemoralis
BRACH.	Brachialis	ILFEM. EXT.	Iliofemoralis externus
CAUD. FEM.	Caudofemoralis	ILFEM. INT.	Iliofemoralis internus
COR. BRA. CAUD.	Coracobrachialis caudalis	ILFIB.	Iliofibularis
COR. BRA. CRAN.	Coracobrachialis cranialis	IL. TIB.	Iliotibialis
COS. STER. MAJ.	Costosternalis majoris	ILTIB. CRAN.	Iliotibialis cranialis
COS. STER. MIN.	Costosternalis minoris	IL. TROC. CAUD.	Iliotrochantericus caudalis
DELT. MAJ.	Deltoideus major	IL. TROC. CRAN.	Iliotrochantericus cranialis
DELT. MIN.	Deltoideus minor	IL. TROC. MED.	Iliotrochantericus medius
DEPR. CAUDAE	Depressor caudae	INT. COS. EXT.	Intercostalis externus
ECT.-ULN.	Ectepicondyloulnaris	INT. COS. INT.	Intercostalis internus
E. DIG. COM.	Extensor digitorum communis	INT. DOR.	Interosseus dorsalis
E. LON. AL.	Extensor longus alulae	INT. VEN.	Interosseus ventralis
E. LON. DIG. MAJ.	Extensor longus digiti majoris	ISCH. FEM.	Ischiofemoralis
E. META. RAD.	Extensor metacarpi radialis	LAT. DOR. CAUD.	Latissimus dorsi caudalis
E. META. UL.	Extensor metacarpi ulnaris	LAT. DOR. CRAN.	Latissimus dorsi cranialis
EXT. BREV. D. III.	Extensor brevis digiti III	LAT. DOR. MET.	Latissimus dorsi metapatagialis
EXT. BREV. D. IV	Extensor brevis digiti IV	OBT. LAT.	Obturatorius lateralis
EXT. DIG. L.	Extensor digitorum longus	OBT. MED.	Obturatorius medialis
EXT. HAL. L.	Extensor hallucis longus	PECT. SUB. ABD.	Pectoralis pars subcutanea abdominalis
F. CAR. UL.	Flexor carpi ulnaris	PECT. THO.	Pectoralis thoracica
F. DIG. L.	Flexor digitorum longus	PLAN.	Plantaris
F. DIG. MIN.	Flexor digiti minoris	PROPAT.	Propatagialis
F. DIG. PROF.	Flexor digitorum profundus	PUB.-IS.-FEM.	Pubo-ischio-femoralis
F. DIG. SUP.	Flexor digitorum superficialis	RHOM. PRO.	Rhomboideus profundus
FEM. TIB. EXT.	Femorotibialis externus	RHOM. SUP.	Rhomboideus superficialis
FEM. TIB. INT.	Femorotibialis internus	SCAP. HUM. CAUD.	Scapulohumeralis caudalis
FEM. TIB. MED.	Femorotibialis medius	SERR. PRO.	Serratus profundus
F. HAL. L.	Flexor hallucis longus	SERR. SUP. CAUD.	Serratus superficialis caudalis
FIB. BREV.	Fibularis brevis	SERR. SUP. CRAN.	Serratus superficialis cranialis
FIB. LONG.	Fibularis longus	STER. COR.	Sternocoracoideus
FL. CR. LAT.	Flexor cruris lateralis	STER. TRACH.	Sternotrachialis
FL. CR. MED.	Flexor cruris medialis	SUBCOR.	Subcoracoideus
FLEX. PER. D. II	Flexor perforatus digiti II	SUBSCP. (CAP. LAT.)	Subscapularis caput laterale
FLEX. PER. D. III	Flexor perforatus digiti III	SUBSCP. (CAP. MED.)	Subscapularis caput mediale
FLEX. PER. D. IV	Flexor perforatus digiti IV	SUP. COR.	Supracoracoideus
F. P. ET P. D. II	Flexor perforans et perforatus digiti II	SUPIN.	Supinator
F. P. ET P. D. III	Flexor perforans et perforatus digiti III	TIB. CRAN.	Tibialis cranialis
GAS.	Gastrocnemius	TRI. HUM.	Triceps humeralis
GAS. (P. INT.)	Gastrocnemius pars intermedia	TRI. SCAP.	Triceps scapularis
		UL. META. DOR.	Ulnimetacarpalis dorsalis

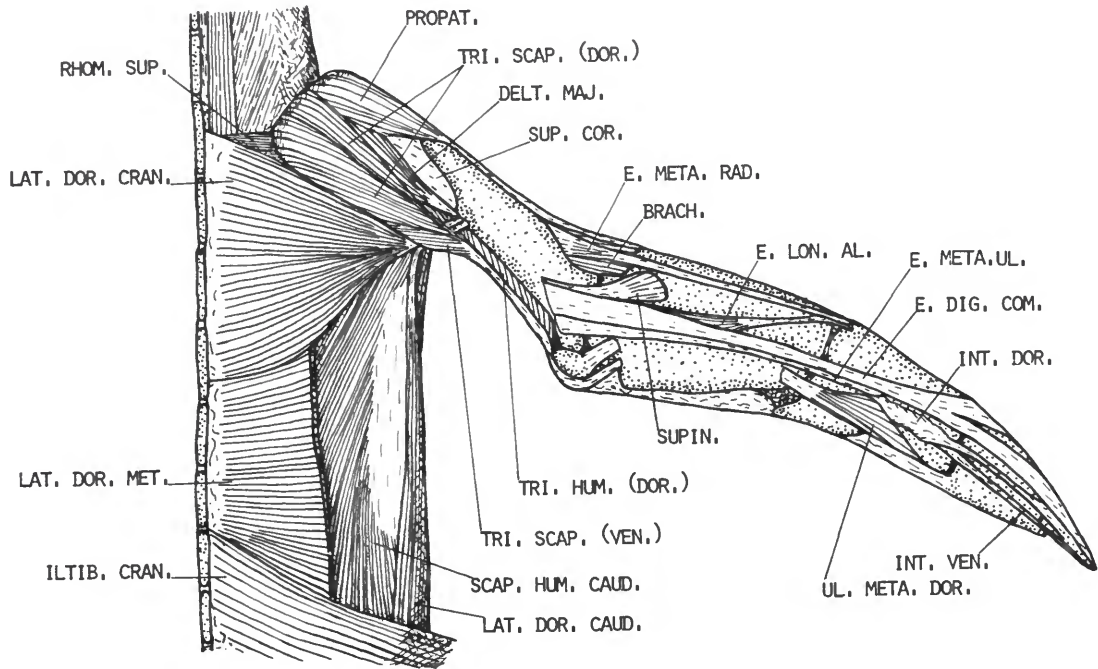


FIGURE 1.—*Eudyptes pachyrhynchus*, dorsal view of superficial muscles of the right wing.

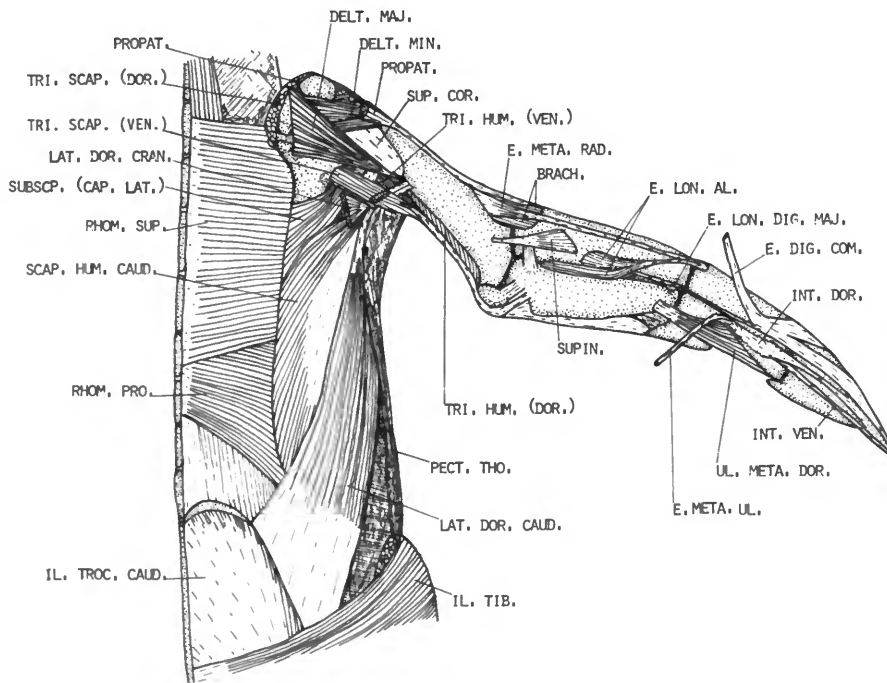


FIGURE 2.—*Eudyptes pachyrhynchus*, dorsal view of second layer of muscles of the right wing.

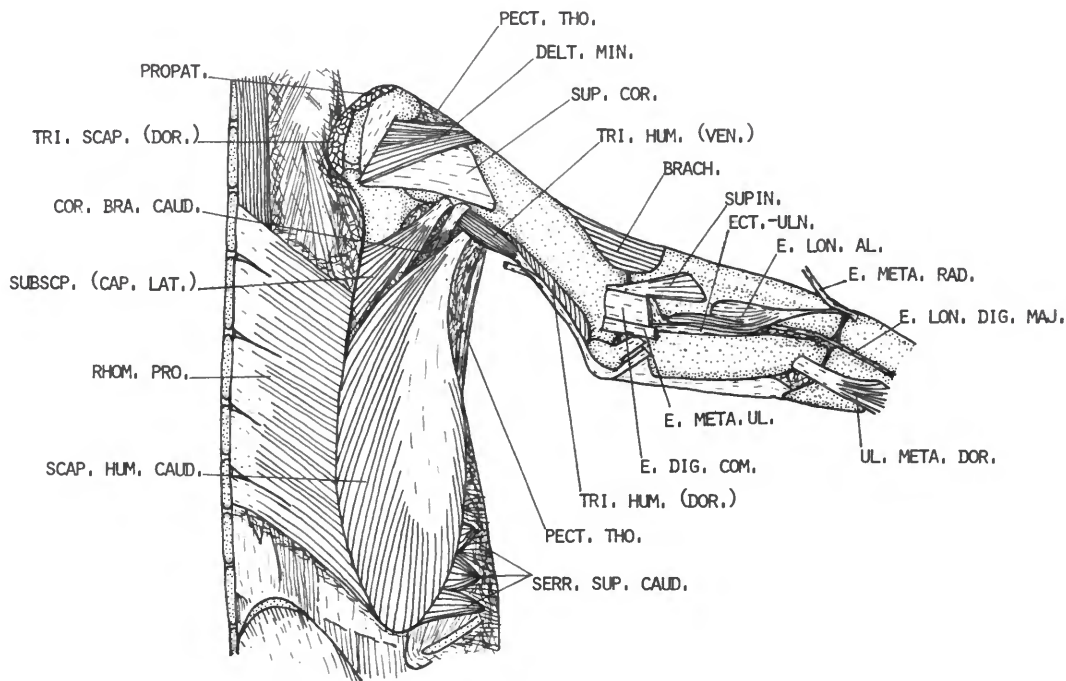


FIGURE 3.—*Eudyptes pachyrhynchus*, dorsal view of deepest muscles of the right wing.

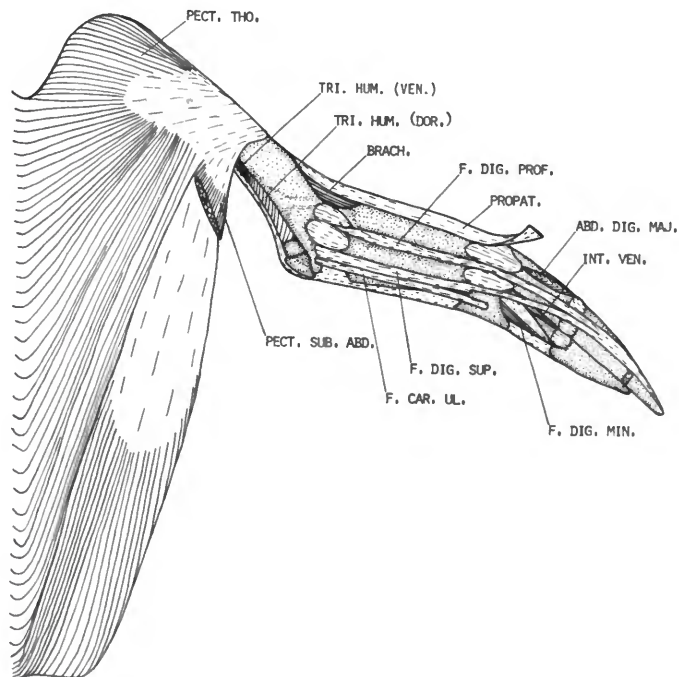


FIGURE 4.—*Eudyptes pachyrhynchus*, ventral view of superficial muscles of the left wing.

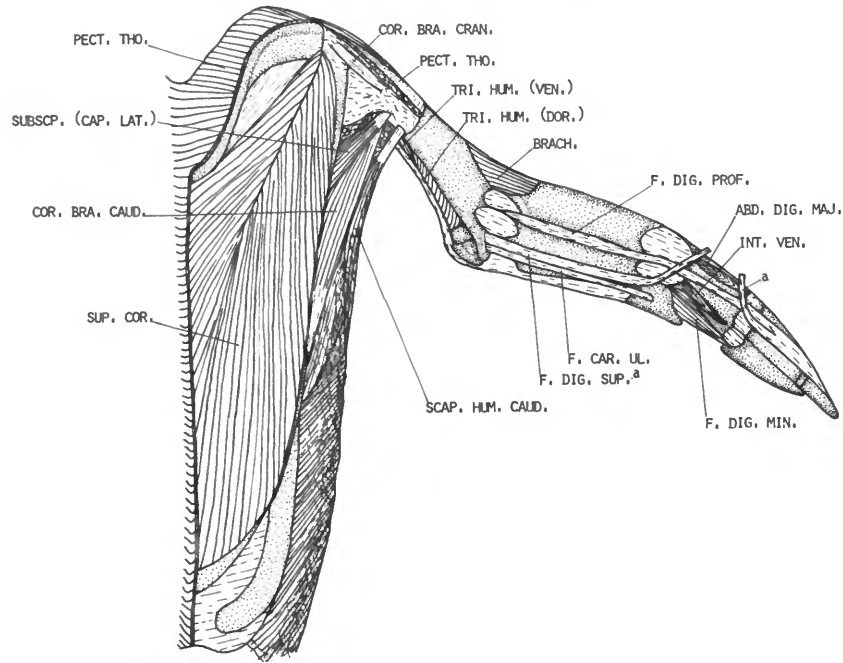


FIGURE 5.—*Eudyptes pachyrhynchus*, ventral view of second layer of muscles of the left wing.

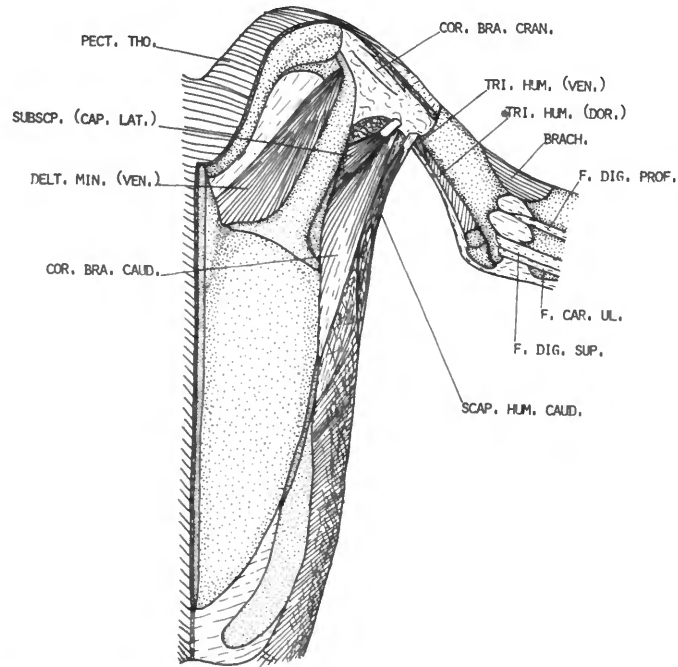


FIGURE 6.—*Eudyptes pachyrhynchus*, ventral view of deepest muscles of the thorax.

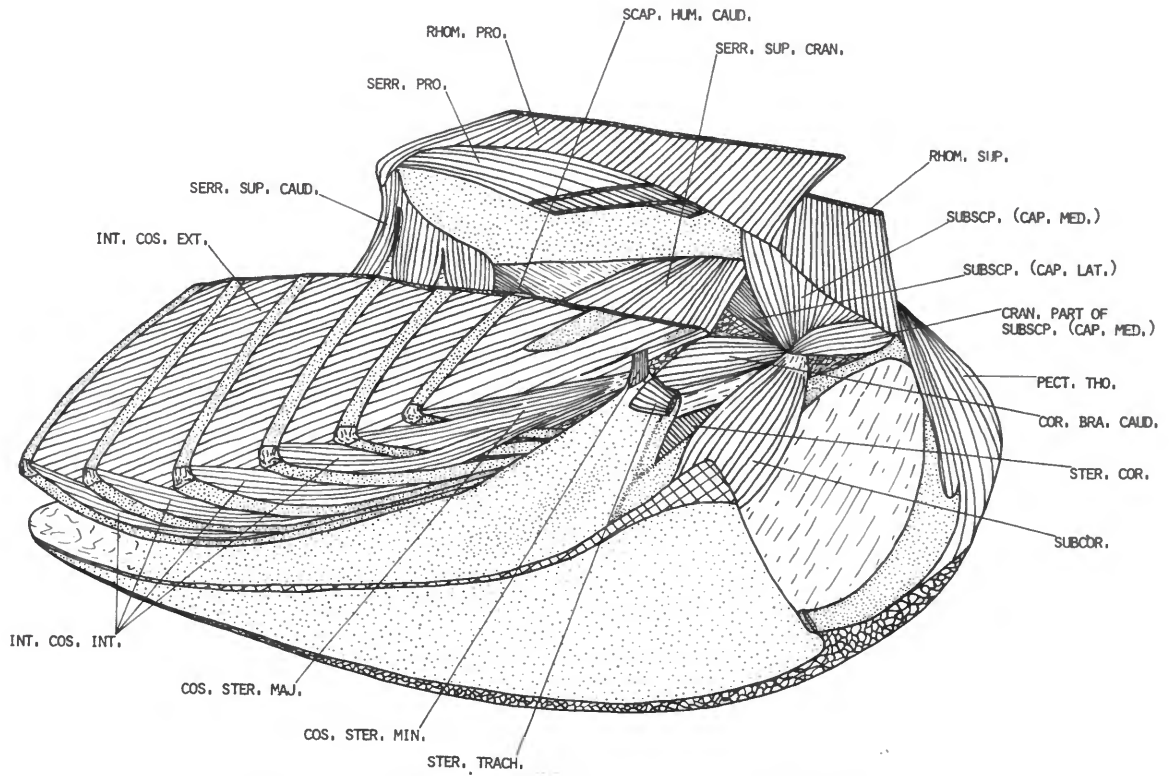


FIGURE 7.—*Eudiptes pachyrhynchus*, medial view of deep muscles of the thorax.

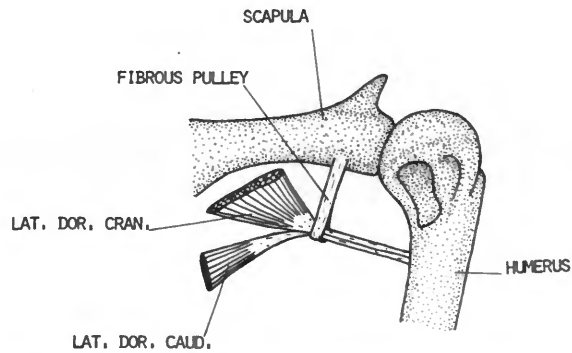


FIGURE 8.—*Eudiptes pachyrhynchus*, dorsal view of fibrous pulley and insertion of the latissimus dorsi cranialis and caudalis.

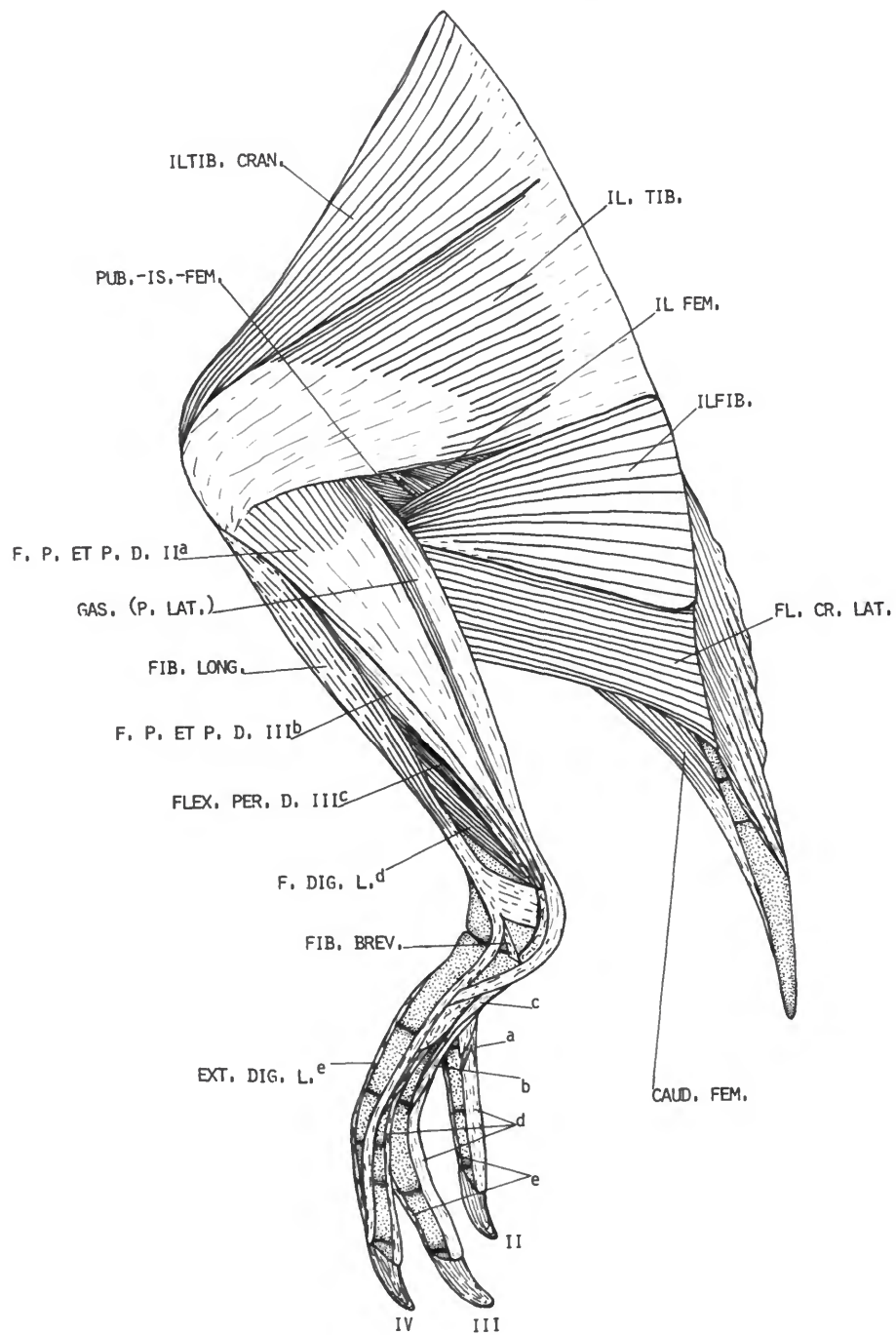


FIGURE 9.—*Eudyptes pachyrhynchus*, lateral view of superficial muscles of the left leg (caudal part of abdomen and most of tail muscles are not shown).

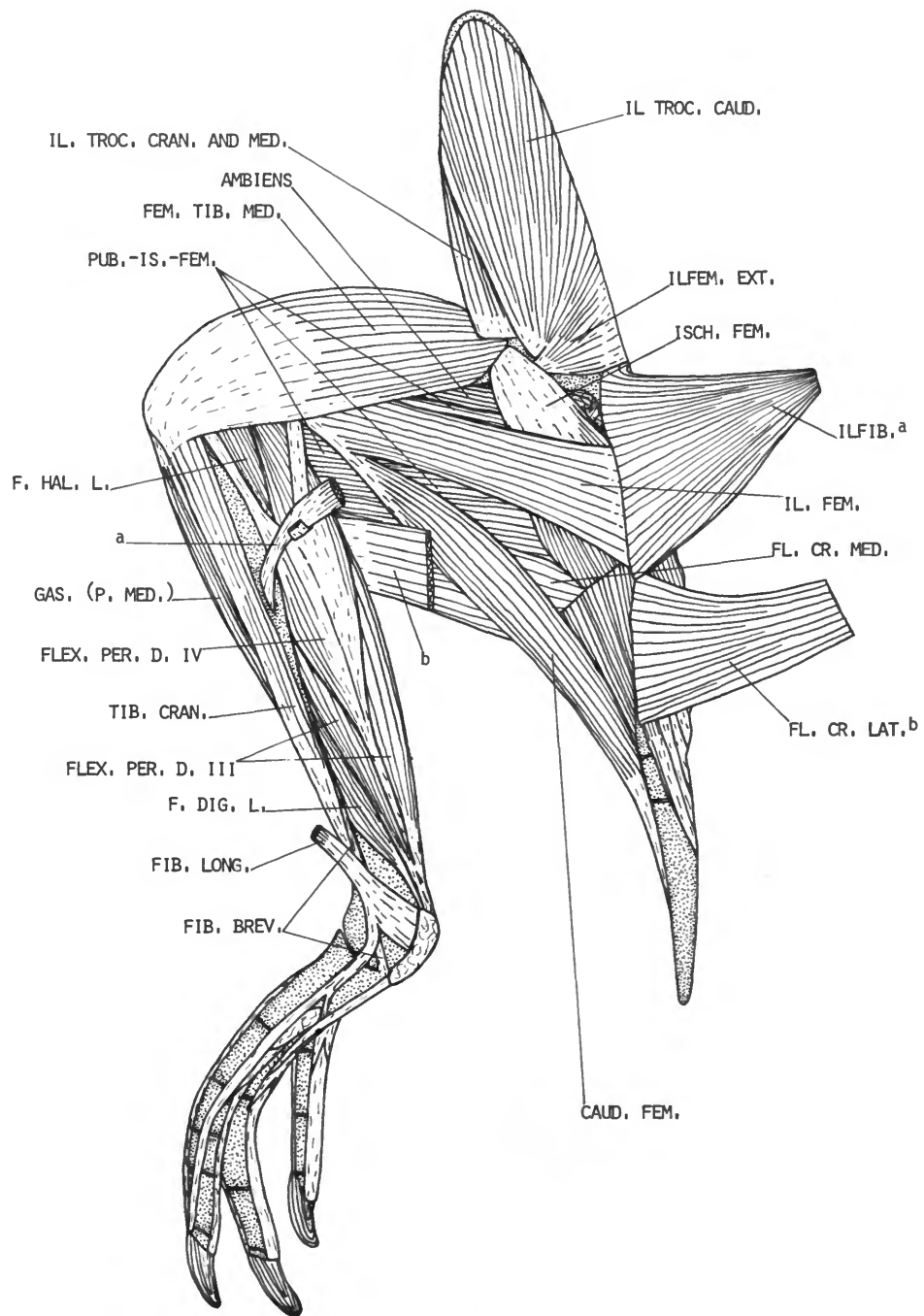


FIGURE 10.—*Eudyptes pachyrhynchus*, lateral view of a second layer of muscles of the left leg.

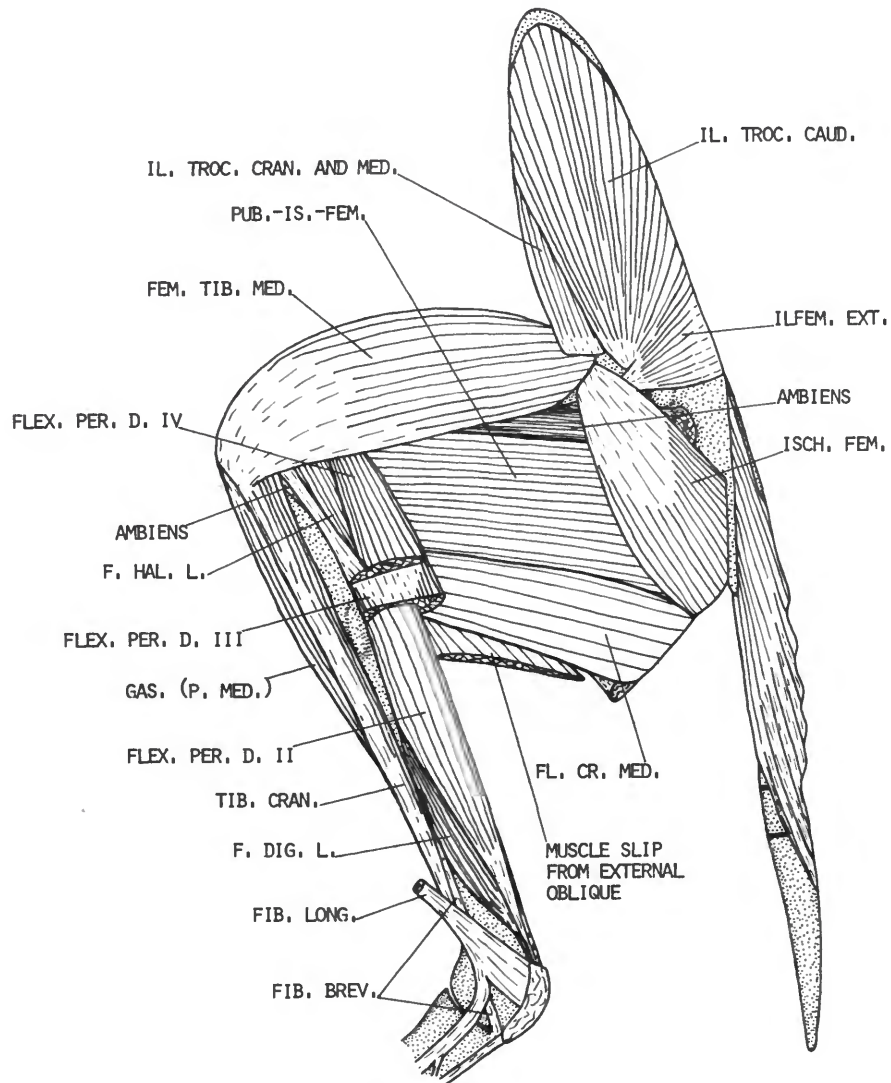


FIGURE 11.—*Eudyptes pachyrhynchus*, lateral view of a third layer of muscles of the left leg.

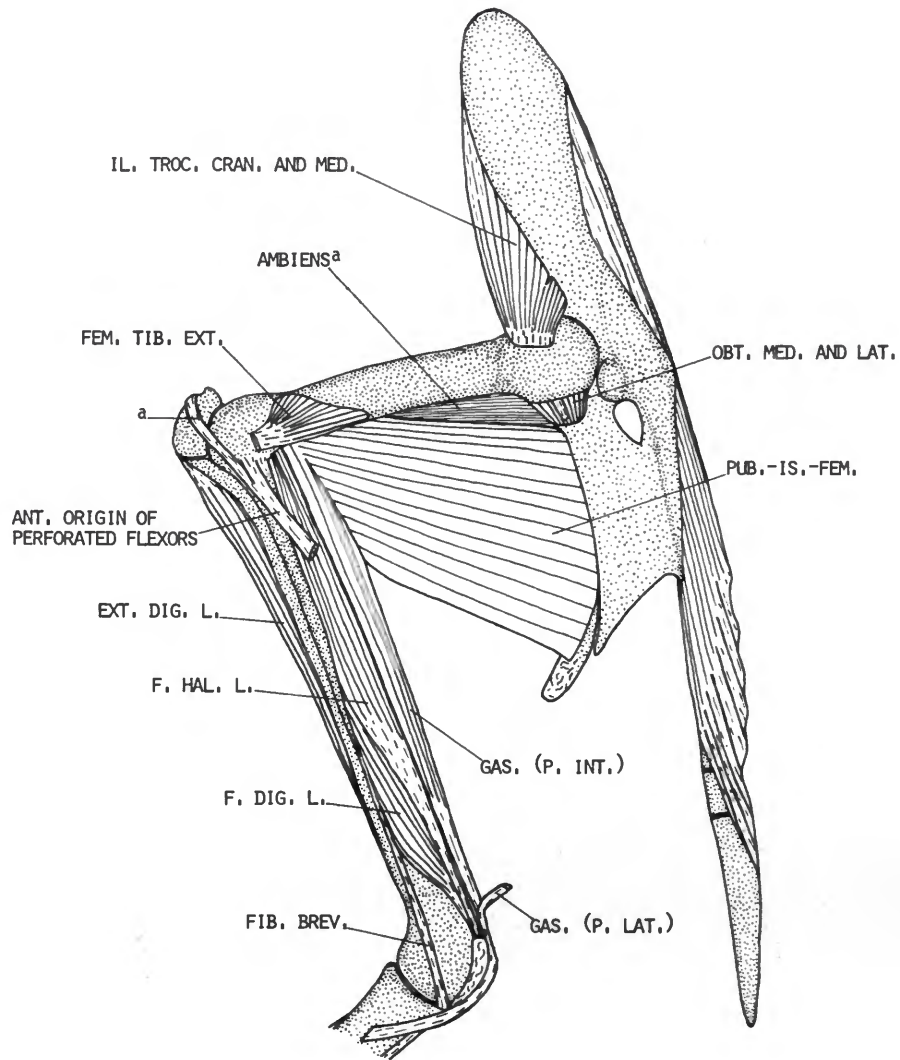


FIGURE 12.—*Eudytes pachyrhynchus*, lateral view of deepest muscles of the left leg.

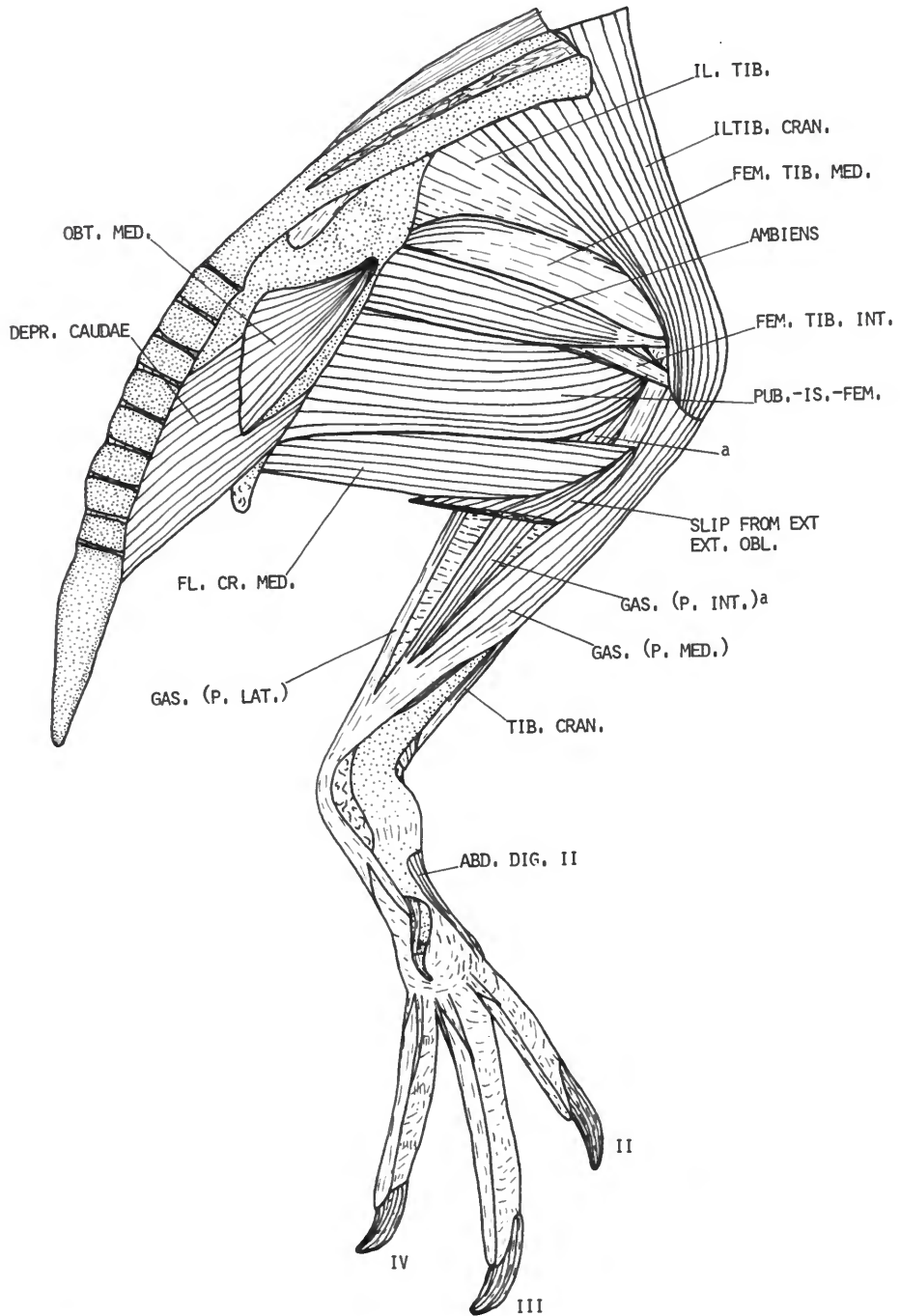


FIGURE 13.—*Eudyptes pachyrhynchus*, medial view of superficial muscles of the left leg.

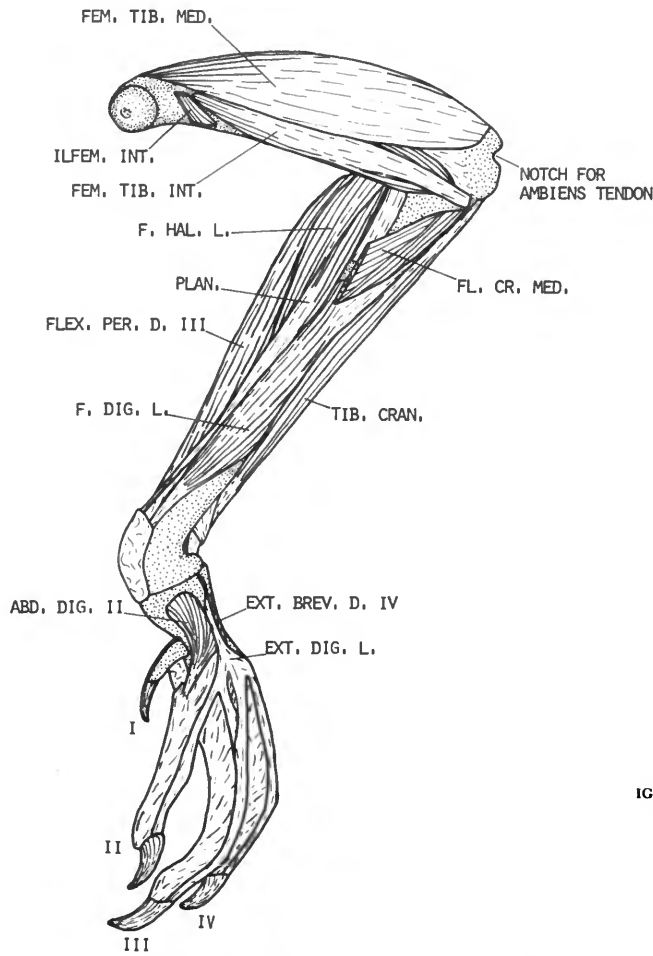


FIGURE 14.—*Eudyptes pachyrhynchus*, medial view of deeper muscles of the left leg.

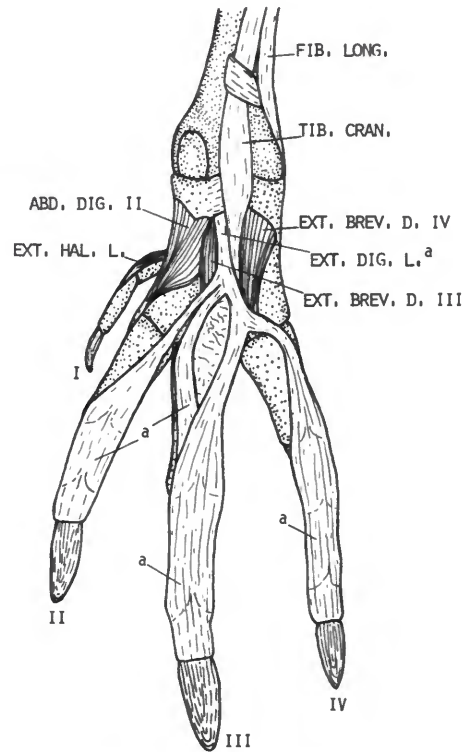


FIGURE 15.—*Eudyptes pachyrhynchus*, dorsal view of superficial muscles of the left foot.

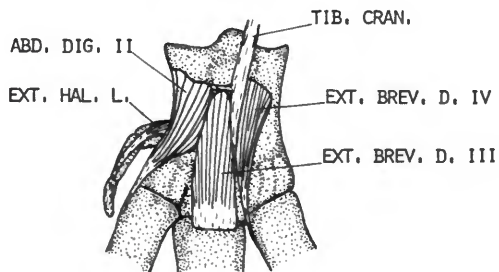


FIGURE 16.—*Eudyptes pachyrhynchus*, cranial view of deep muscles of the left tarsus.

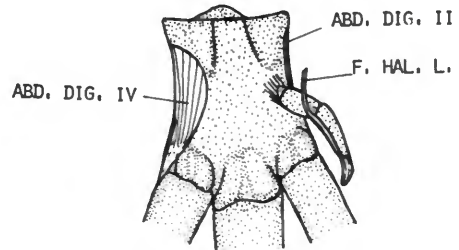


FIGURE 17.—*Eudyptes pachyrhynchus*, caudal view of tarsus showing short foot muscles.

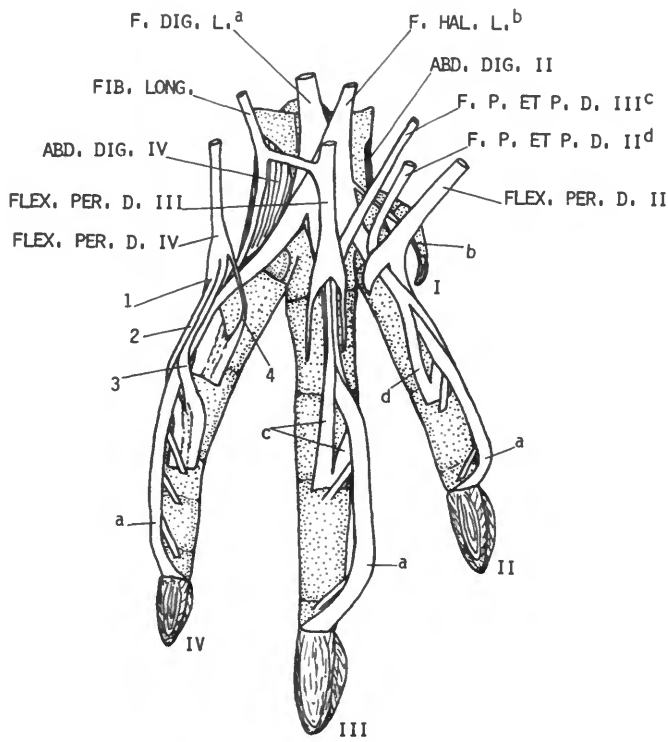


FIGURE 18.—*Eudyptes pachyrhynchus*, plantar view of left foot with most tendons displaced.

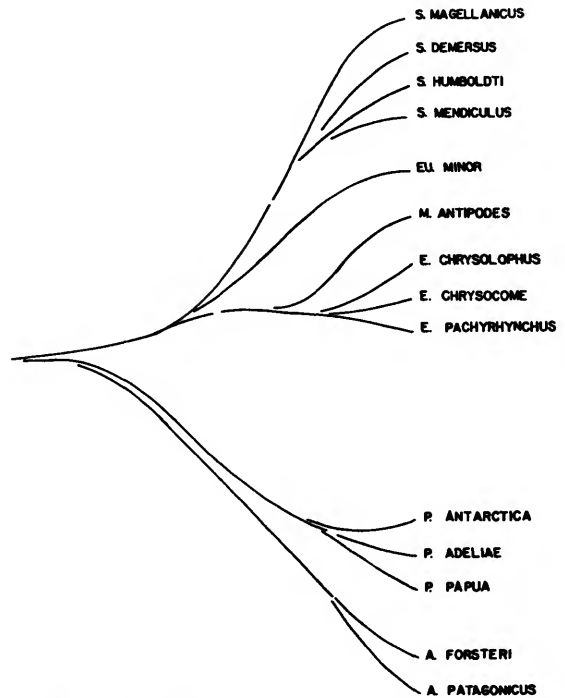


FIGURE 19.—Proposed phylogeny of the Spheniscidae (*Spheniscus*, *Eudyptula*, *Megadyptes*, *Eudyptes*, *Pygoscelis*, and *Aptenodytes*) based on total scores of difference between species and genera derived from numerical analysis.

Index to Muscles

(Pages of primary descriptions in italics.)

- Abductor alulae, 14, 29
Abductor digiti II, 25
Abductor digiti IV, 25
Abductor digiti majoris, 13, 26, 29
Adductor alulae, 14, 29
Adductor digiti II, 25, 27, 30
Adductor digiti IV, 25, 30
Ambiens, 16, 26, 30
Biceps brachii, 9, 26, 29
Biceps femoris, 16
Brachialis, 9, 11, 26, 29
Caudofemoralis, 17
Caudo-ilio-femoralis, 17, 27, 30
Coracobrachialis caudalis, 5, 6
Coracobrachialis cranialis, 6, 29
Deltoideus major, 6, 7, 8, 26, 29
Deltoideus minor, 6, 8, 26, 29
Ectepicondylo-ulnaris, 12, 29
Entepicondylo-ulnaris, 14, 29
Expansor secundariorum, 14, 26, 29
Extensor brevis alulae, 14, 29
Extensor brevis digiti III, 24
Extensor brevis digiti IV, 25, 30
Extensor digitorum communis, 11, 12, 13, 29
Extensor digitorum longus, 20, 30
Extensor hallucis longus, 24, 30
Extensor longus alulae, 11, 12, 26, 29
Extensor longus digiti majoris, 11, 12, 29
Extensor metacarpi radialis, 11, 12, 26, 29
Extensor metacarpi ulnaris, 12, 29
Extensor proprius digiti III, 25, 30
Femorotibialis externus, 16, 30
Femorotibialis internus, 16, 17, 30
Femorotibialis medius, 15, 17, 30
Fibularis brevis, 20, 30
Fibularis longus, 20, 22, 23, 30
Flexor alulae, 14, 29
Flexor carpi ulnaris, 10, 29
Flexor cruris lateralis, 18, 27, 30
Flexor cruris medialis, 18, 27, 30
Flexor digiti minoris (Flexor digiti III), 14, 26, 30
Flexor digitorum longus, 21, 22, 23, 24
Flexor digitorum profundus, 10
Flexor digitorum superficialis, 10, 29
Flexor hallucis brevis, 25, 27, 30
Flexor hallucis longus, 21, 23, 27, 30
Flexor perforans et perforatus digiti II, 21, 22, 30
Flexor perforans et perforatus digiti III, 21, 22, 23, 30
Flexor perforatus digiti II, 21, 22, 23
Flexor perforatus digiti III, 20, 21, 22, 23
Flexor perforatus digiti IV, 21, 22, 23, 30
Gastrocnemius, 18, 19, 21, 22, 30
Iliofemoralis, 17
Iliofemoralis externus, 14, 15, 26, 30
Iliofemoralis internus, 16, 17
Iliofibularis, 18, 22, 23, 27, 30
Iliotibialis, 16, 18, 26, 30
Iliotibialis cranialis, 16
Iliotrochantericus caudalis, 14, 15, 26
Iliotrochantericus cranialis, 15, 17, 19, 26, 30
Iliotrochantericus medius, 15, 16, 17, 19, 26
Interosseus dorsalis, 13, 30
Interosseus ventralis, 14, 26
Ischiofemoralis, 15, 18, 19, 30
Latissimus dorsi, 2, 8, 26
Latissimus dorsi caudalis, 2, 3, 8, 27, 29
Latissimus dorsi cranialis, 2, 3, 27, 29
Latissimus dorsi matapatagialis, 2, 3, 26, 29
Lumbricalis, 25, 27, 30
Obturatorius lateralis, 19, 30
Obturatorius medialis, 19, 30
Pectoralis, 5
Pectoralis pars subcutanea abdominalis, 5, 6, 29
Pectoralis propatagialis, 5
Pectoralis thoracica, 5, 6, 9, 26
Plantaris, 21
Popliteus, 24, 30
Pronator profundus, 14, 26, 29
Pronator superficialis, 14, 26, 29
Propatagialis, 5, 7, 8, 9, 10, 11, 26, 29
Pubo-ischio-femoralis, 19, 21, 30
Rhomboideus profundus, 3
Rhomboideus superficialis, 3, 4
Scapulohumeralis caudalis, 5
Scapulohumeralis cranialis, 14, 26, 29
Serratus profundus, 4
Serratus superficialis caudalis, 4, 5
Serratus superficialis cranialis, 4, 7, 29
Serratus superficialis matapatagialis, 14, 26, 29
Sternocoracoideus, 6
Subcoracoideus, 7, 29
Subscapularis, 7
Subscapularis caput laterale, 4, 7, 29
Subscapularis caput mediale, 4, 7

Supinator, 11, 29
Supracoracoideus, 5, 6, 26, 29
Tensor patagii longus, 7, 8
Tibialis cranialis, 19, 20, 21, 30
Triceps brachii, 8, 26

Triceps humeralis, 8, 9, 26, 29
Triceps scapularis, 3, 8, 9, 26, 29
Ulnimetacarpalis dorsalis, 13, 26, 29
Ulnimetacarpalis ventralis, 10, 29

REQUIREMENTS FOR SMITHSONIAN SERIES PUBLICATION

Manuscripts intended for series publication receive substantive review within their originating Smithsonian museums or offices and are submitted to the Smithsonian Institution Press with approval of the appropriate museum authority on Form SI-36. Requests for special treatment—use of color, foldouts, casebound covers, etc.—require, on the same form, the added approval of designated committees or museum directors.

Review of manuscripts and art by the Press for requirements of series format and style, completeness and clarity of copy, and arrangement of all material, as outlined below, will govern, within the judgment of the Press, acceptance or rejection of the manuscripts and art.

Copy must be typewritten, double-spaced, on one side of standard white bond paper, with 1 $\frac{1}{4}$ " margins, submitted as ribbon copy (not carbon or xerox), in loose sheets (not stapled or bound), and accompanied by original art. Minimum acceptable length is 30 pages.

Front matter (preceding the text) should include: **title page** with only title and author and no other information, **abstract page** with author/title/series/etc., following the established format, **table of contents** with indents reflecting the heads and structure of the paper.

First page of text should carry the title and author at the top of the page and an unnumbered footnote at the bottom consisting of author's name and professional mailing address.

Center heads of whatever level should be typed with initial caps of major words, with extra space above and below the head, but with no other preparation (such as all caps or underline). Run-in paragraph heads should use period/dashes or colons as necessary.

Tabulations within text (lists of data, often in parallel columns) can be typed on the text page where they occur, but they should not contain rules or formal, numbered table heads.

Formal tables (numbered, with table heads, boxheads, stubs, rules) should be submitted as camera copy, but the author must contact the series section of the Press for editorial attention and preparation assistance before final typing of this matter.

Taxonomic keys in natural history papers should use the aligned-couplet form in the zoology and paleobiology series and the multi-level indent form in the botany series. If cross-referencing is required between key and text, do not include page references within the key, but number the keyed-out taxa with their corresponding heads in the text.

Synonymy in the zoology and paleobiology series must use the short form (taxon, author, year:page), with a full reference at the end of the paper under "Literature Cited." For the botany series, the long form (taxon, author, abbreviated journal or book title, volume, page, year, with no reference in the "Literature Cited") is optional.

Footnotes, when few in number, whether annotative or bibliographic, should be typed at the bottom of the text page on which the reference occurs. Extensive notes must appear at the end of the text in a notes section. If bibliographic footnotes are required, use the short form (author/brief title/page) with the full reference in the bibliography.

Text-reference system (author/year/page within the text, with the full reference in a "Literature Cited" at the end of the text) must be used in place of bibliographic footnotes in all scientific series and is strongly recommended in the history and technology series: "(Jones, 1910:122)" or ". . . Jones (1910:122)."

Bibliography, depending upon use, is termed "References," "Selected References," or "Literature Cited." Spell out book, journal, and article titles, using initial caps in all major words. For capitalization of titles in foreign languages, follow the national practice of each language. Underline (for italics) book and journal titles. Use the colon-parentheses system for volume/number/page citations: "10(2):5-9." For alinement and arrangement of elements, follow the format of the series for which the manuscript is intended.

Legends for illustrations must not be attached to the art nor included within the text but must be submitted at the end of the manuscript—with as many legends typed, double-spaced, to a page as convenient.

Illustrations must not be included within the manuscript but must be submitted separately as original art (not copies). All illustrations (photographs, line drawings, maps, etc.) can be intermixed throughout the printed text. They should be termed **Figures** and should be numbered consecutively. If several "figures" are treated as components of a single larger figure, they should be designated by lowercase italic letters (underlined in copy) on the illustration, in the legend, and in text references: "Figure 9 \underline{b} ." If illustrations are intended to be printed separately on coated stock following the text, they should be termed **Plates** and any components should be lettered as in figures: "Plate 9 \underline{b} ." Keys to any symbols within an illustration should appear on the art and not in the legend.

A few points of style: (1) Do not use periods after such abbreviations as "mm, ft, yds, USNM, NNE, AM, BC." (2) Use hyphens in spelled-out fractions: "two-thirds." (3) Spell out numbers "one" through "nine" in expository text, but use numerals in all other cases if possible. (4) Use the metric system of measurement, where possible, instead of the English system. (5) Use the decimal system, where possible, in place of fractions. (6) Use day/month/year sequence for dates: "9 April 1976." (7) For months in tabular listings or data sections, use three-letter abbreviations with no periods: "Jan, Mar, Jun," etc.

Arrange and paginate sequentially EVERY sheet of manuscript—including ALL front matter and ALL legends, etc., at the back of the text—in the following order: (1) title page, (2) abstract, (3) table of contents, (4) foreword and/or preface, (5) text, (6) appendixes, (7) notes, (8) glossary, (9) bibliography, (10) index, (11) legends.

