

Myology of the Purple-throated
Carib (*Eulampis jugularis*)
and Other Hummingbirds
(Aves: Trochilidae)

RICHARD L. ZUSI
and
GREGORY DEAN BENTZ

SERIES PUBLICATIONS OF THE SMITHSONIAN INSTITUTION

Emphasis upon publication as a means of “diffusing knowledge” was expressed by the first Secretary of the Smithsonian. In his formal plan for the Institution, Joseph Henry outlined a program that included the following statement: “It is proposed to publish a series of reports, giving an account of the new discoveries in science, and of the changes made from year to year in all branches of knowledge.” This theme of basic research has been adhered to through the years by thousands of titles issued in series publications under the Smithsonian imprint, commencing with *Smithsonian Contributions to Knowledge* in 1848 and continuing with the following active series:

Smithsonian Contributions to Anthropology
Smithsonian Contributions to Astrophysics
Smithsonian Contributions to Botany
Smithsonian Contributions to the Earth Sciences
Smithsonian Contributions to Paleobiology
Smithsonian Contributions to Zoology
Smithsonian Studies in Air and Space
Smithsonian Studies in History and Technology

In these series, the Institution publishes small papers and full-scale monographs that report the research and collections of its various museums and bureaux or of professional colleagues in the world of science and scholarship. The publications are distributed by mailing lists to libraries, universities, and similar institutions throughout the world.

Papers or monographs submitted for series publication are received by the Smithsonian Institution Press, subject to its own review for format and style, only through departments of the various Smithsonian museums or bureaux, where the manuscripts are given substantive review. Press requirements for manuscript and art preparation are outlined on the inside back cover.

S. Dillon Ripley
Secretary
Smithsonian Institution

SMITHSONIAN CONTRIBUTIONS TO ZOOLOGY • NUMBER 385

Myology of the Purple-throated Carib
(*Eulampis jugularis*) and Other
Hummingbirds (Aves: Trochilidae)

Richard L. Zusi
and *Gregory Dean Bentz*



SMITHSONIAN INSTITUTION PRESS

City of Washington

1984

ABSTRACT

Zusi, Richard L., and Gregory Dean Bentz. Myology of the Purple-throated Carib (*Eulampis jugularis*) and Other Hummingbirds (Aves: Trochilidae). *Smithsonian Contributions to Zoology*, number 385, 70 pages, 20 figures, 1984.— All muscles of the axial and appendicular skeleton of *Eulampis jugularis* are described and illustrated, and comparisons are made with the Rufous-breasted Hermit (*Glaucis hirsuta*), the Fork-tailed Woodnymph (*Thalurania furcata*), the Velvet-browed Brilliant (*Heliodoxa xanthogonys*), the Giant Hummingbird (*Patagona gigas*), the Tyrian Metaltail (*Metallura tyrianthina*), and the Bahama Woodstar (*Calliphlox evelynae*). These species were chosen to include the major taxonomic subdivisions within the Trochilidae. Although species with remarkable structural modifications of the bill, wings, and tail are excluded from this study, myological variation within the hummingbirds studied nevertheless suggests considerable potential for future studies of systematics and adaptation within the Trochilidae. Unusual features in hummingbirds are identified and compared with oscines (Passeriformes), swifts, and various other birds for future use in phylogenetic studies on the familial and ordinal levels. Hummingbirds are shown to lack 19 muscles or distinct parts of muscles found in some members of the Passeriformes.

OFFICIAL PUBLICATION DATE is handstamped in a limited number of initial copies and is recorded in the Institution's annual report, *Smithsonian Year*. SERIES COVER DESIGN: The coral *Montastrea cavernosa* (Linnaeus).

Library of Congress Cataloging in Publication Data

Zusi, Richard L. (Richard Laurence), 1930-

Myology of the purple-throated Carib (*Eulampis jugularis*) and other hummingbirds (Aves: Trochilidae)

(Smithsonian contributions to zoology ; no. 385)

Bibliography: p.

Includes index.

1. Purple-throated carib—Anatomy. 2. Hummingbirds—Anatomy. 3. Muscles. 4. Birds—Anatomy. I. Bentz, Gregory Dean. II. Title. III. Series.

QL1.S54 no. 385 598.8'99 83-14794 [QL696.A558]

Contents

	<i>Page</i>
Introduction	1
Methods	2
Terminology	2
Acknowledgments	2
Muscles of the Eye	3
Muscles of the Jaws	4
Muscles of the Tongue and Hyoid Apparatus	8
Muscles of the Vertebral Column	11
Muscles of the Trunk and Abdomen	18
Muscles of the Tail	21
Muscles of the Forelimb	23
Muscles of the Hindlimb	33
Subcutaneous Muscles	40
Discussion	41
Systematic Studies within the Trochilidae	41
Phylogenetic Relationships of the Trochilidae	41
Muscles Absent in Hummingbirds	44
Adaptations	44
Literature Cited	45
Appendix 1: Index to Muscle Abbreviations	47
Appendix 2: Index to Abbreviations, Excluding Muscles	50
Figures 1–20	52
Index to Main Muscle Headings	69

Myology of the Purple-throated Carib (*Eulampis jugularis*) and Other Hummingbirds (Aves: Trochilidae)

Richard L. Zusi
and *Gregory Dean Bentz*

Introduction

Comparative studies of avian myology in recent decades have dealt typically with muscles of the appendages or jaws within an order or family. The purpose of these broad studies has been either descriptive or systematic and authors have not felt compelled to study the complete myology of their subjects, perhaps because the task would be monumental for large and varied taxonomic groups. For systematic studies it has been stated or implied that, if the problem can be "solved" using only a portion of the bird, there is no need to include the remainder. As a result the literature of avian myology contains a mosaic of data with numerous information gaps; for any given family or order we are likely to find comparative studies of jaw muscles, hindlimb muscles, or forelimb muscles, but rarely all three, and in no case comparisons of all skeletal muscles.

This paper presents the description of all muscles that attach on the axial and appendicular skeletal systems in the Purple-throated Carib (*Eulampis jugularis*, Trochilidae). Striated muscles intrinsic to other systems (respiratory system,

sense organs) are not included except for two eye muscles. Broad comparisons throughout the Trochilidae have not been attempted here but six other species of six genera are compared with *Eulampis* to determine major variation within the family. These genera (*Glaucis*, *Thalurania*, *Heliodoxa*, *Patagona*, *Metallura*, and *Calliphlox*) were chosen to include representatives of the main suprageneric divisions of the Trochilidae as determined by Zusi (in preparation). Thus our data can be used to represent the Trochilidae in comparisons with other families.

The purposes of this paper are several. One is simply to put the myological data on record. The literature on hummingbird myology is incomplete and of mixed quality. Some aspects of myology were studied long ago and are not readily accessible (wing: Buri, 1900; tongue and jaws: Moller, 1931). Other more recent studies are partially in error (tongue: Weymouth et al., 1964) or essentially accurate but incomplete for the portion of the bird treated (neck: Burton, 1971; wing: Fürbringer, 1888; Cohn, 1968). We are not aware of any complete studies on the neck, trunk, tail, or hind limb muscles of a hummingbird.

Another purpose is to serve as a guide for future studies on myology and systematics of hummingbirds. Until recently there has been no comparative myological work done within the Trochilidae,

Richard L. Zusi, Department of Vertebrate Zoology, National Museum of Natural History, Smithsonian Institution, Washington, D.C. 20560. Gregory Dean Bentz, Mount Vernon College, Washington, D.C. 20007.

and its potential for solving systematic problems within the family has been completely unknown. In addition, the broader question of the phylogenetic relationships of the Trochilidae with other families is still open. A paper by Zusi and Bentz (1982) and the present paper suggest that comparative myology has considerable potential for systematic studies at various taxonomic levels. In discussing relationships of the Trochilidae, previous authors have sometimes come to opposite conclusions from similar data. This is partly for lack of adequate data both for hummingbirds and for other families. The future looks more promising because a comparative myological base for many land bird families is presently emerging from the work of various authors. This base consists largely of appendicular and jaw myology, with which the present descriptions may be compared.

Hummingbirds present a particularly difficult phylogenetic problem because their locomotor and feeding systems are highly modified for hovering flight, perching and clinging, and lapping nectar. These modifications affect virtually all portions of the bird; thus hummingbirds are either unique or highly unusual among birds in many of their structural attributes. For example, Cohn (1968) argued that those features of wing myology and osteology in which hummingbirds resemble only swifts are probably the result of convergence from one common aspect of their flight—a highly developed powered upstroke of the wing. For these reasons we feel that myological clues to the phylogeny of hummingbirds will be difficult to recognize and that data other than the available jaw, tongue, and wing myologies might be needed.

The above comments lead to the third objective of this paper. We hope that a demonstration of myological variation within hummingbirds and the identification of those features that are unique or unusual among birds will stimulate the study of functional anatomy and adaptations within the Trochilidae.

METHODS.—Spirit specimens from the collections of the National Museum of Natural History, Smithsonian Institution, were dissected under

magnifications of $\times 6$, $\times 12.5$, or $\times 25$. Muscles were routinely stained with an aqueous solution of potassium iodide and iodine (Bock and Shear, 1972). Without this stain we probably would not have found or correctly described certain muscles. Zusi made detailed pencil drawings for the figures with the aid of a camera lucida.

The species and numbers of specimens dissected are: Purple-throated Carib (*Eulampis jugularis*), 7; Rufous-breasted Hermit (*Glaucis hirsuta*), 3; Giant Hummingbird (*Patagona gigas*), 1; Fork-tailed Woodnymph (*Thalurania furcata*), 2; Violet-browed Brilliant (*Heliodoxa xanthogonys*), 2; Tryrian Metaltail (*Metallura tyrianthina*), 2; and Bahama Woodstar (*Calliphlox evelynae*), 1. In addition we checked certain points in the Magnificent Hummingbird (*Eugenes fulgens*).

TERMINOLOGY.—We have followed the “Nomina Anatomica Avium” (Baumel et al., 1979) for terminology of muscles and have usually employed anglicized versions of NAA Latin names for other anatomical structures. The NAA name follows our first use of an anglicized name whenever possible. Certain departures from NAA terminology are explained in the appropriate sections.

Directional terms apply to a bird that is standing with the head and neck stretched forward and the wings fully extended to the side. The terms “cranial” and “caudal” are used throughout except for the skull and hyoid apparatus, in which “rostral” replaces “cranial,” and for the eye, in which “anterior” and “posterior” are used. We depart from NAA usage with reference to the tarsometatarsus, using “caudal” rather than “ventral” for the plantar surface, and “cranial” rather than “dorsal” for the opposite surface.

Most abbreviations in figures refer to muscles, and we have omitted “M.” (for “musculus”) to save space. These abbreviations are identified in Appendix 1. Abbreviations for other anatomical features are italicized in the figures and are identified in Appendix 2.

ACKNOWLEDGMENTS.—This project was begun during Bentz’s tenure as a Smithsonian Postdoctoral Fellow. Partial financial support was received from Smithsonian Research Award Sg

3372400 to Zusi, and from Mount Vernon College to Bentz. We acknowledge David Steadman for obtaining some of the spirit specimens used in this study. Zusi's pencil drawings were rendered in ink by Carolyn Cox Lyons (Figures 1*a,b*, 2-4, 6-9, 17*c*), Ellen Paige (Figures 1*c*, 15, 19), and Irene Jewett (the remainder). All illustrations were labelled by Ellen Paige.

Muscles of the Eye

Three muscles of the eyelids (*M. levator palpebrae dorsalis*, *M. depressor palpebrae ventralis*, *M. tensor periorbitae*) that attach on the cranium are omitted here because we were unable to obtain an accurate description by gross dissection. However, we include the two intrinsic muscles of the eye associated with the nictitating membrane (*membrana nictitans*) and mentioned in descriptions of the extrinsic muscles.

M. RECTUS MEDIALIS (R M)

FIGURE 1*a-c*

This muscle arises mainly fleshy from a depression in the interorbital septum (*septum interorbitale*) just anterior to the optic foramen (*foramen opticum*) and ventral to the floor of the orbital fonticulus (*fonticulus orbitale*). The muscle broadens to a strap and passes anteriorly around the medial surface of the eye to insert by a flat aponeurosis on the sclera near the anterior limit of the eye.

M. OBLIQUUS DORSALIS (O D)

FIGURE 1*a-c*

The origin of this muscle is from a depression in the posterior wall of the ectethmoid plate (*os ectethmoidale*) posteromedial to the foramen of the olfactory nerve (*foramen orbitonasale mediale*) and ventral to the groove of that nerve (*sulcus olfactorius*). It is deep to *M. rectus medialis*. The muscle flattens, passes between two rami of the olfactory nerve (*nervus olfactorius*), and flares out as it continues dorsolaterally over the eye to insert by a broad, flat aponeurosis near the dorsal limit

of the eye, just medial to the attachment of *M. rectus dorsalis* and lateral to the fleshy attachment of *M. quadratus membranae nictitantis*.

M. OBLIQUUS VENTRALIS (O V)

FIGURE 1*a-c*

This muscle is the ventral counterpart of *M. obliquus dorsalis*. Its origin is adjacent and ventral to that of *dorsalis*. The muscle flares out and passes posteroventrolaterally around the eye to insert on the sclera by a broad, flat aponeurosis just lateral to the attachment of *M. rectus ventralis*.

M. RECTUS DORSALIS (R D)

FIGURE 1*a-c*

This is a broad, strap-like muscle that lies on the dorsomedial surface of the eye. It originates by an aponeurosis from a narrow depression on the posteroventral bony rim of the optic foramen. The aponeurosis curves anterodorsally around the optic nerve (*nervus opticus*) and quickly fans out and gives rise to the fleshy belly. Insertion is by a broad aponeurosis on the sclera near the dorsal limit of the eye and lateral to the attachment of *M. obliquus dorsalis*.

M. RECTUS VENTRALIS (R V)

FIGURE 1*a-c*

This is the ventral counterpart of *rectus dorsalis* and its aponeurotic origin is continuous with that of *dorsalis*. It passes anteroventrally around the optic nerve and fans out to give rise to the fleshy belly. Insertion is by a broad aponeurosis on the sclera medial to the attachment of *M. obliquus ventralis* and lateral to the fleshy attachment of *M. pyramidalis membranae nictitantis*.

M. RECTUS LATERALIS (R L)

FIGURE 1*a-c*

This muscle lies on the caudal surface of the eye. It originates mainly fleshy from a depression

posterolateral to the origins of rectus dorsalis and lateralis, and between the ventral rim of the orbital fonticulus and the dorsal edge of *M. protractor pterygoidei et quadrati*. The belly passes laterally around the eye and inserts by a flat aponeurosis on the sclera near the posterior limit of the eye.

M. QUADRATUS MEMBRANAE NICTITANTIS (Q M N)

FIGURE 1c

This broad, flat, fan-shaped muscle lies on the posterodorsomedial surface of the eye from the optic nerve dorsally almost to the dorsal limit of the eye. It has a curved, linear origin that extends posteriorly toward the insertion of *M. rectus lateralis*, dorsally to the insertion of *M. obliquus dorsalis*, and anteriorly toward *M. rectus medialis*. The fibers pass ventrally and converge on a tendinous tube that curves around the dorsal half of the optic nerve. This tube transmits the tendon of *M. pyramidalis membranae nictitantis*.

M. PYRAMIDALIS MEMBRANAE NICTITANTIS (P M N)

FIGURE 1c

This is a narrow, fan-shaped muscle that originates ventrally on the eye just medial to the insertion of *M. rectus ventralis*. Its fibers converge on a narrow tendon that enters the tendinous tube of *M. quadratus membranae nictitantis* anterior to the optic nerve and passes through the tube to emerge on the posterior side of the optic nerve. The tendon then continues ventrolaterally along the surface of the eye where it passes through a tendinous loop on the sclera before continuing to the anterolateral side of the eye. It attaches on the rostral edge of the nictitating membrane.

Muscles of the Jaws

The only description of the jaw muscles in hummingbirds is that of Moller (1931) for the Green-throated Carib (*Sericotes holosericeus*). His

accounts are brief and the illustrations lack detail. An important difference between his interpretation and ours is his recognition of adductor mandibulae externus caudalis as well as adductor mandibulae caudalis in hummingbirds. The former muscle is present in oscine Passeriformes (Beecher, 1953; Fiedler, 1951; Richards and Bock, 1973) but absent in swifts (Apodidae) according to Morioka (1974), and the interpretation of the situation in hummingbirds may therefore have systematic significance. We found that, as in swifts, the adductor mandibulae caudalis was well developed and adductor mandibulae externus caudalis absent. Moller's description of the pterygoideus complex is incomplete and not useful for comparisons.

Fiedler's comments on the jaw muscles of hummingbirds in comparison with those of oscines and other groups are drawn exclusively from Moller's descriptions.

Terminology of the parts of the palatine bone and subdivisions of certain jaw muscles follows that of Richards and Bock (1973).

M. ADDUCTOR MANDIBULAE EXTERNUS (A M E)

FIGURES 2a-c, 3b,c

In hummingbirds this muscle consists of two large and well-defined bellies—pars rostralis and pars ventralis. Pars rostralis can be further subdivided into temporal, medial, and lateral portions. Pars caudalis of *M. adductor mandibulae externus*, present in many other birds, is apparently absent in hummingbirds.

PARS ROSTRALIS (A M E R).—*Pars rostralis temporalis* (A M E R T): This is a large, superficial muscle that occupies the temporal fossa (fossa temporalis) of the cranium. It originates fleshy from the entire fossa and from the lateral and dorsal surfaces of the zygomatic process (processus zygomaticus). Some fibers of rostralis temporalis originate from a superficial aponeurosis that attaches along the dorsal edge of the temporal fossa.

Insertion is by a tendon that begins as a broad sheet that is parallel to the surface of the cranium. It has a thickened "midrib" that is continuous

with the main tendon of insertion. In its rostral portion this sheet curves medially into the orbit (orbita) to receive fibers from pars medialis. Fibers from the temporal fossa insert on the medial surface of the broad sheet; those from the superficial aponeurosis on its lateral surface. The superficial fibers have a weakly pennate arrangement where they meet at the midrib, but most assume a fan-like arrangement as they converge onto the aponeurosis. The aponeurosis emerges from the belly of temporalis and is briefly superficial as it passes rostroventrally toward its insertion. The aponeurosis narrows to form a stout tendon that is covered laterally by rostralis lateralis before passing deep to pars ventralis and attaching on the coronoid process (processus coronioideus) of the mandible (mandibula).

Pars rostralis lateralis (A M E R L): In hummingbirds this is sometimes identifiable as a separate belly but it amounts to little more than a rostral development of the ventral portion of pars temporalis. Fibers arise from the rostradorsal rim of the ear opening (meatus acusticus externus) and from the lateral surface of the zygomatic process and insert on the ventral and ventrolateral surfaces of the main tendon of insertion of pars rostralis just above the point where it is crossed by pars ventralis.

Pars rostralis medialis (A M E R M): This portion is continuous with rostralis temporalis. Fibers arise in the orbit between *M. pseudotemporalis superficialis* and the postorbital process, and from the dorsal and medial surfaces of the postorbital process (processus postorbitalis). They insert on both surfaces of the orbital extension of the aponeurotic sheet described under rostralis temporalis. The orbital aponeurosis passes rostroventrally as a medial extension of the main tendon of rostralis, narrowing and disappearing as that tendon approaches the coronoid process of the mandible.

PARS VENTRALIS (A M E V).—This major portion of the adductor mandibulae externus arises by a strong aponeurosis from the ventral edge and tip of the zygomatic process. The aponeurosis passes rostroventrally, crosses the lateral surface

of the main tendon of rostralis, and continues forward to fan out along the lateral surface of the mandibular ramus (ramus mandibulae). From its medial, ventrolateral, and rostrrolateral surfaces fibers pass to their insertion on the lateral surface of the mandible from the lateral jugomandibular ligament (ligamentum jugomandibulare laterale) forward under the orbit and ectethmoid. The jugal bar lies immediately lateral to this muscle.

The caudal, deep fibers of this muscle from the medial surface of the zygomatic process insert on a thin aponeurotic sheet that attaches along the dorsal edge of the mandibular ramus just caudal to the tendon of insertion of pars rostralis. A few fibers also attach deep to that tendon. This caudal and deep portion of the muscle lies adjacent and lateral to the rostral portion of *M. adductor mandibulae caudalis*.

Pars caudalis of *M. adductor mandibulae externus* is either absent or inextricably fused with the caudal, deep portion of ventralis just described. We regard it as absent in hummingbirds.

Variations in adductor mandibulae externus are chiefly in the relative sizes of its parts and in the configuration of the aponeurotic sheet buried in pars rostralis temporalis. In *Glaucis*, pars lateralis is scarcely developed and pars ventralis is much reduced, attaching only on the dorsal edge and dorsolateral surface of the mandibular ramus. The "midrib" of the aponeurotic sheet of rostralis temporalis is a pronounced, flattened wall that stands at right angles to the sheet and extends along its caudoventral border. Its free edge can be seen as a line on the surface of the muscle where the fibers meet in pennate fashion. In *Calliphlox* and *Patagona* the midrib and pars lateralis are poorly developed. In *Eulampis* and *Glaucis* the narrow, caudodorsal extremity of pars rostralis temporalis arises in part from the transverse nuchal crest (crista nuchalis transversa).

Pars lateralis is especially well developed in *Metallura*.

M. ADDUCTOR MANDIBULAE CAUDALIS (A M C)FIGURES 2*a,b*, 3*c*

This stout muscle lies deep to *M. adductor mandibulae externus*. It extends from the quadrate (quadratum) to the mandible. Its origin is from the lateral surfaces of the body of the quadrate (corpus quadrati) and of the orbital process (processus orbitalis quadrati) except for its dorsal edge and lateral surface near the tip, which are occupied by *M. pseudotemporalis profundus*. The muscle passes ventrally to its insertion on the dorsal surface of the mandibular ramus and on the medial surface of a superficial aponeurotic sheet. Its attachment is immediately rostral to the jaw articulation (fossa articularis quadratica), bounded medially by the attachment of *M. pterygoideus dorsalis medialis* and rostrally by the two *pseudotemporalis* muscles. The more superficial fibers from the body of the quadrate are oriented rostroventrally from origin to insertion; the deeper fibers from the orbital process are more vertical in orientation. Criteria for separating this muscle from *M. pseudotemporalis profundus* are described under that muscle.

In *Glaucis* the more lateral fibers converge on the lateral surface of an aponeurotic sheet that inserts along the dorsolateral edge of the mandibular ramus caudal to the coronoid process. The rostromedial fibers insert on the medial surface of the same aponeurosis and the muscle is thus unipennate. In *Heliodoxa* the superficial aponeurotic sheet of insertion is particularly well developed.

M. PSEUDOTEMPORALIS PROFUNDUS (PS P)FIGURES 2*b,c*, 3*c*

This muscle extends from the orbital process of the quadrate to the dorsal surface of the mandibular ramus. It is partially deep to the insertion of *adductor mandibulae externus (rostralis temporalis)*. The dorsal attachment occupies the dorsal edge of the orbital process and a depression in the lateral surface of the tip of that process. The muscle overlies the more rostroventral portion of

M. adductor mandibulae caudalis from the orbital process. Its fibers pass rostroventrally, parallel and adjacent to the superficial fibers of *adductor mandibulae caudalis*, to their fleshy attachment on the mandible medial to the coronoid process and caudally to the attachments of *M. pseudotemporalis superficialis* and *M. adductor mandibulae caudalis*. A few fibers attach on the adjacent aponeurotic insertion of *M. pterygoideus dorsalis medialis*.

This muscle is not readily separable from *M. adductor mandibulae caudalis*. Dorsally the two muscles appear to meet at the point of penetration of a ramus of the mandibular nerve (nervus mandibularis), and ventrally at the tendon of insertion of *M. pseudotemporalis superficialis*. Ventrally the two muscles are further demarcated by the anterior limit of the superficial aponeurosis of insertion of *M. adductor mandibulae caudalis*.

In *Glaucis* this muscle is not strongly developed. By contrast it is unusually well developed in *Patagona*, and it includes an extensive superficial aponeurosis from the dorsal edge of the orbital process of the quadrate.

M. PSEUDOTEMPORALIS SUPERFICIALIS (PS S)FIGURES 2*b,c*, 3*b,c*

This muscle originates on a restricted portion of the caudal wall of the orbit above the optic foramen and between *M. protractor pterygoidei et quadrati* and *M. adductor mandibulae externus (rostralis temporalis)*. It extends ventrally, passing between the *pseudotemporalis profundus* and *adductor mandibulae externus (rostralis caudalis)* to its attachment on a tubercle (tuberculum pseudotemporale) of the dorsal surface of the mandibular ramus. The origin includes a partially superficial lateral aponeurosis and an internal aponeurosis, each from a pronounced tubercle on the caudal wall of the orbit. Fibers from the cranium and both aponeuroses attach on an aponeurotic sheet that is superficial on the caudal and rostromedial surfaces of the muscle. This partially investing aponeurosis coalesces to form a stout tendon of insertion. The muscle is multipennate.

In *Glaucis* the muscle is more slender and less strongly pennate.

M. PROTRACTOR PTERYGOIDEI ET QUADRATI
(P P Q)

FIGURES 2a-c, 3b

This thick muscle is differentiated into quadrate and pterygoid portions only at its insertion. It lies deep in the orbit between *M. pseudotemporalis superficialis* and *M. pterygoideus, pars dorsalis medialis*. It originates from the caudal wall of the orbit and the adjacent portion of the interorbital septum and sphenoidal rostrum (rostrum sphenoidale), caudally from the rostral edge of the ear opening forward to a point just rostral and ventral to the optic foramen. Fibers of the quadrate portion attach on a well-marked depression in the rostromedial surface of the quadrate, including the entire surface of the orbital process and the body of the quadrate rostral to the otic process (processus oticus quadrati) and excepting its ventral portion. Fibers from the pterygoid portion insert on the caudodorsal surface of the pterygoid (os pterygoideum) and on an aponeurosis extending forward from a ridge on the caudodorsal edge of the pterygoid.

M. PTERYGOIDEUS, PARS VENTRALIS MEDIALIS
(PT V M)

FIGURES 2c, 3a-c, 5d

This is a long, powerful muscle that extends from the medial process of the mandible (processus mandibulae medialis) to the palatine (os palatinum). Its structure is largely unipennate, and partially bipennate. Caudally, fibers have a fleshy attachment on the rostral edge of the medial process of the mandible and on a depression in its ventral surface. The major attachment, however, is by an aponeurotic sheet that passes caudally within the belly of the muscle. It emerges on the dorsal surface of the muscle and immediately attaches on the tip of the medial process of the mandible.

The rostral fleshy attachment of the muscle is

on most of the ventral and lateral surfaces of the wall of the palatine trough. In addition, fibers attach on a long, strong aponeurosis that covers most of the ventral surface of the muscle. This aponeurosis becomes stronger as it passes rostrally to its attachment on the transpalatine process and along the prepalatine bar to the ventral surface of the bony shelf that connects the prepalatine bar with the jugal bar. (See Figure 3a for terminology of the palatine and lower jaw.) The strongest part of this aponeurosis follows the long axis of the transpalatine process.

The short fibers of this long muscle pass mainly from the mandibular aponeurosis and medial process of the mandible to the dorsal and caudoventral surfaces of the palatine aponeurosis; those from the medial surface of the mandibular aponeurosis pass rostromedially to the wall of the palatine trough. The lateral portion of the palatine aponeurosis is intimately associated with *M. pterygoideus ventralis lateralis*.

PTERYGOIDEUS, PARS VENTRALIS MEDIALIS, EUSTACHIAN SLIP (PT V M E).—This short fleshy slip departs from the caudomedial surface of the main belly of this muscle and passes rostromedially to attach on the lateral wall of the opening of the eustachian tube (rima infundibula).

M. PTERYGOIDEUS, PARS VENTRALIS LATERALIS
(PT V L)

FIGURES 2c, 3a-c

This muscle lies lateral to *M. pterygoideus ventralis medialis* and is not clearly separable from it rostrally. Its fleshy caudal attachment is on the rostradorsal edge of the base of the medial process of the mandible and on the adjacent caudodorsal surface of the mandibular ramus. Its attachment lies between that of ventralis medialis and that of dorsalis medialis. Fibers pass rostromedially to their attachment on the caudolateral portion of the palatine aponeurosis of ventralis medialis. The lateralmost portion of this aponeurosis, attaching on the transpalatine process and bony shelf as described under ventralis medialis, may in fact represent this muscle.

M. PTERYGOIDEUS, PARS DORSALIS MEDIALIS
(PT D M)

FIGURES 2c, 3b,c

This broad, strap-like muscle lies in the orbit between the other portions of the pterygoideus muscle and the protractor pterygoidei et quadrati. From its attachment on the ventral and lateral surfaces of the pterygoid, the adjacent wall of the palatine trough, and the caudal part of the palatine hasp, it passes caudoventrolaterally over M. pterygoideus, pars ventralis medialis and pars dorsalis lateralis to its insertion on the dorsomedial surface of the mandibular ramus immediately rostral to the articulation. Fibers also attach on a short aponeurotic sheet that outlines its fleshy attachment. This aponeurosis is especially well developed along the rostral edge of the muscle.

The mandibular attachment is particularly broad in *Glaucis*, extending forward to a point just medial to the coronoid process of the mandible. The muscle is somewhat differentiated into rostral and caudal parts, the latter attaching on the ventral surface of the lateral portion of the pterygoid where it is partially overlapped by the caudal edge of the rostral part.

M. DEPRESSOR MANDIBULAE (D M)

FIGURES 2a, 3a, 5d

This is a stout muscle that passes from the ventrolateral surface of the cranium to the caudal end of the lower jaw and lies just behind the ear opening. Area for fiber attachment is greatly increased in this muscle by the presence of extensive external and internal aponeuroses. The origin of the more superficial portion of this muscle is from a well-defined inflated portion of the cranium caudal to the ear opening and along the adjacent transverse nuchal crest. Origin of the deeper portion is from aponeurotic sheets that extend from the caudal edge of the ear opening and from a crest just caudal to that edge. The aponeurosis from the edge of the ear opening is

superficial on the medial surface of the belly. It is folded and stronger from the tympanic process of the exoccipital (ala tympanica, os exoccipitale). The much smaller aponeurosis from the crest is internal.

The more superficial fibers insert on the medial surface of a large, superficial aponeurosis that attaches along a poorly defined transverse crest on the ventral and ventrolateral surfaces of the mandible. Deeper fibers attach just caudal to that aponeurosis on the caudodorsal slope of the ventral surface of the mandible, on a deep aponeurosis that inserts on the tip of the retroarticular process (processus retroarticularis), and along the adjacent caudal edge of the mandibular ramus to a point just medial to the retroarticular process. This aponeurosis extensively overlaps the aponeurosis of origin from the edge of the ear opening, and these aponeuroses coalesce at their medial limit to form the occipitomandibular ligament (ligamentum occipitomandibulare). This ligament extends from the tympanic process of the exoccipital to the caudal border of the mandible medial to the retroarticular process and caudal to the attachment of the medial jugomandibular ligament (ligamentum jugomandibulare mediale).

Muscles of the Tongue and Hyoid Apparatus

The most important descriptive works on myology of the hyoid apparatus (apparatus hyobranchialis) and tongue of hummingbirds are those of Moller (1931) for *Sericotes holosericeus*, and Weymouth et al. (1964) for *Eugenes fulgens*. Moller's work included brief descriptions and crude illustrations of some muscles, but he overlooked three muscles and incorrectly described another. Weymouth et al. overlooked one muscle and gave inaccurate or incomplete descriptions of two others. Other workers have alluded to the extraordinarily long hyoid horns (cornu branchiale) and their associated muscles.

We did not study the tracheal or laryngeal muscles in detail, but we note that none has an

attachment on the hyoid apparatus in hummingbirds.

M. SERPIHYOIDEUS (SE)

FIGURES 2a, 4a,b

This thin, strap-like muscle lies on the floor of the throat just caudal to *M. intermandibularis*. It has a linear origin along the transverse nuchal crest bordering *M. depressor mandibulae*. Here it lies deep to *M. cucullaris capitis*. The muscle passes ventrally along the surface of the mandibular depressor, angles rostromedially over *M. stylohyoideus*, and emerges below *M. branchiomandibularis*. The muscle is crossed obliquely by a tendinous intersection that follows the medial border of *M. stylohyoideus*. The belly inserts near the midventral portion of a transverse tendinous sling that supports the hyoid apparatus and permits it to move forward or backward beneath the larynx. The sling originates on the ventrolateral surface of the larynx, passes ventrally lateral to the ceratobranchiale (os ceratobranchiale), and curves ventromedially between the *stylohyoideus* and *branchiomandibularis* muscles to meet its opposite half in the midline. In some specimens the lateralmost fibers attach on an arm of the weak connective tissue sheet that forms the caudal limit of *M. intermandibularis*.

The above description applies to *Eulampis* and *Glaucis*. In the remaining forms (*Thalurania*, *Calliphlox*, *Heliodoxa*, *Metallura*, and *Patagona*) the lateral portion of this muscle meets its opposite member on a median raphe that is shared by *M. intermandibularis*. The medial portion separates from the lateral portion and passes dorsal to it to insert on a connective tissue sling as described for *Eulampis*. This sling lies deep to the rostral part of the muscle (Figure 4b) and to the caudal portion of *M. intermandibularis*. The muscle is partially divided by a tendinous intersection that is associated with the lateral portion.

Moller (1931) overlooked this muscle. Weymouth et al. (1964:254) inaccurately described it as attaching on "the ventral margin of the angle

of the mandible" and "apparently, on the belly of *M. stylohyoideus*."

M. INTERMANDIBULARIS (IM)

FIGURE 4a,b

This thin sheet of muscle is slung between the mandibular rami. It consists of two separate portions: a rostral sheet that has a linear origin along the dorsomedial surface of the ramus from a point about halfway between the origin of *M. branchiomandibularis* to the mandibular fenestra (fenestra mandibulae), and a more caudal sheet under the base of the tongue that originates on the dorsal surface of the ramus caudad from the mandibular fenestra for about 3 mm. The muscle lies dorsal to *M. branchiomandibularis* but ventral to the larynx and floor of the mouth. Fibers of both sheets meet along a midline raphe; those of the anterior sheet angle rostromedially toward the raphe, and those of the caudal sheet angle caudomedially. The caudal end of the muscle is extended by a weak sheet of connective tissue that sends an arm caudolaterally on either side to the lateral fibers of *M. serpihyoideus*.

The two sheets that comprise this muscle are sometimes formed of an irregular series of flat straps that may lie at different angles, causing gaps or overlaps between them. The larger gap between the two sheets may contain one or several such straps.

In *Heliodoxa*, *Thalurania*, and *Calliphlox* the muscle is divided as in *Eulampis*, but in *Glaucis* it is continuous and cannot be divided into rostral and caudal portions. In *Metallura* the muscle is divided only by a narrow gap and in *Patagona* by a narrow gap only at the origin but not on the raphe. We found the muscle to be divided in *Eugenes*; apparently Weymouth et al. overlooked the rostral portion.

M. GENIOGLOSSUS (GG)

FIGURE 4a

This is a long, slender, strap-like muscle that, with its twin, extends along the midline of the

floor of the mouth dorsal to *M. intermandibularis*. It originates from the caudomedial edge of the mandibular symphysis (symphysis mandibularis) and passes caudally. When the tongue is in its normal resting position the basihyale lies in a sheath-like evagination of the floor of the mouth. The fibers of this muscle pass caudad and terminate on the mouth lining at the base of this sheath. There is no insertion on the hyoid apparatus or tongue. In some specimens lateral fibers of this muscle curve laterally and attach on the mouth lining near the rostrrolateral portion of the larynx.

In *Heliodoxa* all fibers curve laterally; no fibers insert along the midline.

Weymouth et al. (1964) and Moller (1931) overlooked this muscle.

M. STYLOHYOIDEUS (ST)

FIGURES 2a, 4a,c,f

This is a long, strap-like muscle that follows the epibranchiale (os epibranchiale) and branchiomandibularis muscle in its course. It arises along the transverse rostral edge of a depression in the roof of the skull just behind the craniofacial hinge (zona elastica craniofacialis). It extends backward, following the curve of the cranium and closely appressed to the lateral edge of *M. branchiomandibularis*. The epibranchiale and these muscles occupy a shallow trough lateral to the cerebellar prominence (prominentia cerebellaris). The muscle continues rostrad below the cranium and mandibular ramus. It crosses *M. serpihyoideus* ventrally and angles anteromedially parallel to that muscle across *M. branchiomandibularis*, to pass through the lateral portion of the connective tissue sling associated with *M. serpihyoideus*. It continues rostrad ventral to *M. interceratobranchialis* and *M. ceratoglossus* to its insertion in a longitudinal depression on the dorsolateral surface of the basibranchiale rostrale, somewhat caudal to its midpoint. The insertion is along the dorsal edge of *M. hypoglossus obliquus*. The muscle is fleshy throughout.

In *Patagona* the origin is on the dorsal surface of the upper jaw at the level of the caudal end of the nares (apertura nasalis ossea), and in *Heliodoxa* just rostral to the craniofacial hinge. In *Metallura* the insertion is by a short, flat aponeurosis.

M. BRANCHIOMANDIBULARIS (BM)

FIGURES 2a, 4a,c

This is a long, strong, strap-like muscle that lies along the mandibular ramus ventral to *M. intermandibularis* and the large sublingual salivary gland (glandula mandibulares caudale), and crosses over *M. stylohyoideus* to engulf the epibranchiale along its entire length. The 4 mm origin is fleshy from the medial surface of the ventral half of the ramus about midway between the mandibular fenestra and the tip of the mandibular symphysis (symphysis mandibularis). The muscle passes caudally, and at the junction of the ceratobranchiale and epibranchiale it develops a dorsomedial trough into which the epibranchiale disappears. This muscle then ensheathes the epibranchiale. Fibers from either side of the trough curve dorsally around the epibranchiale and merge as they pass distally in parallel arrangement toward its tip. The muscle covers both sides and the deep surface of the epibranchiale, but superficially the belly is separated by a narrow gap that is closed by a tough membrane through which the epibranchiale may be seen. Toward the distal tip the gap closes and the epibranchiale becomes completely ensheathed by the belly. The long fibers extend almost the full length of the muscle belly and attach on a connective tissue sheath that contains the distal end of the epibranchiale.

In *Heliodoxa* the two epibranchiales and this muscle curve to the right of the dorsal bar of the upper jaw, pass over the bony flanges of the nares, and then curve left between the dorsal and ventral bars to enter a sheath in the roof of the upper jaw. In *Glaucis* the two muscles extend rostrad on either side of the dorsal bar of the upper jaw and terminate over the nasal flanges.

M. INTERCERATBRANCHIALIS (ICB)

FIGURE 4d,f,g

This spindle-like muscle lies along the medial surface of the ceratobranchiale. It originates from the medial surface of all but the rostralmost portion of that bone, and inserts in part fleshy on the lateral edge of the basibranchiale caudale (os basibranchiale caudale), and in part by a long, superficial, medial aponeurosis that attaches on the tip of the basibranchiale caudale. The muscle is thus unipennate.

M. CERATOGLOSSUS (CG)

FIGURE 4d-g

This slightly fan-shaped muscle lies along the ceratobranchiale and basibranchiale lateral to M. hypoglossus obliquus and medial to M. stylohyoideus and M. branchiomandibularis. It arises by two heads, a long, slender, caudal one from the caudolateral surface of the ceratobranchiale, and a stouter rostral one from the rostrolateral surface of that bone. The bellies fuse and narrow as the muscle proceeds rostrad to form a tendon that inserts on the ventral edge of the entoglossum just rostral to its articulation with the basibranchiale.

M. HYPOGLOSSUS OBLIQUUS (HG O)

FIGURE 4d-g

This spindle-shaped muscle lies along the basibranchiale rostrale (os basibranchiale rostrale) where it is bounded laterally by M. ceratoglossus. It originates along the entire basibranchiale, caudally from the lateral surface and rostrally from the ventral surface. The insertion is on the caudal extension of the entoglossum at a level caudal to the articular surface of that bone. The muscle has a skewed, fan-like shape because of its long origin and restricted rostral insertion. It is fleshy throughout.

A separate, small, fan-shaped slip originates from the rostroventral portion of the lateral sur-

face of the basibranchiale opposite the caudal end of the entoglossum. Fibers pass dorsocaudally to insert on the caudal cartilagenous extension of the entoglossum. This slip lies lateral to the rostralmost portion of the main belly.

Weymouth et al. (1964) described a lesser extent of origin and did not mention the fan-shaped structure or the separate rostral slip in *Eugenes*.

M. HYPOGLOSSUS ROSTRALIS (HG R)

FIGURE 4e-g

This is a tiny muscle arising from the lateral, ventral, and medial surfaces of the entoglossum just rostral to the insertion of M. hypoglossus obliquus. The short belly narrows as it extends rostrad ventral to the entoglossum to insert by a flat tendon on the ventral portion of the rostral cartilagenous extension of that bone. The origin of this muscle is somewhat divided by the entoglossum such that the muscle has been described as having lateral and medial heads (Weymouth et al., 1964).

Muscles of the Vertebral Column

In *Eulampis* there are 14 cervical vertebrae (vertebrae cervicales) and three unfused thoracic vertebrae (vertebrae thoraciae). Vertebrae are numbered in sequence starting with the atlas. Vertebra 13 may bear a tiny rib (costa) and vertebra 14 bears a well-developed floating rib. The cervical vertebrae are morphologically and functionally grouped into three sections (Figure 6). In hummingbirds the first section includes vertebrae 1 through 4; the second section, 5 through 10; and the third section, 11 through 14. The functional and morphological properties of these sections in birds are described by Boas (1929) and Zusi (1962). Muscles of the free thoracic vertebrae also attach on the fused vertebrae of the synsacrum that form the cranial portion of the pelvic girdle in hummingbirds.

The following synonymy for parts of vertebrae may prove useful; our terms, anglicized from Baumel et al. (1979), are in the left column.

vertebral body	centrum
vertebral arch	neural arch
spinous process	neural spine
ventral process	hypapophysis
caudal articular process	postzygapophysis
dorsal process	anapophysis
carotid process	sublateral process

We use the term "dorsal process" with reference to the caudal articular process, and "spinous process" rather than "dorsal process" for the median, vertical process of certain vertebrae (see Baumel et al., 1979:64, 65). The costal process (processus costalis) of the cervical vertebrae consists of two major portions that we call the head of the costal process and the costal spine (Figure 7c).

Most muscles of the vertebral column have not been described previously for hummingbirds. Burton (1971) noted and compared the remarkable cruciform structure of *M. splenius capitis* in hummingbirds, swifts, and a few other families.

M. COMPLEXUS (C)

FIGURE 5a,b

This strap-like, superficial muscle originates by two slips from the transverse processes (processus transversus) of vertebrae 4 and 5. The slips merge as the belly passes craniodorsally to its insertion on the transverse nuchal crest from near the median line laterally to the upper limit of *M. depressor mandibulae*. The insertion is immediately dorsal to that of *M. biventer cervicis*. The belly contains three tendinous intersections that pass craniomedially from its lateral edge without reaching the medial border. The medial fibers thus extend uninterrupted for the length of the belly, while the lateral ones are divided into four segments.

In *Metallura* the origin is from vertebrae 4, 5, and 6.

M. BIVENTER CERVICIS (B C)

FIGURE 5a,b

This muscle is long and slender, extending from the 14th vertebra to the cranium. It originates by a flat tendon from the spinous processes of vertebrae 13 and 14. The tendon passes cranially,

closely appressed to the aponeurosis of *M. longus colli dorsalis*, pars caudalis. At the level of vertebra 11, the tendon gives way to a fleshy, parallel-fibered belly. Dorsal to vertebra 7 this belly ends on a narrow tendon that continues cranially alongside the mid-dorsal line. A second belly originates from the tendon at the caudal end of vertebra 3 and inserts on the cranium just below the transverse nuchal crest, between the insertions of *M. complexus* and *M. splenius capitis*.

The tendon of origin in *Metallura* is from vertebra 14. In *Glaucis*, *Thalurania*, *Patagona*, *Heliodoxa*, *Metallura*, and *Calliphlox* it comes from 13.

M. SPLENIUS CAPITIS (S CA)

FIGURE 5b,c

This muscle originates by several short, flat tendons from the caudodorsal border and dorsal process of the axis. As pointed out by Burton (1971), the right and left muscles have an interdigitating or cruciform pattern of origin in hummingbirds and some other families. The muscle inserting on either side of the midline originates from the opposite side of the midline. In *Eulampis* there are 6 or 7 overlapping layers of flat tendons of origin, mostly from the dorsal processes. Only the deepest pair originates from the middle portion of the ridge between the dorsal processes. From these short tendons each of the fleshy slips fans out and fuses with other slips before inserting on the dorsal and lateral portions of the occipital region. The right and left bellies are more or less divisible into two portions, a thinner dorsal one and a thicker lateral one. The thicker portion is formed from both superficial and deep slips; the thinner portion arises only from intermediate tendons. The dorsal portion has a roughly linear insertion deep to those of *M. complexus* and *M. biventer cervicis*. The lateral portion inserts on a broader area medial to *M. rectus capitis lateralis*.

In one specimen slips inserting on the right side originated in part by a slender tendon from the left dorsal process of the atlas, and another from the dorsal process of vertebra 3. The latter tendon passed forward toward dorsal process 2 before penetrating the left belly of *M. longus colli dor-*

salis and turning toward the right side.

M. RECTUS CAPITIS LATERALIS (R C L)

FIGURE 5a-d

This strap-like muscle of the cranial portion of the neck lies lateral to *M. rectus capitis ventralis* and to the carotid artery (*arteria carotis interna*), and ventral to *M. complexus*. The muscle arises by three short tendons, the most caudal coming from the tendon of *M. longus colli ventralis* just caudal to the level of the ventral process of vertebra 3, and the other two from the ventral processes of vertebrae 3 and 2 respectively. Fleishy slips from these tendons fuse and continue to an insertion that is partly aponeurotic and partly fleshly, along the lateral portion of the transverse nuchal crest just caudal to *M. depressor mandibulae*.

In *Patagona* the slip from 2 is relatively small and the caudal portion from *M. longus colli ventralis* relatively large. The slip from 2 is absent in *Heliodoxa* and *Metallura*.

M. RECTUS CAPITIS DORSALIS (R C D)

FIGURES 3a, 5c-e

This muscle is deep to *M. complexus*, *M. rectus capitis lateralis*, and *M. rectus capitis ventralis*. It consists of three slips that extend from origins on the dorsal processes of the caudolateral portion of the vertebral arch (*arcus vertebra*) of vertebrae 1, 2, and 3 to the caudal transverse crest of the basitemporal plate (*lamina basitemporalis*), from the midpoint laterally almost to the ear opening, and from the area immediately behind the crest. The middle belly is largest and it has a tendinous insertion on the middle and lateral portions of the caudal transverse crest. The small anterior belly inserts deep and caudal to the insertion of the second slip. The caudal belly is long and spindle-shaped. Some of its deeper fibers arise from the lateral surface of the transverse process of 3. It inserts mainly by a long, superficial aponeurosis on the medial portion of the transverse crest and in part by fleshy fibers adjacent to the aponeurosis.

M. FLEXOR COLLI LATERALIS (F C L)

FIGURE 5a, c-e

In hummingbirds this muscle lies largely caudal to *M. rectus capitis dorsalis* rather than deep to it as in many other birds. It originates from the transverse processes of vertebrae 3, 4, and 5, and some fibers attach between the transverse processes on the lateral surface of *Mm. intertransversarii*. The main, superficial portion of the belly proceeds cranioventrally and inserts by a short tendon on the lateral projection of the ventral process of the atlas. Deeper fibers of this muscle insert by a short tendon on the lateral projection just dorsal to the attachment of the main tendon of *M. longus colli ventralis*. The smallest slip arises from the transverse process of vertebra 3 and inserts on the atlas. Its fibers attach on the inner surface of the tendon of insertion of the main portion and on the adjacent bony surface of the atlas.

M. RECTUS CAPITIS VENTRALIS (R C V)

FIGURES 3a, 5a, c, d

This stout muscle lies ventrally on the neck between the branches of the carotid artery as they emerge from the neck and enter the skull. It arises from the caudoventral surface of the body (*corpus vertebrae*) of vertebra 4, the ventral processes of 3, 2, and 1, and from aponeuroses extending forward from these ventral processes. Fibers from vertebrae 1 and 2 fan out cranially to insert fleshy on the basitemporal plate of the cranium, bounded by the eustachian tube, the rostral edge of the basitemporal plate, the ear openings, and the caudal transverse crest of the basitemporal plate. The slips from different vertebrae are partially separable at their origins, but they quickly form a compact muscle mass. The muscle in some specimens is weakly divided by one or two transverse, tendinous intersections.

MM. INTERCRISTALES (IC)

FIGURES 5b, c, e, 7a, e

This series of bellies lies deep to *M. longus colli dorsalis* and connects successive vertebrae from

the craniodorsal portion of the vertebral arch to the caudodorsal portion of the arch of the next cranial vertebra. The origin and insertion of successive bellies on a given vertebra are separated by the transverse-oblique crest (crista transverso-obliqua). In the second neck section they originate along the lateral edge of the transverse-oblique crest and pass forward to insert on a depression of the vertebral arch between the transverse-oblique crest and the midline. The bellies are differently developed in different portions of the neck, as are the transverse-oblique crests. Differences are essentially as follows (numbers refer to vertebrae).

1-2: From cranial face of vertebral arch 2 below transverse crest, fibers converge on dorsal process 1.

2-3: Belly broad and thick, covering most of vertebral arch. Medial fibers oriented longitudinally and somewhat separate from more lateral ones that angle craniolaterally from origin to insertion. Lateralmost fibers pass directly between dorsal processes of 3 and 2. Connects caudal edge, dorsal surface of vertebral arch, and dorsal process of 3, to caudal edge of vertebral arch and dorsal process of 2.

3-4: Smaller than above. Lateral portion less developed, and caudal attachment narrower because of medial shift of dorsal process. This and all succeeding bellies deep to *M. cervicalis ascendens* in lateral view.

4-5: Much smaller, long, and slender. Origin and insertion as described above for second neck section. This and next three bellies displaced laterally from midline of vertebral arch.

5-6: Similar to above but slightly broader.

6-7: Similar to 5-6.

7-8: Broader than 6-7.

8-9: In 9, transverse-oblique crest much less prominent and abruptly shifted caudad. Muscle broad and flat, bordering midline of vertebral arch.

9-10, 10-11, 11-12, 12-13, 13-14: Bellies flat and border midline as above, but become progressively narrower so that last belly is small. Originate on cranial slope of vertebral arch and insert on caudal slope of adjacent vertebral arch.

In *Glaucis* and *Patagona* only bellies four and five (from the front) are displaced laterally from the midline by slips of *M. longus colli dorsalis, pars cranialis*.

M. LONGUS COLLI VENTRALIS (L C V)

FIGURES 5a, c-e, 6a,b, 7b,d

This large muscle occupies most of the ventral surface of the neck and is bordered above by the *Mm. intertransversarii* and *Mm. inclusi*. It consists of a series of compound slips inserting on the costal spines of vertebrae 2 through 12. Origins are fleshy or semitendinous from the carotid processes or ventral processes of 4-18. The first slip attaches on the costal spine of the axis by a long, strong tendon that receives fleshy fasciculi on its ventral surface from the carotid processes of vertebrae 4 through 9 and the ventral processes of vertebrae 10 through 12. The next four slips consist of long slender tendons, each lying dorsal to the preceding one, that receive fasciculi anteriorly from the carotid process of the second vertebra back, and caudally from the ventral processes of neck section 3 and the thoracic vertebra as shown in Figure 6. Slips inserting on vertebrae 7 through 12 receive fasciculi from the second vertebra caudally and from varying numbers of successive vertebrae. The tendon to vertebra 8 is relatively broad, receiving a stout fasciculus from 10 on its medial portion and the more slender and caudal fasciculi on its lateral portion. The short fasciculi originating on the second vertebra caudal to that of insertion that are associated with each slip of this muscle are broad and flat as they pass forward along the intervening vertebra. At the cranial end of that vertebra they give way to a flat tendon that fuses with the longer tendon of insertion of the slip.

M. FLEXOR COLLI MEDIALIS (F C M)

FIGURE 5d,e

This muscle lies deep on the ventral side of the cranial portion of the neck where it is closely associated with *M. longus colli ventralis*. Its slips

extend forward from the carotid processes to the caudal and lateral surfaces of the ventral processes. Slips originate by short tendons from vertebrae 6 and 5 and insert on 3. Slips from 5 and 4 insert on 2.

M. LONGUS COLLI DORSALIS, PARS CRANIALIS
(L C D CR)

FIGURES 5*b*, 7*a*

This muscle of the craniodorsal surface of the neck consists of four slips that lie immediately dorsal to Mm. intercostales. The muscle originates from the dorsomedial surface of the vertebral arch of the vertebrae 6, 5, 4, and 3. The slips pass cranially to attach in sequence on the ventral surface of the tendon of insertion of pars caudalis. The slip from vertebra 6 is very thin and lies mostly deep to pars caudalis. The slips from 5 and 4 are relatively stout. The lateral portion of the slip from 4 passes forward deep to the slip from 5 and inserts just cranial to the attachment of that slip. The slip from 3 consists of only a few deep fibers.

In one specimen the medial fibers from vertebra 4 gave rise to a slender tendon that passed over the axis, the cranialmost belly of Mm. intercostales, and the tendon of M. splenius capitis, to insert on the dorsal process of the atlas.

The pattern of slips in *Patagona* resembles that of *Eulampis*. In *Heliodoxa* an additional slip arises from vertebra 7, and in *Thalurania*, *Metallura*, and *Calliphlox* extra slips arise from 7 and 8. There was no slip to the atlas in *Heliodoxa*, *Metallura*, and *Calliphlox*.

M. LONGUS COLLI DORSALIS, PARS CAUDALIS
(L C D CA)

FIGURES 5*a*,*b*, 7*a*

This is the major dorsal muscle of the neck and is continuous with pars thoracica from the thoracic vertebrae and synsacrum. We define pars caudalis as those slips inserting on vertebra 14 and forward. Separation of slips at their origin is necessarily somewhat artificial because the mus-

cle mass is a compact unit, and the aponeuroses of origin from vertebrae 12, 13, and 14 partially fuse into a broad sheet. Fibers from a particular vertebra of insertion pass back to their origin on this sheet, and the origin of a given slip may be broad enough to include aponeurotic attachments from several vertebrae. Bellies inserting on the dorsal processes were traced back to the following pattern of origins from the dorsal edges of the spinous processes (numbers refer to vertebrae):

insertion	origin
2	11, 12, 13, 14
6	11, 12
7	11, 12, 13, 14
8	11, 12, 13, 14
9	12, 13, 14
10	12, 13, 14
11	13, 14, 15
12	14, 15, 16
13	15, 16, 17, 18
14	15, 16, 17, 18

The first slip is long and strong, giving way cranially to a strong tendon to dorsal process 2. This tendon is shared by pars cranialis. Insertion of the second and narrowest slip is by a short tendon on the dorsal process of 6. The remaining slips are broader and occupy the medial surface of aponeuroses from the dorsal processes of 7 through 14 that are occupied on their lateral surface by M. cervicalis ascendens.

M. CERVICALIS ASCENDENS (C A)

FIGURES 5*a*,*c*,*e*, 7*a*,*b*,*e*, 8*a*

This muscle consists of a series of bellies lying along the dorsolateral surface of the neck between M. longus colli dorsalis and Mm. intertransversarii. In general, each belly inserting on the dorsal process of one vertebra receives slips from the transverse processes of the second and third vertebrae caudal to that of insertion. Origins are partly tendinous and partly fleshy. The longer of the two slips of each belly lies caudal and dorsal to the shorter slip. Both slips converge cranially onto an aponeurosis that inserts on the dorsal process. This aponeurosis serves primarily the

longer slip; the shorter has a more fleshy insertion on the caudal articular process ventral and lateral to the aponeurosis. Caudally (vertebrae 9 and 10) the dorsal surface of the tendon of insertion is largely occupied by *M. longus colli dorsalis pars caudalis*, whereas the ventral surface receives the longer slip of this muscle. Vertebra 9 receives a third slender slip from 13.

We regard this muscle as those bellies inserting on vertebrae 3 through 13. The slip to 13 consists of fasciculi from 15 and 16 and fibers from the ventral surface of a superficial aponeurosis from the edges of the craniodorsal synsacral depression. The entire belly is closely associated with *M. longus colli dorsalis* and is continuous with *M. thoracicus ascendens*.

MM. INTERTRANSVERSARI (IT)

FIGURES 5*a,e*, 7*b,d,e*, 8*a*

This series of multipennate bellies lies along the lateral surface of the neck between *M. longus colli dorsalis* and *M. longus colli ventralis*. Each belly extends from the transverse process and costal process of one vertebra to the transverse process and costal process of the next cranial vertebra. Its structure differs somewhat in different sections of the neck. This muscle is intimately associated with *Mm. inclusi*.

In a typical belly of the second neck section—for example, that between vertebrae 6 and 7—a long aponeurosis from transverse process 6 extends caudally almost to transverse process 7 and it receives pennate fibers on its lateral surface from a smaller aponeurosis that passes cranially from transverse process 7. Fibers from the medial surface of the larger aponeurosis extend caudally and sometimes medially to attach on the lateral surface of the major aponeurosis of *Mm. inclusi dorsalis* and on the transverse process of 7. Ventrally, fibers extend forward from the anterior face of the head of the costal process of 7 to the lateral surface of the costal process of 6 and to the concavity between the costal process and body of vertebra 6. Superficially, some fibers extend from a given vertebra to the second vertebra cranial or caudal to it.

In the first neck section, the belly between vertebrae 4 and 5 is similar to those of the second section but the aponeuroses are weaker and the muscle blends more with *Mm. inclusi*. The belly between vertebrae 3 and 4 is much reduced, with weak aponeuroses. Fibers pass forward from the transverse process to occupy the concavity medial to the costal process of vertebra 3. The first belly is small. It arises fleshy from the head of the costal process of vertebra 3 and passes to the lateral surface of the vertebral arch of the axis. It lies mostly deep to the cranialmost slip of *M. flexor colli lateralis*. Several longer slips occur in the cranial portion of this muscle. From the cranioventral portion of the costal processes of 6 and 5, slips extend forward to a semitendinous insertion on the dorsal edge of the costal spine of vertebra 3. Dorsal to this slip, another extends from the cranial portion of the costal process of 6 to a long aponeurosis attaching on the transverse process of 4, dorsal to the costal spine.

In section three, the belly between vertebrae 10 and 11 is well developed. Its major aponeurosis extends superficially from transverse process 10 caudally and sends fibers in a fan-shaped pattern to the transverse process of 11 and to its cranially directed aponeuroses. A strong ventral aponeurosis from the costal process of 11 extends cranially and sends fibers to the transverse process and body of vertebra 10 (the latter portion represents *Mm. inclusi*). Between vertebrae 11 and 12 the belly is slightly narrower, being displaced ventrally somewhat by the larger bellies of *M. longus colli ventralis*. Between vertebrae 12 and 13, 13 and 14, and 14 and 15 the bellies are markedly reduced in keeping with the sharp reduction in the lateral surface of the transverse process and the absence of the costal process in vertebrae 13, 14, and 15, which bear ribs.

This muscle is continued caudally as *M. iliocostalis*.

MM. INCLUSI (IN)

FIGURE 7*c-e*

These muscles lie on the lateral surfaces of the vertebrae deep to *Mm. intertransversarii*. They

begin on vertebra 3, end on 10, and are best developed in the second neck section. Each typical belly is divided into three slips, one lying dorsal and one ventral to the vertebral artery (*arteria vertebralis*), and a thin, superficial, dorsal slip that is described under this muscle although it may represent an aberrant slip of *Mm. intertransversarii*. The fibers from each of these slips have a broad fleshy attachment on a given vertebra and converge onto a large aponeurosis that originates on the next caudal costal process.

The dorsalmost slip inserts along a dorsolateral ridge of the vertebral arch that begins as a protuberance near the midpoint of the side of the arch and continues caudally along the caudal articular process. Fibers extend caudolaterally and converge onto the ventral surface of a broad but weak aponeurosis that originates on the dorsal edge of the next caudal transverse process. A few fibers of the craniolateral portion of the slip attach on a thin aponeurosis from the protuberance of the vertebral arch. This aponeurosis curves craniolaterally to the dorsolateral tip of the transverse process of the same vertebra. Between the aponeurosis and the caudal border of the preceding caudal articular process, a "window" reveals the deeper portion of *Mm. inclusi* (Figure 7*e*).

The large middle slip attaches on the entire lateral surface of the vertebral arch deep to the dorsal slip. Its fibers converge on the medial surface of a large, strong, fan-shaped aponeurosis that attaches along the craniolateral edge of the next caudal costal process.

The ventral slip is similar in structure, but arises from the ventrolateral surface of the vertebral body and converges on an aponeurosis that attaches on the craniolateral edge of the costal process between its head and the carotid process.

The belly between vertebrae 4 and 5 has well-developed aponeuroses, but that between 3 and 4 is much reduced, largely fleshy, and fused with the belly of *Mm. intertransversarii*. The belly between vertebrae 9 and 10 is much reduced, and the last belly, from 11 to 10, is restricted to a small ventral slip arising from an aponeurosis common to *Mm. intertransversarii*.

M. ILIOCOSTALIS (ILC)

FIGURE 8*a*

This series of slips appears to be a modified continuation of *Mm. intertransversarii*. The bellies between vertebrae 16 and 15, and 17 and 16 interconnect the lateral portions of the transverse processes. The caudalmost belly arises from the craniolateral portion of the synsacrum (fused transverse process of 18) and inserts on the lateral portion of transverse process 17 and the adjacent dorsocaudal edge of the associated rib. In addition to these bellies, a larger, longer slip arises along a long aponeurosis from a short spine on the craniolateral tip of the synsacrum and inserts on the transverse processes of vertebrae 17, 16, and 15 dorsomedial to the smaller bellies. The long aponeurosis of this portion is shared by *M. thoracicus ascendens*.

"M. LONGISSIMUS DORSI"

M. longus colli dorsalis thoracica and *M. thoracicus ascendens* form a complex muscle mass which, in whole or in part, is sometimes referred to as the longissimus dorsi. Our interpretation of these muscles is based on the premise that they should be interpreted as continuations of neck muscles, barring evidence to the contrary; in so doing we conclude that a separate "longissimus dorsi" is superfluous in describing hummingbirds. The basic structure of the thoracic muscle mass is best visualized in terms of its aponeurotic framework because the slips of these muscles are compacted and often inseparable. A series of superficial aponeuroses extends craniolaterad from the dorsal edge of the spinous processes of the thoracic vertebrae. These are clearly continuations of those of *M. longus colli dorsalis, pars caudalis*. A deeper series of shorter aponeuroses from the dorsolateral surface of the thoracic spinous processes parallels the first series; we assign both series to *M. longus colli dorsalis thoracica*, although it is possible that the deep series represents a modification of *Mm. intercostales*. Lying between these two series is a set of long, broad

aponeuroses that pass caudolaterad from the dorsocaudal tip of the spinous processes of the thoracic vertebrae and vertebra 14. This series was assigned to *M. longus colli dorsalis thoracica* by Boas (1929, pl. 15: fig. 7) but we regard it as a thoracic specialization of *M. thoracicus ascendens* because of its lateral origins and medial insertions. These aponeuroses may have originated as a dorso-medial extension of the typical aponeuroses of that muscle, which extend caudad from the caudal articular processes of the thoracic vertebrae and are clearly a continuation of those shared by *M. longus colli dorsalis* and *M. cervicalis ascendens* in the neck. Aponeuroses passing craniad from the craniolateral portion of the synsacrum and the transverse processes are associated primarily with *M. iliocostalis*, which probably represents a modification of *Mm. intertransversarii*. A broad, superficial aponeurosis from the edges of the synsacral depression passes craniad and covers much of the thoracic muscle mass. This aponeurosis serves as partial origin for *M. thoracicus ascendens* as we interpret that muscle.

**M. LONGUS COLLI DORSALIS THORACICA
(L C D T)**

FIGURE 8a

This muscle is much reduced in the thorax whereas *M. thoracicus ascendens* is much enlarged. It consists of superficial and deep portions that are partially separated by aponeuroses of insertion of *M. thoracicus ascendens* on the spinous processes. Fibers of the superficial portion arise from the dorsal edges of the spinous processes of the thoracic vertebrae and the first synsacral vertebra. These aponeuroses become successively stronger craniad, and they pass craniad almost parallel to the median line. They form a series continuous with *M. longus colli dorsalis, pars caudalis*. Insertion of fibers from these aponeuroses is on the caudal articular processes of the thoracic vertebrae and on aponeuroses that pass caudally from them. The aponeurosis of insertion from vertebra 15 is well developed; those from 16 and 17 are very small. As in the

neck, these aponeuroses are shared by the *ascendens* muscles.

Fibers of the deep portion arise from the lateral surfaces of the thoracic spinous processes, and from a deeper series of aponeuroses that pass craniad from the caudodorsal portion of the lateral surface of the spinous processes of vertebrae 16 and 17 and of the first synsacral vertebra. Fibers pass craniad to their insertions on the spinous processes, on the medial surfaces of the aponeuroses of insertion of *M. thoracicus ascendens* to the spinous processes, and on the caudal articular processes and their associated aponeuroses.

M. THORACICUS ASCENDENS (T AS)

FIGURE 8a

This large muscle mass originates from the dorsal surfaces of the transverse processes of the thoracic vertebrae and from the surface of the synsacral depression. In addition it arises from the ventral surface of a large superficial aponeurosis that attaches along the edges of the synsacral depression and the spine on the craniolateral tip of the synsacrum, and from an aponeurosis passing craniad from that spine. The muscle is directly adjacent to *M. iliocostalis* laterally and to *M. longus colli dorsalis thoracicus* medially. Its fibers have two main insertions. The more superficial ones attach on the lateral surfaces of a series of broad aponeuroses that pass caudoventrally from their attachments on the dorsocaudal tips of the spinous processes of 14 (small), 15, 16, and 17. These aponeuroses separate the superficial portion of *M. longus colli dorsalis thoracica* from its deep part. The more lateral and deeper fibers of this muscle insert on the dorsal and ventral surfaces of the aponeuroses attaching on the caudal articular processes, which are shared by *M. longus colli dorsalis thoracica*.

Muscles of the Trunk and Abdomen

In *Eulampis* there are either one or two cervical ribs (in this discussion we refer to only one side of

the bird). Both are floating ribs, lacking bony attachments at their distal ends, and the first, from vertebra 13, is either tiny or absent altogether. The second floating rib is much larger. There are five attached ribs—that is, ribs that attach on the sternum. The first three are associated with the three free thoracic vertebrae and the last two with fused vertebrae of the synsacrum. Caudal to these ribs are three more that attach distally on the preceding rib. These are the accessory ribs, and they attach further caudally on the synsacrum and may be bound to the craniolateral edge of the ilium. The dorsal portion of each rib is termed the vertebral rib; the ventral portion is the sternal rib. The latter portion is absent in floating ribs. Uncinate processes attach on vertebral ribs and they are usually associated only with the attached ribs.

Numbers of thoracic vertebrae, floating ribs, attached ribs, and accessory ribs vary within and between species. A proper comparison of these features and their associated muscles would be a statistical one, but we have not recorded or analysed quantitative variation of these features in this paper.

M. OBLIQUUS EXTERNUS ABDOMINUS (O E A)

FIGURE 8b

This is the most superficial muscle of the abdominal wall. It arises by an aponeurosis from the lateral surfaces of the five attached ribs at the level of their uncinat processes (processus uncinatus), from the ventral edge of the base of the uncinat processes, and from the lateral surfaces of the accessory ribs. The aponeurosis of origin from the attached ribs quickly gives rise to fleshy fasciculi. These fasciculi pass caudoventrally and end on short flat aponeuroses that fuse with the superficial dorsolateral aponeurosis on the surface of *M. pectoralis* adjacent to the rib cage, caudally to the caudolateral angle of the sternal plate (corpus sterni). Caudal to that point the belly ends on an aponeurosis that meets its counterpart from the other side at the midline and is closely applied to *M. rectus abdominus*.

M. SCALENUS (S)

FIGURES 5a, 8a

The belly of this muscle arises fleshy from the transverse process of the penultimate cervical vertebra (13) and from the rudimentary floating rib when it is present on that vertebra. The fibers of the stout belly pass caudoventrally and insert fleshy on the cranial edge of the dorsal two-fifths of the floating rib of the last cervical vertebra.

MM. LEVATORES COSTARUM (L CO)

FIGURE 8a

These triangular muscles occupy the dorsal-most portion of the intercostal spaces. The first arises fleshy from the tip of the transverse process of the last cervical vertebra (14). Fibers of the somewhat two-parted belly fan out caudoventrally. The dorsal part inserts fleshy onto the lateral and cranial surfaces of the proximal 3mm of the first attached vertebral rib. The ventral part inserts onto the cranial edge of that rib. On vertebrae 15 and 16 similar bellies arise semitendinously from the tip of the transverse process and from the caudal edge of the corresponding rib. The fibers pass caudoventrally and insert fleshy onto the cranial and lateral surfaces of the next caudal vertebral rib and on an aponeurotic sheet connecting successive ribs. The last slip is the smallest and is covered dorsally by a slip of *M. iliocostalis* and ventrally by the dorsal portion of *Mm. intercostales externi*. The origin and insertion are similar to the other slips.

MM. INTERCOSTALES EXTERNI (I E)

FIGURE 8a,c

These muscles occupy the spaces between adjacent ribs. They arise fleshy from the caudolateral surface of a given rib, beginning with the floating rib from vertebra 14. The first belly arises fleshy from that entire rib and by an aponeurosis from its tip. The fibers of the belly pass caudoventrally and insert fleshy on the cranial surface of the first attached vertebral rib between the ven-

tral border of *M. levator costarum* and the articulation with the sternal rib. The next four slips of this muscle arise fleshy from the entire caudal surface of the uncinat process and its vertebral rib ventrally almost to the articulation with the sternal ribs. Parallel fibers pass caudoventrally and insert fleshy on the cranial surface of the ventral half of the next caudal uncinat process and the cranial edge of its rib ventrally to the articulation with the sternal rib. The origins of the third, fourth, and fifth bellies of this muscle are aponeurotic in the region of the junction of the uncinat process and the rib. This tends to separate the bellies into dorsal and ventral portions. The sixth belly consists of completely separate dorsal and ventral portions. The dorsal portion arises from the last uncinat process and inserts by means of an aponeurosis onto the lateral surface of the first accessory rib at about the level of the uncinat processes. The ventral portion arises by an aponeurosis and by fleshy fibers from the caudal surface of the fifth attached rib ventral to its uncinat process. It inserts by a short aponeurosis on the cranial surface of the ventral portion of the first accessory proximal rib. The last bellies consist of fleshy slips between the ventral ends of the vertebral accessory ribs 1-2 and 2-3. The last belly is minute.

MM. INTERCOSTALES INTERNI (I I)

FIGURE 8a-d

These muscles occupy the spaces between successive attached ribs and accessory ribs. They arise from the caudomedial surface of one rib and pass caudally to insert along most of the craniomedial surface of the next caudal rib. At the level of the uncinat process the fibers pass caudodorsally. Dorsal to the uncinat process the belly between the first and second attached ribs is largely aponeurotic. The short fibers of the belly are restricted to the caudal edge of the muscle. The belly between the second and third ribs dorsal to the uncinat process is more fleshy but the cranial edge is partly aponeurotic. The remaining bellies are completely fleshy.

M. COSTOSTERNALIS (CST)

FIGURE 8c,d

Pars minor is absent in hummingbirds.

PARS MAJOR (CST MA).—This strong, cylindrical, unipennate muscle lies medial to the sternal ribs. It arises fleshy and by a superficial medial aponeurosis from the craniolateral process of the sternum (*processus craniolateralis*). The cranialmost fibers from the aponeurosis of origin form a strap-like belly to the first sternal rib near its articulation with the vertebral rib. Fibers arising more caudally from the aponeurosis form a series of slips to the second, third, and fourth sternal ribs.

M. COSTOSEPTALIS (CSP)

FIGURE 8d

This muscle is represented by a series of muscle slips that arise fleshy from the inner aspect of all the vertebral attached ribs and the first two accessory ribs. Cranially the first two slips arise very near the articulation with the sternal ribs. Succeeding slips arise progressively further dorsally along the ribs. The small, strap-like or fan-shaped slips pass dorsomedially and coalesce so that there is a continuous fleshy insertion onto the horizontal septum (*septum horizontale*). See Baumel et al. (1979:225) for a diagrammatic cross-section that shows the relations of this muscle.

M. RECTUS ABDOMINUS (R A)

FIGURE 8b

This muscle arises by a dense aponeurosis from the ventral portion of the distal end of the pubis and from dense connective tissue between the distal ends of the pubes. Fleshy parallel fibers pass cranially and slightly laterad to insert on the caudal edge of the sternum (*margo caudalis*) from a point immediately lateral to the midline laterally to the widest point of the sternum.

M. TRANSVERSUS ABDOMINUS (T AB)

FIGURE 9b

This is the deepest of the abdominal muscles and it lies just cranial to the distal end of the

pubis. The muscle arises fleshy from the ventral edge of the distal few millimeters of the pubis. The fibers of the 3 mm long belly pass medially parallel to the pubis to end on a midline raphe (linea alba) that extends from the interpubic connective tissue to the caudal end of the sternum.

In *Heliodoxa* the belly is relatively wider than in the other species.

M. OBLIQUUS INTERNUS ABDOMINUS (O I A)

FIGURE 8b

This sheet of muscle arises fleshy from the entire length of the pubis as far caudad as the lateral border of *M. rectus abdominus*. Fibers of the belly pass cranioventrally to insert on the caudal edge of all but the distal tip of the last accessory vertebral rib.

Muscles of the Tail

M. BULBI RECTRICIUM (B R)

FIGURE 9c-e

This muscle arises from a sheet of connective tissue that extends from the distal end of the pygostyle (pygostylus) across the ventral surfaces of the medial four rectrices. Fleshy fibers pass cranioventrally to the ventral surfaces of the lateral four rectrices and to a connective tissue envelope that encloses the bases of those four feathers. A distinct lateral slip arises from the dorso-lateral portion of this connective tissue envelope. Its fleshy fibers ensheath the base of the lateral-most rectrix and pass distally to attach along the ventrolateral surface of the base of that feather.

M. LEVATOR CAUDAE (LE C)

FIGURE 9a,b

This large muscle arises fleshy from the dorso-medial surface of the synsacrum beginning at the level of the acetabulum, from the dorsomedial portion of the transverse processes of the caudal vertebrae (vertebrae caudales), and from the

lower surface of a superficial aponeurosis that covers the cranial part of the belly. The muscle lies just lateral to the midline and is the most superficial of the dorsal tail muscles. Separate fasciculi pass caudomedially dorsal to the transverse processes of the caudal vertebrae. They insert tendinous on each of the spinous processes of the caudal vertebrae and on the craniomedial surface of the pygostyle.

The cranial portion of the deeper part of this muscle lies deep and lateral to the insertion of the portion described above. It is largely obscured by the uropygial gland (glandula uropygialis). This portion arises fleshy from the bases of the transverse processes of the first four caudal vertebrae. The fan-shaped belly passes caudolaterally and inserts by a short tendon onto the calamus of each of the five rectrices.

M. LATERALIS CAUDAE (LA C)

FIGURE 9a-c

This muscle arises fleshy from the lateralmost portion of the fused transverse processes of the two caudalmost synsacral vertebrae and the first free caudal vertebra, from an aponeurosis that connects these transverse processes, and from the medial edge of the ilium opposite the laterally projecting processus terminalis illi. The nearly parallel fibers pass caudally and slightly laterad lateral to the uropygial gland to insert fleshy on to the lateral edge of the base of the outermost rectrix just cranial to *M. pubocaudalis externus*.

M. DEPRESSOR CAUDAE (D C)

FIGURE 9a,d

This muscle consists of a superficial and a deep portion. The superficial portion arises fleshy from the fused lateral border of the last three transverse processes of the synsacrum and from the ventrolateral surfaces of those transverse processes. In addition, fibers originate from the ventral surface of the lateral two-thirds of the transverse processes of all caudal vertebrae. Fibers pass caudomedially and attach on the ventral surface of a strong

superficial aponeurotic sheet that is common to the right and left muscles. This sheet forms a sling under the body of the pygostyle. Fibers from the last transverse process attach on the lateral fork of the ventral process of the pygostyle. These fibers blend with those of the deep portion of the muscle. A flat, oval bone lies imbedded in the caudoventrolateral portion of the aponeurotic sheet. A short, stout tendon joins the caudal end of the oval bone with the lateral process of the base of the pygostyle (basis pygostyli). Flat tendinous fasciculi pass caudolaterally from the aponeurotic sheet and oval bone to the bases of all but the medial rectrix (see also *M. pubocaudalis internus*).

The deep portion of this muscle arises from the ventral surface of the bodies of the caudal vertebrae and from the ventral surfaces of the medial third of the transverse processes of caudal vertebrae 2-5. The medial fibers pass caudally to insert tendinously onto the ventral processes of the last three caudal vertebrae. Fibers from the transverse processes of these vertebrae pass caudomedially to insert on the ventrolateral surface of the base of the pygostyle and on the ventral process of that bone deep to the tendon from the oval bone.

M. PUBOCAUDALIS EXTERNUS (P E)

FIGURE 9a-c

This muscle has a fleshy origin from the caudal portion of the ischium and along the caudal portion of the pubis almost to its tip. The belly passes caudodorsally superficial to *M. pubocaudalis internus* and tapers slightly to a short, flat tendon. The insertion is on the calamus of the outermost rectrix immediately caudal to that of *M. lateralis caudae*.

M. PUBOCAUDALIS INTERNUS (P I)

FIGURE 9b-d

This muscle has a fleshy origin from the caudal portion of the ischium and from the entire dorsal surface of the pubis distal to the ischiopubic juncture. The fibers of the belly converge dorso-

medially and end on a tendinous intersection at about the level of the cloaca. Fleshy fibers continue dorsally from the intersection to insert on an aponeurotic sheet that connects the caudolateral border of the oval bone to the bases of the lateral four rectrices by distinct fasciculi. In addition a strap-like tendon penetrates this aponeurotic sheet between the caudalmost two fasciculi and inserts on the caudolateral edge of the blade of the pygostyle (lamina pygostyli) midway between the base and the tip.

The tendinous intersection mentioned above is continuous with a thin aponeurotic sheet, the supracloacal septum (septum supracloacale), that passes across the dorsal surface of the cloaca. Caudally this septum is overlain by the cranial portion of *M. sphincter cloacae*.

M. TRANSVERSUS CLOACAE (T C)

FIGURE 9b,c

This superficial, sheet-like muscle has two parts that have different origins and insertions but that are fused in their midportion. The larger, or ventral, part of this muscle arises by an aponeurosis from the caudalmost portion of the ischium and by fleshy fibers from the dorsal surface of the caudal third of the pubis. Parallel fibers pass caudomedially superficial to *M. pubocaudalis externus* and end on an aponeurosis just cranial to the distal end of the pubis. This aponeurosis continues ventral to the cloaca and meets the aponeurosis from the other side.

In *Eulampis* the dorsal belly is a small band of muscle, 4 mm long and 0.25 mm wide, that arises fleshy from the terminal process of the ilium (processus terminalis illi) just dorsal to the caudal margin of the origin of *M. iliofibularis*. The parallel fibers pass caudally superficial to the belly of *M. caudofemoralis*. The belly ends on a tendon that fuses with the dorsal edge of the aponeurosis of origin of the ventral part of the muscle. Caudally, the aponeurosis of the dorsal portion forms a belly that separates from the ventral portion and passes deep to *M. sphincter cloacae*, curves medially, and inserts on the caudodorsal wall of the cloaca.

The cranial belly is absent in *Patagona* and is represented only by an aponeurotic band. In *Heliodoxa* the cranial belly is markedly enlarged.

M. LEVATOR CLOACAE (L CL)

This muscle is absent in hummingbirds.

M. SPHINCTER CLOACAE (S CL)

FIGURE 9b

This band of muscle completely encircles the cloaca. Cranioventrally, fibers end on a ventral aponeurotic sheet that is continuous with the caudal aponeurosis of the main portion of *M. transversus cloacae*.

Muscles of the Forelimb

Muscles of the wing and shoulder of hummingbirds have received more attention than those of other body regions. Those associated with the shoulder were described in abbreviated form for the Long-tailed Hermit (*Phaethornis superciliosus*) by Fürbringer (1888), but with six exceptions, were not illustrated. An ostensibly complete description of the wing muscles of swifts, with rather detailed comparative notes for hummingbirds and other groups, was published by Buri (1900). This work included three figures that showed most of the wing and shoulder muscles of the Rufous Hummingbird (*Selasphorus rufus*). Cohn (1968) described and discussed only those wing muscles that she regarded as demonstrating differences in wing action between swifts and hummingbirds (primarily *Patagona gigas*), but that included 35 of the 40 muscles of the wing. George and Berger (1966) noted unusual features of certain wing muscles of *Eugenes fulgens* (based on Berger's dissections) but did not provide full descriptions or illustrations. A detailed study of variation of *M. tensor propatagialis, pars brevis* in hummingbirds and swifts was undertaken by Zusi and Bentz (1982), and of the structure of the humeroulnar pulley by Bentz and Zusi (1982).

The terms ectepicondylar process, lateral epicondyle, and dorsal supracondylar process have

been used for the points of attachment of *M. extensor metacarpi radialis* and *M. tensor propatagialis, pars brevis* on the humerus. We avoid those terms, and instead refer to the process of extensor metacarpi radialis and the tubercle of tensor propatagialis, pars brevis because these points are widely separated in the humerus of hummingbirds and because the homology with bony projections on the humerus of other birds is uncertain.

M. LATISSIMUS DORSI (L D)

FIGURES 10a-c, 15a

This muscle consists of two parts.

PARS CAUDALIS (L D CA).—This is a slightly fan-shaped muscle that arises by a thin aponeurosis from the spinous processes and interspinous ligaments of the first three thoracic vertebrae. The belly passes laterally superficial to *M. rhomboideus superficialis*, tapers to a narrow tendon, and inserts on a crest at the base of the bicipital crest just proximal to the origin of the dorsal head of *M. humerotriceps*.

PARS CRANIALIS (L D CR).—This is a thin band of muscle less than 1 mm wide. It arises by a thin aponeurosis from the spinous processes and interspinous ligaments of the last cervical and first thoracic vertebrae, passes laterally superficial to pars caudalis, and inserts on the humerus along the dorsomedial margin of *M. humerotriceps* lateral to the insertion of pars caudalis.

In *Calliphlox* the origin of pars cranialis is from the last cervical vertebra only. Buri (1900) stated that the origin (presumably of pars caudalis) was from the last cervical and first two thoracic vertebrae with "no distinct humeral insertion."

M. RHOMBOIDEUS SUPERFICIALIS (R S)

FIGURES 10a, 11, 13

This rhomboid-shaped muscle arises by an aponeurosis from the spinous processes and interspinous ligaments of the last two cervical and the first three thoracic vertebrae. Caudally the origin is between the aponeurosis of origin of *M. latis-*

simus dorsi, pars caudalis and *M. rhomboideus profundus*. The belly passes cranio-laterally to insert on the dorsal surface of the cranial half of the scapula.

Buri stated that the origin in the Trochilidae is from the 13th, 14th, and 15th vertebrae, which are the last two cervical and first thoracic vertebrae. According to Cohn (1968) the origin is from the last two cervical and first two thoracic vertebrae.

M. RHOMBOIDEUS PROFUNDUS (R P)

FIGURES 8*b*, 10*a*, 11

This muscle arises by an aponeurosis from the spinous processes and interspinous ligaments of the first three thoracic vertebrae deep to the caudal portion of *M. rhomboideus superficialis*. The belly passes caudolaterally to insert fleshy onto the dorsomedial surface of the caudal third of the scapula.

MM. SERRATI

M. serratus profundus (S P)

FIGURES 8*a*, 10*a*, 11

This muscle arises fleshy from the lateral portion of the floating rib of vertebra 14 and from the lateral portion of the first attached rib dorsal to its uncinatous process. The parallel-fibered fasciculi pass caudally to insert fleshy on the medial surface of the distal portion of the scapula just cranial and deep to the cranial half of the insertion of *M. rhomboideus profundus*.

M. serratus superficialis (S S)

FIGURES 8*a-c*, 10*a*, 11

This muscle consists of two independent bellies.

PARS CRANIALIS (S S CR).—This belly originates by two heads. The cranial head arises fleshy from the ventral portion of the floating rib of vertebra 14. The caudal head originates by fleshy fibers from the first attached rib at the level of its uncinatous process. The two parallel-fibered heads

pass craniodorsally deep to the belly of *M. scapulo-humeralis caudalis* and join on a thin aponeurosis that passes between the caudal portion of the two heads of *M. subscapularis*. The insertion is on the dorsomedial surface of the scapula just cranial to the midpoint of that bone.

PARS CAUDALIS (S S CA).—This belly is the larger portion of this two part complex. The fan-shaped belly arises fleshy from the lateral surfaces of the second, third, fourth, and fifth attached ribs. The fibers converge as they proceed dorsally to insert on the ventral and lateral edges of the caudal portion of the scapula. The caudal fibers have a fleshy insertion and the cranial fibers insert by a flat tendon.

Cohn (1968:83) stated that the insertion of pars cranialis was "displaced mediad onto the deep surface of the scapula by the great development of the external head of *M. subscapularis*." We found no lateral head to *M. subscapularis*.

M. SCAPULOHUMERALIS CRANIALIS (SH CR)

FIGURES 10*a-c*, 13, 15*a*

This small, fan-shaped muscle arises fleshy from the lateral and ventral surfaces of the cranial 2 mm of the scapula just cranial to the belly of *M. subscapularis*. The belly lies between the tendon of insertion of *M. latissimus dorsi, pars caudalis* and the belly of *M. subscapularis*. It passes between the two heads of *M. humerotriceps* and inserts fleshy in a caudal depression at the base of the bicipital crest.

M. SCAPULOHUMERALIS CAUDALIS (SH CA)

FIGURES 8*b*, 10*a, c, f*, 11, 12*b*, 13, 15*a*

This large unipennate muscle arises fleshy from the lateral and ventral surfaces of the blade of the scapula (*corpus scapulae: facies lateralis*). The central portion of the belly also arises from the medial surface of the scapula ventral to the attachment of *M. serratus superficialis, pars cranialis*. The origin extends from the caudal margin of the belly of *M. scapulo-humeralis cranialis* caudally to a point immediately cranial to the insertion of *M. serratus superficialis, pars caudalis*.

The fibers of the belly pass cranioventrally to insert on the medial surface of a large, superficial aponeurosis that ends on a short tendon of insertion. The insertion is on the ventral head of the bicipital crest of the humerus ventral to the insertion of *M. subcoracoideus*. The bicipital crest of the humerus in most trochiline hummingbirds is slightly or distinctly notched, resulting in a dorsal and a ventral head (see Figure 15a).

In *Thalurania* the muscle appears to be very large for the size of the bird.

MM. SUBCORACOSCAPULARES

M. subscapularis (SBS)

FIGURES 10d,f, 11, 15a

This fan-shaped muscle arises by fleshy fibers from the medial and ventral surfaces of the scapula. Caudally the belly is divided into lateral and medial heads by the insertion of *M. serratus superficialis*, pars cranialis. Thus, in hummingbirds the lateral head does not arise from the lateral surface of the scapula as it does in most other birds. The belly lies between the dorsal head of *M. subcoracoideus* and the belly of *M. scapulohumeralis caudalis*. It ends on a tendon that passes cranioventrally deep to *M. scapulohumeralis cranialis* and inserts on the dorsal head of the bicipital crest of the humerus just proximal to the tendon of insertion of *M. coracobrachialis caudalis*.

M. subcoracoideus (SBC)

FIGURES 10f, 11, 15a

The small, dorsal head of this muscle arises fleshy from the cranial end of the scapula cranial to the belly of *M. subscapularis*. The ventral head is much larger and bulbous. It arises fleshy from the dorsal surface of the sternocoracoidal process (processus lateralis) of the coracoid (coracoideum), from the medial surface of the distal half of the coracoid, from the lateral surface of the sternal spine (rostrum sterni), and from the lateral and ventromedial surfaces of the large sternocoracoidal ligament (ligamentum sternocoracoideum longum). These two heads join on a tendon

that inserts on the dorsal head of the bicipital crest of the humerus ventral to the insertions of *Mm. subscapularis* and *scapulohumeralis caudalis*.

M. CORACOBRAChIALIS CRANIALIS (C CR)

FIGURES 10e, 13, 15b

The muscle arises by fleshy, parallel fibers from the cranial surface of the head of the coracoid adjacent to the origin of *M. tensor propatagialis*, pars brevis. The 1 mm wide belly proceeds distally 4 mm to insert on the deltoid crest of the humerus (crista pectoralis) between the insertion of *M. pectoralis* and the belly of *M. deltoideus minor*. The belly lies deep to that of *M. tensor propatagialis*, pars brevis.

Cohn (1968:90) stated that "in both swifts and hummingbirds [this] is an inconspicuous muscle." We have found, however, that in hummingbirds this small muscle is unusually well developed for the size of the bird. In *Heliodoxa* it was relatively large.

M. CORACOBRAChIALIS CAUDALIS (C CA)

FIGURES 10f, 11, 15a

This muscle arises fleshy from the ventrolateral surface of the caudal third of the coracoid, from the entire lateral surface of the craniolateral process of the sternum, and from the lateral margin of the sternum caudally to the third rib attachment. Additional origin is by an aponeurotic sheet that originates on the sternum between the third and fifth rib attachments. The fan-shaped belly passes caudodorsally and ends on a tendon that passes between the tendons of insertion of *M. subcoracoideus* and *M. scapulohumeralis caudalis*. The tendon inserts on the dorsal head of the bicipital crest of the humerus.

M. PECTORALIS (P)

FIGURES 10d,e, 12a,b, 15b

This is the largest muscle of the body in all flying birds and it is especially large in humming-

birds. It consists of two parts. The large main belly has a fleshy origin from a limited area of the pectoral girdle: from the caudolateral portion of the sternum lateral to the corporal intermuscular line (linea intermuscularis [dorsalis]), from the keel of the sternum (carina sterni) ventral to the carinal intermuscular line (linea intermuscularis [ventralis]), and from the adjacent sternocoracoclavicular membrane (membrana sternocoracoclavicularis). In addition, fibers arise from a ventral, superficial aponeurosis that arises from the ventral edge of the keel and from a strong aponeurosis arising from the corporal intermuscular line. The fibers of the belly converge onto a flattened, internal tendon that inserts on the cranial surface of the deltoid crest of the humerus.

Deep and cranial to the main belly is an "anterior" component correctly described by Cohn (1968:86). It arises fleshy from the dorsal surface of the cranial 3 mm of the sternal keel, from the caudodorsal surface of the clavicle (clavicula) along most of its length, and from the sternocoracoclavicular membrane. The fibers of the belly pass laterally and converge onto a short tendon that fuses with the tendon of insertion of the main belly just prior to that tendon's insertion on the deltoid crest of the humerus. The belly of *M. tensor propatagialis*, pars longa, lies superficial to the cranial portion of this component.

Buri (1900) also stated that the presternal part of the muscle consisted of a stratum profundum and stratum superficiale. Pars propatagialis longus and brevis are absent in hummingbirds.

M. SUPRACORACOIDEUS (SUP)

FIGURES 10*b*, *e*, 12*b*, 13, 15*a*

This bipennate muscle is about half as large as *M. pectoralis*. It arises fleshy from the lateral surface of the sternum, between the corporal and carinal intermuscular lines, and from the caudoventral portion of the sternocoracoclavicular membrane. The fibers converge onto a strong tendon that passes dorsally through a coracoidal canal (canalis triosseus) and inserts on the caudal surface of the deltoid crest opposite the attach-

ment of *M. pectoralis*. The tendon contains a sesamoid at a point just after the tendon's emergence from the canal.

We found no sesamoid in *Metallura*. Development of the sesamoid in the genera examined appeared to vary. Cohn (1968) stated that a sesamoid was present in the "the most advanced" genera.

Buri (1900) saw the basal two-thirds of the ventral side of the coracoid as a site of origin.

M. STERNOCORACOIDEUS (SC)

According to Beddard (1898:85, 224) and Cohn (1968:92) this muscle is absent in hummingbirds. George and Berger (1966:316) did not find it in *Eugenes fulgens*, and it was absent in *Eulampis* as well as all other genera examined.

M. TENSOR PROPATAGIALIS (T P)

FIGURES 10*b*-*e*, 12*b*, 14*c*, 15*b*

This muscle consists of two parts.

PARS LONGA (T P L).—This part arises fleshy from the clavicle just ventral to the head. The small, parallel-fibered belly ends on a thin tendon (tendo longa) that passes distally in the propatagium. The tendon then fuses with the distal end of the belly of *M. extensor metacarpi radialis* and continues along the tendon of that muscle to insert on the extensor process of the carpometacarpus (processus extensorius). Dense fascia in this area may extend the functional insertion of this muscle onto the proximal portion of the alular phalanx (phalanx digiti alulae). As in most birds, pars brevis is much longer than pars longa.

PARS BREVIS (T P B).—This part arises by a short tendon from the dorsal edge of the head of the coracoid immediately dorsal to the origin of *M. coracobrachialis cranialis*. The nearly parallel fibers of the 5 mm long, 2.5 mm wide belly pass distally and end on a central aponeurosis that fuses with an internal aponeurosis of *M. extensor metacarpi radialis*. At this point of fusion tendo brevis is formed. This tendon of insertion of tensor propatagialis, pars brevis exhibits variation

within hummingbirds (Zusi and Bentz, 1982). The proximal portion of the tendon passes proximally superficial to the belly of *M. extensor metacarpi radialis* and its tendon of origin, and inserts on the tubercle of *pars brevis* (see remarks on terminology under "Muscles of the Forelimb"). The distal portion of the tendon proceeds distally along the dorsal surface of the belly of *M. extensor metacarpi radialis* so that in dorsal view the tendon appears to divide the belly of *M. extensor metacarpi radialis* into cranial and caudal portions. This tendon is bound to the superficial aponeurosis of the extensor and ultimately fuses with that muscle's tendon of insertion at about the distal end of the radius.

In *Glaucis* the proximal tendon of insertion of *M. tensor propatagialis, pars brevis* passes through the proximal portion of the belly of *M. extensor metacarpi radialis* rather than over the surface of that belly. The tendon emerges from the belly, passes distally superficial to the distal-most fibers of origin of the extensor, and inserts on the tubercle of *pars brevis*. This tendon is tightly bound to the tendon of origin of *M. extensor metacarpi radialis*. The distal portion of the tendon of *M. tensor propatagialis, pars brevis*, manifests itself as a broad, transparent, aponeurotic sheet on the surface of the distal half of the belly of *M. extensor metacarpi radialis*.

In *Metallura, Heliodoxa, Thalurania, Calliphlox*, and *Patagona* the distal portion of the tendon of this muscle is strong and free of the belly of *M. extensor metacarpi radialis*. Further, it passes along the cranial edge of that belly rather than along the dorsal surface.

Neither Buri (1900) nor Cohn (1968) mentioned variation in this muscle within hummingbirds.

M. DELTOIDEUS MAJOR (D MA)

FIGURES 10c, 13, 15a

Both deltoid muscles are greatly reduced in hummingbirds. *M. deltoideus major* arises by fleshy parallel fibers from the dorsolateral surface of the acromion of the scapula. The belly passes

distally caudal to the tendon of insertion of *M. supracoracoideus* and inserts fleshy on the distal end of the deltoid crest of the humerus just dorsal to the insertion of that tendon.

Neither Buri (1900) nor George and Berger (1966) found this muscle in hummingbirds. Cohn (1968) said that it was greatly reduced in both swifts and hummingbirds.

M. DELTOIDEUS MINOR (D MI)

FIGURES 10c, 13, 15b

The cranialmost fibers of this slender, parallel-fibered muscle arise fleshy from the caudal portion of the head of the clavicle, while the caudal fibers arise from the acromion of the scapula. Between these attachments the fibers arise from the coracoidal bar that closes the triosseal canal in hummingbirds. The belly passes laterally and crosses the tendon of *M. supracoracoideus* to insert on the deltoid crest of the humerus just medial to the insertion of *M. coracobrachialis cranialis*.

Cohn (1968:95) found the muscle to be two-headed in *Patagona*. We noted that this condition was variable within a species and we regard the difference as insignificant. Buri (1900) failed to find this muscle in several species of hummingbirds but found it to be "almost microscopic" in others.

M. BICEPS BRACHII (B B)

FIGURES 14a,b, 15b

Caput coracoideum arises by a flat tendon from the dorsolateral surface of the head of the coracoid just caudal to the origin of *M. tensor propatagialis, pars brevis*. The 4 mm tendon passes across the head of the humerus (*caput humeri*) and broadens as it gives rise to the belly deep to the tendon of insertion of *M. pectoralis*. Just proximal to the belly the tendon sends a branch ventrolaterally to a point about midway along the lateral edge of the bicapital crest, adjacent to the attachment of *M. humerotriceps*. This branch apparently represents a remnant of *caput*

humerales as described for other birds by George and Berger (1966:329).

The plump, spindle-shaped belly passes distally and ends on a narrow tendon that inserts on the proximal end of the ulna proximal to the insertion of *M. brachialis*. The tendon crosses the distal end of the radius and is loosely bound to it by connective tissue, but in our judgment there is no insertion on the radius.

George and Berger (1966:329) and Cohn (1968:98) reported that *caput humerale* was absent in hummingbirds. Buri (1900:534) stated that in Anna's Hummingbird (*Calypte anna*) the muscle inserts "also weakly on the radius."

M. TRICEPS BRACHII (T B)

FIGURES 10*b,c,f*, 13, 14*b,c*, 15*a,b*

This muscle has two well-developed parts that are often described as separate muscles.

M. SCAPULOTRICEPS (TS).—This muscle arises by semitendinous fibers from the cranio-lateral edge of the scapula just caudal to the glenoid cartilage (ligamentum coracoscapulare interosseum) of the scapula. The large belly gives rise to a strong tendon that encloses a large sesamoid, the patella ulnaris (os sesamoideum *M. scapulo-tricipitis*), passes deep to the ulnar anchor of *M. extensor metacarpi ulnaris*, and inserts on the caudodorsal surface of the ulna just distal to the olecranon.

M. HUMEROTRICEPS (TH).—This muscle is larger than the scapular head and consists of two parts. The ventral head arises fleshy from the distal edge of the bicipital crest between the shaft of the humerus and the ventral head of that crest. The dorsal head arises fleshy from the fossa pneu-motricipitalis of the humerus, and along the caudal surface of the humerus dorsolaterally toward the epicondylus dorsalis. These heads join to form a belly that extends almost to the elbow. The insertion is by semitendinous fibers on the olecranon of the ulna.

In *Metallura*, *Heliodoxa*, *Thalurania*, and *Patagona* the origin of the ventral head of *M. humerotriceps* is more extensive, arising also from the proximal edge of the bicipital crest.

We agree with Cohn (1968) that there are no scapular or humeral anchors in hummingbirds, although Buri (1900) reported an apparent humeral anchor in *Selasphorus rufus*.

M. EXPANSOR SECONDARIORUM (E S)

FIGURE 14*a,b*

In *Eulampis* this small triangular muscle arises by a short tendon from what remains of the humeroulnar pulley (trochlea humeroulnaris) (see Bentz and Zusi, 1982). The fibers fan out to insert fleshy on the calami of the proximal three secondaries with only a few fibers reaching the third. In addition, a poorly defined tendon from the cranio-lateral edge of the belly passes distally on the ventral surface of *M. flexor carpi ulnaris*, and sends a branch to the third secondary. The distal tendon then fuses with the surface of *M. flexor carpi ulnaris* as an aponeurotic sheet and sends branches to the more distal secondaries.

In *Heliodoxa*, *Thalurania*, and *Calliphlox* the muscle inserted on only two secondaries, although in the latter connective tissue may extend the functional insertion onto the third. The distal tendon is stronger and better defined in *Patagona*.

M. BRACHIALIS (B)

FIGURES 14*b*, 15*b*

This muscle exhibits only minor variations among birds (George and Berger, 1966:344). The short parallel-fibered muscle arises fleshy from the cranial surface of the humerus just dorsal to the attachment of the ventral collateral ligament (ligamentum collaterale ventrale). The belly passes distally parallel to the cranial edge of that ligament. The insertion is fleshy onto the brachial impression of the ulna between the two heads of the ulnar belly of *M. flexor digitorum profundus*.

M. PRONATOR SUPERFICIALIS (PR S)

FIGURES 14*a*, 15*b*

This muscle arises by a short tendon from a tubercle on the ventral surface of the shaft of the

humerus just distal to the midpoint of that bone. Distally the belly fans out and ends on an aponeurosis that inserts on the ventral surface of the radius along its distal half. The insertion is just cranial to the insertion of *M. pronator profundus*. The caudal margin of the belly may be fused a few millimeters to the accessory belly of *M. flexor digitorum profundus*.

Buri (1900) reported that there was no special tubercle of origin.

M. PRONATOR PROFUNDUS (PR P)

FIGURES 14a,b, 15b, 16b

The pronator profundus arises by a short tendon from the proximal portion of the epicondylus ventralis of the humerus. The tendon of origin fans out into a broad aponeurosis that covers the ventral surface of the proximal half of the muscle. The fan-shaped belly inserts fleshy on the ventral surface of the distal two-thirds of the radius between the bellies of *M. pronator superficialis* and *M. extensor longus digiti majoris*.

M. FLEXOR DIGITORUM SUPERFICIALIS (F D S)

FIGURES 14a,b, 15b

A fleshy belly is absent from this muscle in *Eulampis*. George and Berger (1966:350) also noted the absence of a belly in *Eugenes fulgens*, and Buri (1900) and Cohn (1968) reported the muscle absent in hummingbirds. The muscle is represented only by a small tendon that arises from the distal end of the humerus between the tendons of origin of *M. pronator profundus* and *M. flexor carpi ulnaris*. This tendon quickly joins the ligamentum humerocarpale.

In *Glaucis*, *Metallura*, *Heliodoxa*, and *Thalurania* the tendon extends somewhat further distally along the ligamentum humerocarpale.

M. FLEXOR DIGITORUM PROFUNDUS (F D P)

FIGURES 14a,b, 15b, 16b

In hummingbirds, as in other birds, this muscle originates from the ulna, but in addition it has a

large accessory belly from the humerus. The ulnar belly of this muscle arises fleshy by two heads from the ventral and cranial surfaces of the proximal end of that bone. These two heads quickly fuse to form a single, spindle-shaped belly that ends on a strong tendon at the distal end of the ulna. The accessory belly of this muscle arises by both fleshy and tendinous fibers from the cranio-ventral surface of the shaft of the humerus (corpus humeri), from the origin of *M. pronator superficialis* distally along the ventral edge of the humerus as far as the midpoint of the humeral origin of ligamentum collaterale ventrale. This belly ends on a short, flat tendon that fuses with an aponeurosis of the typical and smaller ulnar belly at about the midpoint of that belly.

The tendon of insertion passes distally through a fibrous loop (1, in Figures 14a,b, 16b) at the end of the ulna and proceeds into the manus. It passes deep to a ligament that extends from the distal end of the radius to the pisiform process (processus pisiformis), passes around that process, and extends distally in a groove on the cranial surface of the belly of *M. abductor digiti majoris*. The insertion is on the proximal end of the distal phalanx of the major digit (digitus major).

Buri (1900) stated that in *Metallura* there was a sesamoid in the tendon at the metacarpophalangeal joint. We did not find it.

M. FLEXOR CARPI ULNARIS (F C U)

FIGURES 14a,b,d, 15b, 16b

This large muscle arises by a well-developed tendon from the distalmost portion of the epicondylus ventralis of the humerus. The short tendon passes under a ligamentous sling (2, in Figure 14d) and what remains of the humeroulnar pulley (see Bentz and Zusi, 1982) and ends on a large belly (pars cranialis). The multipennate belly extends most of the length of the forearm and sends fleshy fasciculi (pars caudalis) to the bases of the proximal five secondary feathers before it ends on a short tendon. The insertion is on the proximal surface of the os carpi ulnare.

M. EXTENSOR METACARPI RADIALIS (E M R)FIGURES 10*c*, 14*a,c,d*, 15*a,b*, 16*a,b*

Buri (1900) stated of this muscle that a division into two heads was absent. Cohn (1968), however, noted an origin from the ectepicondylar process as well as from the surface of the humerus "distal and palmar" to that process. We too found that this large bipennate muscle consists of two heads. Caput dorsale arises by a short tendon from a well-developed dorsal process on the shaft of the humerus—the process of E M R (page 23). Caput ventrale arises by both fleshy and tendinous fibers from the humeral process and from the shaft of the humerus distal and ventral to the process of E M R. These two heads quickly fuse to form a single belly. The cranialmost fibers of this belly may arise fleshy from the proximal tendon of *M. tensor propatagialis pars brevis*. The belly extends most of the length of the forearm before tapering to a strong tendon that passes deep to a strong fascial loop (3, in Figure 14*c*) just before it inserts on the extensor process of the carpometacarpus.

In *Glaucis* the proximal fibers of the belly of *M. extensor metacarpi radialis* also arise fleshy from the dorsal surface of the process of E M R, and the proximal portion of the belly conceals the proximal portion of the tendon of *M. tensor propatagialis, pars brevis*. In *Patagona* a fascial slip arises from the tendon of *M. extensor metacarpi radialis* at a point where the tendon of *M. tensor propatagialis, pars brevis* joins that tendon. This slip passes caudally superficial to the distal ends of *M. extensor digitorum communis* and *M. extensor metacarpi ulnaris* and fuses with the fascia surrounding the calami of secondaries 2, 3, and 4, and their coverts.

M. EXTENSOR METACARPI ULNARIS (E M U)FIGURES 14*c*, 15*a,b*, 16*a*

This muscle has the most distal origin of all muscles arising from the distal end of the lateral surface of the humerus. The origin is by a tendon from the distal end of the epicondylus dorsalis of the humerus. The belly of the muscle extends distally and gives rise to a strong tendon about

three-fourths of the distance down the ulna. At the distal end of the ulna the tendon passes through a short deep groove under a transverse ligament (4, in Figures 14*c,d*) and continues distally cranial to the origin of *M. ulnometacarpalis dorsalis* to insert on the processus intermetacarpalis of the carpometacarpus proximal to the insertion of that muscle. From the proximal end of the belly a tendinous slip passes caudally. It contains a large sesamoid as it passes around the caudodorsal border of the ulna. On reaching the ventral side of the ulna, it fuses with what remains of the humeroulnar pulley and serves as a point of origin for *M. expansor secundariorum* (see Bentz and Zusi, 1982).

M. EXTENSOR DIGITORUM COMMUNIS (E D C)FIGURES 10*c*, 14*c*, 15*b*, 16*a*

This hypertrophied muscle has a 2 mm wide fleshy origin from the craniodorsal surface of the humerus just distal to the tubercle of *M. tensor propatagialis, pars brevis*. A few of the proximal fibers of the belly cross the proximal tendon of *M. tensor propatagialis, pars brevis*, concealing the insertion of that tendon. The distalmost fibers may arise by a short tendon (or ligament) from the patella ulnaris. The belly extends most of the length of the forearm and ends on a strong tendon that passes into the manus parallel and cranial to a ligamentous ulna-manus band (see under *M. extensor longus digiti majoris*). The tendon proceeds distally and slightly caudad in a shallow groove, often covered with bone, on the craniodorsal surface of the carpometacarpus deep to the tendon of *M. extensor longus digiti majoris* and to the ulna-manus band. It then turns caudally through a ligamentous loop (5, in Figure 16*a*) that extends from the proximodorsal corner of the first phalanx to the distal end of the carpometacarpus. The tendon then passes cranially superficial to the loop and encloses a small sesamoid just before it inserts on a tubercle on the cranial surface of the proximal end of the first phalanx of the major digit.

Both Buri (1900) and Cohn (1968) noted the presence of the ligamentous loop and the small

sesamoid. They also stated that no branch tendon is sent to the pollex as it is in most birds.

M. ULNOMETACARPALIS VENTRALIS (U V)

FIGURES 14a,b, 16b

This muscle arises by two equally well-developed heads. The caudal head arises fleshy from most of the caudoventral surface of the shaft of the ulna. The cranial head arises fleshy from most of the cranial surface of the ulna and fuses with the caudal head about one-third the distance along the forearm. The fibers of the unipennate bellies insert onto a large superficial aponeurosis that ends on a strong tendon. This tendon passes under a fibrous loop (1, in Figures 14a,b, 16b) at the distal end of the ulna and passes deep to a ligament that extends from the radius to the pisiform process. The tendon continues craniodorsally deep to the tendon of *M. extensor metacarpi radialis* and inserts on the craniodorsal edge of the proximal end of the carpometacarpus just proximal to the extensor process.

M. ECTEPICONDYLO-ULNARIS (EC)

FIGURES 14d, 15a,b

This muscle is relatively larger in hummingbirds than in most other birds. It arises by a wide, flat tendon from the dorsal aspect of the distal end of the humerus just proximal to the origin of *M. extensor metacarpi ulnaris*. The fan-shaped belly passes distally to insert fleshy on the craniodorsal surface of the middle third of the ulna.

M. SUPINATOR (SU)

FIGURES 14d, 15a,b

Although Buri (1900) considered this muscle to be weak in hummingbirds, we found it to be relatively well developed, as did George and Berger (1966). It arises by a narrow tendon from the distal end of the humerus just proximal to the origin of *M. ectepicondylo-ulnaris*. The belly fans out to insert fleshy on the craniodorsal surface of the proximal half of the radius cranial to the belly of *M. extensor longus digiti majoris*.

M. EXTENSOR LONGUS DIGITI MAJORIS (E L D M)

FIGURES 14b,d, 16a,b

Only pars proximalis is present in hummingbirds. This large muscle arises fleshy from most of the caudal surface of the radius and tendinous from the caudal edge of the proximal end of the radius. The proximal portion of the belly arises ventral to a flat, transverse, radio-ulnar ligament (ligamentum transversum radio-ulnare). At the distal end of the radius the bipennate belly ends on a strong tendon that passes under the interosseal radio-ulnar ligament (ligamentum interosseum radio-ulnare) and proceeds into the manus deep to the ulna-manus band (see below). It then passes between the branches of the ulna-manus band and encloses a sesamoid that is bound to the carpometacarpal-phalangeal joint capsule. The tendon continues distally and inserts on the cranial edge of the proximal end of the second phalanx of the major digit. Just prior to insertion the tendon encloses a second sesamoid that is also bound to the joint capsule. Much of the tendon between these two sesamoids is ossified, as noted by Buri (1900) and Cohn (1968).

The ulna-manus band is a strong ligament that arises from the dorsal surface of the distal end of the ulna and attaches to the bases of the proximal four primaries before branching at about the midpoint of the carpometacarpus. One branch passes cranially and inserts on the proximoventral corner of the first phalanx of the major digit. The other branch passes caudally, attaches to the bases of primaries five through eight, sends a short tendinous branch distally to the dorsal surface of the first phalanx, and fuses with the ossified portion of the tendon of insertion of *M. extensor longus digiti majoris*.

In *Glaucis* the tendon between the sesamoids was not ossified.

M. EXTENSOR LONGUS ALULAE (E L A)

FIGURE 14c,d

George and Berger (1966:370) stated that this muscle was rudimentary in *Eugenes fulgens* and that the belly was composed primarily of aponeu-

rotic fibers. Cohn (1968) did not mention it, and it is easily overlooked. In *Eulampis* it arises fleshy from the craniodorsal surface of the proximal end of the ulna deep to the ulnar attachment of ligamentum transversum radioulnare. The thin narrow belly passes distally and cranially between the bellies of *M. extensor longus digiti majoris* and *M. ectepicondylo-ulnaris* and ends on a thin tendon that inserts on the caudodorsal surface of the tendon of insertion of *M. extensor metacarpi radialis*.

M. ULNOMETACARPALIS DORSALIS (U D)

FIGURE 16a,b

In *Eulampis* this fan-shaped muscle arises by a short, thin tendon from the tuberculum retinaculi on the dorsal surface of the distal end of the ulna. The insertion is on the caudal surface of the carpometacarpus just proximal to the origin of *M. flexor digiti minoris*.

George and Berger (1966:371) reported this muscle absent in *Eugenes*. Cohn (1968:111) said that it was represented by a ligament in most hummingbirds, but that some fleshy fibers were present in *Patagona*. We found it present in all species examined.

M. ABDUCTOR ALULAE (AB A)

FIGURES 14a, 16b

This small muscle arises fleshy from the caudoventral surface of the distal end of the tendon of insertion of *M. extensor metacarpi radialis*. The spindle-shaped belly tapers to a fine tendon and inserts on the cranial edge of the alular phalanx along most of its length.

M. ADDUCTOR ALULAE (AD A)

FIGURE 16a

This is a very small muscle that has a fleshy origin from the cranial surface of the proximal end of the carpometacarpus just distal to the extensor process, and inserts fleshy onto the caudal surface of the alular phalanx along most of its length.

M. ABDUCTOR DIGITI MAJORIS (AB D M)

FIGURE 16a,b

The unipennate belly of this muscle arises fleshy from the cranioventral surface of the proximal two-thirds of the major metacarpal (os metacarpale majus). The belly tapers to a tendon that passes through a ligamentous loop (6, in Figure 16b) at the distal end of the major metacarpal, angles cranially, and inserts on the proximal end of the first phalanx of the major digit. The ligament contains a sesamoid.

M. INTEROSSEUS DORSALIS (I D)

FIGURE 16a

This is a small, bipennate muscle that occupies a portion of the intermetacarpal space (spatium intermetacarpale). It arises fleshy from the facing surfaces of the major and minor metacarpals, tapers to a fine tendon, and passes through a short bony canal (7, in Figure 16a) at the distal end of the carpometacarpus. The tendon encloses a small sesamoid just before inserting on the proximodorsal corner of the distal phalanx of the major digit. The caudal edge of the belly may be fused a few millimeters to the cranial edge of the belly of *M. flexor digiti minoris*.

M. INTEROSSEUS VENTRALIS (I V)

FIGURE 16a,b

This muscle is slightly larger than *M. interosseus dorsalis*. It arises fleshy from the caudoventral surface of the major metacarpal in the intermetacarpal space and in a depression of the caudoventral surface of the carpometacarpus, proximally as far as the pisiform process. The unipennate fibers attach along a fine tendon on the caudal edge of the belly. Beyond the belly this tendon passes to the dorsal side of the manus and proceeds through the same bony canal (7) as above, caudal to the tendon of insertion of *M. interosseus dorsalis*. The tendon continues distally along the caudodorsal border of the proximal phalanx of the major digit. The insertion is on

the caudal surface of the expanded tip of phalanx two of the major digit.

M. FLEXOR DIGITI MINORIS (F D M)

FIGURE 16a,b

This small muscle arises fleshy from most of the caudal surface of the minor metacarpal (os metacarpale minus). The unipennate belly ends on a fine tendon that inserts on the caudal surface of the midpoint of the minor digit (phalanx digiti minoris).

Muscles of the Hindlimb

We have found no description of the complete hindlimb myology of hummingbirds. Attention has previously been focussed on those muscles or features that were believed to have systematic importance, but full descriptions of even those muscles are lacking. Knowledge of these so-called "formula" muscles, originally discussed by Garrod (1873), has been expanded and summarized by George and Berger (1966:233-238). Of ten muscles that show interesting patterns of occurrence at the family and subfamily levels, hummingbirds are unique in having only one. These authors list hummingbirds (represented by *Eugenes*) as formula AC (i.e., caudofemoralis and ilioprochantericus medius present), but we found ilioprochantericus medius to be absent in the one phaethornithine genus and six trochiline genera we dissected. Cohn (1968) said it was also absent in *Eugenes* and several other genera she dissected.

Different relationships between the tendons of flexor digitorum longus and flexor hallucis longus in hummingbirds have been described by Gadow in Newton (1893-1896), by Lucas (1895), and redescribed by Gadow (1895). Our findings agree only with those of Gadow (1895).

M. ILIOTIBIALIS CRANIALIS (I CR)

FIGURES 17a, 18a

This muscle arises by an aponeurosis from the spinous process of the last free thoracic vertebra

and fleshy from the cranial margin of the ilium and the lateral surface of the cranialmost portion of the synsacrum just cranial to the ilium. The nearly parallel fibers converge as they approach the knee. The insertion is tendinous on the medial portion of the patellar crest (crista patellaris).

M. ILIOTIBIALIS LATERALIS (I L)

FIGURES 17a, 18a

Only the preacetabular portion of this muscle is present in *Eulampis*. This part arises by a broad aponeurosis that extends from the cranial portion of the dorsal iliac crest (crista iliaca dorsalis) caudally along the dorsal margin of the belly on M. ilioprochantericus cranialis as far caudad as the acetabulum. This aponeurosis gives rise to a nearly parallel-fibered belly at about the level of the acetabulum. The fibers of the belly pass distally caudal to the belly of M. ilioprochantericus cranialis and may be fused to the belly of M. femorotibialis medius for a few millimeters before tapering to a narrow tendon. This tendon passes over the cranio-lateral margin of the patella and inserts on the lateral portion of the patellar crest of the tibiotarsus.

MM. ILIOTROCHANTERICI

M. ilioprochantericus caudalis (IT CA)

FIGURE 17a,b

This bipennate muscle arises fleshy from the very shallow dorsal iliac fossa (fossa iliaca dorsalis). The fibers of the belly converge onto an internal aponeurosis that ends as a short tendon. The insertion is on the lateral surface of the trochanter of the femur (trochanter femoris).

M. ilioprochantericus cranialis (IT CR)

FIGURES 17a,b, 18b

This small band of parallel fibers arises fleshy from a process on the lateral edge of the preacetabular ilium just lateral to the cranial portion of M. ilioprochantericus caudalis. The dorsal margin

of the belly may be fused to the ventral margin of the belly of *M. iliotrochantericus caudalis* for a few millimeters. The belly proceeds caudally, penetrates the proximal portion of the belly of *M. femorotibialis externus*, and inserts tendinous on the lateral surface of the femur (os femoris) distal to the insertion of *M. ischiofemoralis*.

M. iliotrochantericus medius (IT M)

George and Berger (1966) stated that this muscle was present in *Eugenes fulgens*. Cohn (1968) reported that it was absent in all the hummingbirds she dissected, including *Eugenes*. We did not find it in *Eulampis* or in the other genera we examined.

MM. FEMOROTIBIALES

M. femorotibialis externus (FT E)

FIGURE 17a-c

This muscle arises fleshy from the lateral surface of most of the shaft of the femur beginning just proximal to the insertion of *M. iliotrochantericus cranialis*. The cranial border of this muscle is fused to the caudal margin of the belly of *M. iliotrochantericus medius*. The unipennate belly ends on an aponeurosis near the distal end of the femur. The insertion is on the lateral cnemial crest (crista cnemialis lateralis) and on most of the patellar crest superficial to the insertion of *M. femorotibialis medius*.

M. femorotibialis medius (FT M)

FIGURES 17b, 18a,b

This muscle arises fleshy from the cranial and medial surfaces of the femur throughout most of its length. The proximolateral surface of the muscle is covered by a superficial aponeurosis. The unipennate belly ends on a large tendon that encloses a sesamoid (the os patella) just before it inserts on the patellar crest of the tibiotarsus deep and medial to the insertion of *M. femorotibialis externus*.

M. femorotibialis internus (FT I)

FIGURE 18a,b

This muscle arises fleshy from most of the caudomedial surface of the femur beginning at the level of the insertion of *M. pubo-ischio-femoralis*. The unipennate belly widens as it passes distally and ends on a tendon that inserts on the medial surface of the cranial cnemial crest (crista cnemialis cranialis) of the tibiotarsus.

In *Metallura* and *Calliphlox* *M. pubo-ischio-femoralis* inserts well below the proximal end of *M. femorotibialis internus*.

M. ILIOFIBULARIS (IF)

FIGURE 17a-c

This triangular muscle arises cranially by an aponeurosis from a point just dorsal to the acetabulum and by fleshy fibers from the dorsolateral iliac crest (crista iliaca dorsolateralis). The belly passes distally, tapers to a strong tendon, and proceeds through the iliofibular loop (ansa *M. iliofibularis*). The insertion is on a tubercle (tuberculum m. iliofibularis) on the distal end of the fibula. As in most birds, the iliofibular loop (formerly "biceps loop") is composed of three arms. Two of these arise a short distance apart from each other from the lateral surface of the distal end of the femur. The smaller fibular arm joins these arms at their distal end.

In *Metallura*, *Thalurania*, and *Calliphlox* there are two heads of origin. The cranial head arises by an aponeurosis from a small area dorsal to the acetabulum. The caudal head arises by fleshy fibers from the dorsolateral iliac crest. These two heads join about one-fourth the distance down the femur. An artery (arteria ischiadica) and a nerve (nervus ischiadicus) pass between the two heads. The main difference between the two-headed condition and that of *Eulampis* is that, in the latter, the ischiadic nerve is covered by a thin sheet of muscle fibers.

M. FLEXOR CRURIS LATERALIS, PARS PELVICA
AND PARS ACCESSORIA

George and Berger (1966:404) stated that both parts of this muscle were absent in the Apodi-

formes. Neither was present in *Eulampis* or the other species studied herein.

M. ISCHIOFEMORALIS (ISF)

FIGURE 17b

This fan-shaped muscle arises fleshy from the lateral surface of the ischium caudal to the ilioischiatric foramen (foramen ilioischadicum), and from a thin membrane overlying the ischiopubic fenestra (fenestra ischiopubica). The belly passes cranially and ends on a stout tendon that inserts on the lateral surface of the shaft of the femur just distal to the tendon of insertion of *M. obturatorius medialis*.

M. FLEXOR CRURIS MEDIALIS (F CR M)

FIGURES 17a, 18a,b

This muscle arises fleshy from the lateral edge of most of the ischium and lies caudal to the belly of *M. iliofibularis*. The parallel fibers pass distally obscuring most of *M. pubo-ischio-femoralis* and end on a flat tendon. This tendon passes between the widely separated *pars medialis* and *pars intermedia* of *M. gastrocnemius*. The tendon divides and sends a ventromedial branch to its insertion on the caudal edge of the belly of *M. gastrocnemius, pars medialis*. The proximolateral portion of the tendon inserts on the proximomedial surface of the tibiotarsus and on the distal end of the medial collateral ligament (ligamentum collaterale mediale).

M. CAUDOFEMORALIS (CF)

FIGURES 9a-d, 17a,b, 18b

This muscle arises by a thin tendon from the caudal surface of the femur about 3 mm from the proximal end of the bone. The nearly parallel-fibered belly passes caudodorsally cranial to the belly of *M. flexor cruris medialis* and then passes between the cranial and caudal portions of *M. transversus cloacae*. Ventrolateral to *M. depressor caudae*, about half way along that muscle, the belly tapers to a thin tendon that inserts on the

lateral tip of an oval bone (see tail musculature) on the ventral surface of *M. depressor caudae*. A ligament joins the oval bone to the lateral process of the pygostyle.

M. PUBO-ISCHIO-FEMORALIS (PIF)

FIGURES 17a,b, 18a,b

As noted by George and Berger (1966:414), this muscle arises as a single muscle mass. There are, however, two separate insertions. The muscle arises by fleshy and tendinous fibers from the ventral and lateral edges of the cranial two-thirds of the pubis as far caudad as the ischiopubic juncture. The strap-shaped belly then passes cranioventrally. The cranial fibers insert fleshy onto the caudal surface of the femur from a point just distal to the origin of *M. caudofemoralis* distally to the medial condyle (condylus medialis) of the femur. The caudal fibers insert fleshy on the belly and tendon of origin of *M. gastrocnemius pars intermedia*.

In *Metallura* and *Calliphlox* the proximal fibers of insertion begin well distal to the proximal limit of origin of *M. femorotibialis internus*.

M. OBTURATORIUS LATERALIS (O L)

FIGURE 17b

This muscle consists of two parts in many birds. *Pars dorsalis* is not found in *Eulampis jugularis*.

PARS VENTRALIS (O L V).—This part arises by fleshy parallel fibers from the proximal end of the pubis ventral to the obturator foramen (foramen obturatum). The small, 1 mm-long belly passes cranio-laterally to insert on the femur distal to the insertion of *M. obturatorius medialis*. A few fibers of the dorsal margin of the belly may be fused to the tendon of *M. obturatorius medialis*. George and Berger (1966:415) apparently also found only *pars ventralis* in *Eugenes*.

M. OBTURATORIUS MEDIALIS (O M)

FIGURES 9b, 17b, 18a

This bipennate muscle arises fleshy from the dorsomedial surface of the pubis and the ventro-

medial edge of the ischium and covers the medial surface of the membrane that closes the ischio-pubic fenestra. The fibers converge onto an internal aponeurosis that becomes a stout tendon. The tendon and fleshy fibers ventral to the tendon pass laterally through the obturator foramen. The insertion is on the caudolateral surface of the femur just proximal to the tendon of *M. ischiofemoralis*.

M. ILIOFEMORALIS INTERNUS (IF I)

This muscle is absent in all species studied herein. George and Berger (1966:418) did not find it in *Eugenes*, and Cohn (1968:122) stated that it was absent in hummingbirds.

M. ILIOFEMORALIS EXTERNUS (IF E)

This muscle also is absent in the species studied herein. George and Berger (1966:393) reported it absent in *Eugenes*.

M. GASTROCNEMIUS (G)

FIGURES 17a,c, 18a, 19b, 20a

This muscle consists of three parts.

PARS LATERALIS (G L).—This part has its origin by a short tendon from the lateral surface of the distal end of the femur just proximal to the trochlea fibularis. The tendon is fused to the lateral femoral arm of the iliofibular loop. The belly extends about half the distance down the crus and ends on a tendon that forms the lateral portion of the common tendon of this muscle.

PARS MEDIALIS (G M).—This part arises fleshy from the cranial cnemial crest of the tibiotarsus, from the medial surface of the proximal one-half of the tibiotarsus and from the medial surface of the investing aponeurosis of *M. tibialis cranialis*. The belly extends most of the distance down the crus before tapering to an aponeurosis that forms the medial portion of the common tendon.

PARS INTERMEDIA (G I).—This part arises by both fleshy and tendinous fibers from an area just proximal to the internal femoral condyle and

deep to the distal portion of the belly of *M. femorotibialis internus*. The belly extends about one-third the distance down the crus and ends on a tendon that forms the central portion of the common tendon. Much of the surface of the unipennate bellies of *pars lateralis* and *pars medialis* is covered by superficial aponeuroses. In *pars intermedia* the aponeurosis covers the deep or cranial surface of the belly. These aponeuroses converge to form the *tendo m. gastrocnemius* that passes distally over the tibial cartilage (*cartilago tibialis*) to which it is loosely attached. The insertion is on the caudal surface of the hypotarsus.

In some specimens of *Glaucis*, *pars medialis* exhibits a poorly defined patellar band. The patellar band (Raikow, 1976:784) is a band of muscle that arises from the patellar ligament (*ligamentum patellae*) and proceeds around the cranial surface of the knee. In *Glaucis* a few fibers may arise from the patellar ligament and pass over the cranial cnemial crest onto the main belly of *pars medialis*.

M. FIBULARIS LONGUS (F L)

This muscle is absent in the species studied herein. George and Berger (1966:429) stated that it was absent in the Apodiformes.

M. TIBIALIS CRANIALIS (T CR)

FIGURES 17b,c, 18a,b, 20a,c

This muscle lies along the cranial and craniolateral margin of the crus and consists of two heads. *Caput tibiale* arises fleshy from the patellar crest of the tibiotarsus and tendinous from the cranial cnemial crest. Fibers of the proximomedial edge of the belly arise from the surface of *M. extensor digitorum longus*. The smaller, caudolateral head, *caput femorale*, arises by a short tendon from the distal end of the lateral femoral condyle (*condylus lateralis*). These heads pass distally in close apposition and fuse to form a common tendon near the distal end of the tibiotarsus, where the tendon passes through a transverse ligamentous loop (*retinaculum extensorium tibi-*

otarsi: 8, in Figures 17*b,c*, 18*b*). The insertion is on a tubercle (tuberositas m. tibialis cranialis) on the cranial surface of the tarsometatarsus about one-third the distance down that bone.

M. FIBULARIS BREVIS (F B)

FIGURES 17*b,c*, 20*c*

This muscle has a fleshy and tendinous origin from the distal tip of the fibula. It also arises by fleshy fibers from the lateral and cranio-lateral surfaces of the tibiotarsus distal to the fibula. The unipennate belly extends to the distal end of the tibiotarsus where a short tendon is formed. The tendon crosses the intertarsal joint and inserts on a prominent lateral tubercle (tuberositas M. fibularis longus) on the proximal end of the tarsometatarsus.

In *Metalhura* the tendon of insertion is longer, forming about two-thirds the distance down the crus.

M. EXTENSOR DIGITORUM LONGUS (E D L)

FIGURES 17*c*, 18*b*, 19*a*, 20*a,d,e*

This bipennate muscle arises fleshy from the patellar crest, tendinous from the cranial cnemial crest, from the proximal half of the cranio-lateral and cranio-medial surfaces of the tibiotarsus, and from the cranial surface of the shaft of the fibula. The belly extends three-fourths the distance down the crus and ends on a strong tendon that passes under the retinaculum extensorium tibiotarsi. It then proceeds through a bony canal (pons supratendineus) at the distal end of the tibiotarsus, crosses the intertarsal joint, and proceeds through a second bony canal at the proximal end of the tarsometatarsus, medial to the tendon of M. tibialis cranialis. The tendon trifurcates about two-thirds the distance down that bone, sending branches to all of the foretoes. With the exception of the branch to digit III none of these branches divides any further. Each passes along the dorsal surface of the phalanges and inserts on the proximal end of the ungual phalanx (phalanx distalis) of its respective digit. The branch to digit III does

bifurcate and sends a small branch to insert on the proximal end of the third phalanx. The main insertion is the same.

M. FLEXOR PERFORANS ET PERFORATUS DIGITI III (F P P D 3)

FIGURES 17*b,c*, 19*a,b*, 20*d*

This muscle arises by a short tendon from the lateral surface of the lateral femoral condyle, by fleshy fibers from the lateral surface of the head of the fibula, and from the lateral surface of the distal end of that bone. The muscle also arises from an aponeurosis between the bellies of M. fibularis brevis and M. flexor digitorum longus. The slender, unipennate belly ends on a tendon that passes through a large, caudolateral canal of the tibial cartilage in company with M. flexor perforans et perforatus digiti 3 and M. flexor perforatus digiti IV, and proceeds distally lateral to the hypotarsus. The tendon continues distally along the tarsometatarsus, becomes thickened at the distal end of that bone and then perforates the tendon of M. flexor perforatus digiti III. The tendon then bifurcates to allow for the passage of the branch tendon of M. flexor digitorum longus. The two flat branches thus formed insert on the lateral and medial corners of the proximal end of the third phalanx of digit III.

M. FLEXOR PERFORANS ET PERFORATUS DIGITI II (F P P D 2)

FIGURES 17*b,c*, 19*a,b*, 20*d*

This small, spindle-shaped muscle lies just caudal to M. flexor perforans et perforatus digiti III and arises by a short tendon from the proximal portion of the lateral femoral condyle. Three other muscles share this origin: M. flexor perforatus digiti II, M. flexor perforatus digiti III, and M. flexor perforatus digiti IV. The belly extends one-third the length of the crus and ends on a wide, flat tendon that becomes thread-like. It passes through a separate canal of the tibial cartilage and then through a lateral groove or canal of the hypotarsus caudal to the canal of M.

flexor digitorum longus. The tendon continues distally along the caudal surface of the tarsometatarsus and passes deep to the metatarsus hallucis (os metatarsale 1). Just distal to that bone the tendon perforates the tendon of *M. flexor perforatus digiti II* and then becomes thickened at the base of the tarsometatarsus. It then splits to allow for the passage of the branch tendon of *M. flexor digitorum longus*. The two resulting flattened branches insert on the lateral and medial surfaces of the proximal end of the second phalanx of digit II.

M. FLEXOR PERFORATUS DIGITI IV (F P D 4)

FIGURES 17*b,c*, 19*a,b*, 20*c-e*

This muscle has a common tendinous origin with *M. flexor perforatus digiti III* from the lateral femoral condyle. The spindle-shaped belly passes distally cranial to *M. flexor perforatus digiti III* and ends on a thin tendon that passes through a large caudolateral canal of the tibial cartilage in company with *M. flexor perforatus digiti III* and *M. flexor perforans et perforatus digiti III*. The tendon passes along the caudolateral surface of the tarsometatarsus, becomes thickened, and bifurcates at about the midpoint of phalanx one. The branch tendon of *M. flexor digitorum longus* passes between the two resulting branches that insert on the lateral and medial corners of the proximal end of the third phalanx of digit IV.

In *Thalurania* the belly is very slender and needle-like.

M. FLEXOR PERFORATUS DIGITI III (F P D 3)

FIGURES 17*b,c*, 19*a,b*, 20*d*

This muscle arises by a long, narrow tendon from the lateral femoral condyle—an origin that it shares with *M. flexor perforans et perforatus digiti II*, *M. flexor perforatus digiti II*, and *M. flexor perforatus digiti IV*. This tendon passes medial to the tendon of insertion of *M. iliofibularis* and forms a spindle-shaped belly at the distal end of the proximal one-fourth of the crus. The belly is fused along its lateral margin to the belly by *M. flexor perforatus digiti IV*. The belly ex-

tends distally and ends on a tendon that passes through a large caudolateral canal of the tibial cartilage, lateral to the hypotarsus, and along the caudal surface of the tarsometatarsus. The flattened tendon divides at the distal end of the thickened portion of *M. flexor perforans et perforatus digiti III* and is perforated by the tendons of the muscle and of *M. flexor digitorum longus*. The insertion is on the medial and lateral surfaces of the proximal end of the second phalanx of digit III.

M. PLANTARIS (PL)

George and Berger (1966:442) reported this muscle absent in *Eugenes*. It is also absent in all species examined in this study.

M. FLEXOR PERFORATUS DIGITI II (F P D 2)

FIGURES 17*c*, 19*a,b*, 20*d*

This muscle arises by a long, thread-like tendon from the cranial edge of the common tendon of origin of *M. flexor perforatus digiti III*, *M. flexor perforans et perforatus digiti II*, and *M. flexor perforatus digiti IV*. This tendon gives rise to a tiny, spindle-shaped belly that is bounded by the distal portions of the bellies of *M. flexor hallucis longus*, *M. flexor perforatus digiti IV*, and *M. flexor digitorum longus*. The belly ends on a slender tendon that passes through a separate canal in the tibial cartilage, continues lateral to the hypotarsus in a groove or canal, and passes down the tarsometatarsus deep to the metatarsus hallucis. The tendon bifurcates and is perforated by the proximal end of the thickened portion of *M. flexor perforans et perforatus digiti II*. The two tendons insert on the lateral and medial surfaces of the proximal end of the first phalanx of digit II. The medial tendon is strongly developed but the lateral one is weak and easily overlooked.

M. FLEXOR HALLUCIS LONGUS (F H L)

FIGURES 17*b,c*, 18*b*, 19*a-c*, 20*d,e*

This large muscle arises by fleshy fibers from a depression just proximal to the lateral condyle of

the femur and medial to the iliofibular loop, and by a tendon from the medial border of that depression. The tendon of origin continues distally as a broad aponeurosis on the cranial surface of the belly. Most of the caudal surface of the belly is covered by an aponeurosis that extends distally to become the tendon of insertion. The large fusiform belly extends most of the length of the crus and ends on a tendon that passes cranial to the tibial cartilage and lateral to the base of the hypotarsus. As it continues distally it sends a strong, tendinous connection to the branch tendon of *M. flexor digitorum longus* to digit II, just distal to the point of trifurcation. A series of thinner tendinous connections is sent to the branch tendons of digits III and IV across the point of their bifurcation. The main tendon continues caudally on to the ventral surface of the hallux. The insertion is on the proximal end of the unguis phalanx of the hallux.

M. FLEXOR DIGITORUM LONGUS (F D L)

FIGURES 17c, 18b, 19a-c, 20c-e

The lateral head of this muscle arises fleshy from the entire caudal surface of the head (caput fibulae) and shaft (corpus fibulae) of the fibula. The larger medial head arises fleshy from a crest on the proximocaudal border of the tibiotarsus and from the caudal surface of the proximal half of that bone. These heads fuse after independent courses of a few millimeters. The large, bipennate belly extends three-fourths of the distance down the crus and ends on a strong tendon that passes cranial to the tibial cartilage. The tendon continues through a bony canal in the base of the hypotarsus and as it proceeds distally, trifurcates and receives the short tendinous connections from the tendon of *M. flexor hallucis longus* described above.

The branch to digit II perforates the tendon of *M. flexor perforatus digiti II*, passes deep to the thickened portion of the tendon of *M. flexor perforans et perforatus digiti II*, and then perforates that tendon. The tendon continues distally along the ventral surface of digit II and inserts on the proximal end of the unguis phalanx of that

digit. The branch to digit III perforates the tendons of *M. flexor perforatus digiti III* and *M. flexor perforans et perforatus digiti III*, and continues distally along the ventral surface of digit III to insert on the proximal end of the unguis phalanx of that digit. The branch to digit IV perforates the tendon of *M. flexor perforatus digiti IV* at the proximal end of the first phalanx. It continues distally to insert on the proximal end of the unguis phalanx of digit IV. A single vinculum arises from the deep surface of each branch tendon. In each case the vinculum inserts on the distal end of the penultimate phalanx of the digit.

In *Heliodoxa* the belly extends the entire length of the crus.

M. FLEXOR HALLUCIS BREVIS (F H B)

FIGURE 20a-c,e

This small muscle arises fleshy from the entire medial surface of the hypotarsus, from the distal portion of the lateral surface of the hypotarsus, and from the caudomedial surface of the proximal 1 mm of the 5 mm long tarsometatarsus. The muscle also arises from the distal end of the tendon of insertion of *M. gastrocnemius*. The belly overlaps onto the lateral surface of the tarsometatarsus without arising from it. The bipennate belly tapers to a strong tendon that passes between the metatarsus hallucis and the tarsometatarsus and inserts on the proximal end of the hallux lateral to the tendon of insertion of *M. flexor hallucis longus*.

M. EXTENSOR HALLUCIS LONGUS (E H L)

FIGURE 20a,b,e

This small muscle arises from a tubercle on the proximal end of the medial surface of the tarsometatarsus cranial to the belly of *M. flexor hallucis brevis*.

PARS PROXIMALIS (E H L P).—This 4 mm belly passes distally and ends on a strong tendon that proceeds under a fibrous loop (9, in Figure 20b), and continues distad along the dorsal surface of the hallux. The insertion is on the dorsal surface of the proximal end of the unguis phalanx of the hallux.

PARS DISTALIS (E H L D).—This tiny distal belly is also present. It arises fleshy from the caudomedial surface of the tarsometatarsus between the metatarsus hallucis and the belly of *M. flexor hallucis brevis*. The belly passes distally along the dorsal surface of the metatarsus hallucis, passes through the fibrous loop, and ends on a thin tendon. The insertion is on the dorsal surface of the proximal end of the hallux.

In both *Metallura* and *Thalurania* the distal belly is unusually large for the size of the bird and in the former the origin has expanded proximally along the tarsometatarsus. The distal belly is barely discernible in *Glaucis*.

M. ADDUCTOR DIGITI II (AD D 2)

FIGURE 20*c, e*

This bipennate muscle arises fleshy from most of the caudolateral surface of the tarsometatarsus beginning just distal to the insertion of *M. fibularis brevis*. The small belly extends the entire length of the tarsometatarsus and ends on a well-developed tendon that passes medially deep to the metatarsus hallucis and the flexor tendons, and inserts on the proximolateral corner of the first phalanx of digit II.

In *Heliodoxa* the belly is shorter, extending only half the length of the tarsometatarsus.

Subcutaneous Muscles

Four of the five muscles described below have skeletal attachments on the cranium, clavicle, or pubis. The other attaches on the tendon of insertion of *M. pectoralis* and thus has an indirect attachment on the humerus. Our findings are in essential agreement with the descriptions of these muscles for *Phaethornis superciliosus* by Fürbringer (1888). Differences are noted below.

M. CUCULLARIS CAPITIS (C C)

FIGURES 2*a, 4c*

This muscle lies in a depression in the dorso-lateral surface of the cranium that begins in the

interorbital region and extends caudolaterally along the rim of the orbit. The slender, parallel-fibered belly arises fleshy from the rostral end of this depression, passes caudally superficial to *M. adductor mandibulae externus temporalis*, and bifurcates.

PARS INTERSCAPULARIS (C C I).—This dorsal part passes caudally on the skin of the neck and inserts on the interscapular feather tract (pteryla interscapularis).

PARS PROPATAGIALIS (C C PR).—The fibers of this part pass caudally in the ventral skin of the neck. Just cranial to the belly of *M. tensor propatagialis, pars longa*, the belly ends and a weak tendon is formed. This tendon passes caudally superficial to the belly of that muscle and inserts on the lateral side of the anterior component of *M. pectoralis*.

In some forms, e.g., *Thalurania*, this tendon continues caudally across the anterior component and inserts on the craniolateralmost corner of the main portion of *M. pectoralis*. Fürbringer (1888) did not mention the tendon of this muscle, and he stated that the insertion was on the clavicle and the shoulder fascia.

M. PECTORALIS SUBCUTANEA (P S)

FIGURES 9*b, 12a*

This muscle has two parts.

PARS ABDOMINALIS (P S A).—This part consists of a 2 mm wide belly that arises by a thin, broad tendon from the distal end of the pubis just lateral to the midline. The belly passes cranially and inserts on the skin near the caudal end of the lateral thoracic feather tract.

PARS THORACICA (P S T).—This part arises by a tough aponeurosis from the medial surface of the tendon of insertion of *M. pectoralis*. The aponeurosis passes caudolaterally onto the fleshy surface of *M. pectoralis* where it gives rise to a narrow belly. The belly passes ventrolaterally and fans out to a width of 10 mm as it inserts on the skin near the middle three-fifths of the lateral thoracic feather tract (pteryla pectoralis).

M. CUCULARIS CERVICIS, PARS CLAVICULARIS
(C CE C)

FIGURE 10*d*

This small muscle arises fleshy from the head of the clavicle. It passes dorsally medial to the head of the coracoid and then caudally, superficial to *M. rhomboideus superficialis*. The insertion is on the skin of the interscapular feather tract just lateral to the midline. It does not meet its counterpart from the other side at the midline.

Fürbringer (1888) described the muscle as attaching on the skin of the proximal two-thirds of the neck.

M. SERRATUS SUPERFICIALIS, PARS METAPATAGIALIS
(S S M)

This muscle is absent in the species studied herein. According to Cohn (1968) it is absent in all hummingbirds.

M. CONSTRICTOR COLLI, PARS INTERMANDIBULARIS
(CO C I)

FIGURE 4*a*

This is the rostralmost portion of *M. constrictor colli*. It arises from the transverse nuchal crest immediately rostral to the dorsal portion of *M. serpihyoideus*, and dorsomedially on the crest to its intersection with *M. stylohyoideus*. The thin, strap-like muscle passes ventrally and then medially as it becomes bound to the skin of the throat and meets its opposite member on a median raphe just caudal to *M. serpihyoideus*. This is probably *M. cucullaris caput* portion of Bock et al. (1973).

Discussion

The main purpose of this paper is to provide background data for future studies of phylogeny and adaptation of hummingbirds. Toward that end we have described all muscles attaching on the axial, appendicular, and hyoid skeletons that are associated with the eye, jaws, tongue, hyoid,

trachea, vertebral column, trunk, abdomen, tail, appendages, and integument. In hummingbirds these muscles number 132, using the terminology of Baumel et al. (1979). Here we will isolate some of the features that are likely to play an important role in future research.

SYSTEMATIC STUDIES WITHIN THE TROCHILIDAE.—The following features may prove particularly useful in defining subgroups within hummingbirds. When referring to relative differences in size we list only major differences.

Hyoid: The insertion of *M. serpihyoideus* as a single layer, or as two partially overlapping layers.

Jaws: The relative size and internal structure of *M. adductor mandibulae externus rostralis temporalis*; relative development of the belly and the extent of insertion of pars ventralis of the same muscle; the relative size and extent of insertion of *M. pterygoideus dorsalis medialis*.

Neck: The pattern of vertebral origins of *M. longus colli dorsalis cranialis*, *M. rectus capitis lateralis*, and *M. complexus*.

Tail: Relative development of the belly of the dorsal portion of *M. transversus cloacae*.

Wing: Patterns of variation in the proximal and distal tendons of *M. tensor proptagialis*, pars brevis (Zusi and Bentz, 1982); the extent of the fleshy belly of *M. extensor metacarpi radialis* at its origin; presence or absence of a sesamoid in the tendon of *M. supracoracoideus*; configuration of insertions of *M. subscapularis*, *M. subcoracoideus*, *M. coracobrachialis caudalis*, *M. scapulo-humeralis caudalis*, and *M. humerotriceps* in relation to a notched versus an unnotched bicapital crest (Cohn, 1968).

Leg: Extent of insertion of *M. pubo-ischio-femoralis*; one versus two heads of origin of *M. iliofibularis*; presence or absence of the patellar band of *M. gastrocnemius*; relative length of the tendon of *M. fibularis brevis*; relative development of the distal belly of *extensor hallucis longus*; extent of origin of *M. adductor digiti II*.

PHYLOGENETIC RELATIONSHIPS OF THE TROCHILIDAE.—The search for features that are unique to hummingbirds or to hummingbirds and only one or a few other groups must involve broad com-

parisons, many of which cannot be made at this time for lack of published information. Instead, we shall focus on some peculiarities of hummingbirds that are brought to light by comparison with oscine Passeriformes, for which information on all muscles from at least a few species is available (Shufeldt, 1890; Beecher, 1953; Fiedler, 1951; Bock, 1972; Bock and Morioka, 1971; Bock et al., 1973; Richards and Bock, 1973; Engels, 1938; Palmgren, 1949; Hudson, 1937; Hudson and Lanzillotti, 1955; Raikow, 1976, 1977, 1978; Berger, 1956, 1957). We also comment on the Apodidae insofar as such information is available from Buri (1900), Hudson (1937), George and Berger (1966), Cohn (1968), Morioka (1974), and Burton (1971), and on birds in general from George and Berger (1966) and Hofer (1950).

Hyoid: Origin of *M. serpihyoideus* from the exoccipital region of the skull in hummingbirds differs from that of most oscines, in which the muscle attaches on the base of the cranium or lower jaw. Hummingbirds also differ from oscines in having the interceratobranchialis insert on the basibranchiale caudale whereas in oscines the muscle forms a sling without bony attachment. *M. hypoglossus obliquus* originates from the basibranchiale rostrale in hummingbirds; in oscines it may originate from that bone or from an unattached sling. Unlike the oscines, tracheal and laryngeal muscles of hummingbirds have no attachment on the hyoid apparatus.

Jaws: In hummingbirds the absence of *M. adductor mandibulae externus caudalis* and the unusual development of *M. adductor mandibulae caudalis* agrees with swifts, but not with oscines and many other birds. In both swifts and hummingbirds the structure of the pterygoideus complex is relatively simple, but the two groups differ in the form of *M. pterygoideus ventralis lateralis* and *M. pterygoideus dorsalis medialis* (see Morioka, 1974).

Neck: The structure of *M. splenius capitis* in swifts, crested-swifts (Hemiprocnidae), hummingbirds, owl-frogmouths (Aegothelidae), and hemipode-quails (Turnicidae) differs from other birds in being cruciform at its origin (Burton, 1971). In hummingbirds the *inclusi* are especially

well developed, occupying the entire ventrolateral surface of the centrum that is occupied by a slip of *M. longus colli ventralis* in some oscines and other birds. The caudal portion of *M. rectus capitis lateralis* in hummingbirds, but not in oscines or in other orders studied to date, takes its origin from the tendon of *M. longus colli ventralis* rather than from a vertebral ventral process. In hummingbirds the slips of *M. longus colli ventralis* lack a fasciculus from the centrum of the vertebra caudal to that of insertion, such as that found in some oscines and in other orders; in addition, hummingbirds differ from oscines in having the first section of the neck served by long slips from the third section or the thorax, as opposed to only short slips from the second section. An unusual feature of hummingbirds is the predominance of muscle fibers inserting on the full extent of the first long tendon of *M. longus colli ventralis* and the virtual absence of fibers to all but the cranial and caudal ends of the next four long tendons.

Tail: Hummingbirds have a pair of flat, oval bones (noted by Cohn, 1968) lying ventrolateral to the caudal vertebrae on the surface of *M. depressor caudae*. Analogous bones occur also in the Falconidae (Richardson, 1972). Insertion of *M. caudofemoralis* on these bones is apparently confined to hummingbirds and falconids.

Abdomen: *M. transversus abdominus* is extremely reduced in hummingbirds, perhaps in relation to their expanded sternum. A feature of some interest is the craniodorsal portion of *M. transversus cloacae* and its fleshy belly within and among families (Zusi, unpublished data). Hummingbirds more closely resemble swifts than oscines in this feature.

Wing: In most birds *M. biceps brachii* originates from the humerus and from the coracoid, and inserts on both the radius and ulna. In hummingbirds it also has a double origin, contrary to published statements, and it inserts only on the ulna. Cohn (1968) reported that in swifts it inserts on the radius and ulna, or only on the radius. *M. flexor digitorum superficialis* is represented in hummingbirds only by a tendon that connects the humerus and the ligamentum hu-

merocarpale whereas swifts and most other birds have a fleshy belly that arises from the humerus and inserts by a tendon on the proximal phalanx of the major digit. Some forelimb muscles are greatly enlarged in hummingbirds. In relation to *M. pectoralis*, *M. supracoracoideus* is larger in hummingbirds than in any other bird. It is also enlarged in swifts in relation to the powered upstroke of their wings (Cohn, 1968). *M. coracobrachialis cranialis* is absent in many passerines but well developed in hummingbirds. Apparently it is also large in swifts and caprimulgids. Another hypertrophied muscle in hummingbirds and swifts is *M. tensor propatagialis pars brevis*. In the former, and in some swifts, it makes a broad, fleshy contact with the belly of *M. extensor metacarpi radialis*. The relationship of these two muscles in swifts and hummingbirds has been described previously (Zusi and Bentz, 1982). *M. flexor digitorum profundus* is comprised of not only a typical belly that arises by two heads from the ulna, but also an accessory belly. This accessory belly appears to be unique to hummingbirds and swifts (Cohn, 1968:102) although the muscle is not identical in the two families.

At least three muscles of the forearm are markedly reduced in size. These are *M. deltoideus major*, *M. deltoideus minor*, and *M. extensor longus allulae*. In the first two muscles the reduction is dramatic in both hummingbirds and swifts. In most birds, including oscines, *M. deltoideus major* consists of two heads, one arising from the clavicle and the other from *os humeroscapulare* (*fibrocartilago humerocapsularis*). Hummingbirds have only the scapular head. In passerines the bellies extend most of the length of the humerus and insert along the shaft. However, in hummingbirds and swifts the shaft of the humerus has been extremely shortened and muscles that are confined to the distal end of the humerus in other birds have migrated proximally in hummingbirds and swifts, obliterating the usual area of attachment of the deltoids. In hummingbirds the two small muscles lie on either side of the tendon of *M. supracoracoideus* and insert near its attachment. The third muscle, *M. extensor longus allulae*, is so small in hummingbirds

that it is no wonder that previous workers overlooked it. Its needle-like belly arises from the ulna. In many non-passerine birds the muscle is proportionately larger and has two heads of origin, one from the ulna and another from the radius.

In most birds *M. expansor secundariorum* arises from the distal end of the humerus, the humeroulnar pulley, or both, and in some it receives a tendon from the axilla. In hummingbirds the muscle arises from what remains of the pulley, and it lacks the axillary tendon (Bentz and Zusi, 1982). In most birds a short, tendinous slip, the ulnar anchor, is present on *M. extensor metacarpi ulnaris*, but in hummingbirds this anchor is absent. In passerines and most other birds the tendon of insertion of *M. extensor digitorum communis* sends a branch to the pollex. In hummingbirds there is no branch to the pollex and the muscle is hypertrophied.

Hindlimb: Hummingbirds are noted for the lack of numerous leg muscles found in other birds (see list below). A muscle that is absent in oscines but present in hummingbirds is *M. adductor digiti II*. The muscle is also absent in *Chaetura* (swift) and *Chordeiles* (nighthawk). *M. femorotibialis internus* has two heads of origin in some oscines, but only a single head in hummingbirds. Similarly, in the former *M. pubo-ischio-femoralis* typically has two bellies whereas in the latter the muscle is divided only at its insertion. A partial origin of *M. extensor digitorum longus* from the fibula as seen in hummingbirds is absent in swifts, passerines, and most other birds (Hudson, 1937). In oscines, the tendon of this muscle branches extensively and sends various tendinous slips to the interphalangeal joint capsules, but in *Chaetura* and hummingbirds the tendons attach mainly on the unguis phalanges.

Striking variation also occurs in *M. flexor hallucis longus* and its relations with *M. flexor digitorum longus*. According to George and Berger (1966:444) *M. flexor hallucis longus* arises by a single head from the intercondyloid region of the femur in most non-passerines. In *Chordeiles* and *Chaetura* the entire tendon fuses with that of *M. flexor digitorum longus*, and the common tendon then splits into four branches to supply all of the

toes. In many oscines there are three heads of origin: from the intercondyloid region, from the external femoral condyle, and from the distal end of the femur. Also, in passerines (except Eurylaimidae) there is no connection between the tendons of *M. flexor hallucis longus* and *M. flexor digitorum longus*. In hummingbirds there are two heads of origin of *M. flexor hallucis longus*: one fleshy from the femur proximal to the external condyle, and a second medial to the first head. The tendons of the two muscles have tendinous connections at the point of trifurcation of *M. flexor digitorum longus*, and *M. flexor hallucis longus* continues distally to insert on the hallux. Our description of the relations of these two tendons in hummingbirds agrees with that of Gadow (1895). Hummingbirds most closely resemble the Type 1 tendon arrangement of Gadow (Newton, 1893–1896), but they are not identical to that type.

M. flexor perforatus digiti II is extremely small in hummingbirds and it is lacking in *Chaetura*. The tendon of this muscle is perforated by the tendons of *M. flexor perforans et perforatus digiti II* and *M. flexor digitorum longus* in hummingbirds and in some, but not all, passerines.

MUSCLES ABSENT IN HUMMINGBIRDS.—The following muscles, present in at least some oscines, are lacking in hummingbirds: adductor mandibulae externus, pars caudalis; adductor mandibulae externus, pars rostralis lateralis (some spe-

cies); pterygoideus, pars dorsalis lateralis; pterygoideus, pars retractor; longus colli dorsalis profundus; levator cloacae; serratus superficialis, pars costohumeralis; pectoralis, pars propatagialis longus and brevis; sternocoracoideus, iliobtibialis lateralis (acetabular and postacetabular parts); ilioprochantericus medius; flexor cruris lateralis, pars pelvica; flexor cruris lateralis, pars accessoria; iliofemoralis internus; fibularis longus; plantaris; and lumbricalis.

ADAPTATIONS.—In this study we have excluded species that show bizarre modifications of the bill, wings, or tail in order to avoid describing features that relate to special adaptations. Such features should be studied separately and in depth. Nevertheless, we suggest that most or all of the differences among the Trochilidae, listed above, will prove to have an adaptive explanation, as will some of the differences between hummingbirds and other families. Cohn (1964) has discussed the functional significance of various modifications of the wing in swifts and hummingbirds, and Scharke (1931) and others have dealt with the tongue and hyoid apparatus. Yet, both of these adaptive complexes need further study. We have shown that the Trochilidae represent a rich source for the study of structural adaptations in other parts of the body as well, and we anticipate that these adaptive complexes will have systematic significance at various taxonomic levels.

Literature Cited

- Baumel, J.J., A.S. King, A.M. Lucas, J.E. Breazile, and H.E. Evans, editors
 1979. *Nomina Anatomica Avium*. 637 pages, illustrated. London: Academic Press.
- Beddard, F.E.
 1898. *The Structure and Classification of Birds*. 524 pages, 252 figures. London: Longmans, Green, and Co.
- Beecher, William J.
 1953. A Phylogeny of the Oscines. *Auk*, 70(3):270-333, 18 figures.
- Bentz, Gregory Dean, and Richard L. Zusi
 1982. The Humeroulnar Pulley and Its Evolution in Hummingbirds. *Wilson Bulletin*, 94(1):71-73, 1 figure.
- Berger, Andrew J.
 1956. The Expansor Secundariorum Muscle with Special Reference to Passerine Birds. *Journal of Morphology*, 99(1):137-168.
 1957. On the Anatomy and Relationships of *Fregilupis varius*, an Extinct Starling from the Mascarene Islands. *Bulletin of the American Museum of Natural History*, 113(3):231-272, 12 figures, 5 tables.
- Boas, J.E.V.
 1929. Biologisch-anatomische Studien über den Hals der Vögel. *Kongelige Danske Videnskabernes Selskab Skrifter: Naturvidenskabelig og Mathematisk Afdeling* (Copenhagen), series 9, 1(3):101-222, 20 figures, 23 plates.
- Bock, Walter J.
 1972. Morphology of the Tongue Apparatus of *Ciridops anna* (Drepanididae). *Ibis*, 114:61-78, 13 figures.
- Bock, Walter J., and Hiroyuki Morioka
 1971. Morphology and Evolution of the Ectethmoid-mandibular Articulation in the Meliphagidae (Aves). *Journal of Morphology*, 135(1):13-50, 16 figures.
- Bock, Walter J., and Ch. R. Shear
 1972. A Staining Method for Gross Dissection of Vertebrate Muscles. *Anatomischer Anzeiger*, 130:222-227.
- Bock, Walter J., Russell P. Balda, and Stephen B. Vander Wall
 1973. Morphology of the Sublingual Pouch and Tongue Musculature in Clark's Nutcracker. *Auk*, 90(3):491-519, 9 figures.
- Buri, Rud. O.
 1900. Zur Anatomie des Flügels von *Micropus melba* und einigen anderen Coracornithes, zugleich Beitrag zur Kenntnis der systematischen Stellung der Cypselidae. *Jenaische Zeitschrift für Naturwissenschaft*, 33:361-610, 6 plates.
- Burton, P.J.K.
 1971. Some Observations on the Splenius Capitis Muscle of Birds. *Ibis*, 113:19-28, 5 figures.
- Cohn, Jean M.W.
 1968. The Convergent Flight Mechanism of Swifts (Apodi) and Hummingbirds (Trochili) (Aves). 201 pages, 21 figures, 13 tables. Doctoral dissertation, University of Michigan, Ann Arbor, Michigan.
- Engels, William L.
 1938. Tongue Musculature of Passerine Birds. *Auk*, 55(4):642-650, 1 figure.
- Fiedler, W.
 1951. Beiträge zur Morphologie der Kiefermuskulatur der Oscines. *Zoologische Jahrbücher, Abteilung für Anatomie und Ontogenie der Tiere*, 71(2):235-288, 25 figures.
- Fürbringer, Max
 1888. *Untersuchungen zur Morphologie und Systematik der Vögel, zugleich ein Beitrag zur Anatomie der Stütz- und Bewegungsorgane*. 2 volumes, 1751 pages, 30 plates. Amsterdam: Van Holkema.
- Gadow, H.F.
 1895. The Deep Plantars in the Trochilidae. *Ibis*, 1:299-300.
- Garrod, A.H.
 1873. On Certain Muscles of the Thigh of Birds and on Their Value in Classification, Part 1. *Proceedings of the Zoological Society of London*, 1:626-644, 6 figures.
- George, J.C., and A.J. Berger
 1966. *Avian Myology*. xii + 500 pages, 248 figures. New York: Academic Press.
- Hofer, Helmut
 1950. Zur Morphologie der Kiefermuskulatur der Vögel. *Zoologische Jahrbücher, Abteilung für Anatomie und Ontogenie der Tiere*, 70(4):427-556, 44 figures.
- Hudson, George E.
 1937. Studies on the Muscles of the Pelvic Appendage in Birds. *American Midland Naturalist*, 18(1):1-108, 74 figures.
- Hudson, George E., and Patricia J. Lanzilloti
 1955. Gross Anatomy of the Wing Muscles in the Family Corvidae. *American Midland Naturalist*, 53(1):1-44, 35 figures.
- Lucas, F.A.
 1895. On the Deep Plantar Tendons in the Trochilidae. *Ibis*, 1:298-299, 1 figure.

- Moller, Walter
 1931. Über die Schnabel-und Zungenmechanik blütenbesuchender Vögel, I: Ein Beitrag zur Biologie des Blumenvogels. *Biologia Generalis*, 6:651-723, 36 figures.
- Morioka, Hiroyuki
 1974. Jaw Musculature of Swifts (Aves, Apodidae). *Bulletin of the National Science Museum of Tokyo*, 17(1): 16 pages, 8 figures.
- Newton, Alfred
 1893-96. *A Dictionary of Birds*. 1088 pages. London: Adam and Charles Black.
- Palmgren, Pontus
 1949. Zur biologischen Anatomie der Halsmuskulatur der Singvögel. In E. Mayr and E. Schuz, editors, *Ornithologie als Biologische Wissenschaft*, pages 192-203. Heidelberg: Carl Winter.
- Raikow, Robert J.
 1976. Pelvic Appendage Myology of the Hawaiian Honeycreepers (Drepanididae). *Auk*, 93(4):774-792, 4 figures, 1 table.
 1977. Pectoral Appendage Myology of the Hawaiian Honeycreepers (Drepanididae). *Auk*, 94(2):331-342, 5 figures, 1 table.
 1978. Appendicular Myology and Relationships of the New World Nine-Primaried Oscines (Aves: Passeriformes). *Bulletin of the Carnegie Museum of Natural History*, 7: 43 pages, 10 figures, 5 tables.
- Richards, Lawrence P., and Walter J. Bock
 1973. Functional Anatomy and Adaptive Evolution of the Feeding Apparatus in the Hawaiian Honeycreeper Genus *Loxops* (Drepanididae). *Ornithological Monographs, American Ornithologists' Union*, 15: vii + 173 pages, 14 figures, 26 plates.
- Richardson, Frank
 1972. Accessory Pygostyle Bones of Falconidae. *Condor*, 74(3):350-351.
- Scharnke, Hans
 1931. Beiträge zur Morphologie und Entwicklungsgeschichte der Zunge der Trochilidae, Meliphagidae, und Picidae. *Journal für Ornithologie*, 79(4):425-491, 54 figures.
- Shulfieldt, Robert W.
 1890. *Myology of the Raven (Corvus corax sinuatus), A Guide to the Study of the Muscular System in Birds*. xix + 343 pages, 76 figures. London: MacMillan and Co.
- Weymouth, Robert D., R.C. Lasiewski, and A.J. Berger
 1964. The Tongue Apparatus in Hummingbirds. *Acta Anatomica*, 58:252-270, 10 figures.
- Zusi, Richard L.
 1962. Structural Adaptations of the Head and Neck in the Black Skimmer, *Ryncops nigra* Linnaeus. *Publications of the Nuttall Ornithological Club*, 3: viii + 101 pages, 44 figures.
- Zusi, Richard L., and Gregory Dean Bentz
 1982. Variation of a Muscle in Hummingbirds and Swifts and Its Systematic Implications. *Proceedings of the Biological Society of Washington*, 95(2):412-420, 2 figures.

Appendix 1

Index to Muscle Abbreviations

The following list includes all muscle abbreviations used in figures in this paper. In addition, we have included abbreviations for muscles not present in hummingbirds or not illustrated here as a possible standard for future workers on avian myology. The muscle names are taken mainly from Baumel et al., 1979. This list may also prove useful to anyone using abbreviations for muscle names other than these to prevent duplication of abbreviations.

AB A	abductor alulae	CO G	constrictor glottidis
AB D 2	abductor digiti II	COL	columellae
AB D 4	abductor digiti IV	CSP	costoseptalis
AB D M	abductor digiti majoris	CST	costosternalis
AD A	adductor alulae	CST MA	costosternalis, pars major
AD D 2	adductor digiti II	CST MI	costosternalis, pars minor
AD R	adductor rectricium	CT	cleidotrachealis
A M C	adductor mandibulae caudalis	D C	depressor caudae
A M E	adductor mandibulae externus	D G	dilator glottidis
A M E C	adductor mandibulae externus, pars caudalis	D M	depressor mandibulae
A M E R	adductor mandibulae externus, pars rostralis	D MA	deltoideus major
A M E R L	adductor mandibulae externus, pars rostralis lateralis	D MI	deltoideus minor
A M E R M	adductor mandibulae externus, pars rostralis medialis	D P V	depressor palpebrae ventralis
A M E R T	adductor mandibulae externus, pars rostralis temporalis	E B A	extensor brevis alulae
A M E V	adductor mandibulae externus, pars ventralis	E B D 3	extensor brevis digiti III
B	brachialis	E B D 4	extensor brevis digiti IV
B B	biceps brachii	EC	ectepicondylo-ulnaris
B C	biventer cervicis	E D C	extensor digitorum communis
BM	branchiomandibularis	E D L	extensor digitorum longus
B R	bulbi rectricium	E H L	extensor hallucis longus
C	complexus	E H L D	extensor hallucis longus, pars distalis
C A	cervicalis ascendens	E H L P	extensor hallucis longus, pars proximalis
C C	cucullaris capitis	E L A	extensor longus alulae
C CA	coracobrachialis caudalis	E L D M	extensor longus digiti majoris
C CE C	cucullaris cervicis, pars clavicularis	E M R	extensor metacarpi radialis
C C I	cucullaris capitis, pars interscapularis	E M U	extensor metacarpi ulnaris
C C PR	cucullaris capitis, pars propatagialis	EN	entepicondylo-ulnaris
C CR	coracobrachialis cranialis	E P D 3	extensor proprius digiti III
CF	caudofemoralis	E S	expansor secundariorum
CG	ceratoglossus	F A	flexor alulae
CH	cricohyoideus	F B	fibularis brevis
CO C I	constrictor colli, pars intermandibularis	F C L	flexor colli lateralis
		F C M	flexor colli medialis
		F CR L	flexor cruris lateralis
		F CR L A	flexor cruris lateralis, pars accessoria
		F CR L P	flexor cruris lateralis, pars pelvica
		F CR M	flexor cruris medialis
		F C U	flexor carpi ulnaris

F D L	flexor digitorum longus	LE C	levator caudae
F D M	flexor digiti minoris	L P D	levator palpebrae dorsalis
F D P	flexor digitorum profundus	M	mesoglossus
F D S	flexor digitorum superficialis	O D	obliquus dorsalis
F H B	flexor hallucis brevis	O E A	obliquus externus abdominus
F H L	flexor hallucis longus	O I A	obliquus internus abdominus
F L	fibularis longus	O L	obturatorius lateralis
F P D 2	flexor perforatus digiti II	O L D	obturatorius lateralis, pars dorsalis
F P D 3	flexor perforatus digiti III	O L V	obturatorius lateralis, pars ventralis
F P D 4	flexor perforatus digiti IV	O M	obturatorius medialis
F P P D 2	flexor perforans et perforatus digiti II	O V	obliquus ventralis
F P P D 3	flexor perforans et perforatus digiti III	P	pectoralis
FT E	femorotibialis externus	P E	pubocaudalis externus
FT I	femorotibialis internus	P I	pubocaudalis internus
FT M	femorotibialis medius	PIF	pubo-ischio-femoralis
G	gastrocnemius	PL	plantaris
GG	genioglossus	P M N	pyramidalis membrane nictitantis
G I	gastrocnemius, pars intermedia	PO	popliteus
G L	gastrocnemius, pars lateralis	P P B	pectoralis, pars propatagialis brevis
G M	gastrocnemius, pars medialis	P P L	pectoralis, pars propatagialis longus
HG O	hypoglossus obliquus	P P Q	protractor pterygoidei et quadrati
HG R	hypoglossus rostralis	PR P	pronator profundus
IC	intercristales	PR S	pronator superficialis
ICB	interceratobranchialis	P S	pectoralis subcutanea
I CR	iliotibialis cranialis	P S A	pectoralis subcutanea, pars abdominalis
I D	interosseus dorsalis	PS P	pseudotemporalis profundus
I E	intercostales externi	PS S	pseudotemporalis superficialis
IF	iliofibularis	P S T	pectoralis subcutanea, pars thoracica
IF E	iliofemoralis externus	PT	pterygoideus
IF I	iliofemoralis internus	PT D L	pterygoideus, pars dorsalis lateralis
I I	intercostales interni	PT D M	pterygoideus, pars dorsalis medialis
I L	iliotibialis lateralis	PT R	pterygoideus, pars retractor
ILC	iliocostalis	PT V L	pterygoideus, pars ventralis lateralis
IM	intermandibularis	PT V M	pterygoideus, pars ventralis medialis
IN	inclusi	PT V M E	pterygoideus, pars ventralis medialis, eustachian slip
ISF	ischiofemoralis	Q M N	quadratus membrane nictitantis
IT	intertransversarii	R A	rectus abdominus
IT CA	iliotrochantericus caudalis	R C D	rectus capitis dorsalis
IT CR	iliotrochantericus cranialis	R C L	rectus capitis lateralis
IT M	iliotrochantericus medius	R C V	rectus capitis ventralis
I V	interosseus ventralis	R C V L	rectus capitis ventralis, pars lateralis
L	lumbricalis	R C V M	rectus capitis ventralis, pars medialis
LA C	lateralis caudae	R D	rectus dorsalis
L C D	longus colli dorsalis	R L	rectus lateralis
L C D CA	longus colli dorsalis, pars caudalis	R M	rectus medialis
L C D CR	longus colli dorsalis, pars cranialis	R P	rhomboideus profundus
L C D P	longus colli dorsalis profundus	R S	rhomboideus superficialis
L C D T	longus colli dorsalis thoracica	R V	rectus ventralis
L CL	levator cloacae	S	scalenus
L CO	levatores costarum	SBC	subcoracoideus
L C V	longus colli ventralis	SBS	subscapularis
L D	latissimus dorsi	SBS L	subscapularis caput laterale
L D CA	latissimus dorsi, pars caudalis		
L D CR	latissimus dorsi, pars cranialis		

SBS M	subscapularis caput mediale	T AB	transversus abdominus
SC	sternocoracoideus	T AS	thoracicus ascendens
S CA	splenius capitis	T B	triceps brachii
S CL	sphincter cloacae	TB B	tracheobronchialis brevis
S D	syringealis dorsalis	TB D	tracheobronchialis dorsalis
SE	serpihyoideus	TB V	tracheobronchialis ventralis
SH CA	scapulohumeralis caudalis	T C	transversus cloacae
SH CR	scapulohumeralis cranialis	T CR	tibialis cranialis
S O L	syringealis obliquus lateralis	TH	humerotriceps
S O V	syringealis obliquus ventralis	TL	tracheolateralis
S P	serratus profundus	T P	tensor proapatagialis
S S	serratus superficialis	T P B	tensor proapatagialis, pars brevis
S S CA	serratus superficialis, pars caudalis	T PE	tensor periorbitae
S S CR	serratus superficialis, pars cranialis	T P L	tensor proapatagialis, pars longa
S S M	serratus superficialis, pars metapatagialis	TS	scapulotriceps
ST	stylohyoideus		
STH	sternohyoideus	U D	ulnometacarpalis dorsalis
STT	sternotrachealis	U V	ulnometacarpalis ventralis
SU	supinator		
SUP	supracoracoideus	V D	vocalis dorsalis
S V	syringealis ventralis	V V	vocalis ventralis

Appendix 2

Index to Abbreviations, Excluding Muscles

The following abbreviations appear in *italics* in the figures to distinguish them from abbreviations for muscle names.

<i>A</i>	atlas	<i>HS</i>	horizontal septum
<i>AP</i>	alular phalanx	<i>HU</i>	humerus
<i>AX</i>	axis	<i>HY</i>	hypotarsus
<i>BC</i>	bicipital crest of humerus	<i>IFL</i>	iliofibular loop
<i>BCA</i>	basibranchiale caudale	<i>IL</i>	ilium
<i>BCD</i>	bicipital crest, dorsal head	<i>IRL</i>	interosseal radioulnar ligament
<i>BCR</i>	basibranchiale craniale	<i>IS</i>	ischium
<i>BCV</i>	bicipital crest, ventral head	<i>JB</i>	jugal bar
<i>BP</i>	blade of pygostyle	<i>LJL</i>	lateral jugomandibular ligament
<i>BT P</i>	basitemporal plate	<i>LS</i>	ligamentous sling
<i>BV</i>	body of vertebra	<i>LSL</i>	long sternocoracoidal ligament
<i>CA</i>	carpometacarpus	<i>M</i>	mandible
<i>CA P</i>	carotid process	<i>MET</i>	metatarsus
<i>CAP</i>	caudal articular process	<i>MF</i>	mandibular fenestra
<i>CB</i>	coracoidal bar	<i>MI D</i>	minor digit
<i>CE</i>	ceratobranchiale	<i>MJL</i>	medial jugomandibular ligament
<i>CL</i>	clavicle	<i>MN</i>	mandibular nerve
<i>CLO</i>	cloaca	<i>M P M</i>	medial process of mandible
<i>CL P</i>	craniolateral process of sternum	<i>MR</i>	mandibular ramus
<i>CO</i>	coracoid	<i>NF</i>	nasal flange
<i>CP</i>	cerebellar prominence	<i>OB</i>	oval bone
<i>CP H</i>	head of costal process	<i>OL</i>	occipitomandibular ligament
<i>CS</i>	costal spine	<i>ON</i>	optic nerve
<i>DB</i>	dorsal bar of upper jaw	<i>OP F</i>	optic foramen
<i>DC</i>	deltoid crest	<i>OR F</i>	orbital foniculus
<i>DE</i>	dorsal epicondyle	<i>PB</i>	prepalatine bar
<i>DP</i>	dorsal process	<i>P EMR</i>	process of M. extensor metacarpi radialis
<i>DP A</i>	dorsal process of axis	<i>PL</i>	postorbital ligament
<i>DP MA</i>	distal phalanx, major digit	<i>P P MA</i>	proximal phalanx, major digit
<i>EN</i>	entoglossum	<i>PT</i>	pterygoid
<i>EO</i>	ear opening	<i>PU</i>	pubis
<i>EP</i>	epibranchiale	<i>PY</i>	pygostyle
<i>EP</i>	ectethmoid plate	<i>QU</i>	quadrate
<i>FE</i>	femur	<i>RA</i>	radius
<i>FI</i>	fibula	<i>RE</i>	rectrices
<i>GC</i>	glenoid cartilage	<i>R M N</i>	ramus of mandibular nerve
<i>G O N</i>	groove of olfactory nerve	<i>R P M</i>	retroarticular process of mandible
<i>HA</i>	hallux	<i>SC</i>	scapula
<i>HB</i>	humerocondylar band	<i>S M</i>	sternocoracoclavicular membrane
<i>H HU</i>	head of humerus	<i>S P</i>	spinous process
<i>HP</i>	humerocondylar pulley		

<i>SR</i>	sternal rib	<i>UG</i>	urophygial gland
<i>STP</i>	synsacral transverse process	<i>UL</i>	ulna
<i>TC</i>	tibial cartilage	<i>ULMB</i>	ulnar-manus band
<i>TI</i>	tibiotarsus	<i>ULP</i>	ulnar patella
<i>TNC</i>	transverse nuchal crest	<i>UP</i>	uncinate process
<i>TPE</i>	tympanic process of exoccipital	<i>VA</i>	vertebral arch
<i>TPI</i>	tendon of M. pubocaudalis internus	<i>VB</i>	ventral bar of the upper jaw
<i>TPIL</i>	terminal process of the ilium	<i>VCL</i>	ventral collateral ligament
<i>TPP</i>	transpalatine process	<i>VE</i>	ventral epicondyle
<i>TPRS</i>	tubercle of M. pronator superficialis	<i>VP</i>	ventral process
<i>TRC</i>	triosseal canal	<i>VR</i>	vertebral rib
<i>TRL</i>	transverse radioulnar ligament	<i>WPT</i>	wall of the palatine trough
<i>TRP</i>	transverse process	<i>ZP</i>	zygomatic process
<i>TPB</i>	tubercle of M. tensor propatagialis, pars brevis		

Figures 1-20

(Abbreviations identified in Appendices)

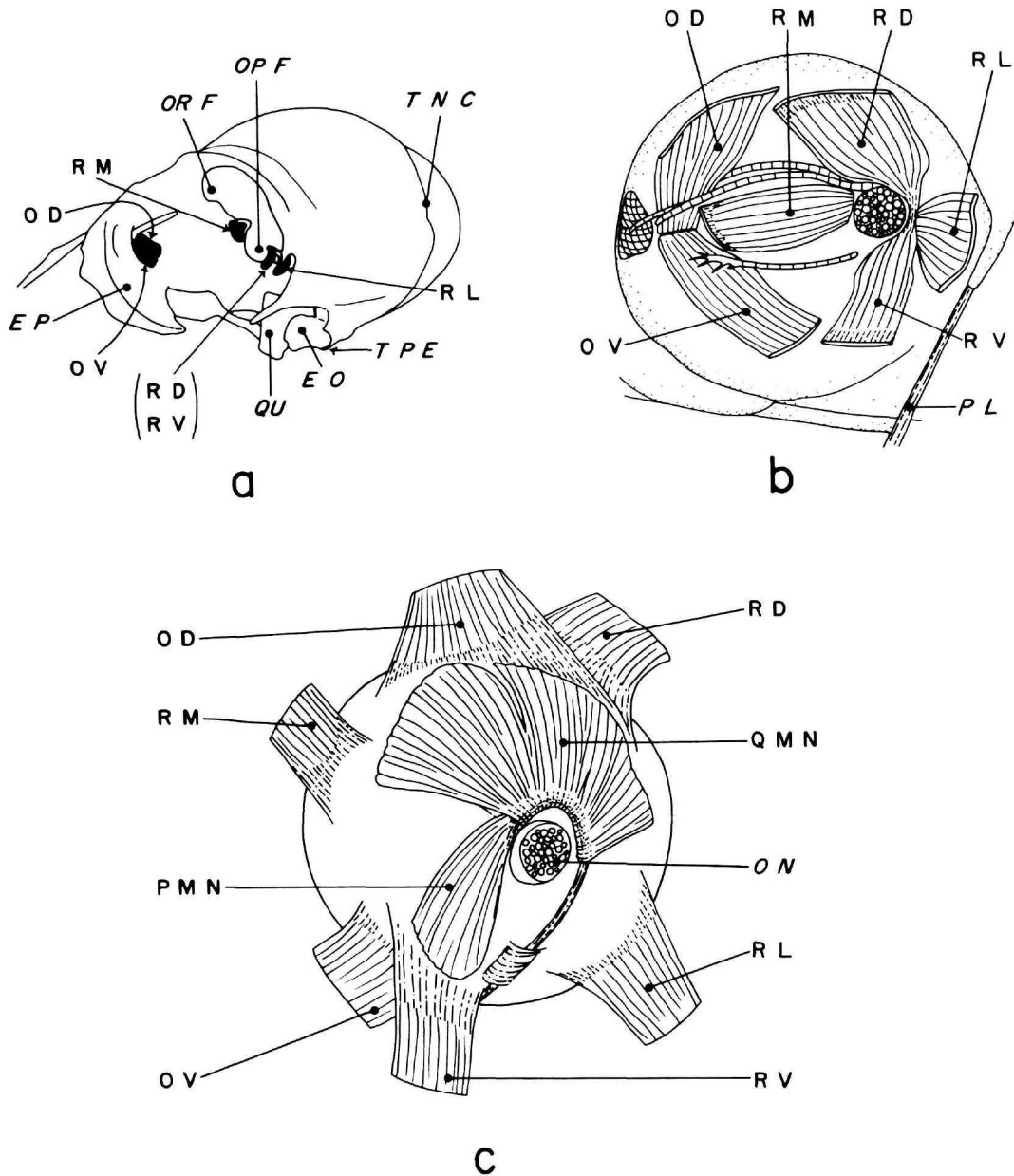


FIGURE 1.—Muscles of eye, *Eulampis jugularis*: a, areas of origin on skull; b, muscles with left eye removed; c, muscles of nictitating membrane of right eye in posteromedial view.

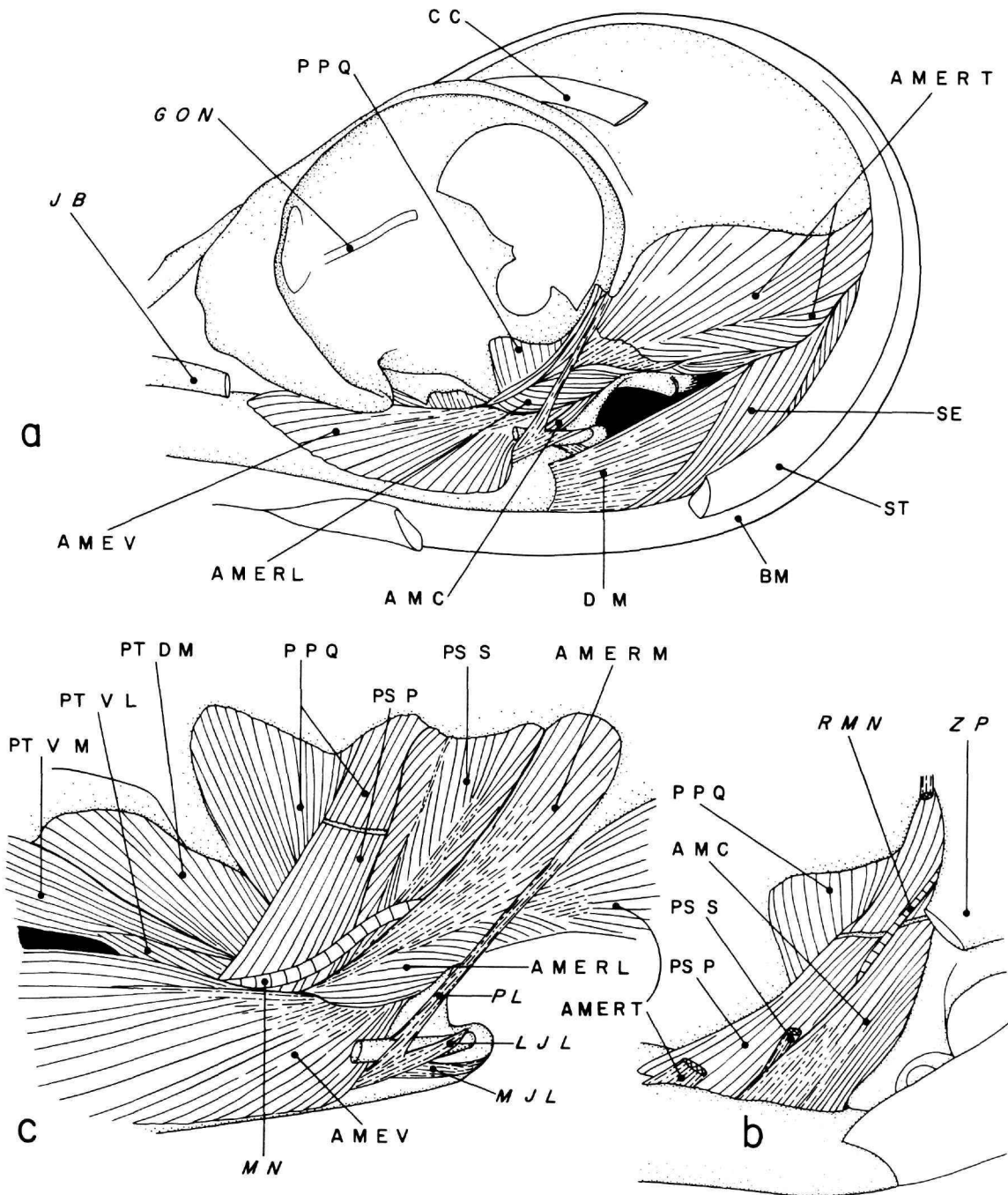


FIGURE 2.—Muscles of jaws, *Eulampis jugularis*: a, superficial muscles in left lateral view; b, muscles of quadrate; c, rostradorsolateral view of muscles of orbit.

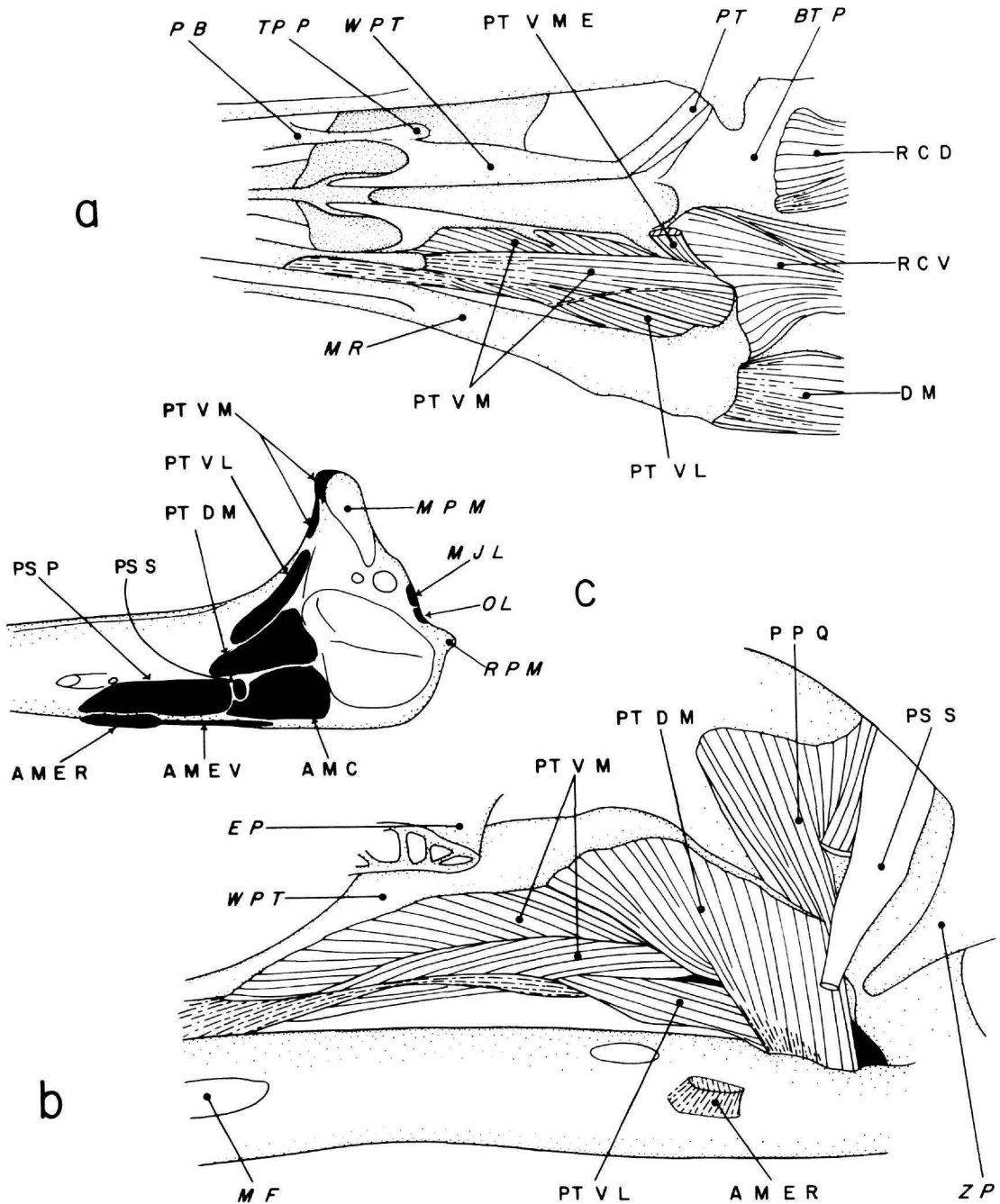


FIGURE 3.—Muscles of jaws, *Eulampis jugularis*: a, ventral view; b, left dorsolateral view with eye, ectethmoid, jugal bar, adductor muscles, and *M. pseudotemporalis profundus* removed; c, dorsal view of caudal end of left ramus of lower jaw showing areas of muscle attachment in black.

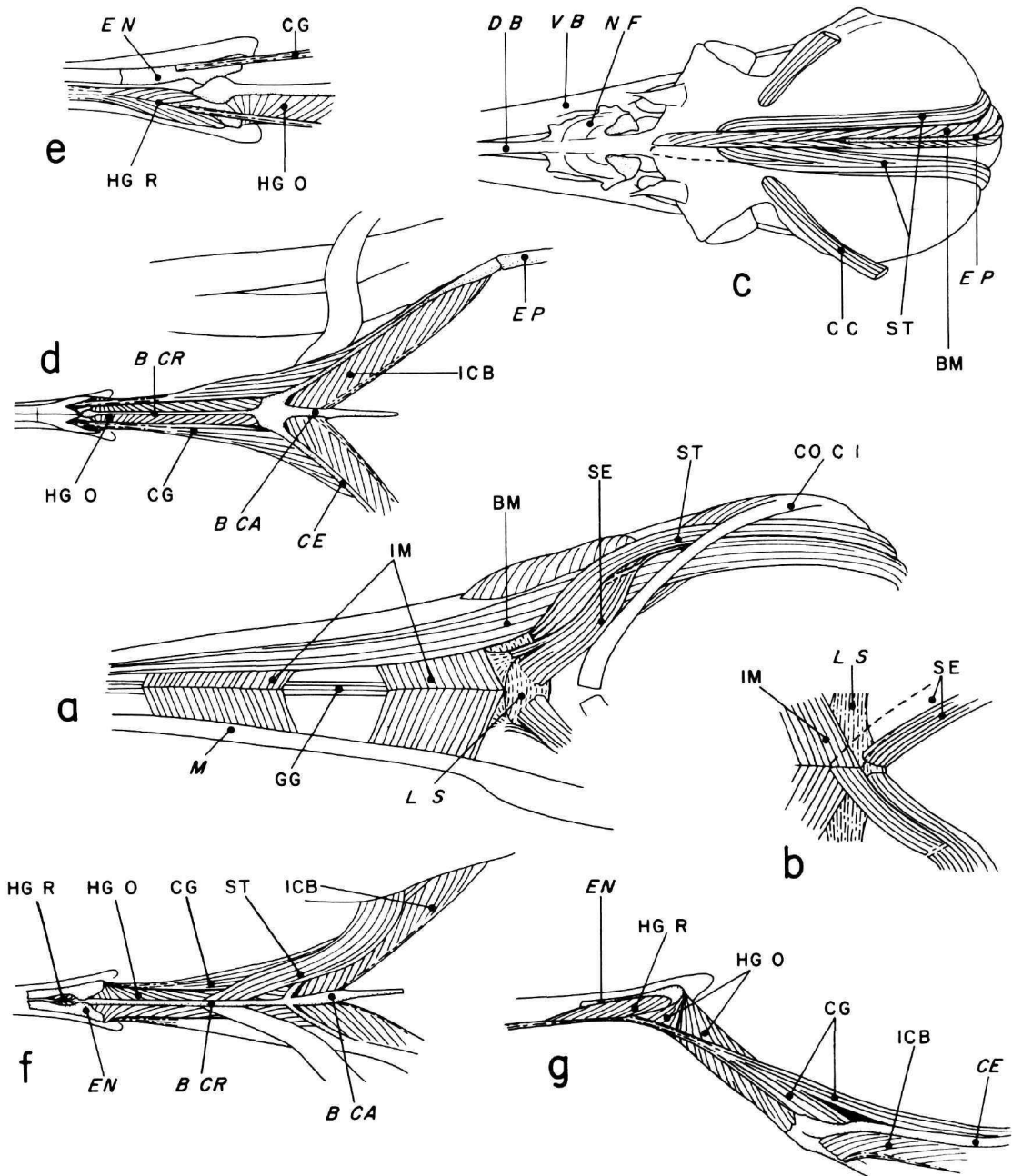


FIGURE 4.—Muscles of tongue and hyoid apparatus, *Eulampis jugularis*: a, ventral view, right branchiomandibularis removed; b, form of *M. serpihyoideus* found in some other genera; c, dorsal view of skull, left branchiomandibularis removed; d, ventral view of hyoid muscles; e, enlarged ventral view of tongue muscles; f, dorsal view of hyoid muscles; g, left lateral view of hyoid muscles.

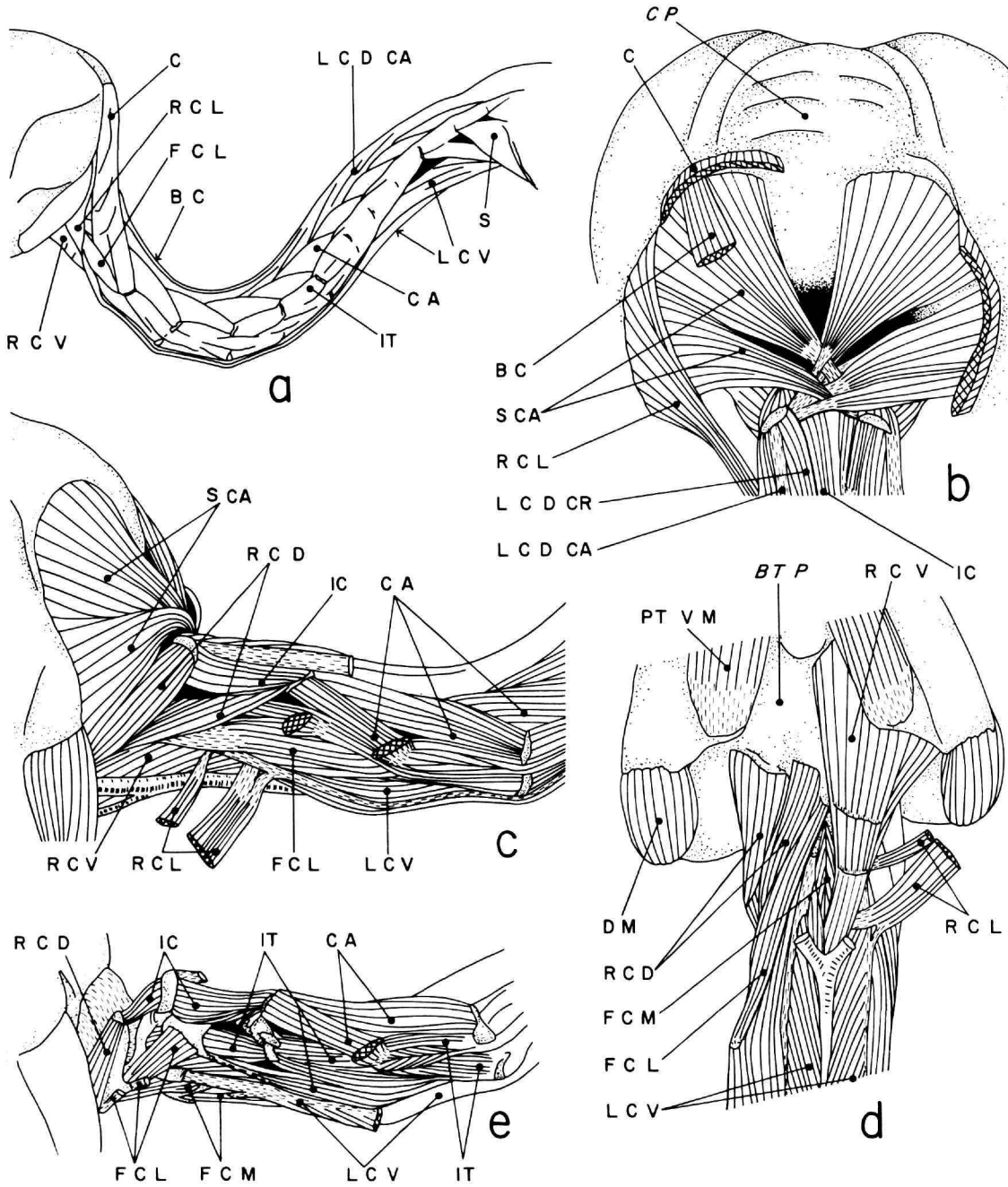


FIGURE 5.—Muscles of neck, *Eulampis jugularis*: a, left lateral view of superficial muscles; b, caudal view of deep, dorsal muscles to cranium; c, left lateral view of middle layer of neck section I; d, ventral muscles of cranium and neck section I; e, left lateral view of deep muscles of cranium and neck section I.

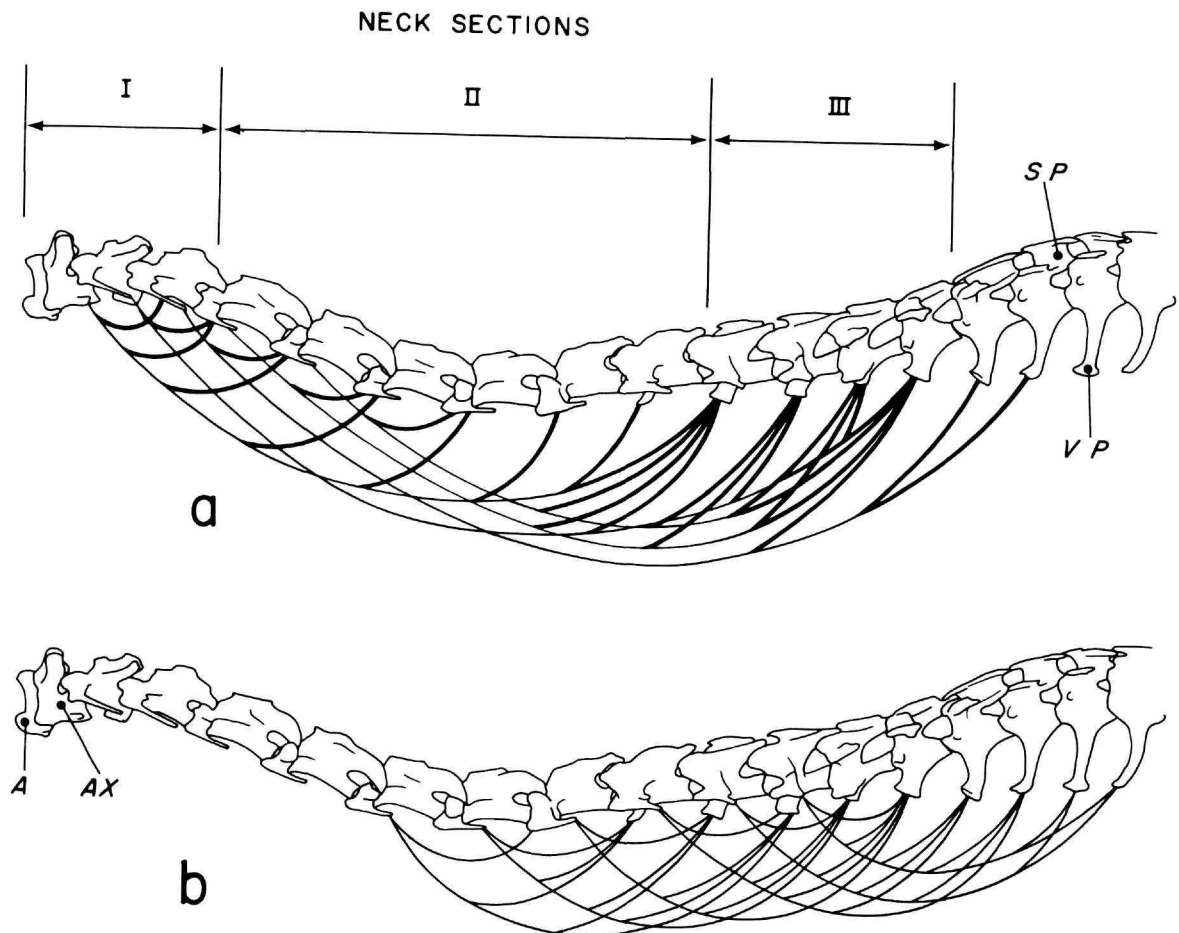


FIGURE 6.—Diagram of slips of *M. longus colli ventralis*, *Eulampis jugularis* in left lateral view:
a, longer slips; *b*, shorter slips.

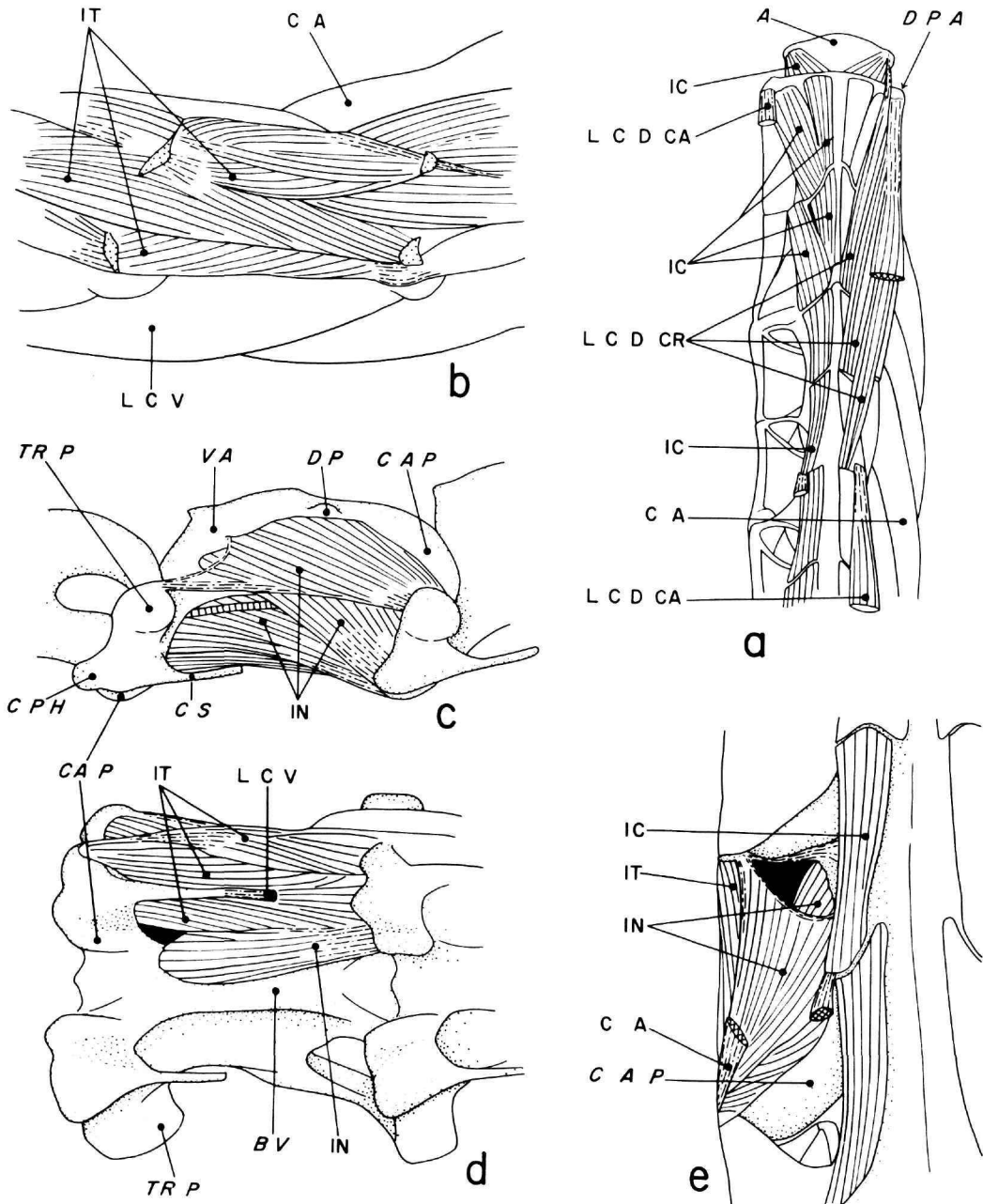


FIGURE 7.—Muscles of neck, *Eulampis jugularis*: a, dorsal view of deep muscles of cranial portion of neck; b, left lateral view of muscles between vertebrae 6 and 7; c, left lateral view of deep muscles to vertebra 6; d, ventral view of muscles between vertebrae 6 and 7, with *M. longus colli ventralis* removed; e, dorsal view of muscles between vertebrae 6 and 7, with *M. longus colli dorsalis* and *M. cervicalis ascendens* removed.

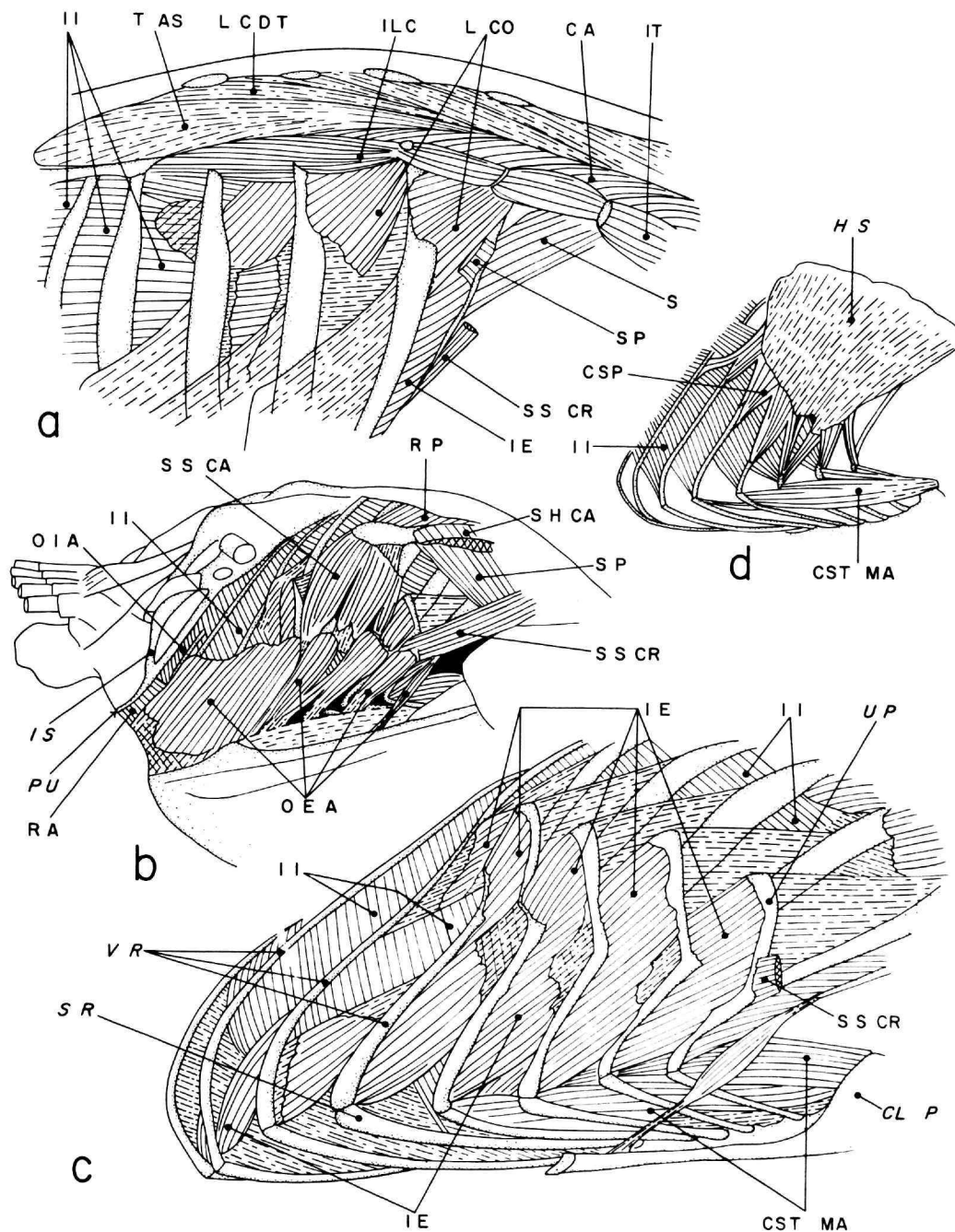


FIGURE 8.—Muscles of trunk, *Eulampis jugularis*: a, right dorsolateral view of vertebral muscles; b, right lateral view of trunk and abdomen; c, right lateral view of deeper muscles of ribs; d, left medial view of muscles of ribs.

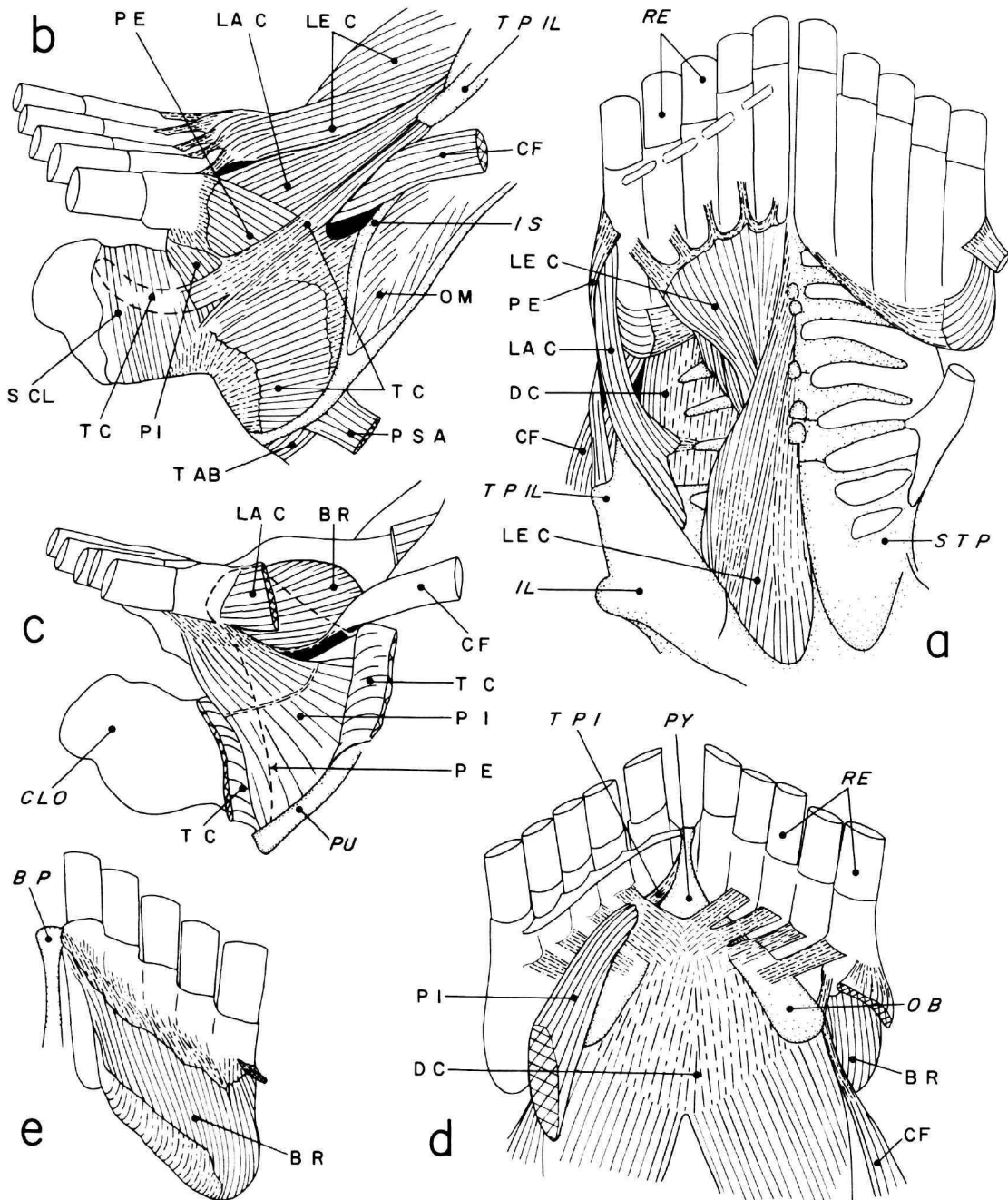


FIGURE 9.—Muscles of tail, *Eulampis jugularis*: a, dorsal view with uropygial glands and some muscles of left side removed; b, right lateral view; c, right lateral view with *M. transversus cloacae* cut and reflected, and *M. pubocaudalis externus* (dashed line) removed; d, ventral view; e, ventral view of right rectricial bulb.

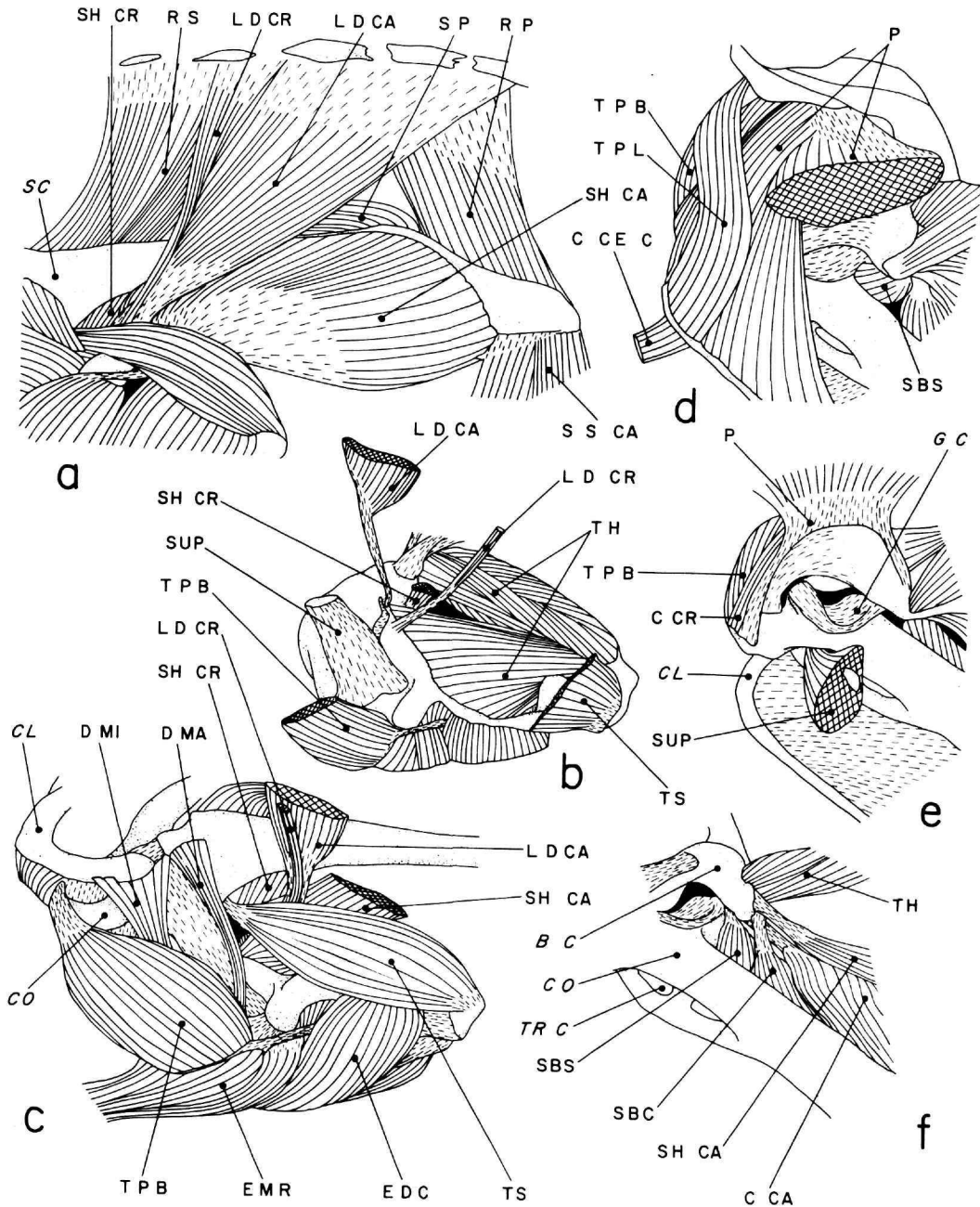


FIGURE 10.—Muscles of shoulder and humerus, *Eulampis jugularis*: a, dorsal view of left side; b, caudal view of left humerus with some muscles removed or cut and displaced; c, dorsal view of deeper muscles of left shoulder; d, lateral view of left shoulder with some muscles cut and removed; e, like d with more muscles removed and M. pectoralis raised; f, left lateral view of deep muscles to bicipital crest of humerus.

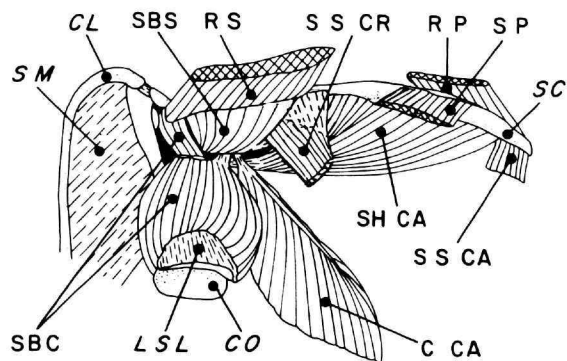


FIGURE 11 (above).—Axillary muscles of *Eulampis jugularis*, ventromedial view of isolated right pectoral girdle, with *M. coracobrachialis caudalis* displaced.

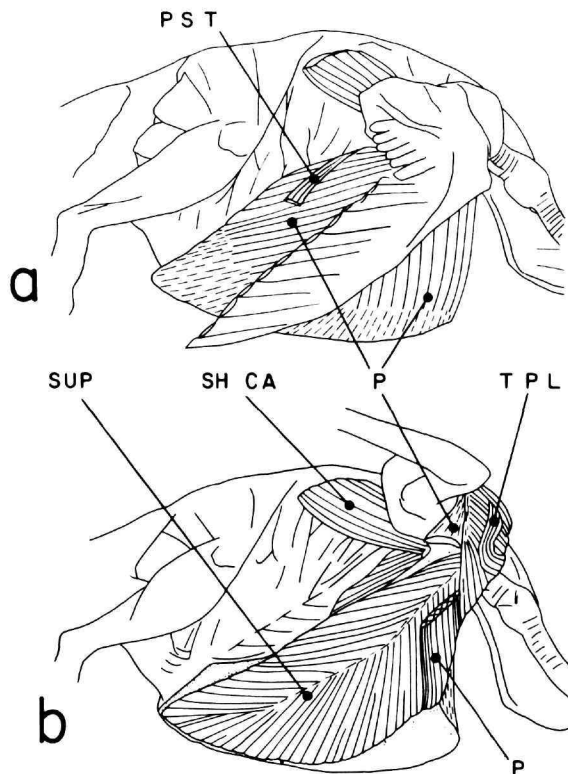


FIGURE 12 (upper right).—Major flight muscles, *Eulampis jugularis*: a, right lateral view of superficial muscles; b, same view of deeper muscles, with right wing raised.

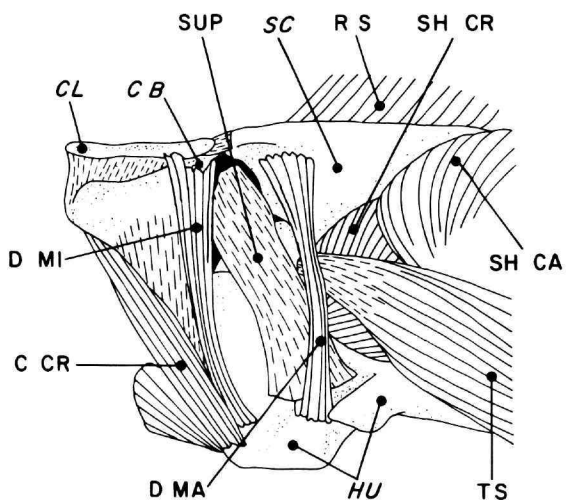


FIGURE 13 (lower right).—Deep muscles of shoulder, *Eulampis jugularis*, left side, dorsal view.

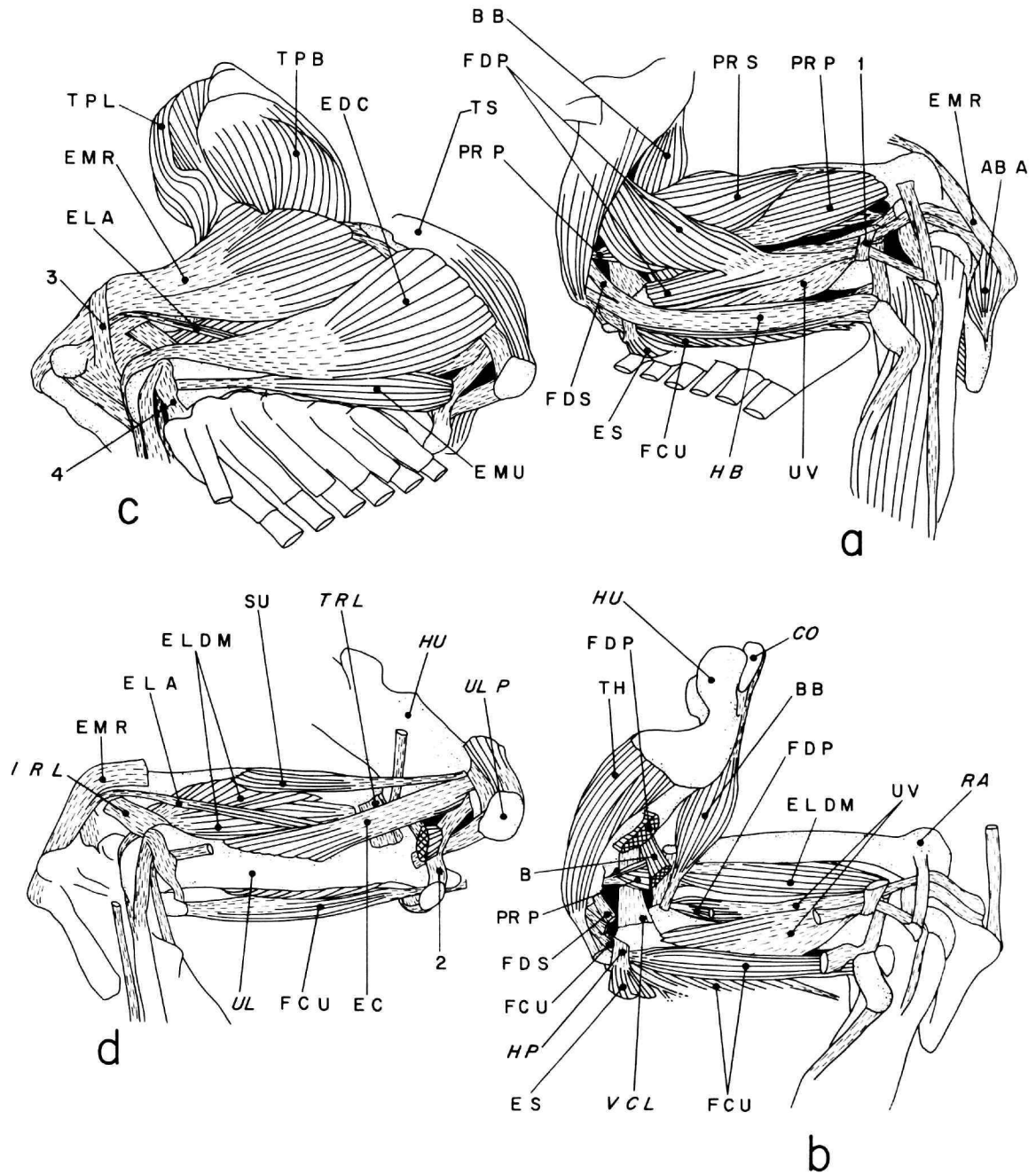


FIGURE 14.—Muscles of left wing, *Eulampis jugularis*: a, superficial muscles, ventral view; b, deep muscles, ventral view; c, superficial muscles, dorsal view; d, deep muscles, dorsal view. (Numbers 1-4 refer to ligamentous loops discussed in text.)

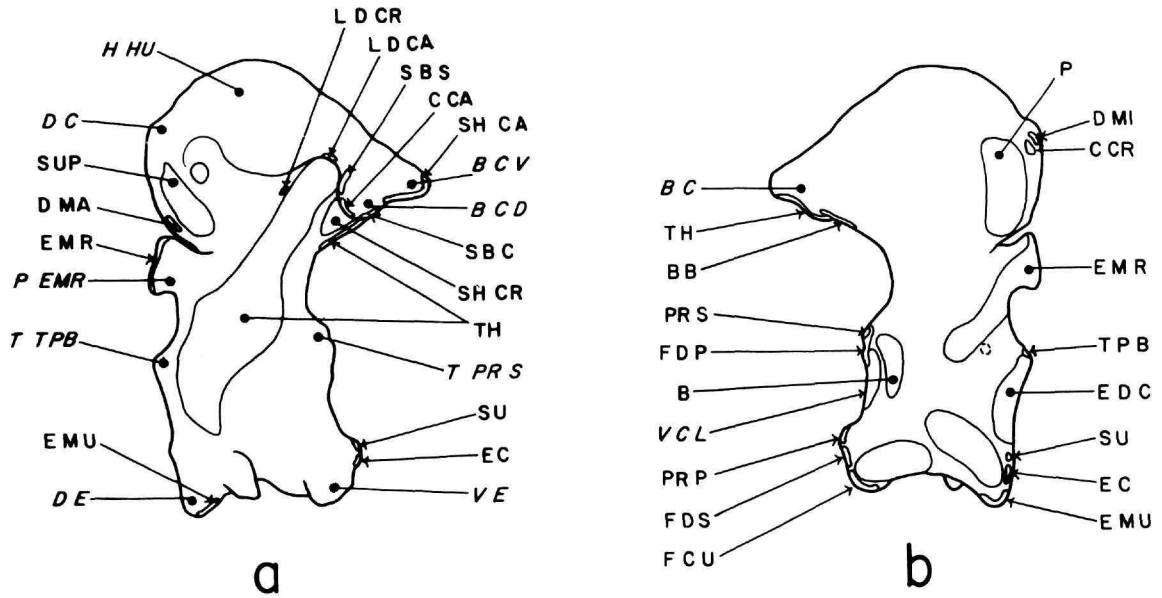


FIGURE 15.—Left humerus showing attachments of muscles and ligaments, *Eulampis jugularis*: a, caudal view; b, cranial view.

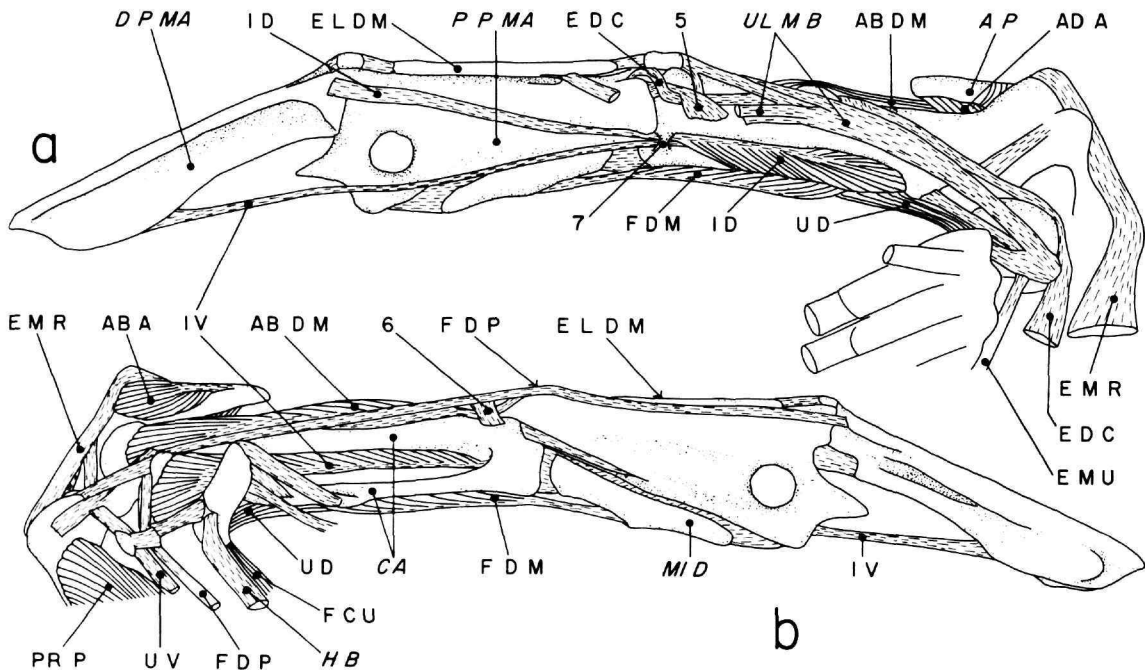


FIGURE 16.—Muscles of left manus, *Eulampis jugularis*: a, dorsal view; b, ventral view. (Numbers 1 and 5-7 refer to ligamentous or bony loops discussed in text.)

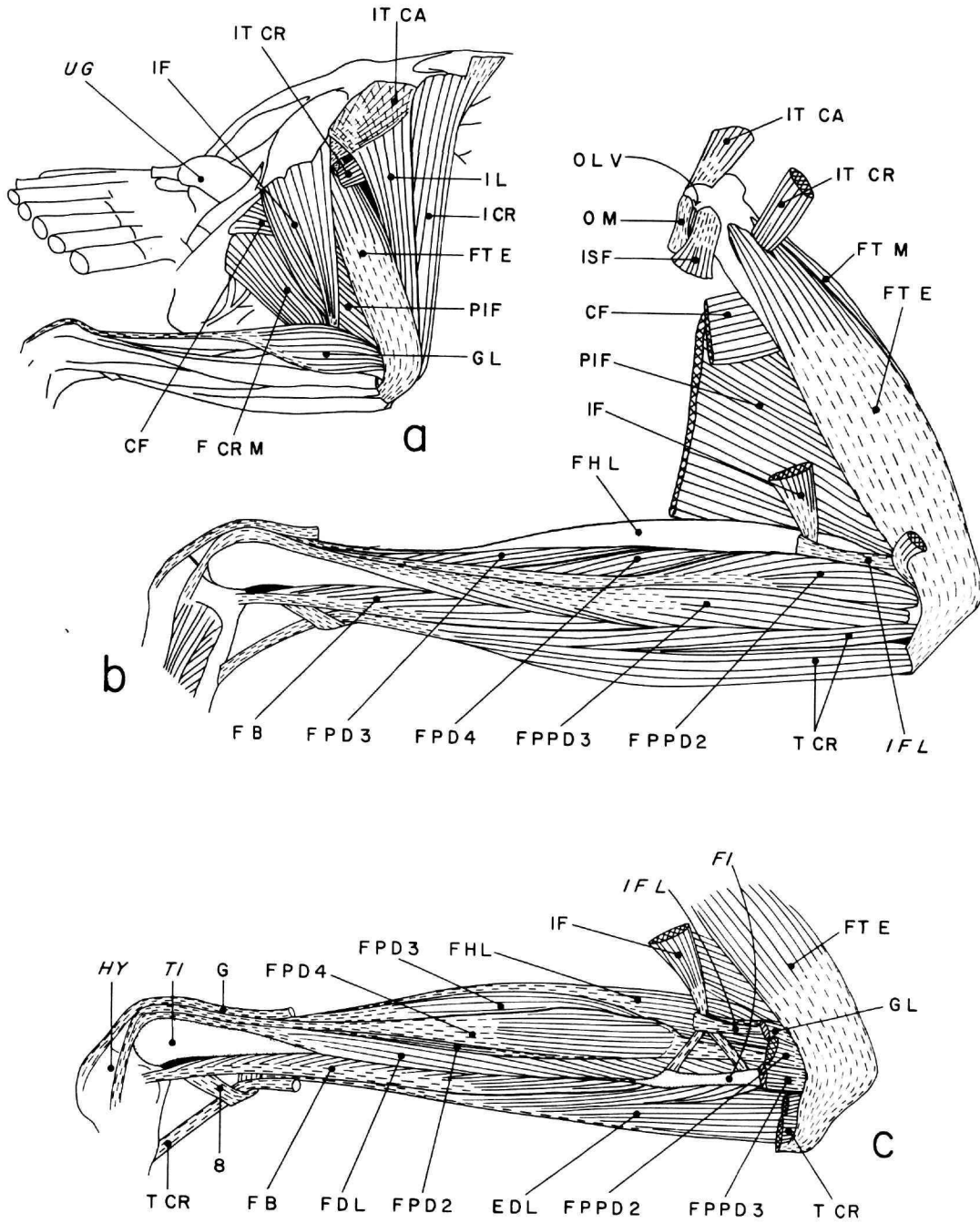


FIGURE 17.—Muscles of right hindlimb, *Eulampis jugularis* in lateral view: *a*, superficial muscles; *b*, deep thigh muscles and middle layer of crus; *c*, deep muscles of crus. (Number 8 refers to ligamentous loop discussed in text.)

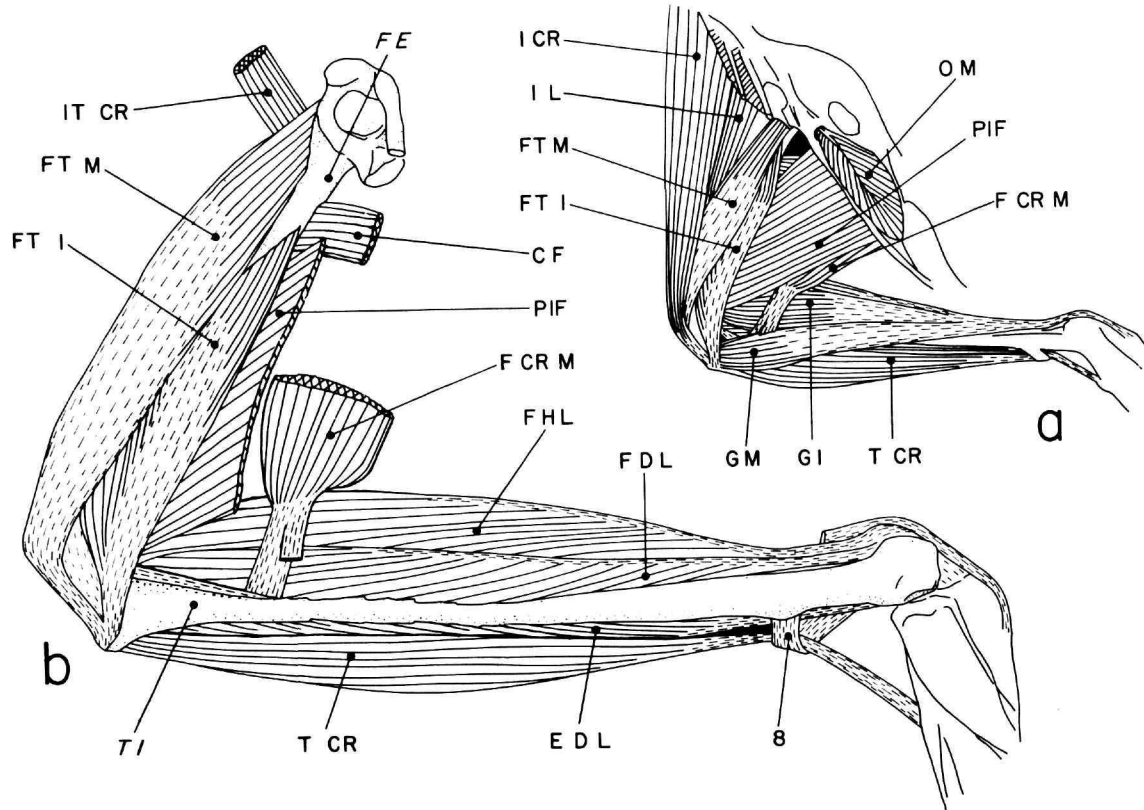


FIGURE 18.—Muscles of right hindlimb, *Eulampis jugularis* in medial view: *a*, superficial muscles; *b*, deep muscles. (Number 8 refers to ligamentous loop discussed in text.)

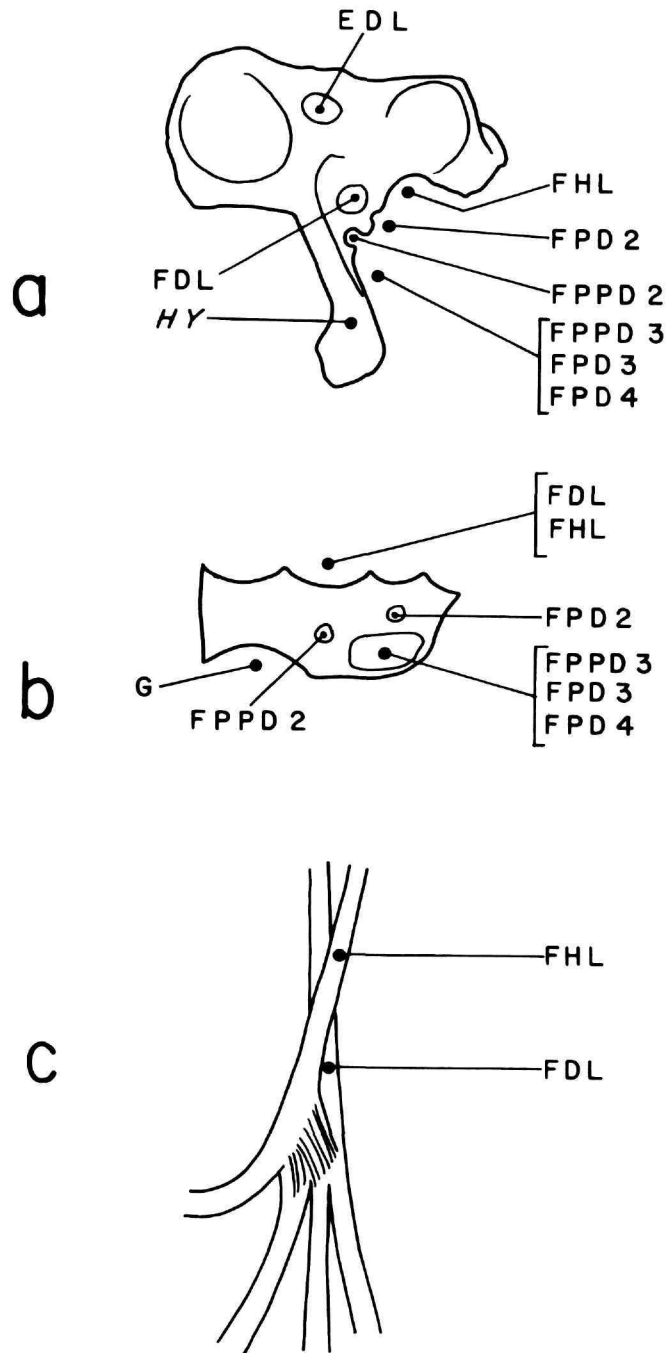


FIGURE 19.—Tendons on ventral surface of right foot, *Eulampis jugularis*: a, proximal end of tarsometatarsus; b, cross section of tibial cartilage; c, relations of major flexor tendons.

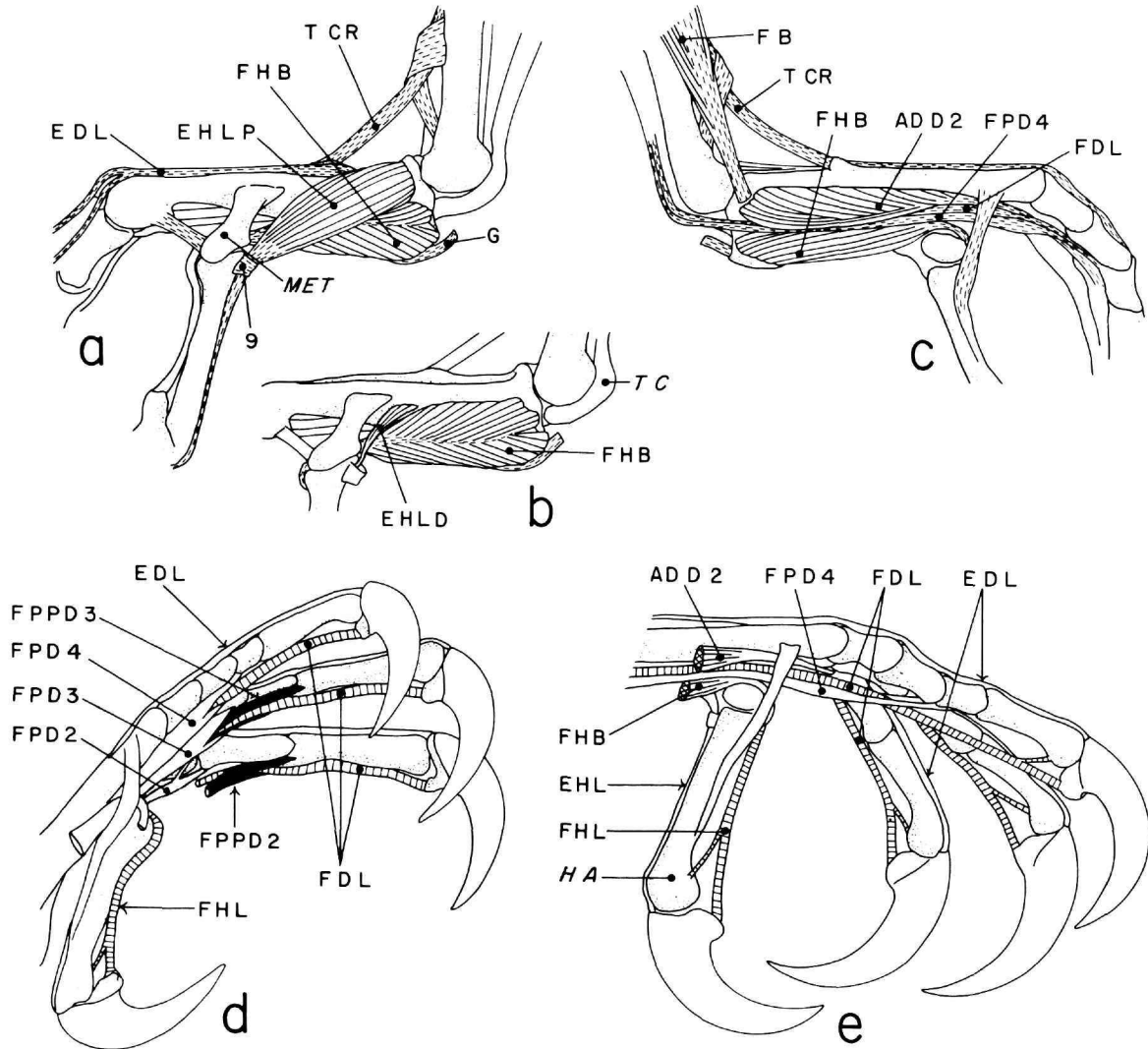


FIGURE 20.—Muscles of right foot, *Eulampis jugularis*: *a*, superficial muscles, medial view; *b*, deep muscles, medial view; *c*, superficial muscles, lateral view; *d*, tendons of the digits in cranioventromedial view; *e*, deep tendons of the digits. (Some tendons shown in black or cross-hatched for clarity. Number 9 refers to ligamentous loop discussed in text.)

Index to Main Muscle Headings

- abductor alulae, 32
 abductor digiti majoris, 32
 adductor alulae, 32
 adductor digiti II, 40
 adductor mandibulae caudalis, 6
 adductor manibulae externus, 4
 biceps brachii, 27
 biventer cervicis, 12
 brachialis, 28
 branchiomandibularis, 10
 bulbi rectorium, 21
 caudofemoralis, 35
 ceratoglossus, 11
 cervicalis ascendens, 15
 complexus, 12
 constrictor colli, pars intermandibularis, 41
 coracobrachialis caudalis, 25
 coracobrachialis cranialis, 25
 costoseptalis, 20
 costosternalis, 20
 cucullaris capitis, 40
 cucullaris cervicis, pars clavicularis, 41
 deltoideus major, 27
 deltoideus minor, 27
 depressor caudae, 21
 depressor mandibulae, 8
 ectepicondylo-ulnaris, 31
 extensor digitorum communis, 30
 extensor digitorum longus, 37
 extensor hallucis longus, 39
 extensor longus alulae, 31
 extensor longus digiti majoris, 31
 extensor metacarpi radialis, 30
 extensor metacarpi ulnaris, 30
 expansor secundariorum, 28
 femorotibiales, 34
 femorotibialis externus, 34
 femorotibialis internus, 34
 femorotibialis medius, 34
 fibularis brevis, 37
 fibularis longus, 36
 flexor carpi ulnaris, 29
 flexor colli lateralis, 13
 flexor colli medialis, 14
 flexor cruris lateralis, pars pelvica and pars accessoria, 34
 flexor cruris medialis, 35
 flexor digiti minoris, 33
 flexor digitorum longus, 39
 flexor digitorum profundus, 29
 flexor digitorum superficialis, 29
 flexor hallucis brevis, 39
 flexor hallucis longus, 38
 flexor perforans et perforatus digiti II, 37
 flexor perforans et perforatus digiti III, 37
 flexor perforatus digiti II, 38
 flexor perforatus digiti III, 38
 flexor perforatus digiti IV, 38
 gastrocnemius, 36
 genioglossus, 9
 hypoglossus obliquus, 11
 hypoglossus rostralis, 11
 iliocostalis, 17
 iliofemoralis externus, 36
 iliofemoralis internus, 36
 iliofibularis, 34
 iliotibialis cranialis, 33
 iliotibialis lateralis, 33
 iliotorchanterici, 33
 iliotorchantericus caudalis, 33
 iliotorchantericus cranialis, 33
 iliotorchantericus medius, 34
 inclusi, 16
 interceratobranchialis, 11
 intercostales externi, 19
 intercostales interni, 20
 intercostales, 13
 intermandibularis, 9
 interosseus dorsalis, 32
 interosseus ventralis, 32
 intertransversarii, 16
 ischiofemoralis, 35
 lateralis caudae, 21
 latissimus dorsi, 23
 levator caudae, 21
 levator cloacae, 23
 levatores costarum, 19
 longissimus dorsi, 17
 longus colli dorsalis, pars caudalis, 15
 longus colli dorsalis, pars cranialis, 15
 longus colli dorsalis thoracica, 18
 longus colli ventralis, 14
 obliquus dorsalis, 3
 obliquus externus abdominus, 19
 obliquus internus abdominus, 21
 obliquus ventralis, 3
 obturatorius lateralis, 35
 obturatorius medialis, 35
 pectoralis, 25
 pectoralis subcutanea, 40
 plantaris, 38
 pronator profundus, 29
 pronator superficialis, 28
 protractor pterygoidei et quadrati, 7
 pseudotemporalis profundus, 6
 pseudotemporalis superficialis, 6
 pterygoideus, pars dorsalis medialis, 8
 pterygoideus, pars ventralis lateralis, 7
 pterygoideus, pars ventralis medialis, 7
 pubocaudalis externus, 22
 pubocaudalis internus, 22
 pubo-ischio-femoralis, 35
 pyramidalis membranae nictitantis, 4
 quadratus membranae nictitantis, 4
 rectus abdominus, 20
 rectus capitis dorsalis, 13
 rectus capitis lateralis, 13
 rectus capitis ventralis, 13
 rectus dorsalis, 3
 rectus lateralis, 3
 rectus medialis, 3
 rectus ventralis, 3
 rhomboideus profundus, 24
 rhomboideus superficialis, 23
 scalenus, 19
 scapulohumeralis caudalis, 24
 scapulohumeralis cranialis, 24
 serpihyoideus, 9
 serrati, 24
 serratus profundus, 24
 serratus superficialis, 24
 serratus superficialis, pars metapatalis, 41
 sphincter cloacae, 23
 splenius capitis, 12
 sternocoracoideus, 26

stylohyoideus, 10
subcoracoideus, 25
subcoracoscapulares, 25
subscapularis, 25
supinator, 31

supracoracoideus, 26
tensor proptagialis, 26
thoracicus ascendens, 18
tibialis cranialis, 36
transversus abdominus, 20

transversus cloacae, 22
triceps brachii, 28
ulnometacarpalis dorsalis, 32
ulnometacarpalis ventralis, 31

REQUIREMENTS FOR SMITHSONIAN SERIES PUBLICATION

Manuscripts intended for series publication receive substantive review within their originating Smithsonian museums or offices and are submitted to the Smithsonian Institution Press with Form SI-36, which must show the approval of the appropriate authority designated by the sponsoring organizational unit. Requests for special treatment—use of color, foldouts, case-bound covers, etc.—require, on the same form, the added approval of the sponsoring authority.

Review of manuscripts and art by the Press for requirements of series format and style, completeness and clarity of copy, and arrangement of all material, as outlined below, will govern, within the judgment of the Press, acceptance or rejection of manuscripts and art.

Copy must be prepared on typewriter or word processor, double-spaced, on one side of standard white bond paper (not erasable), with 1¼" margins, submitted as ribbon copy (not carbon or xerox), in loose sheets (not stapled or bound), and accompanied by original art. Minimum acceptable length is 30 pages.

Front matter (preceding the text) should include: **title page** with only title and author and no other information; **abstract page** with author, title, series, etc., following the established format; table of **contents** with indents reflecting the hierarchy of heads in the paper; also, **foreword** and/or **preface**, if appropriate.

First page of text should carry the title and author at the top of the page; **second page** should have only the author's name and professional mailing address, to be used as an unnumbered footnote on the first page of printed text.

Center heads of whatever level should be typed with initial caps of major words, with extra space above and below the head, but with no other preparation (such as all caps or underline, except for the underline necessary for generic and specific epithets). Run-in paragraph heads should use period/dashes or colons as necessary.

Tabulations within text (lists of data, often in parallel columns) can be typed on the text page where they occur, but they should not contain rules or numbered table captions.

Formal tables (numbered, with captions, boxheads, stubs, rules) should be submitted as carefully typed, double-spaced copy separate from the text; they will be typeset unless otherwise requested. If camera-copy use is anticipated, do not draw rules on manuscript copy.

Taxonomic keys in natural history papers should use the aligned-couplet form for zoology and may use the multi-level indent form for botany. If cross referencing is required between key and text, do not include page references within the key, but number the keyed-out taxa, using the same numbers with their corresponding heads in the text.

Synonymy in zoology must use the short form (taxon, author, year:page), with full reference at the end of the paper under "Literature Cited." For botany, the long form (taxon, author, abbreviated journal or book title, volume, page, year, with no reference in "Literature Cited") is optional.

Text-reference system (author, year:page used within the text, with full citation in "Literature Cited" at the end of the text) must be used in place of bibliographic footnotes in all Contributions Series and is strongly recommended in the Studies Series: "(Jones, 1910:122)" or "... Jones (1910:122)." If bibliographic footnotes are required, use the short form (author,

brief title, page) with the full citation in the bibliography.

Footnotes, when few in number, whether annotative or bibliographic, should be typed on separate sheets and inserted immediately after the text pages on which the references occur. Extensive notes must be gathered together and placed at the end of the text in a notes section.

Bibliography, depending upon use, is termed "Literature Cited," "References," or "Bibliography." Spell out titles of books, articles, journals, and monographic series. For book and article titles use sentence-style capitalization according to the rules of the language employed (exception: capitalize all major words in English). For journal and series titles, capitalize the initial word and all subsequent words except articles, conjunctions, and prepositions. Transliterate languages that use a non-Roman alphabet according to the Library of Congress system. Underline (for italics) titles of journals and series and titles of books that are not part of a series. Use the parentheses/colon system for volume(number):pagination: "10(2):5-9." For alignment and arrangement of elements, follow the format of recent publications in the series for which the manuscript is intended. Guidelines for preparing bibliography may be secured from Series Section, SI Press.

Legends for illustrations must be submitted at the end of the manuscript, with as many legends typed, double-spaced, to a page as convenient.

Illustrations must be submitted as original art (not copies) accompanying, but separate from, the manuscript. Guidelines for preparing art may be secured from Series Section, SI Press. All types of illustrations (photographs, line drawings, maps, etc.) may be intermixed throughout the printed text. They should be termed **Figures** and should be numbered consecutively as they will appear in the monograph. If several illustrations are treated as components of a single composite figure, they should be designated by lowercase italic letters on the illustration; also, in the legend and in text references the italic letters (underlined in copy) should be used: "Figure 9*b*." Illustrations that are intended to follow the printed text may be termed **Plates**, and any components should be similarly lettered and referenced: "Plate 9*b*." Keys to any symbols within an illustration should appear on the art rather than in the legend.

Some points of style: Do not use periods after such abbreviations as "mm, ft, USNM, NNE." Spell out numbers "one" through "nine" in expository text, but use digits in all other cases if possible. Use of the metric system of measurement is preferable; where use of the English system is unavoidable, supply metric equivalents in parentheses. Use the decimal system for precise measurements and relationships, common fractions for approximations. Use day/month/year sequence for dates: "9 April 1976." For months in tabular listings or data sections, use three-letter abbreviations with no periods: "Jan, Mar, Jun," etc. Omit space between initials of a personal name: "J.B. Jones."

Arrange and paginate sequentially every sheet of manuscript in the following order: (1) title page, (2) abstract, (3) contents, (4) foreword and/or preface, (5) text, (6) appendixes, (7) notes section, (8) glossary, (9) bibliography, (10) legends, (11) tables. Index copy may be submitted at page proof stage, but plans for an index should be indicated when manuscript is submitted.

