

THE SEXUAL EVOLUTION OF *SARCOCYSTIS MURIS*.

BY HOWARD CRAWLEY.

A number of years ago, at the University of Pennsylvania, an investigation of the early stages of the evolution of *Sarcocystis muris* in the intestinal cells of the mouse was undertaken. This investigation was interrupted for several years, but was resumed at the laboratory of the Zoological Division of the Bureau of Animal Industry, Washington, D. C., and the first definite results obtained were outlined in a preliminary note published in 1914 (Crawley, 1914).

In this note it was shown that following ingestion of the so-called spores of this parasite, penetration of the intestinal cells of the mouse was effected within about two hours. Once within the cells the spores rapidly underwent profound changes and after the lapse of about nine hours they had separated into two categories, which were interpreted to represent males and females. In the case of the supposed males, development took the form of a loss of most if not all of the cytoplasm, so that the parasite became reduced to a nucleus, which, however, was of considerably larger size than that of the original spore. Later, the chromatin of this nucleus became collected into a number of small rounded masses placed at the periphery. These masses, at first granular, later became solid and eventually transformed themselves into elongated, thread-like bodies, which were interpreted to be microgametes. This evolution was completed at the end of 18 hours.

Meanwhile others of the original spores went through a wholly different course of development, which was not at the time considered in detail. It was evident, however, that these elements retained their cytoplasm and eventually transformed themselves into oval cells, with rather dense cytoplasm and a vesicular nucleus containing a large karyosome. These, which were interpreted to be females, also reached the end of their development within 18 hours.

Finally, appearances suggesting fertilization were noted.

At the time when this preliminary notice was prepared, my material for the later stages, from 12 to 18 hours, was abundant and the conclusions as published were based on the findings in a number of mice. On the other hand, for the early stages only three mice were

available, these representing, respectively, the 2 to  $2\frac{1}{2}$  hour, the 3 to  $3\frac{1}{2}$  hour, and the 3 and 6 hour stages, the last being a mouse given two infecting feeds between which was an interval of 3 hours, and killed 3 hours after the second meal. It was therefore considered desirable to obtain more material for these earlier stages, and the results to be set forth herein are based upon the examination of a number of mice killed at periods of from one hour onward.

#### MATERIAL AND METHODS.

A list of the mice used, with appropriate explanatory matter, is placed at the end of the present section. During the entire course of the studies on sarcosporidiosis, every mouse obtained in whatsoever manner was given a number. In many cases these were trapped gray mice, or else white mice which had never been inoculated. Hence those used for the microscopical study of the evolution of the parasites in the cells represent but a portion of the entire series. It has been considered better, however, to retain the numbers originally given, since no confusion can possibly arise from such a procedure.

In the list appended the time in hours elapsing between the infecting meal and the death of the mouse has been placed immediately after the number of the mouse, since this is the most important datum. After this the fixing fluid is noted, and finally a statement with reference to the quantity of infectious material which the mouse ate is appended. The omission of these data in a number of cases indicates a failure to keep the record complete.

The list as given includes 38 mice, and the conclusions as set forth herein are thus based on this number of experimental animals. It is desired to lay emphasis on this point on account of the possibility of confusion with other intestinal Protozoa, such as Coccidia.

Erdmann (1914) endeavored to obtain mice in which the possibility of extraneous infection was excluded. The procedure was to raise mice from birth under as sterile conditions as possible. This, of course, is the ideal method, but, as Erdmann states, it is tedious and difficult. The other method is to use a large series of mice, which will presumably yield results that cannot be questioned. Thus, if, after feeding, parasites are found in the cells which are evidently *Sarcocystis* spores and if, as time passes, these intracellular elements undergo serial changes it would seem to be hypercritical to question their identity as stages in the evolution of *Sarcocystis muris*. For it would be necessary to assume that each experimental mouse harbored Coccidia in addition to the Sarcosporidia and that

in each and every case the *Coccidia* happened to be in precisely such a stage as to resemble the *Sarcosporidia*. The mathematical probability of this taking place diminishes with the number of mice used and when this number is large becomes a vanishing quantity.

Of course, since protozoan infections naturally tend to assume the epizootic form, if one or two mice from a given cage were found to be infected with *Coccidia*, the surmise would be warranted that many or all of the others were so infected. But in the case of the series upon which the present studies were based, the mice were obtained from various sources and from various places and in many cases had never been in contact. It is therefore believed that the results as stated are valid, so far as concerns the possibility of confusion with *Coccidia*.

The mice selected for inoculation were deprived of food for 24 hours. This served a two-fold purpose. It rendered them more prone to eat the infectious material when given and it served to free the intestine of half-digested vegetable food, the presence of which interferes with sectioning. For the short periods, up to 18 hours or so, the mice were given a piece of infected muscle of what was regarded as an appropriate size. This was larger or smaller, according to the number of cysts it contained; and when these were abundant the portion given had a weight of the order of one-tenth of a gram.

When the mouse is given its infecting meal, any one of several things may happen. Some mice positively refuse to touch the meat, while others merely play with it for a time and then abandon it. More usually, however, the mouse feeds, and the customary method is for it to hold the food in its forepaws and nibble at it until it is all consumed. This procedure, however, may be interrupted by delays, but if the entire time required to finish the meal is short in comparison with that to elapse between feeding and death, the mouse may be used. Finally, in some cases the meal was bolted in the manner in which a dog feeds.

At the end of the proper period the mouse was chloroformed, opened, and the alimentary canal removed. In nearly all cases it was placed in the killing fluid entire, being neither cut into pieces nor slit open. The intestine of a mouse has such thin walls that the fluids have no difficulty in penetrating, and this procedure does away with the rough handling necessary in slitting the intestine. It moreover retained the intestinal contents, an obvious advantage, and a comparison with slit intestines showed that the fixation was equally accurate. The only disadvantage was that at times the penetration

of the fluids from the muscularis toward the epithelium resulted in the latter being torn loose from the underlying connective tissue. At least this phenomenon was not infrequently manifest and is presumably to be credited to the direction of entrance of the fluids.

Following fixation, each intestine was cut into pieces of a convenient length for embedding in paraffin. In general, the small intestine was cut into 25 to 30 pieces which were numbered, as a rule, from the anterior to the posterior end. Thus, int. 1 of a given mouse indicated the piece immediately following the stomach, the highest or last number that piece immediately in front of the cæcum. Sometimes, however, this process was reversed, the last piece of the intestine being designated as int. —1; the next to the last, int. —2, and so on, the negative signs serving to distinguish such cases from the more usual procedure. This, as already noted, is applicable to the small intestine alone, the cæcum and large intestine being given other designations. The procedure as outlined above was not, however, always followed.

The fixing fluids used were:

1. Hermann's fluid, stronger formula.
2. Zenker's fluid.
3. Picro-acetic acid, made by reducing a saturated aqueous solution of picric acid to one-half strength with water, and adding 1 per cent. glacial acetic acid.
4. An alcoholic-corrosive-acetic mixture, designated in the text as A. C. A. The formula for this is as follows:

Saturated aqueous solution of mercuric chloride .....	50 parts.
Alcohol, 95 per cent.....	50 parts.
Glacial acetic acid .....	5 parts.

Of these, Hermann's fluid and the picro-acetic mixture, the latter despite Lee's strictures, gave the most delicate fixation. Zenker's fluid is not to be recommended, since it leaves the tissues in poor condition for staining and is at best a mediocre fixative.

The A. C. A. fluid, while scarcely so accurate as Hermann's fluid, is none the less a very good fixative. It is, moreover, very convenient, since the tissues can be passed directly from it into alcohol, and it leaves the material in excellent condition for staining.

The material was stained both in bulk and on the slide. While there is a prejudice against the former method for delicate cytological work. Delafield's hæmatoxylin counterstained on the slide with alcoholic eosin or acid fuchsin dissolved in 95 per cent. alcohol, gives

results not far short of the best slide staining. The use of counterstains in alcohol is a great time-saving device, since the preparation has but to be passed from xylol, to absolute alcohol, to 95 per cent. alcohol, to the stain and back again to be ready for the Canada balsam. Moreover, if acid fuchsin be used, one quick dip in the stain is sufficient.

For slide staining, iron hæmatoxylin, Wright's and Giemsa stains and thionin were used either with or without counterstains. The blood stains used alone are unsatisfactory, since only the blue ingredients seem to take hold of the tissues. Wright's stain, counterstained with alcoholic eosin, however, gave very good results. The technique was as follows: The slide holding the sections was first treated as a blood smear and allowed to lie with the mixture of stain and water upon it for 10 to 15 minutes. It was then washed first in water and then in 95 per cent. alcohol until all of the precipitated stain had dissolved. It was then stained with eosin dissolved in absolute alcohol, next passed into clean absolute alcohol, and finally into xylol. Wright's stain comes out very rapidly in alcohol, but the whole procedure as above outlined can be completed in a very short time.

Thionin preparations counterstained in either alcoholic eosin or acid fuchsin in alcohol were largely used and gave in some respects the best results. Preparations so stained display beautifully sharp and clear-cut pictures, and they are very good when it is a question of bringing out the chemical qualities of different parts of the parasites. On the other hand, thionin fails to bring out certain granules in these Sarcosporidia which are perhaps significant, and slides stained in thionin are not permanent.

Accordingly, most of the slides were stained with iron hæmatoxylin. With material fixed in Hermann's fluid, a counterstain is not necessary, although it was often used. With the other fixatives a counterstain was necessary, and acid fuchsin was the one most generally employed.

The list of mice used follows:

Mouse 77	15 hours.		
99	3 and 6 hours.		
106	9 hours	A. C. A	Heavy meal.
120	10½ and 17 hours		Heavy meal.
121	10½ and 17 hours		Heavy meal.
125	2¼ hours	Hermann's fluid.	
126	3¼ hours	Piero-acetic.	
132	8½ hours	Hermann's fluid	Heavy meal.
133	9 hours	Hermann's fluid	Heavy meal.
145	11¼ hours	Hermann's fluid	Moderate meal.



146...	11½ hours	Hermann's fluid	Moderate meal.
147...	21 hours	Hermann's fluid	Moderate meal.
148...	18 hours	Hermann's fluid	Moderate meal.
149	24 hours	Hermann's fluid	Moderate meal.
150.	24 hours	Hermann's fluid	Moderate meal.
152	18 hours.	Hermann's fluid.	
153	24 hours	Hermann's fluid	Heavy meal.
154	24 hours.		
175	12½ hours	Hermann's fluid.	
176	13¼ hours	Hermann's fluid.	
177	14¾ hours	Hermann's fluid.	
178	15¾ hours	Hermann's fluid.	
179.	16¾ hours	Hermann's fluid.	
180	17¾ hours	Hermann's fluid.	
181	18½ hours	Hermann's fluid.	
182	18 hours.	Hermann's fluid.	
246.	1 hour	A. C. A	Light meal.
247.....	4 hours...	A. C. A.....	Heavy meal.
248.....	2 hours...	A. C. A.....	Moderate meal.
249.....	3 hours...	A. C. A.....	Moderate meal.
250.....	5 hours...	A. C. A.....	Heavy meal.
251	1½ hours	A. C. A	Very light meal.
252	2½ hours.	A. C. A	Very light meal.
253	6 hours	A. C. A	Heavy meal.
257	3 hours...	Hermann's fluid...	Moderate meal.
258	4 hours...	A. C. A.....	Moderate meal.
261	4 hours.	Hermann's fluid	Heavy meal.
262	5 hours	Hermann's fluid	Moderate meal.

Prior to taking up the description of the findings in the cells, it is desirable to call attention to a phenomenon first signaled by Erdmann (1910). This is the exfoliation of the intestinal epithelium which appears to follow ingestion of the spores of *Sarcocystis*. The natural inference would be that this was due to the invasion and subsequent destruction of the cells by the parasites, and such was my original idea (Crawley, 1913). No doubt a certain amount of exfoliation is to be accounted for in this way, but other factors are involved. Thus Erdmann found that the ingestion of an extract of *Sarcocystis* cysts, from which the spores themselves had been removed, was followed by exfoliation, and data that I shall now give show that the exfoliation takes place before any extensive invasion of the cells.

The intestines of a series of mice, all of which had been killed within 6 hours after feeding, were examined and the conditions presented by the epithelium in various parts of the intestine noted. The results of this examination are tabulated below. Where no exfoliation was demonstrable, the condition is indicated by the word "none." Where, however, it is in evidence it is designated as "slight," "moderate," or "severe," according to its degree.

## MOUSE 246, 1-HOUR STAGE.

Int. 1.....	Exfoliation slight.
3.....	Exfoliation moderate.
5.....	Exfoliation none.
7.....	Exfoliation slight.
9.....	Exfoliation slight.
11.....	Exfoliation moderate.
13.....	Exfoliation severe.
15.....	Exfoliation severe.
17.....	Exfoliation slight.
19.....	Exfoliation none.
21.....	Exfoliation severe.
23.....	Exfoliation slight.
25.....	Exfoliation none.

## MOUSE 251, 1½-HOUR STAGE.

Int. 1.....	Exfoliation none.
3.....	Exfoliation none.
7.....	Exfoliation none.
9.....	Exfoliation none.

## MOUSE 248, 2-HOUR STAGE.

Int. 3.....	Exfoliation slight.
8.....	Exfoliation none.
9.....	Exfoliation none.
15.....	Exfoliation slight.
21.....	Exfoliation slight.
26.....	Exfoliation none.
27.....	Exfoliation none.
28.....	Exfoliation none.
30.....	Exfoliation very slight.
32.....	Exfoliation very slight.

## MOUSE 249, 3-HOUR STAGE.

Int. 2.....	Exfoliation moderate.
6.....	Exfoliation none.
8.....	Exfoliation none.
10.....	Exfoliation none.
12.....	Exfoliation none.
17.....	Exfoliation moderate.
18.....	Exfoliation slight.
19.....	Exfoliation slight.
20.....	Exfoliation very slight.
22.....	Exfoliation none.
24.....	Exfoliation none.
29.....	Exfoliation slight.
30.....	Exfoliation none.
31.....	Exfoliation none.

## MOUSE 261, 4-HOUR STAGE.

Int. —1.....	Exfoliation none.
—3.....	Exfoliation slight.
—5.....	Exfoliation slight.

## MOUSE 247, 4-HOUR STAGE.

Int. 12.....	Exfoliation none.
14.....	Exfoliation none.

16	Exfoliation slight.
18	Exfoliation slight.
19	Exfoliation slight.
30	Exfoliation slight.
31	Exfoliation very slight.

MOUSE 262, 5 to 3-HOUR STAGE.

Int. -1	Exfoliation none.
-2	Exfoliation slight.
-3	Exfoliation slight.
-4	Exfoliation severe.
-5	Exfoliation moderate.
-6	Exfoliation moderate.

MOUSE 250, 5-HOUR STAGE.

Int. 21	Exfoliation none.
22	Exfoliation none.
30	Exfoliation moderate.
31	Exfoliation moderate.
32	Exfoliation slight.
33	Exfoliation moderate.

MOUSE 253, 6-HOUR STAGE.

Int. 10	Exfoliation slight.
15	Exfoliation slight.
16	Exfoliation none.
19	Exfoliation questionable.
25	Exfoliation slight.
27	Exfoliation none.
28	Exfoliation none.
29	Exfoliation none.

As already stated, as a result of the method of fixing the mouse intestine, the epithelial row was at times torn loose from the sub-epithelial connective tissue. It thus results that in some cases the material presented a decidedly battered appearance. While, however, the epithelial row itself might thus be torn loose and more or less broken, the individual cells were not thereby injured and their appearance indicated an accurate fixation.

On the other hand, it was frequently possible to see that the cells at the tips of the villi were abnormal, this abnormality expressing itself in a loss of staining capacity on the part of the cytoplasm and an obvious degeneracy of the nuclei. This degeneracy, at first affecting only the cells at the tips of the villi, passes into a condition in which these cells have disappeared, while those lying along the sides of the villi are affected. This condition, in its turn, passes into one in which the villi are represented merely by stumps of connective tissue, the epithelium being present only in the regions between the bases of the villi. Finally a stage is reached in which the intestine is wholly denuded of epithelium. In the lists given



the term "slight" defines those conditions in which epithelial degeneration is just beginning to be manifest, and "moderate" conditions where the tips of the villi are seriously affected, and "severe" conditions where the destructive influence has gone further.

The data given in the above lists seem to establish the fact that exfoliation of the epithelium is correlated with ingestion of the spores of Sarcosporidia, but they are not consistent amongst themselves. Thus, mouse 248, a 2-hour stage, is not so badly affected as mouse 246, killed only one hour after feeding, whereas mouse 251, a 1½-hour stage, shows no exfoliation at all, although in this last case observations were confined to only a small part of the intestine.

In the cases of Nos. 249 and 261, both 3-hour stages, and No. 247, 4-hour, exfoliation is not extensive, while No. 262, 5- to 3-hour, shows a considerable amount near the posterior end of the intestine, as does also No. 250, 5-hour. On the other hand, mouse 253, killed 6 hours after feeding, is but slightly affected. In view of the rather contradictory nature of the data, it is impossible to attempt any explanation of the *modus operandi* of loss of the epithelium.

Erdmann suggested that the destruction of the epithelium was an adaptation having for its purpose the easier penetration of the spores into the tissues of the mouse. Presumably this destruction is correlated with ingestion of the parasites, but if it be of any value to host or parasite it seems more plausible to regard it as a defensive move on the part of the former. In their attack upon the mouse the parasites first invade the epithelial cells and this they do within the first two or three hours. Obviously, then, the destruction of this epithelium, either before or after penetration by the parasites can only work to their disadvantage. Hence, while it is possible to look upon this exfoliation as an adaptation on the part of the host, there seems no good reason for so doing. It is a matter of observation that exfoliation follows the ingestion of sarcosporidian cysts, but it is also a matter of observation that such ingestion is practically always followed by infection of the muscles. Hence, the exfoliation is obviously not protective.

The matter is, however, one of minor importance and the data are merely given for what they are worth.

#### EVOLUTION OF THE PARASITES IN THE CELLS. .

The account of the findings in the cells may appropriately be begun with mouse 246, killed one hour after feeding. As indicated in the table on p. 8, slides were prepared from the alternate pieces

of the intestine from one end to the other. The anterior portions, Nos. 1 to 11, were wholly negative, there being no spores either in the lumen or in the cells. Beginning with int. 13, however, spores were present in the lumen, and they were seen in the cells in int. 19, 23, and 25. Their absence from int. 21 is to be credited to the severe exfoliation there present.

From int. 13, where the spores were first seen in the lumen, there was a rapid increase in their numbers in each successive piece, and in the lumina of int. 23 and 25 they were present in enormous numbers. From this it is evident that it requires but one hour for the ingested spores to reach the extreme posterior end of the small intestine, and as shown both by this and other mice, apparently the great majority of them reach this situation very quickly. While they have also been found in the cæcum in very early stages, they evidently do not pass from the small intestine into the cæcum as readily as they pass along the small intestine itself. This is evidenced by the fact that in the earlier stages—up to 9 hours or thereabouts—the last two or three centimeters of the small intestine always harbor spores free in the lumen.

There is thus brought about a state of affairs of some interest when the earlier stages of the evolution of the parasites is under consideration. It is evident that the spores pass along the small intestine very rapidly until the posterior end is reached. The length of time required for this stream of spores to pass a given point will obviously vary in the different mice. In those cases where, as a result of prolonged nibbling, the ingested meat reaches the stomach thoroughly comminuted, we may presume that its stay in the stomach is shortened and its movement along the small intestine more rapid. On the other hand, when the meal is swallowed in large pieces, the presumption is that it will remain in the stomach until it is softened and disintegrated, and in consequence its progress along the small intestine will be delayed. Nevertheless, digestion in mice of purely animal matter is rapid, and in general at the end of a few hours spores are scarce in the lumen of the upper and middle portions of the small intestine. If, as a pure guess, we may assume that the stream of spores requires one hour to pass a given point, then the spores within the cells in any particular part of the intestine (except the posterior end) will all have entered the cells within an hour of one another. On the other hand, as we have seen, great numbers of the spores reach the posterior part of the intestine within one hour, and remain there for several hours, as is shown by finding them in this

situation in 9-hour stages. During the whole of this time it cannot be questioned that individuals are constantly penetrating the cells.

Therefore it seems reasonable to assume that within certain limits, the intracellular spores in a given section of the upper or middle parts of the intestine will be in somewhat the same developmental stage. On the contrary, in the posterior part of the intestine, the intracellular spores will represent a series in the development, covering the greater part of the period of time elapsing between feeding and the death of the mouse. Thus, in a 9-hour mouse, the parasites in the cells of this extreme posterior part of the intestine might represent forms which had been in the cells from only a few minutes up to seven or eight hours, and in Nos. 132 and 133 it was evident that this was the case.

It further follows that in these posterior portions many more cells are parasitized than elsewhere, since there is here maintained for several hours a large supply of extracellular spores.

Returning to the conditions as found in mouse 246, intracellular spores in small numbers were found in int. 19, 23, and 25. These, of course, represented the very earliest stages in the development and in the main were not to be distinguished from those in the lumen. In some cases, however, development had begun, thus demonstrating the extreme rapidity with which these parasites go through with their evolution. The mounted material of this mouse, however, was prepared with a view of getting a general survey of the conditions rather than for detailed cytological study. Hence, no figures of the parasites as found here have been made.

*Mouse 251.*—Mouse 251 was killed  $1\frac{1}{2}$  hours after feeding. According to the observations made at the time of the infecting feed, it received "a very light meal," but when the stomach and intestine were prepared for study the findings suggested that whereas relatively the meal may have been very light, positively such a definition seemed scarcely appropriate. In the stomach, from which the epithelium had largely disappeared, there were abundant cysts of the parasite, many of which were more or less intact and contained the greater number of the spores. In int. 1, 3, 5, and 7 there were abundant spores in the lumen, and in int. 9 they were present both in the lumen and in the cells.

Comparing the conditions found here with those in mouse 246, it is to be noted that in the latter the spores were further back toward the end of the intestine. In No. 246 the upper portions of the intestine were free of spores, whereas in 251 these same portions

contained them in considerable abundance. These differences are, as already suggested, probably to be accredited to differences in the manner in which the two mice fed.

Taking up now the evolution of the spores within the intestine of the mouse, we may advantageously use as a point of departure the spore as it occurs free in the lumen, for it is evident that development begins here.

Plate I, fig. 2, portrays such a spore and may be taken as the point of departure, although in all the early stages the spores in the lumen are identical with many of those in the cells. This particular case is from mouse 248, a 2-hour stage, but it is valid for any of the early stages.

The characteristics of this stage are as follows: The contours of the cell are sharp and clear cut, and there is a distinct bounding line or periplast. The cytoplasm, while obviously alveolar, is dense and ordinarily stains well. Granules may or may not be present. The nucleus, which is conspicuous, is round and gives the appearance as though in life it were turgid with nuclear sap. There is a distinct nuclear membrane and a more or less distinct nuclear net is always present.

With regard to its shape, the spore in the lumen may be a smooth oval, as, for examples, are the intracellular spores shown in Plate I, figs. 3 and 4, or it may have the sides more or less bulged out in the region of the nucleus. This latter phenomenon is due to the increase in size of the nucleus, a process initiated very shortly after the spore reaches the alimentary canal of the mouse.

The appearance of the spores in the intestine, whether they be in the lumen or in the cells, offers a considerable contrast to that of spores removed from the cysts. With regard to these latter, a description is herewith given, although they are familiar objects in the literature and have been described and figured a number of times.

Such spores are shown in Plate I, fig. 1. As is here indicated, one end of the spore is broader, the other end narrower, and the nucleus lies nearer the narrow end.

The internal structure is obscure. The nucleus is a clear-cut vesicle, and to all appearances is provided with a definitive membrane. No internal structure can be made out, and the staining reaction is feeble. In Giemsa preparations it stains a pale reddish color.

The cytoplasm with Giemsa stains a dense blue. Its structure can

scarcely be determined, but it may be inferred that it is alveolar. It is densest in the immediate vicinity of the nucleus. The broad end of the spore is frequently much less dense than elsewhere and at times shows a more or less well defined oval area. This appearance, however, is probably due merely to the fact that here the cytoplasm has a lower affinity for the stain than elsewhere.

The same phenomenon is shown by the spores of *Sarcocystis leporum* (Crawley, 1914). In the case of the rabbit parasite, as I have endeavored to show, one end of the spore seems to be differentiated into a sort of rostrum, the cytoplasm of which does not stain as densely as does that of the balance of the spore. We are probably dealing with the same thing in the case of *Sarcocystis muris*, but in this parasite the differentiation of the rostrum is not so sharp. It may furthermore be suggested that it is this clearer region in the spore which has given rise to the belief, expressed by some authors, that the sarcosporidian spore possesses a polar capsule.

Comparing the spores taken directly from a cyst with those in the intestine, the latter are broader, more oval bodies, and, although this is not shown by the figures, there has been a loss of the granules which are such a characteristic feature of the former. The most noteworthy change, however, concerns the nucleus, which has become larger, apparently much more turgid, and begins to show a nuclear net.

It is thus evident that evolution begins as soon as the spore reaches the intestine of the mouse, and apparently the most important step is a great increase in activity of the nucleus. This evolution, however, does not appear to be carried far unless the spore gains a resting place within a cell of the host.

The cells invaded are the cylinder cells. At least this is so in the vast majority of cases. Now and then, however, parasites are to be found in mucous cells, but since the presence of a parasite in a cell may result in mucoid degeneration, it is difficult to diagnose such instances. The parasite may have invaded a mucous cell or it may have caused mucoid degeneration of a cylinder cell. This question, however, appears to be of no great importance.

It is also well to emphasize the point that the spore is a naked mass of protoplasm and that the only differentiation displayed by the cytoplasm is the peripheral condensation into a periplastic layer. Statements to the effect that the spore opens and releases an amœbula are wholly without warrant, and polar filaments, either coiled up within one end of the cell or discharged, do not exist. Claims of



this sort, which have appeared in the literature from time to time, seem to be due to an unfortunate desire to correlate the Sarcosporidia with the Myxosporidia. These two groups may of course be closely related, but as yet there is no conclusive evidence on hand to show that they are.

Plate I, figs. 3 and 4 show spores in the cells of int. 9 of mouse 251, a  $1\frac{1}{2}$ -hour stage. It is to be noted that each of these lies in a vacuole. Probably they have not been in the cells for more than an hour. In both of them the cytoplasm is dense, compact, and deeply staining. In both of them, also, the nucleus has enlarged and is separated from the periplast only by very narrow strips of cytoplasm.

There is, however, a difference in the nature of the net in these two nuclei. In the case of fig. 3, the meshes in the centre are solidly filled with chromatin, whereas in that of fig. 4 the chromatin is divided into separate masses. In all of these early stages the chromatin has a low affinity for stains, and, following the rule which seems to hold generally true in Protozoa, takes the acid rather than the basic stains. On this account it results that these nuclei are rather difficult microscopical objects, and seen with powers of less than 1,000 diameters, a nucleus like that of fig. 3 looks like a vesicle containing only a central granule. But with a magnification of 1,500 to 2,000, and an intense artificial light, the structure as shown in the figure is brought out. As will be shown later, fig. 3 represents the more primitive condition, in which the chromatin is concentrated into a single mass, within which, however, the meshes of the nuclear net can be traced. In the case of fig. 4, the chromatin occurs in separate masses and the central meshes of the net are largely clear. Nuclei precisely like either of these may be seen in spores in the lumen.

*Mouse 248.*—Mouse 248 was killed two hours after feeding. Its intestine was cut into 32 pieces, int. 32 representing the extreme posterior portion. Observations were made on int. 3, 9, 15, 21, 27, and 32. In the upper portions there were scattered spores in the lumen and occasional specimens in the cells, but, following the general rule, parasitization was not extensive until the more posterior parts were reached.

Plate I, fig. 5, from int. 27, shows a parasite lying in the usual vacuole close to the free edge of the epithelium. The cytoplasm is dense, while the nucleus shows very distinctly a nuclear net supporting scattered chromatin granules. The nucleus, in this case, lies near one end of the cell. Fig. 6, from int. 30, also represents what is clearly a very early stage. The cytoplasm is dense and compact.

the cell contours are sharp and a periplast can be seen. The nucleus, however, shows merely as a faintly stained vacuole containing some formed substance, the details of which could not be made out. It may here be remarked that in most of the cell parasites the nucleus appears as a vesicle containing a nuclear net, and that in general this nuclear net is the only part of the nucleus that stains. Hence the net appears as though projected against a clear background. On the other hand, it is frequently to be observed in the spores free in the lumen, and much less frequently in those in the cells, that the nuclear sap as well as the nuclear net has taken the stain, thus obscuring the details of the latter. This condition is illustrated by fig. 6.

In the preliminary note it was stated that at least a portion of the intracellular spores rapidly underwent a change which expressed itself in a reduction of the cytoplasm and an increase in the size of the nucleus, the ultimate result of which was the production of a body which was apparently only the enlarged original nucleus, the cytoplasm having apparently all disappeared. This, it was stated, was interpreted to be the male form.

This evolution is illustrated in Plate I, figs. 7 to 11. Fig. 7 shows the nuclear enlargement with no great amount of cytoplasmic reduction. The nucleus is large and turgid, it causes the sides of the parasite to bulge and shows a distinct net. This net consists of a central aggregation from which strands run to the periphery. As already indicated in the discussion of figs. 3 and 4, whereas the appearance of this central aggregation differs considerably in the different specimens, its structure appears to be fundamentally the same throughout. It seems to be merely the close-meshed central part of the nuclear net, with the interspaces sometimes empty and sometimes filled in with faintly staining chromatin. The latter is the more primitive condition.

The parasite shown in fig. 7 was from int. 15, or about the middle of the intestine, and hence is presumably that of a parasite which has been within the cell for some little time. Except, however, for the notable enlargement of the nucleus, it has all the characteristics of a very early stage.

Fig. 8, from int. 30, represents a condition in which there has been as yet no great amount of nuclear enlargement, but a slight degree of cytoplasmic degeneration. In fig. 9 there is shown nuclear enlargement accompanied by a considerable degree of cytoplasmic degeneration, as is evidenced by the vacuolization and rough contours of the

cell. In fig. 10 the nucleus projects out from the sides of the cell, while the cytoplasm is reduced and shows uneven contours. In fig. 11 there is seen both nuclear enlargement and cytoplasmic reduction.

The initial steps in the evolution of the male element are illustrated by the figures just described. The details of this evolution vary greatly, and it is doubtless true that this variation in detail is the result not only of variations in the actual biological process itself, but is also dependent on the technique. Thus, in iron hæmatoxylin preparations there are always associated with the nucleus one or more intensely black granules which are either not visible at all or only faintly visible in Delafield or thionin preparations. Furthermore, in material stained in thionin the cytoplasm is frequently seen to be separated into two portions, as shown in Plate I, figs. 12, 13, and 14. Here the cytoplasm is broken up into a number of lumps or streaks either lying embedded in a faintly staining ground substance (figs. 12 and 14) or apparently lying free in the vacuole which the parasite always produces in the mouse cell (fig. 13). It is evident that one of these conditions is readily derivable from the other. Thus, in figs. 12 and 14, the cytoplasm has separated into a chromophil substance lying within an almost achromatic substance. This latter gradually disappears, producing the condition shown in fig. 13.

A high affinity for chromatin stains is characteristic of the by-products of protoplasm, and is especially well brought out by thionin. Thus, in material so stained, both degenerate nuclei and mucus are deeply stained. In the former case we are dealing with a pathological, in the latter with a physiological process, but in both with protoplasmic by-products. In the case of these Sarcosporidia, the great increase in the size of the nucleus seems to predicate a supply of pabulum, and the suggestion is at least permissible that this pabulum is supplied by the cytoplasm. If this were so, the presumption would be that the densely staining flecks, as noted in figs. 12, 13, and 14, represent the cytoplasmic debris remaining after the nucleus has robbed the cytoplasm of a part of its substance. It is of course to be understood that the above is put forth merely as a possibility, the matter being one scarcely open to a rigid demonstration.

*Mouse 125.*—As noted in the list given on p. 6, this mouse represents the conditions from 2 to 2½ hours after feeding. These are in all essentials the same as those of mouse 248, as is evidenced by figs. 15, 16, and 17. In the case of fig. 17, Plate II, it is to be noted that

the cytoplasm is greatly reduced in quantity and is vacuolated, while in all three the nucleus is enlarged and shows the usual nuclear net.

*Mouse 249.*—This animal was killed three hours after feeding. Its intestine was cut into 31 pieces numbered from 1 to 31. Observations were made upon the stomach and upon int. 2, 6, 8, 10, 12, 18, 20, 22, 30, and 31. The stomach and the first five pieces of the intestine examined were negative. In int. 18 spores were present in the lumen; in int. 20, 22, 30, and 31 they were found both in the lumen and in the cells.

It has already been shown (p. 11) that in some of the mice the spores move along the intestine very rapidly, yet it is always to be remembered that the failure to find them in a few selected slides is not proof of their absence from the particular portions of the intestine from which these slides were made. In this mouse it seems unlikely that so much of the intestine was actually negative.

It is in mouse 249 that the differentiation into males and females first begins to be noticeable. In the case of the males, in which the characteristic changes consist of a great enlargement of the nucleus and a reduction of the cytoplasm, there is no confusion, since these changes are conspicuous and readily detected.

Thus, Plate II, figs. 18, 19, and 20 are all obviously males, since they all show nuclear enlargement and cytoplasmic reduction. A particularly good earmark of the males is the fact that the nucleus is not surrounded by cytoplasm, the parasites consisting (fig. 18) of an enlarged nucleus provided with two tongue- or cap-shaped masses of cytoplasm. The conspicuous black granule, mentioned above as appearing in iron hæmatoxylin stains, is to be seen in fig. 20, whereas fig. 19 shows a stage wherein the cytoplasm is nearly gone and the nucleus has reached a size equal to that of many of the entire parasites.

On the other hand, the differences between the female and the original spore are by no means so striking. The female is relatively shorter and broader, while the nucleus is sometimes larger and, as a rule, shows the chromatin concentrated into a single large karyosome. There is, however, no loss of cytoplasm. Moreover, with an exception to be noted below, the female undergoes no such conspicuous changes in the course of its evolution as does the male. In consequence, in these early stages it is always difficult and sometimes impossible to say whether a given parasite is a female or merely one which has been in the cell a short time.

Hence, it is only with much reserve that fig. 21, Plate II, may be pro-

nounced that of a female. It possesses, however, the rather densely staining cytoplasm characteristic for the females and the nucleus is too small for a male. The deeply staining granules present in iron hæmatoxylin material are here in evidence.

Fig. 22 probably also represents a female since it is a smoothly oval cell with dense cytoplasm, and the nucleus, while large, does not cause any protrusion of the sides of the cell. The radiate nuclear structure in this parasite is peculiar for such an early stage, and may represent a very precocious case of maturation (see p. 30).

*Mouse 126.*—This mouse was given the flesh of an infected animal at a stated time and required one-half an hour to complete its meal. It was killed three hours later and in consequence represents the conditions 3 to 3½ hours after inoculation. Figs. 23 and 24, Plate II, are from this mouse and show early male stages, as evidenced by the enlarged nuclei and the scanty quantity of cytoplasm present.

*Mouse 261.*—Mouse 261 was given a piece of infected muscle at 10 A.M. (Feb. 15, 1915). It began to eat at once and consumed a considerable quantity of the infected material, but did not then complete the meal. At 2 P.M. the mouse was chloroformed, the infected muscle having been eaten in the interim. Hence, it represents the conditions from 4 hours down to some shorter period. The only portions of the intestine examined in this case were int. —1 to int. —5, or the last five pieces. The intestine of this mouse was slit open prior to fixation and in consequence the spores in the lumen were lost.

Since the study here was confined to the last few centimeters of the intestine, a given intracellular spore might have been in its place anywhere from a few minutes to three hours or more, and hence it is impossible to pick out the early female stages with any degree of certainty. Thus, fig. 25 might be either that of an early female stage or of a parasite which had been in the cell for only a short time. It is perhaps the same with fig. 26 which represents a form difficult to classify satisfactorily. On the other hand, fig. 27 is an evident early male, and both this and fig. 26 are of interest in showing very clearly the nuclear structure.

In a few cases, in mouse 261, males were found in which the loss of cytoplasm was complete.

*Mouse 247.*—This mouse was killed four hours after feeding. Its intestine was cut into 34 pieces, from int. 1 to 34, and observations were made on int. 12, 14, 16, 19, 30, and 33.

The differentiation into males and females is here carried a little



further, although it is still difficult to get forms that can positively be diagnosed as females.

An evident female, however, is shown in fig. 28, Plate II. This is taken to be a female on account of its shape, its retention of the cytoplasm, and the character of its nucleus. This latter element, as is shown by the figure, is vesicular, with a sharply defined nuclear membrane and a central mass of chromatin from which strands radiate to the periphery. Fig. 29 shows another female. This figure is diagrammatic, but is essentially like fig. 28. Both of these figures were obtained from int. 14 of the mouse; that is, from the anterior half of the intestine, and hence the presumption is that both of the parasites drawn had been in the cells for some considerable time.

Fig. 30, from int. 19, may also be that of a female, although here the diagnosis is more doubtful, since the form rather suggests a parasite which has been in the cell for only a short time.

In addition to the females, characteristic early males were seen in the cells of this mouse.

*Mouse 250.*—This mouse was killed five hours after feeding. Its intestine was cut into 34 pieces, numbered from 1 to 34, and observations were made on int. 21, 22, and 32.

In this mouse it is much easier to distinguish between the males and females, since the two lines of development have become well separated. Thus, figs. 31 and 32, Plate II, represent males which have reached what might be termed the nuclear stage; that is, the stage in which the cytoplasm has nearly or quite disappeared.

Thus, in fig. 31, the cytoplasm has all disappeared except for a cap of degenerate-looking material at one end of the nucleus. The nucleus itself shows the usual net, associated with which are several black granules. Centrally there is an irregular mass of acidophil chromatin in which lies a large black granule. This probably represents the karyosome.

Fig. 32 also represents a male. There is here to be seen a well-defined net of rather broad strands and a number of black granules. The meshes of the net are in some places filled with faintly staining material. A karyosome does not appear to be present, although the large black granule may perhaps represent it. The crescent of staining substance at one end of the nucleus may represent the remnant of the spore cytoplasm, but more probably is a crescent of host tissue which not infrequently forms at the end of the vacuole in which the parasite normally lies. Its actual detachment from the parasite suggests it is the latter, and if this be so the cytoplasm of

the parasite has wholly disappeared and the vacuole in which the nucleus lies is the vacuole originally formed by the parasite.

Fig. 33, Plate II, represents a parasite from the same slide and same section of the intestine as figs. 31 and 32. It is clearly a female. The entire parasite is sharply outlined, and the cytoplasm is dense, although showing several vacuoles. The nucleus is clear cut and contains a large, rather faintly staining karyosome, together with two black granules. One of these granules lies within the karyosome, the other appears to be in the space between the karyosome and membrane, but it is possible that it actually lay upon the membrane itself. In this particular case, strands connecting the karyosome with the nuclear membrane could not be detected.

Fig. 34 was also obtained from the same slide as figs. 31, 32, and 33, but not from the same section. The parasite was clearly outlined. The cytoplasm, while not suggesting degeneration, was not homogeneous, but appeared to consist of a matrix in which were a number of poorly defined denser areas. This is an appearance frequently to be noted in the early female stages, but it has not been possible to work out its significance. The nucleus of this parasite was clear cut and contained a large, faintly staining karyosome. Little strands radiated from the karyosome, but these could not be traced to the nuclear membrane. Two black granules were present, one within or upon the karyosome, the other on the nuclear membrane.

The four parasites here figured and described typify conditions as found in mouse 250. They appear to furnish satisfactory evidence that the spores, after their invasion of the cells, separate into two groups, the later evolution of which indicates that they are to be regarded as males and females. This evolution, moreover, proceeds at such a rate that at the end of five hours at least a considerable number of the parasites can be separated into males and females. It is also believed that the cases herewith considered are the more convincing in that they were all taken from exactly the same place in the intestine. This was the twenty-second piece of an intestine cut into 34 pieces and therefore only two-thirds the way from the anterior end. This permits of the presumption that these four parasites had all entered the cells at somewhat the same time, and that this was perhaps four hours prior to the death of the mouse.

It is of course to be understood that in the whole intestine up to 6 hours, and in its extreme posterior portions up to 9 hours, the parasites are in general in all sorts of conditions and that only a portion are differentiated into males and females. Furthermore,

it is to be understood that the figures are, as is usual in such cases, more or less diagrammatic, since it is impossible to reproduce the exact appearances as found under the microscope.

*Mouse 253.*—This mouse was killed 6 hours after feeding and its intestine cut into 29 pieces, numbered from 1 to 29. Observations were made on int. 15, 19, 25, 27, and 29.

The conditions here are, of course, very much like those of mouse 250, the cells showing evident males and females along with a number of others which had not evolved far enough to permit of their being determined. Characteristic females are shown in figs. 35, 36, and, Plate III, 37. A male is shown in fig. 38, which was taken from int. 16. This, while differing somewhat from figs. 31 and 32, is nevertheless obviously a male, since the cytoplasm has wholly disappeared and the parasite consists of nothing more than the enlarged nucleus of the original spore.

*Mouse 99.*—This mouse was given two infective feeds separated by an interval of 3 hours and killed 3 hours after the second. It therefore represents the conditions at both 3 and 6 hours after inoculation and it is usually possible, in the case of any given parasite, to say to which of the two inoculations it belongs. Thus, fig. 39 is obviously that of a male and no doubt belongs to the 6-hour stage.

#### THE LATER STAGES.

*The Male.*—The early stages of the evolution of *S. muris* have, as far as possible, been traced step by step as they occurred in mice killed from 1 to 6 hours after inoculation. At the outset the spores are apparently all alike, although it is possible that the dimorphism may be in evidence even for the spores in the cysts, as appears to be the case for the spores of *Sarcocystis colii* (Fantham, 1913). But whether this be so or not, by the end of 6 hours at least a considerable proportion of the parasites present are clearly separated into two categories.

For the later stages it is more convenient to follow these two lines of development separately, instead of considering what is found at the end of increasingly longer periods of time. For after the first eight or ten hours the time factor ceases to be of value, and both 9- and 18-hour mice, for instance, may show identical stages of evolution. The development of the male will first be considered.

As we have already seen, in the first few hours the male parasites lose most if not all of their cytoplasm and become reduced to an element which is obviously only the enlarged nucleus of the original

spore. Eventually the chromatin of these elements collects into a number of small aggregates which arrange themselves around the periphery of the parasite and transform themselves into what are evidently the microgametes. It may be assumed that the evolution of the male element, or microgametocyte, proceeds in an orderly manner, and hence it should be possible to obtain an orderly series from some such stage as that of fig. 31 (Plate II) to that of fig. 75 (Plate V). It is not, however, possible to give all of the steps of this evolution. The parasites are themselves small, ranging around 8 $\mu$  in diameter and in consequence the details of their structure require the highest powers of the microscope. There is not a great deal of staining material within them, and the picture is confused by the fact that they lie embedded within the cells of the mouse in sectioned material. It is believed that in order to work out this evolution with precision it would be necessary to develop a technique which would permit of obtaining the parasites isolated, an end which could be gained either by cultural methods or by devising some means of getting the parasites out of the cells in which they had developed. The few attempts which have been made along these lines have as yet not met with any success. It is therefore to be understood that the details of the evolution of the microgametocyte as here set forth are presented with some reserve.

Taking up now this development of the male from the stage found in the 5- and 6-hour mice to that found at the end of 18 hours, the earlier phases of it are illustrated by figs. 40 to 53 (Plate III). As it happens, most of these are from mice 106 and 120, both of which gave especially favorable material. What is seen here, however, is confirmed by the findings in other mice of the same periods.

Evidently what is found in the 2- to 6-hour mice will represent conditions earlier than those found in mice killed 9 hours or more after feeding, and in these former the nuclear net is coarse and has a low affinity for chromatin stains (see figures of these stages). It is a matter of common knowledge that the chemical nature of chromatin varies with the physiological condition of the nucleus and that this is manifested by a varying staining reaction. Thus, in the so-called resting nuclei the chromatin has a relatively low percentage of nucleic acid, and this is indicated by a relatively low affinity for chromatin stains. On the other hand, as the nucleus prepares to divide, the percentage of nucleic acid increases, and as this takes place the chromatin displays a greater and greater affinity for chromatin stains. The percentage of nucleic acid is greatest at the time

when the chromatin is divided into chromosomes, and this is also the time when it stains most intensely.

In the case of Protozoa, the resting, or better the trophic, nucleus takes the plasma rather than the chromatin stains, a fact which may be ascribed to an extremely low content in nucleic acid at such times rather than to a fundamental difference between the chemistry of protozoan and metazoan nuclei. But when in division, the protozoan nucleus stains as does that of the Metazoa, and this same staining reaction is also displayed by certain of the products of this division, such as microgametes.

It is therefore permissible to suppose that in these early male forms of *Sarcocystis muris*, the coarseness of the threads of the nuclear net is due to the fact that the achromatic filaments are bearing a quantity of chromatin poor in nucleic acid. Besides being distributed along the achromatic filaments and upon the inner surface of the nuclear membrane, the chromatin may also occur in lumps, in masses which fill up the meshes of the net, and there is apparently normally present a larger mass or karyosome.

In the course of several hours, however, this type of nucleus transforms itself into a body such as is shown in figs. 66 and 67 (Plate IV). This is an oval element containing some achromatic stringy substance and showing around the periphery a series of granular clusters. The granules composing these clusters are extremely minute, but intensely chromophil, staining as do the chromosomes of a dividing metazoan cell. In spite of their minute size they are readily resolved.

We thus start with a nucleus having a considerable bulk of chromatin which has a low affinity for chromatin stains. Morphologically, this chromatin occurs as granules, irregular masses and bands, borne either by the nuclear net or upon the inner surface of the nuclear membrane. There is also usually present a central mass or karyosome. After several hours, however, the chromatin has diminished in bulk, has an intense affinity for chromatin stains, and is placed around the periphery in the form of clusters of minute granules. The conspicuous changes then consist in the taking on of a high affinity for basic stains, subdivision into minute granules and migration to the periphery.

The desire is to show the several steps in this transformation.

The earlier conditions are shown by figs. 31, 32, 38, and 39. Figs. 31 and 32 are from mouse 250, a 5-hour stage; fig. 38 from mouse 253 (6 hours), and fig. 39 from mouse 99 and presumably represents the 6-hour stage. These four figures show very distinctly the



variations with regard to what is interpreted to be the karyosome. In fig. 32 it is either absent or represented by the large black granule. In fig. 31 the irregular central mass provided with a black granule presumably represents this element. In fig. 38 it is a large irregular body, while in fig. 39 it is a large oval deeply staining granule, split nearly into two by a cleft. To some extent these differences are due to the technique employed, but in the main they represent actual differences in the morphology of the parasite itself.

Passing now to mouse 106, a 9-hour stage which yielded highly favorable material, we have figs. 40 and 41 (Plate III). Fig. 41 is very much like fig. 39, except for the staining reaction of the karyosome. Fig. 40 bears a general resemblance to figs. 31, 32, and 38. It is therefore apparent that figs. 40 and 41 represent the earlier of the stages present in mouse 106 and hence the starting point from which a number of these have arisen. For the parasites in a 9-hour mouse may have been in the cells anywhere from a very short time up to perhaps 8 hours. Hence, in passing from mouse 99, 250, or 253 to mouse 106, it is not necessary and would, indeed, be a mistake to assume that we had also passed over 3 or 4 hours of time spent in development. The period elapsing between the inoculation and death of the mouse, at least as far as concerns the periods up to 9 or 10 hours, is of value only as a high limit. A parasite of mouse 253 cannot be more than 6 hours old; one of mouse 106 cannot be more than 9 hours, and this is all that can be stated with absolute certainty. Nevertheless, the parasites of mouse 106 will in general be older than those of mouse 253, even though they will in a number of cases represent the same stages of development. It is therefore permissible to use parasites such as are shown in figs. 31, 32, 38, and 39, as well as figs. 40 and 41, in tracing the later stages as found in mouse 106.

It is easy to pick out conditions readily derivable from these. Thus, fig. 42 (upper cell) is a good deal like fig. 41. Fig. 43 is also very much like fig. 41, except for the strip of basophil chromatin which runs across the nucleus. Fig. 44 also displays a general resemblance to the earlier stages, but has developed a greater quantity of basophil chromatin present in the form of scattered granules. A similar state of affairs is seen in fig. 45, in which the somewhat quadrangular mass of acidophil chromatin situated in the centre may represent the karyosome. In figs. 46 and 47, we have parasites in which the chromatin is all basophil and occurs in a rather finely divided state. In the case of the two parasites shown in fig. 42,

while they are not wholly unlike morphologically, the chromatin of the one is acidophil, of the other basophil, and the fact that they lie side by side seems to preclude ascribing this difference to irregular action of the stain.

It is to be observed that all of the changes noted above point toward the production of finely divided and highly basophil chromatin.

As pointed out above, in the early stages, a karyosome may or may not be present. When it is present, its evolution appears to take place as follows: In figs. 31, 38, 40, 44, and 48 the karyosome is composed of acidophil chromatin, associated with which are one or more basophil granules. A karyosome of the type shown in figs. 40 and 48, consisting of a rounded acidophil mass bearing several sharply basophil granules, was quite common. In fig. 47 there is a ring of basophil granules, and figs. 46 and 49 show somewhat similar phenomena. We seem here to be dealing with the conversion of the karyosome from an acidophil mass into a group of basophil granules.

Resuming the account of the evolution of the entire parasite, fig. 53, from mouse 120, shows two parasites lying side by side. In the upper one the central body appears to represent the karyosome, here partly basophil and partly acidophil. In addition to this, the organism contains some acidophil material of irregular form together with a number of basophil granules, some of which are placed at the periphery. The lower parasite shows a central basophil mass and a number of basophil granules extending out from it. These parasites, from int. 8 of mouse 120, should represent later rather than earlier conditions, and they can be derived from what is shown in figs. 45, 47, and 48. The lower of the two, also, is very much like fig. 49.

It is always to be kept in mind that we are endeavoring to trace the development of a structure showing a typical nuclear net, and displaying both acidophil and basophil chromatin throughout its entire extent to one in which all the chromatin present is intensely basophil and occurs as clusters of minute granules around the periphery of the parasite. Biological processes never proceed with mathematical precision, and hence we cannot look to find these three processes taking place side by side. But it is entirely reasonable to assume that if we compare any two parasites and find one of them more advanced with reference to one or more of these three conditions that it represents the later stage. Thus the lower parasite of fig. 42 is older than the upper, and the same thing may be said of

fig. 53. Figs. 46, 47, and 49 represent later stages than figs. 40, 44, and 45. On the other hand, in figs. 44 and 48, while the chromatin is in part in the form of small basophil granules, the balance of it is acidophil. Hence, it would not be possible to say whether these represent older or younger stages than the lower parasite of fig. 42. Again, as between figs. 49 and 53, upper parasite, the chromatin of the former is all basophil, while that of the latter is showing a greater disposition to assemble at the periphery. The cases last given illustrate the irregularity with which the evolution proceeds.

Fig. 54 (Plate IV) is from mouse 120. It shows a parasite with an irregular central mass from which prolongations run toward the periphery. The staining reaction is partly basophil and partly acidophil. The basophil substance is partly in the form of granules and partly occurs as streaks and bands, but it is not improbable that these latter are composed of closely compacted granules, as is evidently the case, for instance, in the large aggregation of fig. 49. The central mass as shown in fig. 54 could have been derived from a karyosome of the type shown in fig. 44. Finally, in addition to the central mass shown here (fig. 54), there are four more or less well-defined clusters of chromatin granules, in two of which the granules are very minute.

The conditions shown in fig. 54 appear to be followed by those shown in figs. 55 and 56. In these latter there is a central mass sending out prolongations toward the periphery, but the chromatin is more completely basophil and more completely separated into granules. There is also the same tendency, at least in fig. 55, for the granules to be disposed in clusters. In these two parasites (figs. 55 and 56) there is very little achromatic material remaining, and this is in part only the fragments of the linin network. The parasite shown in fig. 57 appears also to belong to this stage of the evolution.

The development is carried further in the organisms shown in figs. 58 and 59. In these the arrangement of the chromatin granules into aggregates is more obvious. A comparison of figs. 54 and 55 with fig. 59 suggests that at least in some cases the *modus operandi* is for the chromatin to assume the form of a very irregular dendritic mass which later breaks up into smaller masses. Thus, in fig. 59 six of these small masses have already become individualized, and one more seems about to become free. In fig. 58, although the granules are very small, only three such masses have become independent.

The parasites shown in figs. 63 and 64 may belong in the above cycle. Although the central mass of fig. 64 is larger than that of fig. 54, its arrangement is not wholly different. Fig. 63, however, cannot very well be placed.

Figs. 60 and 61, from mouse 179, give slightly later stages than figs. 58 and 59. At least the central dendritic mass has disappeared and the chromatin is distributed throughout the entire nucleus, either in clusters or as separate granules. Furthermore, there is a marked disposition for the clusters to assume a peripheral position, especially well marked in fig. 61. The smaller size of the granular clusters in figs. 60 and 61 than in figs. 58 and 59 suggests that in these last the clusters are destined to subdivide before reaching a peripheral position, a suggestion supported by what is seen in figs. 62, 65, 66, and 67.

In figs. 60 and 61 all of the chromatin which could be seen by raising and lowering the focus was drawn, and hence some of the chromatin apparently central was actually peripheral. In fig. 62, only an optical section of the parasite is drawn. Here evolution has reached the stage where all of the chromatin is in the form of minute granules assembled in clusters that lie around the periphery. It is to be noted, however, that they are irregularly placed. The next stage is shown in fig. 66, where the clusters have come to lie in regular order around the periphery. Fig. 65 no doubt represents the same stage, but apparently shows only a part of the organism. In fig. 67 the clusters, which are the future microgametes or their nuclei, have begun to solidify. The further steps in this process are shown in figs. 68, 69, and 70, the last showing that the nuclei finally become rounded solid balls of highly basophil chromatin. Fig. 71 shows a condition intermediate between figs. 69 and 70.

Fig. 52 (Plate III) shows a parasite in which the chromatin is present in the form of solid balls more or less strung together. The form and solidity of the chromatin masses suggest the later stages such as are pictured in figs. 70 and 71, whereas their arrangement as well as the elongated oval form of the parasite recalls earlier conditions. At times, however, the parasite reaches the end of its development while still retaining this oval form (fig. 74, Plate V).

The final stages of the evolution of the microgametocyte are given in figs. 72 to 76 (Plate V). In fig. 72 the solid rounded elements are seen to be elongating, and this elongation is carried further in the case of fig. 73. Figs. 74 to 76 portray the microgametes. They always lie on the periphery, and fig. 76 gives the aspect as viewed in optical

section, whereas in the other two figures more than an optical section is shown. Figs. 75 and 76 are the more typical; in fig. 74 the parasite is unusually small for this stage, but is characteristic in showing very clearly the arrangement of the microgametes around the periphery.

The fully evolved male element or microgametocyte is a rounded or oval body, showing a stringy or amorphous residual mass and a series of microgametes disposed around the periphery. These latter are bodies about 2 to 2.5 microns long, broader at one end than the other and apparently composed wholly of intensely basophil chromatin. This is at least their appearance in sectioned material, it is not impossible that in life, or in material otherwise prepared, they may show more than is here evident. Analogy would lead us to suspect the existence of flagella.

This stage is apparently of short duration. Mouse 152, killed 18 hours after feeding, was heavily parasitized, but the exact stage shown in fig. 75 was comparatively scarce. This, however, is much as might be expected. The presumption is that the microgametes are motile elements, and once they are fully ripe they doubtless quickly abandon the situation in which they evolved, and without them the residuum would scarcely be recognizable.

In number they vary, following the counts made, from 13 to 17. Allowing both for an actual variation and for the practical difficulties in making an accurate determination, the supposition is plausible that the typical number is sixteen. It is a familiar biological phenomenon that in those cases where the number of elements ultimately produced is some power of two, we are dealing with the results of the repeated division of some one original element. In this case, however, the end appears to be attained in a less regular manner.

In the description of the later stages of the evolution of the male element, reference was confined to the conditions as found in mice 106, 120, 152, and 179, respectively, 9, 10½ and 17, 18 and 16½ hours. The first three of these gave particularly favorable material, all of them being heavily parasitized and none showing much destruction of the cells. The conditions seen here, however, were duplicated in other mice. Thus, Nos. 113, 132, and 133, all either 8½- or 9-hour periods, showed many of the same stages as were seen in mouse 106, while the later stages in the evolution of the microgametes were seen in mice 121, 175, 177, 178, 180, and 182, representing periods ranging from 10½ to 18 hours.



*The Female.*—It has already been shown that the female, in the 5- and 6-hour mice, is an oval cell with rather compact cytoplasm and a vesicular nucleus with a large central body, the karyosome. It is illustrated in figs. 33 to 37. The nuclear structure is comparatively simple and is portrayed well enough by the figures. The nuclear membrane is usually clear cut, and there is always present a large karyosome which takes the acid rather than the basic stain. The karyosome frequently has associated with it one or more sharply basophil granules, and may or may not show strands extending out toward the nuclear membrane.

It is difficult, however, to show the cytoplasm as it actually occurs, and in the main this has been done in the figures in a purely conventional manner. Its fundamental structure appears to be alveolar with the alveoles quite small and frequently tending to be variable in size. The picture, however, is greatly confused by the fact that in general both spongioplasm and hyaloplasm stain with much the same degree of intensity and both have a rather high affinity for plasma stains. Figs. 35, 77, 78, and 81 are attempts to show the conditions as they actually occur. In fig. 35 (Plate II) the alveolar structure is evident, although somewhat obscured, while it is seen much more clearly in fig. 81 (Plate V). Parasites in which the alveolar structure was as obvious as in fig. 81 could be found, but they were rare. Figs. 34, 77, and 78 show the cytoplasm to consist of an aggregation of poorly defined rounded bodies lying in a paler matrix. This was a frequent appearance. The black granules seen in some of the figures represent the black granules usually to be seen in material stained with iron hæmatoxylin. Frequently, also, the cytoplasm is vacuolated.

The general appearance here described does not undergo any great change. Thus, figs. 28 (mouse 247) and 79 (mouse 113), respectively 4- and 9-hour stages, are much alike, as are figs. 77 and 78, respectively, from 6- and 9-hour mice.

There is, however, one phenomenon presented which appears to be of interest. One phase of this is shown in figs. 81 and 82. In each of these the nucleus presents somewhat the appearance of a wheel. There is in each case a central acidophil karyosome which sends out strands to the periphery. Around the periphery are a number of basophil granules. This condition was not at all infrequent and appeared to be especially characteristic of the intermediate periods of 9 or 10 hours. It was, however, seen in mouse 77, a 15-hour stage. We also have the condition illustrated in fig. 83, where there is some basophil material outside of the nucleus.

The appearances suggest maturation, a suggestion which is strengthened by what is seen in figs. 84 to 87. In these the nucleus is the typical vesicle with its central karyosome, while the cytoplasm is more or less liberally provided with sharply staining granules. It seems permissible to suppose that we are here dealing with later stages in which the rejected chromatin has passed out into the cytoplasm.

Here it is apparently absorbed, since the fully mature macrogamete shows no indications of it. This phase of the life history of *S. muris* is portrayed by figs. 88 to 91, from mice 120, 145, and 152. The second of these was killed  $11\frac{1}{4}$  hours after inoculation, and hence the macrogamete may reach the end of its development within this period of time.

#### FERTILIZATION.

The earlier stages of the parasite are passed while within a cylinder cell of the intestinal epithelium in its proper place in the epithelial row. The parasite, however, has a deleterious influence on the cell it invades and apparently always destroys it in the end. It would then necessarily follow that the remnant of the cell, with its contained parasite, would, by pressure, be thrust out of its place in the epithelial row. In so far as the mechanics of the process are concerned, there does not seem to be any choice as to whether the dead cell would be pushed out into the lumen or beneath the row into the subepithelial tissue. It looks as though one contingency would be as likely to occur as the other.

Nevertheless, as early as 9 hours, but more particularly later, a considerable number of the parasites are to be found beneath the epithelium. This is more particularly the case with the macrogametes, which is further in accord with the probabilities. For the macrogametocyte is a rather compact, solid-looking element and presumably will retain its integrity even though subjected to mechanical stress. On the contrary, the microgametocyte, the bulk of which is obviously merely decadent residual matter, would presumably readily yield and break up if acted upon by pressure.

Here and there in the epithelium a ripe male cell occurs in which the microgametes appear to be streaming out into the subepithelial tissue. Conditions such as these may, of course, be interpreted in two ways: the microgametes may have reached their places beneath the epithelium either actively or passively. An examination of fixed material clearly sheds no light on such a question, but analogy

favors the view that such a movement is the result of an actual motility of the microgametes themselves. It may also be that in life the macrogametes are amœboid and gain their subepithelial situation through their own motility, but here the probabilities are the other way. Analogy is not in favor of a belief that the macrogamete is motile, nor do the macrogametes ever show amœboid outlines in the fixed material.

As to the actual situation of the parasites which occur beneath the epithelium, the fixed material does not give wholly conclusive evidence. They appear, however, to occur rather between the row of cells and the stroma than in the stroma itself.

We thus have obvious male elements and obvious female elements occurring beneath the row of epithelium cells. The production of male and female cells necessarily involves their union, and the environment in which they both occur offers no obstacle to such a procedure. It is evident that the proper demonstration of such a process should be made upon living material, since, in a situation such as has been indicated, the identification of a minute fragment of highly basophil matter as a microgamete is largely a matter of guess-work. It is easy enough to identify the thread-like bodies of figs. 75 or 76 as microgametes, since here their relationships with their surroundings can be established. But it is clear that an isolated microgamete cannot be identified when it occurs in a region presenting such a confused picture as does the subepithelial tissue of the mammalian intestine.

Nevertheless, when the macrogametes as they occurred in the subepithelial tissues of mouse 152 were studied, it was possible to separate them into two categories. A certain number were as figs. 88 to 91. Others were as fig. 93. These differ only that in the latter there was present in the cytoplasm a sharply basophil body. Also, conditions such as are illustrated in fig. 92 were found, where two elongated sharply basophil bodies are seen either lying upon or partly within the cytoplasm of a macrogamete. In consideration of the fact that it is axiomatic that the development of males and females involves fertilization, the indirect evidence here offered as to the actuality of the process seems satisfactory. Fig. 92 shows two supposed microgametes associated with the macrogamete, but it is safe to conclude that only one would have been successful in effecting union.

The three cells shown in fig. 93 have somewhat irregular outlines, this being the condition as found. Assuming that this is not an

artifact, it indicates that they are in no sense encysted, but are rather naked masses of cytoplasm. This irregularity of outline, however, is not necessarily associated with the supposed fertilization, since many of the macrogametes which showed the conspicuous chromatin body had maintained their smooth and regularly curved contours.

#### DISCUSSION.

If the evolution of the macro- and microgametocytes of *S. muris*, as outlined above, be compared with that of *Coccidium schubergi*, as worked out by Schaudinn (1900) it will be seen that there is a very close resemblance. Thus, in both, the chromatin of the microgametocyte becomes divided into very small particles which collect in masses at the periphery and there condense to form the microgametes. This mode of division is designated by Minchin (1912) as chromidial fragmentation, the minute granules themselves being the familiar chromidia. Similarly, in both the sarcosporidian and the coccidian, the nucleus of the macrogametocyte discharges chromatic granules into the cytoplasm where they are apparently absorbed.

On the other hand, there are many marked differences. In the first place, in *S. muris* the male cell loses most if not all of its cytoplasm, the formation of the microgametes taking place in what is morphologically the nucleus. Hence, there is not only no increase in size of the parasite after it gains an entrance into a host cell, but actually a loss of substance. It is somewhat the same with the female cell which, while it gains in bulk, does so to a rather limited extent. This is in marked contrast to the phenomena displayed by *Coccidium schubergi*, in which the macro- and microgametocytes are many times bulkier than the merozoites from which they took origin.

The sarcosporidian runs through its sexual development within from 9 to 18 hours, while judging from the data given by Schaudinn (p. 217), the coccidian requires about two days.

The resemblances and differences between these two parasitic Protozoa are here merely pointed out. The resemblances are certainly very striking, but it seems premature to assign any significance to them. It is conceivable that they indicate a genetic relationship between the Sarcosporidia and Coccidia, but it is just as likely that we are dealing with phenomena broader than those suitable for connecting groups of the value of the Coccidia and Sarcosporidia. The problem is one that requires more evidence before any far-reaching conclusions are warranted.

Some of the features presented by the evolution of *S. muris*, however, when considered wholly by themselves, are worthy of attention. One of the most striking of these is the loss of cytoplasm displayed by the microgametocyte. So far as I am aware, no other protozoan displays a mode of development at all like this. Yet it is perhaps not so different from the usual procedure as it may at first seem. In all cases of the evolution of microgametes in Sporozoa the cytoplasm is largely or wholly inert. Thus, in the case used for comparison, that of *Coccidium schubergi*, the nuclear membrane dissolves and the chromidia collect in the cytoplasm where they eventually produce the microgametes. But there is nothing to show that the cytoplasm takes any active part in this development. It may function merely as a mechanical support for the microgametes. Furthermore, at the end of development the microgametes abandon the cytoplasmic mass, which is merely left behind.

This, indeed, is generally true. Throughout the entire group of the Sporozoa the fully developed microgametocyte consists of a number of microgametes associated with a residuum that represents unused cytoplasm. This residuum is always abandoned, and, so far as it is possible to see, it is always about equal in bulk to that of the original cytoplasmic mass. It may therefore be suggested that in the case of *S. muris*, the discarding of the cytoplasm merely takes place before the microgametes are developed instead of afterward.

The next peculiarity is the fact that there is either only a slight gain of substance, as in the females, or an actual loss, as in the males. This is probably correlated with the speed with which the development is effected. In general, parasitic Protozoa that live in cells enter these cells as very minute bodies which increase in size for a longer or shorter period, growing at the expense of the cell, and it is only after they have reached a certain size that they divide. That is, the host cells are the dwelling places of these parasites.

But in the case of *S. muris* in the intestinal epithelium of the mouse, the host cell appears to be used merely as a temporary lodging place. The parasites, although they appear usually to destroy the cells they invade, do not seem to feed upon them. No sooner do they come to rest than they proceed forthwith to evolve into the mature sexual stages, which are produced within 18 hours or less. It is apparent that the so-called spore possesses enough energy at the outset to carry on this development, and it seems much more plausible to look upon the granules which the spores contain as reserve food than as the so-called sarcocystin.



My studies do not extend beyond the formation of the zygote. In mice killed one to two days after feeding, oval cells resembling the zygotes, but larger, are quite frequent. These are most abundant in the villi beneath the epithelial row, but they also occur in the cells and occasionally free in the lumen. Their ultimate fate has not been followed, but Erdmann (1914) describes what seems to be schizogony in the cells and subepithelial tissues of mice killed several days after feeding, and it is not at all unlikely that the oval bodies mentioned above are schizonts.

One fact stands out clearly: the banana-shaped body of the Sarcosporidia is not a spore. There was never any reason to suppose that it was, even though this misleading designation has been used exclusively in the literature during recent years. Labbé (1899) designated it as a sporozoite, which, in view of its form, is far more plausible, and may indeed be a correct designation, so far as it is allowable to apply terms based on the conditions in the Telosporidia to stages of Sarcosporidia. For if the oval bodies occurring in one- and two-day mice give rise to the schizonts described by Erdmann, and if the products of this schizogony give origin to the familiar muscle cysts, then apparently the banana-shaped body is in some respects at least the analogue of the coccidian sporozoite.

As against this interpretation is the fact that in Coccidia, where there is both schizogony and sporogony, the sporonts are derived from merozoites. This would suggest that the banana-shaped sarcosporidian element is a merozoite. Obviously, however, the evidence at hand is not sufficient to warrant a conclusion. Accordingly, it has been considered best to follow recent custom and to retain the term spore, despite the fact that it is incorrect, for it is believed that this procedure is less confusing than to adopt a different designation which future discovery might show to be equally incorrect.

#### SUMMARY.

(1) The spores of *Sarcocystis muris*, ingested by a mouse, may reach the posterior part of the small intestine within one hour.

(2) Invasion of the epithelium cells of the intestine may also take place within the same time.

(3) Upon reaching the lumen of the intestine, the spore rapidly undergoes changes. The nucleus becomes larger and more conspicuous, and a distinct nuclear net becomes evident. The granules characteristic of the spore as it occurs in the cyst either disappear or become much less evident. Further changes, however, do not take place unless the spore gains an intracellular situation.

(4) The spores are sexually differentiated, but it does not appear to be possible, at the outset, to distinguish between the males and females.

(5) Within the mouse cells the changes undergone by the males, or microgametocytes, begin to be evident at the end of  $1\frac{1}{2}$  to 2 hours.

(6) These changes are, first, a further increase in the size of the nucleus accompanied by a further development of the nuclear net, and, second, degeneration and ultimate disappearance of the cytoplasm. The cell contours become rough and irregular, vacuolization occurs, the cytoplasm becomes reduced to two masses of debris lying at the ends of the nucleus. These finally disappear, the entire process usually being completed at the end of 6 hours. The microgametocyte is thus reduced to its original nucleus, which, however, is of approximately the same size as the original spore.

(7) Conspicuous internal changes next take place, which modify both the morphology and chemistry of the parasite. They may be considered under three headings, but they all take place more or less simultaneously.

(a) The chromatin appears to suffer a loss in actual bulk, but alters in staining reaction from acidophil to basophil.

(b) From occurring in large irregular masses or distributed along the threads of the linin net in strips or bands, the chromatin is reduced to granules which become progressively smaller and smaller and at the same time display a greater and greater affinity for chromatin stains.

(c) These granules finally assemble in clusters around the periphery of the organism.

(8) The next step is the solidification of these granular clusters into rounded, solid balls. These balls next elongate and become minute, thread-like bodies, which are the microgametes. This stage may be found in mice killed from 9 to 18 hours after inoculation. It is very rare in the shorter of these two periods, but has apparently passed its acme at the end of 18 hours.

(9) The females go through with their development side by side with the males, but there are no such conspicuous changes and the early female stages are much like the spore which has just entered the cell.

(10) In the course of a few hours, however, the females can be picked out, appearing as broadly oval cells, relatively shorter and broader than the original spores. The cytoplasm is all retained and assumes a rather dense alveolar texture. The nucleus shows no

evident increase in size. The nuclear net does not develop as it does in the male parasite, but the chromatin concentrates into a single large karyosome which maintains an acidophil rather than a basophil staining reaction.

(11) In the 6- to 15-hour periods, phenomena are seen which seem best interpreted by regarding them as maturation. Irregular chromatin granules appear in close association with the nuclear membrane. Later these granules pass out into the cytoplasm, and finally disappear.

(12) The mature female, or macrogamete, may be found in mice killed from 11 to 18 hours after inoculation.

(13) Finally, in the 18-hour stages, macrogametes may be found which in some cases show minute, thread-like bodies upon their surfaces, and in others contain within their substances small solid chromatic bodies, one in each case. These appearances are regarded as warranting the interpretation that fertilization takes place.

#### EXPLANATION OF PLATES I, II, III, IV, V.

The original figures were made by the author and later copied in ink by Mr. Haines, artist of the Bureau of Animal Industry. The greater number are from camera outlines, made on the table with a 2 mm. apochromatic objective and No. 18 eyepiece. This method yields a magnification of about 3,530 diameters. The remaining drawings are free-hand sketches of approximately the same enlargement. In reproduction, the drawings have been reduced in the ratio of 3 to 2, and hence are about 2,350 times larger than the objects themselves.

In order to show the relationships between the parasites and the cells, the latter have in some cases been drawn in outline. It was not, however, considered necessary to do this throughout.

- PLATE I.—Fig. 1.—Camera outline. Giemsa stain. Spores taken directly from a cyst. The cytoplasm stains a dense blue; the nucleus is a reddish vesicle with little or no internal structure. The spores are broader at one end than the other.
- Fig. 2.—Camera outline. Thionin and acid fuchsin. Mouse 248, 2 hours, int. 30. Spore free in lumen. Cell outlines clear cut; a periplast present; cytoplasm shows no signs of degeneracy. The nucleus shows a nuclear net and is somewhat enlarged, causing the cell edges to bulge.
- Fig. 3.—Camera outline. Delafield and acid fuchsin. Mouse 251, 1½ hours, int. 9. Cytoplasm slightly degenerate, but staining deeply. Nucleus enlarged, about to cause bulging of the sides of the cell and showing a central mass joined to the nuclear membrane with strands.
- Fig. 4.—Camera outline. Delafield and acid fuchsin. Mouse 251, 1½ hours, int. 9. Cytoplasm dense and staining deeply. Nucleus enlarged, with the central mass separated into granules.
- Fig. 5.—Camera outline. Delafield. Mouse 248, 2 hours, int. 27. Cytoplasm dense with occasional clear spaces. Nucleus not enlarged. Chromatin in the form of small granules distributed throughout the net.
- Fig. 6.—Camera outline. Thionin and acid fuchsin. Mouse 248, 2 hours, int. 30. Cytoplasm very solid, staining deeply with the thionin and showing no signs of degeneracy. Nucleus is a vacuole which stains more or less homogeneously, apparently due to the fact that the nuclear sap has stained as well as the nuclear net and thus the latter is obscured. This is a frequent appearance, especially in parasites free in the lumen.

- Fig. 7.—Camera outline. Delafield. Mouse 248, 2 hours, int. 15. Typical early male form. Nucleus greatly enlarged; cytoplasm reduced to two separate masses, one at each end of the parasite. Nuclear net distinct.
- Fig. 8.—Camera outline. Thionin and acid fuchsin. Mouse 248, 2 hours, int. 30. Early male stage. Cytoplasm beginning to show irregular outlines and to become vacuolated. Nucleus not greatly enlarged, but otherwise typical.
- Fig. 9.—Camera outline. Thionin and acid fuchsin. Mouse 248, 2 hours, int. 30. Early male stage. Shows very clearly the degeneration of the cytoplasm, evidenced by the rough outlines and vacuolization. Nucleus enlarged, with a distinct nuclear net.
- Fig. 10.—Camera outline. Thionin and acid fuchsin. Mouse 248, 2 hours, int. 30. Early male stage. Cytoplasm degenerate. Nucleus elongated transversely, a frequent appearance in the early stages. Nuclear net showing a single large central mass, in which is a vacuity.
- Fig. 11.—Camera outline. Thionin and acid fuchsin. Mouse 248, 2 hours, int. 30. Early stage of male. Cytoplasm reduced in amount and degenerate in appearance. Nucleus greatly enlarged with a central aggregation differentiated into an acidophil mass beset with basophil granules.
- Fig. 12.—Free-hand drawing. Thionin and eosin. Mouse 248, 2 hours, int. 30. Early male. Shows a method of degeneration of the cytoplasm frequently observed. The cytoplasm consists of a number of basophil masses lying in a faintly staining matrix. The nucleus was typical.
- Fig. 13.—Free-hand drawing. Thionin and eosin. Mouse 248, 2 hours, int. 30. Early male stage. Shows mode of degeneration of cytoplasm, which at one end of the parasite is broken up into a mass of basophil lumps, apparently lying free in the host tissue. The nucleus was typical.
- Fig. 14.—Camera outline. Thionin and eosin. Mouse 248, 2 hours, int. 30. Early male stage, probably slightly earlier than the form shown in fig. 13. The cytoplasm has separated into a number of denser masses, taking the thionin, which lie in an almost achromatic ground substance. The nucleus is typical.
- Fig. 15.—Camera outline. Wright's stain. Mouse 125, 2 to 2½ hours. Early male stage, showing nuclear enlargement.
- Fig. 16.—Camera outline. Wright's stain and eosin. Mouse 125, 2 to 2½ hours. Early male stage.
- PLATE II.—Fig. 17.—Camera outline. Wright's stain and eosin. Mouse 125, 2 to 2½ hours. Early male stage. Cytoplasm greatly reduced and degenerate. Nucleus much enlarged with a very distinct nuclear net.
- Fig. 18.—Camera outline. Thionin and acid fuchsin. Mouse 249, 3 hours, int. 22. Two early males, both lying in the same vacuole. In both the nuclei are enlarged, and although the cytoplasm is reduced, it still retains its smooth outlines and is not vacuolated. Nuclei typical.
- Fig. 19.—Camera outline. Thionin and acid fuchsin. Mouse 249, 3 hours, int. 22. Male. Cytoplasm reduced to a small cap at either end of the parasite. Nucleus greatly enlarged and showing the usual structure.
- Fig. 20.—Camera outline. Iron hæmatoxylin and acid fuchsin. Mouse 249, 3 hours, int. 30. Early male stage. Cytoplasm somewhat reduced in quantity and showing signs of degeneration. Nucleus shows a net of the usual character and is provided with one large conspicuous granule. This kind of granule appears to require iron hæmatoxylin for its demonstration. The parasite lies in a partly emptied mucous cell.
- Fig. 21.—Camera outline. Iron hæmatoxylin and acid fuchsin. Mouse 249, 3 hours, int. 30. Possibly an early female stage. Cytoplasm dense; nucleus clear cut with a central mass and three black granules on periphery.
- Fig. 22.—Camera outline. Thionin and acid fuchsin. Mouse 249, 3 hours, int. 22. Probably an early female stage. Cytoplasm sharply delimited and dense. Nucleus enlarged, but not sufficiently so as to cause bulging of the cell boundaries. Within the nucleus is a round red body from which blue rays extend to the nuclear membrane.



- Fig. 23.—Camera outline. Wright's stain. Mouse 126, 3 to 3½ hours. Early male form. The cytoplasm has nearly disappeared. The nucleus is typical.
- Fig. 24.—Camera outline. Mouse 126, 3 to 3½ hours. Early male stage. Cytoplasm greatly reduced. Nucleus very large with a well-developed nuclear net.
- Fig. 25.—Camera outline. Iron hæmatoxylin. Mouse 261, 4 hours,<sup>1</sup> int. —3. Early stage of doubtful sex. Cytoplasm sharply delimited and dense. Nuclear net obscured. A large black granule present.
- Fig. 26.—Camera outline. Iron hæmatoxylin. Mouse 261, 4 hours, int. —3. Parasite lies in what seems to be a mucous cell. Cytoplasm dense and nearly homogeneous. Nucleus clear cut, showing a sharply marked karyosome and two conspicuous black granules. This parasite might be either a male or a female.
- Fig. 27.—Camera outline. Thionin. Mouse 261, 4 hours, int. —3. Early male stage. Consists of an enlarged nucleus surrounded by a narrow strip of cytoplasm, with a quantity of degenerate material lying on one side. The parasite is probably cut obliquely. The nuclear net is well developed.
- Fig. 28.—Free-hand drawing. Thionin and acid fuchsin. Mouse 247, 4 hours, int. 14. Early female stage. Cell outlines smooth and cytoplasm apparently not degenerate. Nucleus rather small with a clear-cut membrane and a central karyosome.
- Fig. 29.—Camera outline. Iron hæmatoxylin and acid fuchsin. Mouse 247, 4 hours, int. 14. Early female stage. Cell boundaries sharp. The cytoplasm is neither degenerate nor has it suffered any loss in quantity. The nucleus does not cause any protrusion of the sides of the cell. A large, distinct karyosome is present. Figure diagrammatic.
- Fig. 30.—Camera outline. Delafield and acid fuchsin. Mouse 247, 4 hours, int. 19. Form difficult to classify. The cytoplasm shows a distinct external boundary and, while vacuolated, is apparently not degenerate. Nucleus is a vesicle with a very large central mass.
- Fig. 31.—Camera outline. Iron hæmatoxylin and acid fuchsin. Mouse 250, 5 hours, int. 22. Male. Cytoplasm has disappeared, except for a crescentic mass at one end. The nucleus is greatly enlarged and shows a well-developed net. The net itself is acidophil, the granules associated with it are basophil.
- Fig. 32.—Camera outline. Iron hæmatoxylin and acid fuchsin. Mouse 250, 5 hours, int. 22. Male. Cytoplasm has apparently wholly disappeared. The nucleus is very large and shows an acidophil net beset with a number of sharply basophil granules.
- Fig. 33.—Camera outline. Iron hæmatoxylin and acid fuchsin. Mouse 250, 5 hours, int. 22. Female. Cytoplasm dense and, while vacuolated, shows no signs of degeneration. Nucleus a vesicle with a large karyosome and two intensely black granules. Strands joining the karyosome with the nuclear membrane could not be made out.
- Fig. 34.—Camera outline. Iron hæmatoxylin and acid fuchsin. Mouse 250, 4 hours, int. 22. Female. Cytoplasm shows no signs of degeneracy. It consists of a lighter ground substance in which are a number of poorly defined darker bodies. Nucleus a vesicle in which is a large karyosome. Little strands extend out from the karyosome, but they could not be traced the whole distance to the nuclear membrane. Two black granules present.
- Fig. 35.—Camera outline. Delafield and acid fuchsin. Mouse 253, 6 hours, int. 19. Female. In this figure an attempt is made to indicate the alveolar character of the cytoplasm of the females. Nucleus a vesicle containing a large karyosome.
- Fig. 36.—Camera outline. Delafield and acid fuchsin. Mouse 253, 6 hours, int. 19. Female. Cytoplasm rather dense, but liberally vacuolated. Nucleus a vesicle with a large karyosome.
- PLATE III.—Fig. 37.—Camera outline. Delafield and acid fuchsin. Mouse 253, 6 hours, int. 19. The figure shows two females which have invaded the same cell and developed side by side.

<sup>1</sup> See the annotation with regard to mouse 261, on p. 19.



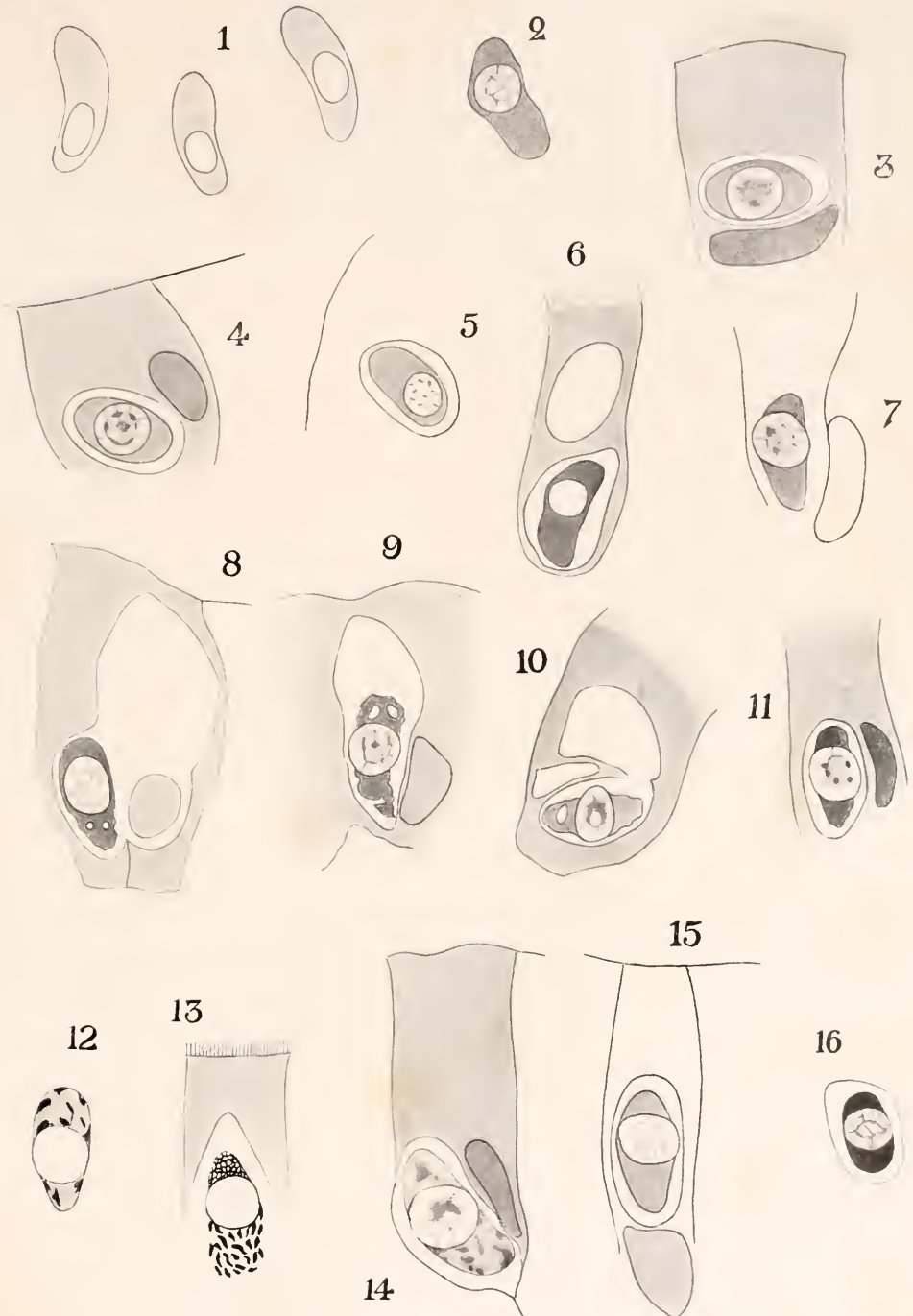
- Fig. 38.—Camera outline. Thionin and acid fuchsin. Mouse 253, 6 hours, int. 16. Male. Parasite reduced to its nucleus which shows the nuclear net and a large central mass of chromatin.
- Fig. 39.—Camera outline. Iron hæmatoxylin and acid fuchsin. Mouse 99, 3 and 6 hours. Male. The parasite, reduced to the nucleus, shows a well-developed nuclear net and a basophil karyosome nearly cut into two by a cleft.
- Fig. 40.—Camera outline. Iron hæmatoxylin and acid fuchsin. Mouse 106, 9 hours. Male. Parasite reduced to its nucleus, which shows the typical net and a large central aggregation in which are five basophil granules.
- Fig. 41.—Camera outline. Delafield and eosin. Mouse 106, 9 hours. Typical male parasite.
- Fig. 42.—Camera outline. Delafield and acid fuchsin. Mouse 106, 9 hours. The figure shows two male parasites lying in adjacent cells of the mouse, and it is instructive in that a marked contrast in staining reaction is to be seen, the upper cell being acidophil, the lower basophil.
- Fig. 43.—Camera outline. Iron hæmatoxylin and acid fuchsin. Mouse 99, 3 and 6 hours. Male, doubtless belonging to the 6-hour period. The nuclear net is in the main acidophil, but a portion of it has taken on a sharply basophil staining reaction.
- Fig. 44.—Camera outline. Iron hæmatoxylin and acid fuchsin. Mouse 106, 9 hours. Male. Shows a typical nuclear net, a large acidophil karyosome and a number of basophil granules.
- Fig. 45.—Camera outline. Iron hæmatoxylin and acid fuchsin. Mouse 106, 9 hours. Male. The nuclear material is partly acidophil, partly basophil.
- Fig. 46.—Camera outline. Iron hæmatoxylin and acid fuchsin. Mouse 106, 9 hours. Male. The chromatin is basophil and finely divided.
- Fig. 47.—Camera outline. Iron hæmatoxylin and acid fuchsin. Mouse 106, 9 hours. Male. The chromatin is basophil, and occurs as minute granules, except for the cluster of larger granules which is presumably derived from the karyosome.
- Fig. 48.—Camera outline. Iron hæmatoxylin and acid fuchsin. Mouse 106, 9 hours. Male. The chromatin is partly acidophil, partly basophil.
- Fig. 49.—Camera outline. Iron hæmatoxylin and acid fuchsin. Mouse 106, 9 hours. The chromatin is basophil and in a state of fine subdivision, except for the central mass which is probably derived from the karyosome.
- Fig. 50.—Camera outline. Thionin and acid fuchsin. Mouse 106, 9 hours. Male. The parasite shows a delicate net provided here and there with basophil granules.
- Fig. 51.—Camera outline. Iron hæmatoxylin and acid fuchsin. Mouse 106, 9 hours. Male. The parasite shows a delicate net provided with minute chromatin granules.
- Fig. 52.—Camera outline. Iron hæmatoxylin and acid fuchsin. Mouse 120, 10½ and 17 hours. Male. The chromatin is extremely basophil and the bulk of it is concentrated into round balls. It is impossible to say to which of the two infective feeds this parasite belongs.
- Fig. 53.—Camera outline. Iron hæmatoxylin and acid fuchsin. Mouse 120, 10½ and 17 hours. Shows two male parasites lying side by side. Instructive on account of the marked difference in staining reaction.
- PLATE IV.—Fig. 54.—Camera outline. Iron hæmatoxylin and acid fuchsin. Mouse 120, 10½ and 17 hours. Male. The central aggregation consists of sharply basophil substance between which is acidophil material. In the former rounded granules can be distinguished. This central mass is throwing out extensions into the balance of the nucleus where there are aggregates composed partly of sharply black granules and partly of acidophil material.
- Fig. 55.—Camera outline. Iron hæmatoxylin and acid fuchsin. Mouse 120, 10½ and 17 hours. Male. The chromatin is black in the iron hæmatoxylin and occurs as minute granules. The general mass is showing a tendency both to form small clusters and to assemble upon the periphery.

- Fig. 56.—Camera outline. Iron hæmatoxylin and acid fuchsin. Mouse 120, 10½ and 17 hours. Male. The chromatin occurs as small granules which appear to be migrating toward the periphery.
- Fig. 57.—Camera outline. Wright's stain. Mouse 146, 11½ hours. Male. There is a large, irregular mass consisting of acidophil material which is liberally provided with punctiform basophil granules, and, in addition, a number of sharply staining elongated granules. It is difficult to determine just where in the development of the male parasite a form like this belongs.
- Fig. 58.—Camera outline. Delafield and acid fuchsin. Mouse 106, 9 hours. Male. The chromatin is in the form of minute basophil granules. There is a large irregular mass of these, and three rounded clusters near the periphery.
- Fig. 59.—Camera outline. Iron hæmatoxylin and acid fuchsin. Mouse 106, 9 hours. Male. The chromatin is aggregated into clusters of fine granules, all of which are sharply basophil. Some of these clusters are wholly independent of one another; others are still united by strips of acidophil substance.
- Fig. 60.—Camera outline. Iron hæmatoxylin and acid fuchsin. Mouse 179, 16½ hours, int. —1. Male. The chromatin occurs as minute basophil granules, either scattered or aggregated into clusters. A marked tendency toward the assumption of a peripheral situation is to be noted. The remnant of the linin network is omitted in the drawing.
- Fig. 61.—Camera outline. Iron hæmatoxylin and acid fuchsin. Mouse 179, 16½ hours, int. —1. The chromatin is in the form of minute basophil granules which occur in clusters, most of which are peripheral. The remnant of the linin network is omitted from the drawing.
- Fig. 62.—Camera outline. Iron hæmatoxylin and acid fuchsin. Mouse 179, 16½ hours, int. —1. Male. This figure portrays much the same conditions as are shown in fig. 61, but only an optical section of the parasite is shown. The granular clusters are thus seen to be exclusively peripheral.
- Fig. 63.—Camera outline. Delafield and acid fuchsin. Mouse 120, 10½ and 17 hours. Form supposed to be a male.
- Fig. 64.—Free-hand sketch. Iron hæmatoxylin and acid fuchsin. Mouse 120, 10½ and 17 hours. Supposed male.
- Fig. 65.—Camera outline. Iron hæmatoxylin and acid fuchsin. Mouse 106, 9 hours. Male. The chromatin occurs as clusters of minute granules.
- Fig. 66.—Camera outline. Wright's stain and eosin. Mouse 152, 18 hours. Male. Optical section. The chromatin is in the form of minute, intensely basophil granules, aggregated in clusters that are arranged in a regular manner around the periphery.
- Fig. 67.—Camera outline. Wright's stain and eosin. Mouse 152, 18 hours, int. —2. Male. Optical section. The granular clusters, the forerunners of the microgametes, are seen to be arranged in a regular manner around the periphery. They are slightly more compact than in fig. 66.
- Fig. 68.—Camera outline. Wright's stain and eosin. Mouse 152, 18 hours, int. —2. Optical section. The clusters are becoming more and more solid.
- Fig. 69.—Camera outline. Iron hæmatoxylin and acid fuchsin. Mouse 106, 9 hours. The microgamete nuclei have still further solidified. It is worthy of note that fig. 69, from a 9-hour mouse, represents later conditions than fig. 68, an 18-hour stage.
- Fig. 70.—Camera outline. Iron hæmatoxylin and acid fuchsin. Mouse 106, 9 hours. Optical section. The microgamete nuclei have become round solid balls.
- Fig. 71.—Camera outline. Iron hæmatoxylin and acid fuchsin. Mouse 106, 9 hours. Male. Condition intermediate between those shown in figs. 69 and 70.
- PLATE V.—Fig. 72.—Camera outline. Wright's stain and eosin. Mouse 152, 18 hours, int. —2. Male. The solid nuclei are elongating to form the microgametes.
- Fig. 73.—Camera outline. Wright's stain and eosin. Mouse 152, 18 hours, int. —2. The elongation continues.

- Fig. 74.—Camera outline. Iron hæmatoxylin and eosin. Mouse 106, 9 hours. Male. Stage showing microgametes. The parasite is unusually small. This stage is very rare in periods as short as 9 hours.
- Fig. 75.—Camera outline. Wright's stain. Mouse 152, 18 hours. Male. Stage showing microgametes.
- Fig. 76.—Camera outline. Iron hæmatoxylin. Mouse 152, 18 hours, int. —1. Optical section of the same stage of development as shown in fig. 75.
- Fig. 77.—Free-hand sketch. Thionin and acid fuchsin. Mouse 247, 4 hours, int. 14. Female, typical early stage.
- Fig. 78.—Camera outline. Iron hæmatoxylin and acid fuchsin. Mouse 106, 9 hours. Female. Cytoplasm mottled. Karyosome shows several black granules. This is possibly a very early stage of maturation.
- Fig. 79.—Camera outline. Iron hæmatoxylin. Mouse 113, 9 hours. Typical female.
- Fig. 80.—Free-hand sketch. Iron hæmatoxylin. Mouse 113, 9 hours. Female.
- Fig. 81.—Camera outline. Iron hæmatoxylin and acid fuchsin. Mouse 106, 9 hours. Female. Cytoplasm shows the alveolar structure which can frequently be made out in the females. Nucleus shows a ring of deeply staining granules lying around the membrane. These are taken to represent that part of the chromatin which is rejected during maturation.
- Fig. 82.—Camera outline. Delafield and acid fuchsin. Mouse 106, 9 hours. Female, same phase as shown in fig. 83. The granules lying in the mouse cell are not believed to have anything to do with the parasite.
- Fig. 83.—Camera outline. Iron hæmatoxylin and acid fuchsin. Mouse 106, 9 hours. Female. Later stage of maturation.
- Fig. 84.—Camera outline. Iron hæmatoxylin and acid fuchsin. Mouse 145, 11¼ hours, int. —1. Female. Late stage of maturation.
- Fig. 85.—Camera outline. Wright's stain. Mouse 146, 11½ hours, int. —1. Female. Late stage of maturation.
- Fig. 86.—Camera outline. Iron hæmatoxylin and acid fuchsin. Mouse 120, 10½ and 17 hours. Female, late stage of maturation.
- Fig. 87.—Camera outline. Wright's stain. Mouse 146, 11½ hours, int. —1. Female, late stage of maturation.
- Fig. 88.—Camera outline. Wright's stain and eosin. Mouse 152, 18 hours, int. —2. Mature female or macrogamete.
- Fig. 89.—Camera outline. Iron hæmatoxylin and acid fuchsin. Mouse 120, 10½ and 17 hours. Macrogamete.
- Fig. 90.—Camera outline. Iron hæmatoxylin and acid fuchsin. Mouse 145, 11¼ hours, int. —1. Macrogamete.
- Fig. 91.—Camera outline. Wright's stain and eosin. Mouse 152, 18 hours, int. —2. Macrogamete.
- Fig. 92.—Camera outline. Wright's stain and eosin. Mouse 152, 18 hours, int. —2. Two microgametes are seeking to fertilize a macrogamete.
- Fig. 93.—Camera outline. Wright's stain and eosin. Mouse 152, 18 hours, int. —2. Three macrogametes are shown, in each of which is a conspicuous chromatic element, taken to be the microgamete.

## BIBLIOGRAPHY.

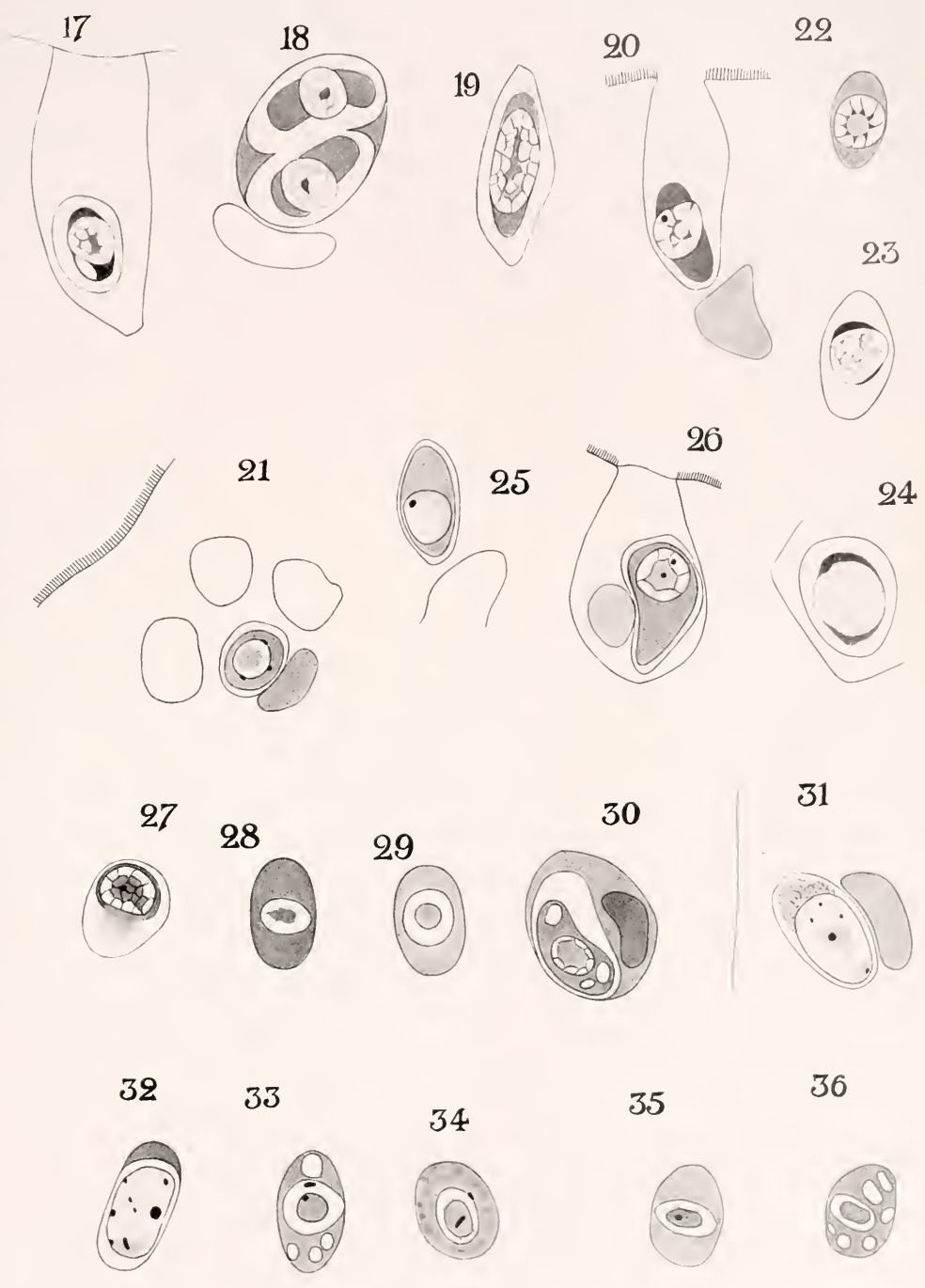
- CRAWLEY, HOWARD. 1913. Initial stages of *Sarcocystis* infection. [Note presented before Helminthol. Soc. Wash., D. C., Feb. 6.] <Science, N. Y., n. s. (952), v. 37, Mar. 28, p. 498.
- 1914. Two new *Sarcosporidia*. <Proc. Acad. Nat. Sc. Phila., v. 66 (1), Jan.-Mar., pp. 214-218, 1 fig.
- 1914. The evolution of *Sarcocystis muris* in the intestinal cells of the mouse. (Preliminary note.) <Proc. Acad. Nat. Sc. Phila., v. 66 (2), Apr.-Aug., pp. 432-436, pl. 15, figs. 1-12.
- ERDMANN, RH. 1910. Die Entwicklung der *Sarcocystis muris* in der Muskulatur. <Sitzungsber. d. Gesellsch. naturf. Fr. zu Berl. (9), Nov., pp. 377-387, figs. A-E, pls. 18-19, figs. 1-14.



CRAWLEY: SEXUAL EVOLUTION OF SARCOCYSTIS.

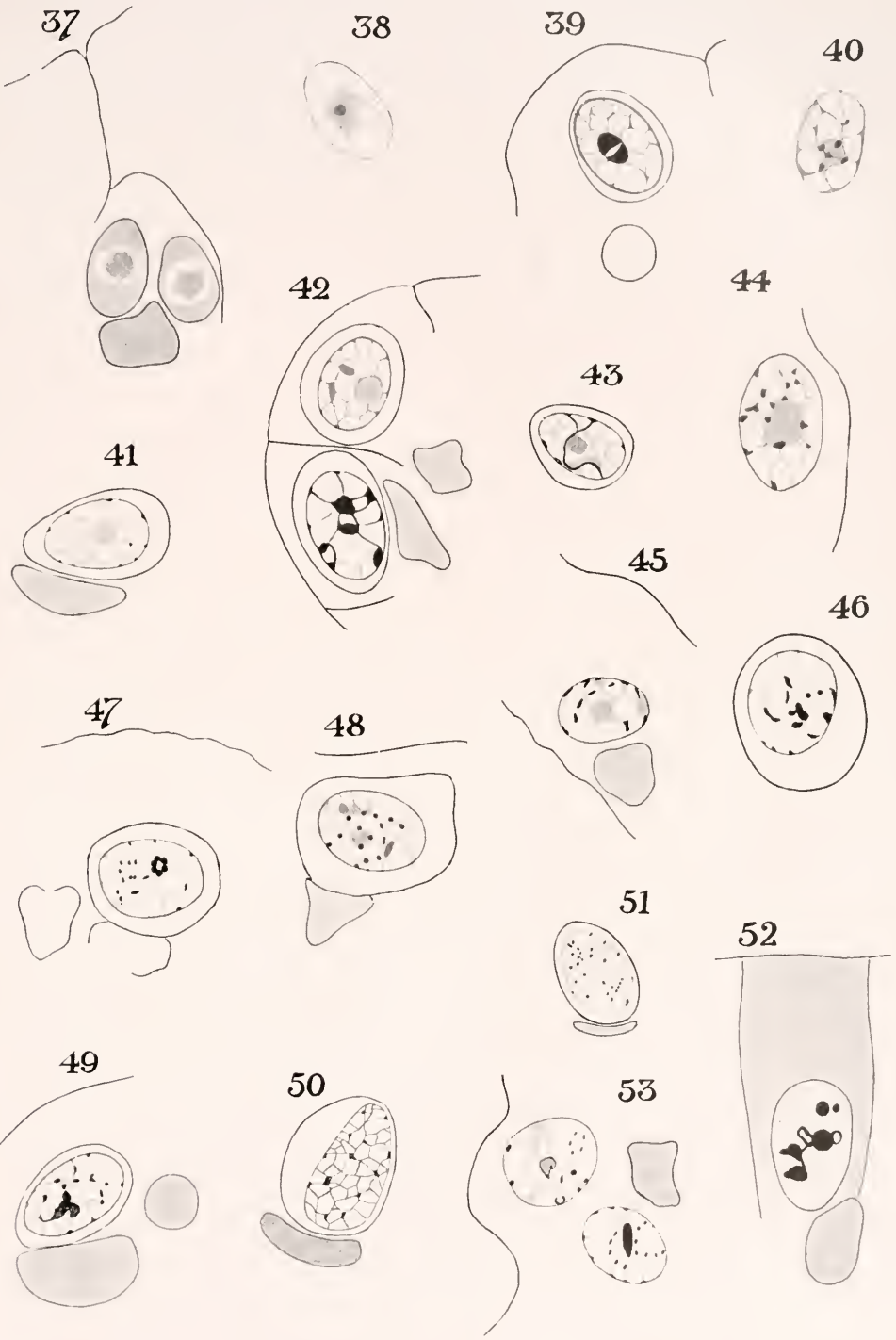






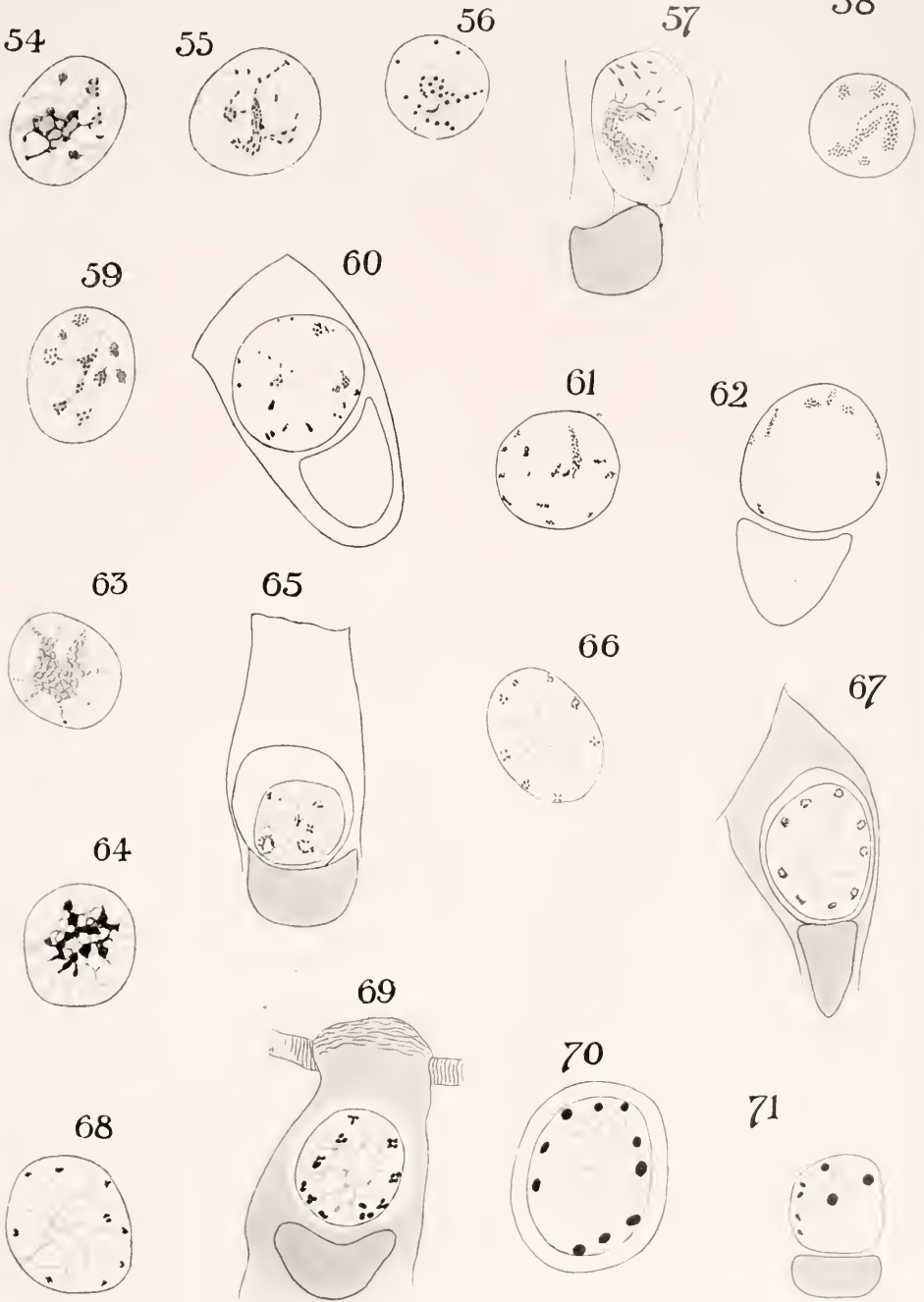
CRAWLEY: SEXUAL EVOLUTION OF SARCOCYSTIS.





CRAWLEY: SEXUAL EVOLUTION OF SARCOCYSTIS.

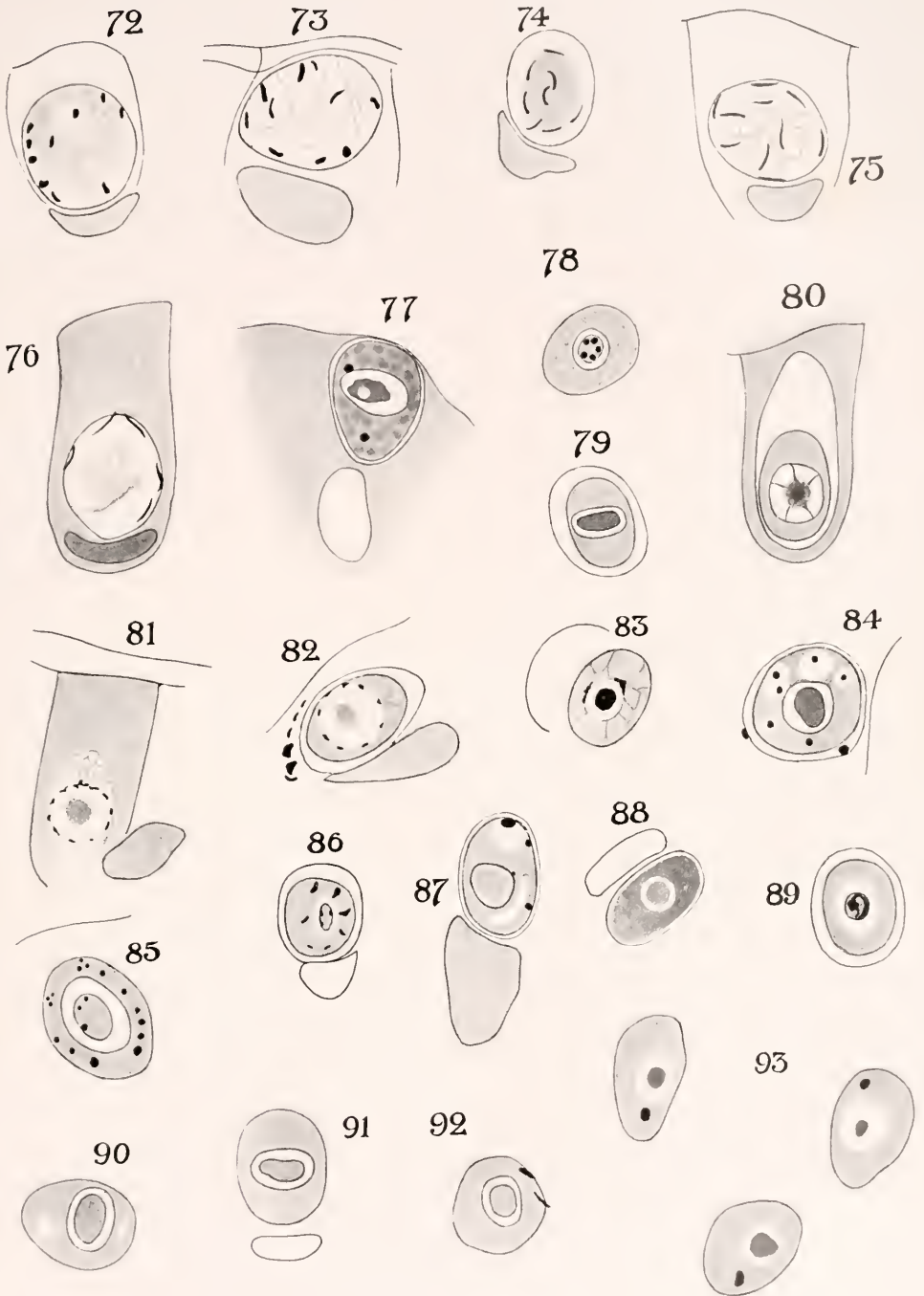




CRAWLEY: SEXUAL EVOLUTION OF SARCOCYSTIS









- 1914. Zu einigen strittigen Punkten der Sarkosporidienforschung. <Arch. de zool. expér. et gén., Par., v. 53 (9), juin, pp. 579-596, pls. 17-18, figs. 1-40.
- FANTHAM, H. B. 1913. *Sarcocystis colii*, n. sp., a sarcosporidian occurring in the red-faced African mouse bird, *Colinus erythronotus*. <Proc. Cambridge [Eng.] Phil. Soc., v. 17 (3), Sept. 8, pp. 221-224, pl. 5.
- LABBÉ, ALPHONSE. 1899. Sporozoa. 8°. Berlin. (Das Tierreich, Berl., 5. Lief., xx + 180 pp., 196 figs.)
- MINCHIN, E. A. 1912. An introduction to the study of the Protozoa, with special reference to the parasitic forms. xi + 517 pp., 194 figs. 8°. London.
- SCHAUDINN, FRITZ. 1900. Untersuchungen über den Generationswechsel bei Coccidien. <Zool. Jahrb., Jena, Abt. f. Anat., v. 13 (2), 22. Jan., pp. 197-292, pls. 13-16, figs. 1-108.