

Hodgkins Fund

THE AIR-SACS OF THE PIGEON

BY BRUNO MÜLLER

The present investigation of the air-sacs of the pigeon was carried out at the Zoölogical Laboratory of the German University at Prague with the assistance of the Hodgkins Fund of the Smithsonian Institution. It was under the supervision of Prof. R. von Lendenfeld, the director of that laboratory. I express my warmest thanks for his active interest in this work, his kindness in placing the necessary facilities at my disposal, and his valuable advice.

INTRODUCTION

Although the air-sacs of birds have been carefully investigated by many authors and our knowledge of them is quite extensive, none of the theories advanced concerning their function has found universal acceptance. In this essay an attempt is made to throw more light on this subject. The most reliable basis for a solution of the problem seemed to me to be an exact knowledge of the morphology of the air-sac system in some species of birds known as good fliers and abundantly provided with these organs. Such a bird is the pigeon, and this species appeared particularly suitable because numerous specimens of it are readily obtainable, a consideration of special importance, since, as was soon found, the air-sacs are subject to very considerable variation in different individuals of the same species, which makes it impossible to describe these structures in any species with scientific exactitude without studying them in a large number of specimens. But it was not only this consideration that led me to select the pigeon as the subject of my investigations. I was also led to make this choice by the fact that most of the physiological studies on air-sacs have been carried out with this species. Although much has been written on the morphology of the air-sacs of the pigeon, the data given in the literature on the subject are by no means complete and in several respects inexact; and there exist no correct and comprehensive graphic representations of the air-sac system of this species.

I have not included an historical review of the development of our knowledge of the air-sacs, because such reviews are given in the

recent works on this subject by Roché (1891, p. 4), Baer (1896, p. 454), and Bertelli (1900, p. 45). A list of the literature relating to the subject is given at the conclusion of this paper.

METHODS

The investigations were made upon our ordinary semi-domesticated pigeon (*Columba livia*). It is by no means easy to demonstrate the air-sacs with all their diverticula in their true shape and size. Most authors who have studied the morphology of these organs have employed the ordinary injection-method, that is to say, they injected fresh specimens. Although this method, when judiciously applied, may give useful results, it is not free from defects. If the air-sacs are filled with a suitable stiff-setting mass, it is possible, by dissecting out the injected material, to obtain a cast showing the shape of the cavities. Unfortunately it is impossible to expel all the air from the sacs before injecting them, so the injected mass can fill only a portion of the cavities, the spaces occupied by the residual air appearing as hollows in the cast. It is true that the mass penetrates well into the large sacs. These, however, are easily enough demonstrated without injection. Into the smaller diverticula and secondary passages which are hard to find by mere dissection, it penetrates only partially, or not at all. Some authors, as Roché (1891, p. 17) and Plateau (1890, p. 72) have got rid of most of the residual air by means of complicated systems of tubes inserted into the air-sacs; but this method also has its disadvantages. In life the air-sacs are enlarged by pressure on their walls varying locally with the nature of the surrounding structures and the size of the sac; when injected, the walls are subjected to a uniform pressure. The expansion of the various parts of the air-sac system produced by injection is therefore very different from their normal expansion in life.

Results of injections vary also according to the position of the bird during the process; if it is injected when lying on its back the air-sacs are filled in a different manner than if it is injected when lying on its ventral side. It may well be that this unreliability of the injection method is responsible for the mistake made by Baer (1896, vol. XXI, fig. 3a) in representing the lung of the pigeon relatively much too small, a mistake which appears to have markedly influenced his views regarding the mechanical work of breathing in birds.

An injection-mass cannot be forced in without using considerable pressure. This causes an abnormal enlargement of the thoracic and

abdominal cavities; the crop is pushed forward and the internal organs, especially the intestines, are compressed. The principal expansible parts of the air-sac system appear in such preparations much too large, the secondary diverticula which are less expansible much too small. The high pressure usually bursts the thin walls of the air-sacs in one or two places, causing effusions of the injected material, which may lead to erroneous deductions. I am inclined to suspect that the *saccus subpectoralis* described by Baer (1896, p. 437) owes its origin, or at least its great size, to a rupture of this sort. This structure is also seen in my injected specimens, but it is an entirely artificial product, arising as an effusion from a sacculation of the *diverticulum axillare*. Similar effusions are often observed arising from the diverticula that surround the heart.

A better method than the direct injection of a setting mass is the following: A pigeon killed with chloroform or ether is placed in formol, and for a period varying from some days up to two weeks strong formol is also injected with gentle pressure through a canula into the trachea, and thence into the air-sacs. The apparatus I used for this purpose is very simple. I connected a water reservoir with a wash bottle 1.5 m. below it. This produced in the wash bottle a constant and gentle pressure, which was conveyed to a second bottle containing formol, which was thus forced through rubber tubing and a canula into the trachea, and thence into the air-sacs. By this method the air-sacs are hardened in a moderately distended condition. As soon as the hardening is complete, suitable openings can be cut without causing any change in the shape of the air-sacs through collapse, and they can then be satisfactorily injected.

For the injections I used paraffine and gelatine (ten per cent with Berlin blue or carmine). The large air-sacs could easily be completely filled with either material; the smaller diverticula, however, could only be filled with the gelatine and by changing the position of the pigeon many times and using massage during the injection. Even in this way I could not inject all parts of the air-sac system at once, but I succeeded in filling all the parts of the system in different specimens, so that it was possible, by combining the results from a number of pigeons treated in this manner, to obtain a clear conception of their distribution, shape, and size.

The air cavities in the bones can easily be made visible by an injection of glycerine and water with much Berlin blue. The animal was distended with the injected fluid for about 12 hours, during which time it was kept warm, often changed in position, shaken and massaged, and after that it was hardened in alcohol. The pneumatic

parts of the bones could then be recognized from without by means of their blue color.

In order to obtain an idea of the degree of expansion of the air-sacs during the various phases of breathing, I strangled several pigeons, some during inspiration and some during expiration, so suddenly that no more air could pass either in or out, and then hardened them by long immersion in formol.

THE AIR-SAC-SYSTEM IN GENERAL

In pigeons and other flying birds there are numerous hollow, air-filled spaces, the air-sacs, some of which are very large. Their size varies with the respiratory and other movements. All are connected either directly or indirectly with the bronchi, and through them and the trachea with the outer air. The air passes from the buccopharyngeal cavity (fig. 12, CO),¹ into the larynx (fig. 12, L), the trachea (figs. 2, 7, 11, 12, TR), the syrinx (fig. 12, S), and the two bronchi (figs. 9, 10, 12, BR). From the latter two tubes branch off to the air-sacs, of which 10 groups, forming 5 pairs, can be distinguished:

1. Cervical sacs (in the region of the nape of the neck).
2. Interclavicular sacs (adherent to the syrinx and situated ventrally, laterally, and proximally from it).
3. Anterior intermediate sacs.
4. Posterior intermediate sacs.
(in the thoracic cavity).
5. Abdominal sacs (in the abdominal cavity).

Each of the 10 groups consists of a main sac, from which numerous diverticula arise. The latter, as well as the main sacs, possess many secondary diverticula (sacculi).

Before considering the details of the air-sacs it will be well to determine the localities where they are situated and their relations to the diaphragmatic membranes.

THE DIAPHRAGMATIC MEMBRANES

The open communication between the cavities of the lungs and the air-sacs makes diaphragmatic breathing, as it occurs in mammals, impossible in birds. The diaphragm of birds is quite different in structure and function from that of mammals. It is composed of two parts, viz., the pulmonary diaphragm, which separates the air-sacs from the lungs and effects the expansion of the latter in a man-

¹ The figures referred to are on plates XLV-XLIX.

ner quite different from that of the mammalian diaphragm; and the abdominal diaphragm, which separates the air-sacs from the intestine and has nothing to do with respiration.

THE PULMONARY DIAPHRAGM (FIG. 1, DIP)

(Anterior, transverse or trilateral diaphragm; Pulmonary aponeurosis, Huxley; Diaphragme pulmonaire, Sappey; Diaphragme antérieur, Milne Edwards.)

This diaphragm is formed by that portion of the pleura which covers, as an aponeurotic septum, the ventral surface of each lung. The medio-ventral surfaces of the two lungs closely adhere to the diaphragm, which is penetrated by blood-vessels and by the tubes connecting the lungs with the air-sacs. Where the two halves of the pulmonary diaphragm approach each other in the median plane, they adhere to the mediastinum which extends in the shape of a vertical septum in the median plane of the body, is attached to the dorsal vertebræ, and separates the two lungs. This diaphragm, therefore, shuts off from the rest of the body-cavity a special space, the *Cavum pulmonale*, which contains the lungs and the small intra-thoracic portion of the cervical sacs.

Being adherent to the pleura, this membrane assists in the expansion of the lungs during inspiration. It is enabled to perform this function by the two pulmonary muscles of Perrault (fig. 8, MP), which in many birds are strongly developed. In the pigeon these muscles are not so large as in some other birds, as, for example, the cassowary, but they are not at all rudimentary and are certainly functional. These muscles arise from the true ribs near their sterno-costal articulations, and run, parallel to the ribs, obliquely downward to the pulmonary diaphragm. When they contract, this diaphragm is drawn downward and becomes ventrally convex, the pulmonary cavity is enlarged, and the lungs expand. The muscles arising from the anterior ribs are membranous, and unite to form a muscular sheet which, although quite thin in some places, is nowhere pierced by an air-tube. The muscle arising from the lowest rib is more cylindrical in form and not so completely coalesced with those in front as they are with each other. Its insertion coincides with the partition that separates the anterior and posterior sacci intermedii, and extends as far as the proximal edge of the ostium intermedium posterius. From the last rib a second flat pulmonary muscle arises medially, which appears as a branch of the one just mentioned. This muscle extends between the ostium intermedium posterius (figs. 8, 9, 10, 12, OIP) and the ostium posterius (figs. 8, 9, 10, 12, OP), and is attached to the diaphragm.

It crosses the ventral surface of the lung diagonally, whereby it is enabled to assist in the expansion of the pulmonary cavity. The upper muscle of the last rib also follows a somewhat oblique course. All these muscles are innervated by branches of the intercostal nerves.

THE ABDOMINAL DIAPHRAGM (FIG. I, DIA)

(Posterior, oblique, vertical or abdominal diaphragm; Oblique septum, Huxley; Diaphragme thoraco-abdominal, Sappey; Diaphragme postérieur, Milne Edwards.)

This membrane, which is likewise aponeurotic, appears to be a continuation of the ventral border of the mediastinum. It extends from that border on either side, obliquely to the wall of the body cavity, and is attached in front to the pericardium. It therefore incloses a wedge-shaped space (the *cavum cardio-abdominale* of Huxley), whose base is at the sternum and whose sharp edge is at the ventral border of the mediastinum. It reaches forward as far as the pericardium, and appears there to be shut off by the heart. Backwards, it extends as far as the posterior extremity of the abdominal cavity. In it lie the heart and all the other viscera.

Symmetrically placed on either side of this wedge-shaped space there is a space similar in form whose sharp edge is formed by the union of the pulmonary diaphragm with the outer surface of the abdominal diaphragm. The bases of these secondary cuneiform spaces, the *cava subpulmonalia* of Huxley, are the lateral walls of the body cavity. Each one of these two spaces is divided by four septa into as many portions, each of which is occupied by an air-sac. The first sac lies, as already mentioned, in the *cavum pulmonale*. The second extends towards its symmetrical companion of the opposite side and unites with it, where the *cavum cardio-abdominale*, that elsewhere separates these two cavities, is wanting. The arrangement of the air-sacs is dependent on the development of the diaphragms, which are never pierced by air ducts. When pneumatic connections are present they are in every case extra-thoracic. The general plan of the system is as follows:

In the *cavum cardio-abdominale* lies the *saccus cervicalis*;

In the *cavum subpulmonale*, *loculus primus*, lies the *saccus interclavicularis*;

In the *cavum subpulmonale*, *loculus secundus*, lies the *saccus intermedius anterior*;

In the *cavum subpulmonale*, *loculus tertius*, lies the *saccus intermedius posterior*;

In the cavum subpulmonale, *loculus quartus*, lies the *saccus abdominalis*.

Before entering on the description of these sacs we will consider more closely the organs from which the air-sacs phylogenetically and ontogenetically arise, the lungs.

THE LUNGS (FIGS. 9, 10; FIGS. 1, 2, 11, 12, P)

Each of the two symmetrical lungs has the shape of a three-sided pyramid with posterior base, and a dorsal, a medial, and a ventral face.

The dorsal face of the lung pyramid is convex and of greater extent than the others. It extrudes in the intercostal spaces, the ribs lying in deep, transverse, furrow-like depressions of the lung (fig. 10, C). One of the two edges of the lung-pyramid bounding this face extends along the vertebral column; the other, which is convex downward, extends along the ribs in a line ventral from their uncinatè processes. At its lowest point it usually reaches the line of junction between the vertebral and sternal portions of the ribs.

The medial face of the lung pyramid is the smallest in extent. It lies in the median plane of the animal, and is in contact with the mediastinum that separates the two lungs.

The ventral face of the lung pyramid (fig. 9) is more irregular than the two others. Its anterior portion (fig. 9, SICL) is convex, its posterior (fig. 9, SI) concave. Both portions, but especially the anterior one, have a rough appearance, and are in places markedly furrowed. These irregularities are caused by the bronchial branches, many of which lie very near this ventral surface and are covered, on their ventral side, with only a thin membrane. As long as the pleura is intact the ventral surface of the lung appears as if it were really as smooth (fig. 9, PL) as it is generally figured and described in the text-books. If, however, the pleura is removed, the true character of this surface is at once revealed.

Near the center of the ventral face of the lung pyramid the bronchus enters. Within the lung it retains for a considerable distance its cartilaginous character, although rings are not present in its wall. From the place of entrance it extends in an arch, convex towards the ribs, to the *ostium posterius* (figs. 8, 9, 10, 12, OP), situated near the middle (somewhat nearer the ribs than the median plane) of the posterior border of the lung. The part of the bronchus lying within the lung has been named by Huxley the *mesobronchium*. The anterior portion of this *mesobronchium* is distended to the *vestibulum* (fig. 10, V), which in many birds has the shape of a

large ampulla, but is only slightly developed in the pigeon. In its further course the mesobronchium narrows considerably, and at its posterior end, the ostium posterius, it is not wider than the other air-tubes that approach that opening. In the literature on this subject it is usually stated that the mesobronchium opens into the saccus abdominalis with a wide orifice. Perhaps this may occur normally in other birds; in the pigeon I have seen such an arrangement only once.

From the middle of the mesobronchium there is given off ventrally a branch-canal which, on account of its small caliber, is to be considered an accessory passage. Unlike the mesobronchium, it retains throughout its course the same width. It extends to the ostium intermedium posterius (figs. 8, 9, 10, 12, OIP), which is situated on the posterior border of the lung, laterally and a little ventrally from the ostium posterius. Some distance before reaching this opening the canal lies just below the ventral surface of the lung (fig. 8).

The wall of the mesobronchium is perforated by numerous openings which lead into canals supplying the lung and the air-sacs with air. Those supplying the lung itself are the entobronchia; those extending beyond the lung and supplying the air-sacs, the ectobronchia. Besides numerous small openings, eleven large ones can be distinguished. All these lie upon the dorsal side of the mesobronchium. In the anterior portion of the mesobronchium—that is to say, in the vestibulum—there are four large openings quite close together. From these the entobronchia take their origin. The seven other openings are smaller and situated at nearly equal distances from each other in the remaining central and posterior portions of the mesobronchium. Their size decreases posteriorly. These openings lead into the seven ectobronchia (fig. 10, ECT). Sappey calls the entobronchia “*bronches divergentes*”; the ectobronchia, because they run near the ribs, “*bronches costales*.” The former are regular, the latter irregular. From the ento- and ectobronchia lateral branches, the parabronchia (Lungenpfeifen; canaux tertiaires, Cuvier; bronchial tubes) are given off. These are so numerous, and the holes in the sides of the ecto- and entobronchia, which lead into them, lie so close together that the walls of these canals have a sieve-like appearance. The angles at which the parabronchia leave the ecto- and entobronchia always closely approach a right angle, but apart from this, these branch canals are variously arranged in one row, in two rows, or spirally. These parabronchia impart to the bird's lung its characteristic appearance. They often anastomose with each other, and I have found that occasionally the

parabronchia of different bronchial branches communicate with each other in this manner. With one exception the ento- and ectobronchia do not divide into branches of equal value, but end blindly, gradually thinning out, or terminating in the air-sacs.

THE OSTIA

Besides the entrance for the bronchus and the already mentioned ostium posterius, each lung possesses four other ostia, the ostium cervicale, claviculare, intermedium anterius, and intermedium posterius. The ostium cervicale (præbronchiale, Gadow; figs. 9, 10, and 12, OC) is penetrated by the distal branch of the ectobronchium primum. It lies between the bronchus and the apex of the lung, and supplies the cervical sac. The ostium claviculare (subbronchiale, Gadow; figs. 9 and 12, OCL) is penetrated by the ectobronchium primum itself. It lies in front of the entrance of the bronchus into the lung, and supplies the interclavicular sac. The ostium intermedium anterius (figs. 9 and 12, OIA) is penetrated by the ectobronchium tertium. It is situated behind and medially from the entrance of the bronchus and supplies the saccus intermedius anterior. The ostium intermedium (figs. 8, 9, 10, and 12, IOP) is penetrated by a special lateral branch of the mesobronchium. It lies near the ostium posterius, and supplies the saccus intermedius posterior.

Concerning the shape of the ostia, it may be remarked that the transition from the lung to the air-sac is somewhat gradual. Eberth (1863, p. 436) has stated that the ciliated epithelium of the air-passages is continued through the ostia posteriora into the abdominal air-sacs. Recent authors have confirmed this, and it is only a question of how far into the air-sacs the ciliated epithelium extends. Eberth (1863, p. 436) reports that he has seen at these ostia oblique and radial muscle fibers. I was unable to verify this, and found no trace of a true muscular sphincter at these ostia.

THE AIR-SACS

TRUE AIR-SACS AND OTHER AIR-SPACES

I here regard as true air-sacs only those air-filled spaces in the body that arise ontogenetically from branches of the bronchi. The bronchial branches that form the air-sacs develop rapidly, and early invade the body cavity. Besides these true air-sacs, other air-spaces occur. Such are the tracheal labyrinths of ducks and emus (Gadow, 1890), and the pneumatic cavities of the bones of the head.

THE NOMENCLATURE OF THE PARTS OF THE AIR-SAC-SYSTEM

In order to avoid confusion I will restrict the term *sac* to the large primary air-spaces, and not use it, as is usually done, also for the processes arising from these primary spaces. These processes I will call *diverticula*, and instead of saying axillary sac, subscapular sac, etc., say axillary diverticulum, subscapular diverticulum, etc. If this terminology be used, the names indicate the morphological value of the part of the air-sac system, for example, that the axillary diverticulum and the interclavicular sac are not structures of the same morphological value and homologous. The *sac* is an enlargement of a bronchial branch; the *diverticulum* an appendage of the sac. Air-spaces that take their origin from diverticula I will call outgrowths or secondary diverticula. According to this nomenclature the pigeon has five pairs of large (primary) air-sacs. Besides these, other true (primary) sacs may exceptionally occur. Gadow (1891, p. 751) mentions numerous openings of the secondary bronchi at the surface of the lung which lead into such sacs. I found such sacs only very rarely, in a few individuals and in varying localities, mostly near the ribs. Having no regularity in their arrangement or occurrence, they are, in the pigeon at least, only to be considered as abnormal structures, and both on that account and because of their small size, can hardly be regarded as possessing any great functional importance.

RELATIONS OF THE AIR-SACS OF BIRDS TO SIMILAR STRUCTURES IN REPTILES

In the chameleon and some other reptiles bronchial branches extending beyond the lungs are observed. These are homologous with the true (primary) air-sacs of birds. At an early stage of development the reptilian lung is similar to that of birds. If, as Milani (1897, p. 47) remarks, we compare a bird's lung with that of *Thalassochelys caretta*, and disregard the adaptive peculiarities of this organ in the latter, we find that the chief air duct of the bird's lung, although shorter, essentially corresponds, so far as it is supported by cartilage, with the intrapulmonary bronchus of the lung of *Thalassochelys*, and that there are structures in the lung of the latter homologous with the bronchial tubes and the parabronchia in the lung of the former.

THE PRIMARY AIR-SACS

The Sacci cervicales

Synonyms

- Bertelli*: Sacchi cervicali.
Campana: Réceptacle supérieur postérieur.
Colas: Sac trachélien.
Fatio: Sacci cervales.
Gegenbaur: Sacci cervales.
Gonillot: Réservoirs supralaryngiens.
Huxley: Præbronchial air-sac.
Jacquemin: Poches pneumatiques pectorales.
Merrem: Bulla jugularis.
Milne Edwards: Sacci cervicales (Réservoirs cervicaux).
Owen: Cervical air-cells.
Pagenstecher: Sacci præbronchiales.
Saphey: Sacci cervicales.
Stannius: Vordere thoracale Zelle.
Tiedemann: Cellula cordis posteriora.

The two cervical sacs arise from the right and left ostia cervicalia respectively. According to Selenka (1866, p. 181) they are first visible in the chick on the 11th day of incubation as diminutive protuberances. Bertelli (1900, p. 162) says, regarding their origin in this bird, "Al quinto giorno appariscono gli abbozzi dei sacchi cervicali. Prendono origine dalla meta dorsale della periferia dei tubi pulmonali. Si spingono in avanti prima nelle cavita pleurichi, poi nel tessuto mediastinale e così raggiungono il collo." The two (right and left) cervical sacs together form a morphological unit. In the adult pigeon they are paired, quite symmetrical, and not in direct communication with each other. The ostia cervicalia from which they arise lie just behind the bronchus. As, however, these sacs assume the form of dorsoventrally compressed canals, which extend between the pleura and the lung towards the anterior pulmonary wall, the ostia seem, when the pleura is not removed, to lie at the end of the medial third of the anterior margins of the lungs. From these (apparent) ostia the sacci cervicales extend forward, forming two lobes which are closely attached to the ventral and lateral surfaces of the muscles of the neck (figs. 7 and 11, SC; fig. 2, SC). These sacs are small. Their medio-dorsal surfaces touch the ventro-lateral musculature of the neck, their latero-ventral surfaces are parallel to the medio-dorsal ones, and touch the diverticulum œsophageo-tracheale, the diverticula subscapularia of the interclavicular sac (figs. 7 and 11, DO&E;TR), the œsophagus (fig. 7, OE), the trachea (figs. 2, 7, 11, and 12, TR), the vagus nerves and

the jugular veins. Ventrally from the vertebral column, the right and left cervical sacs are separated from each other by only a thin partition. Anteriorly they extend to the distal end of the tenth cervical vertebra, posteriorly as far as the lung-margin. The external border clings closely to the musculature of the neck and curves in a dorsal direction, ending with a small oval extension, the *pars ovalis* (fig. 12, SC 2), which reaches as far as the *diverticulum subscapulare*. Baer (1896, p. 432) says concerning these sacs: "Von der Lungenspitze entspringend, reichen sie ungefähr bis zur Mitte des letzten Halswirbels." I cannot agree with this. Although I have seen many variations in the length of the cervical sacs, I have never observed them so short as that in the pigeon. In conclusion it should be mentioned that the *sacci cervicales* communicate with the *saccus interclavicularis*. This communication is effected by means of the *diverticula subscapularia*, which are described below.

THE DIVERTICULA

While the cervical sacs themselves are simple, their *diverticula* are complicated. The sacs and their *diverticula* pneumatize the vertebral column and its muscles. Since the *diverticula* of the cervical sacs extend both into the neck and into the thorax, they may be divided into two distinct groups or systems belonging to these two regions, the cervical and the thoracic.

THE CERVICAL SYSTEM

From the proximal end of the *pars ovalis* (fig. 12, SC 2) of each cervical sac a flattened canal arises which usually penetrates the cervical muscles in the region of the 11th cervical vertebra, and then turns forward, becoming a long, almost straight canal, the *canalis intertransversarius* (figs. 3, 4, 5, 7, 11, and 12, CI 2). This canal is usually connected with the sac by a second communication further on. Together with the ascending vertebral artery, the vertebral vein and the deep cervical sympathetic nerve, the *canalis intertransversarius* passes forward through the *foramina transversaria* formed by the heads and tubercles of the ribs. Beyond a point lying in the region between the 5th and 7th cervical vertebræ this canal (figs. 11 and 12, CI 1) is enlarged like a spindle between the successive *foramina transversaria*, through which it passes; further on, it becomes simply cylindrical and finally ends on the distal side of the atlas which it pneumatizes (figs. 11 and 12, CI 3).

Two kinds of *diverticula* are given off from this canal, the *diverticula supravertebralia* (figs. 3, 4, 5, 7, 11, 12, DSPV) and the diver-

ticula medullaria. The supravertebral diverticula surround the intervertebral articulations and increase the relative mobility of the vertebræ. These diverticula are given off from the anterior ends of the portions (spindle-shaped enlargements) of the canal lying between the successive transverse processes. They extend medially, are club-shaped, and terminate before reaching the median plane. They lie dorsally, behind the vertebræ, and are largest in the middle of the neck, where the relative mobility of the vertebræ is greatest. The medullary diverticula are given off from the cervical canal just in front of the foramina transversaria. They consist of extravertebral and intravertebral portions. The extravertebral portions are small and simple vesicles. The intravertebral portions, which I name diverticula supramedullaria (fig. 12, DSPM 1; figs. 11 and 12, DSPM 2), enter the medullary canal through the intervertebral foramina, and extend dorsally from the spinal cord. Within the medullary canal they widen out and impinge upon the corresponding diverticula of the opposite side. They partly unite with these as well as with the adjacent diverticula (in front and behind) of the same side, to form a continuous canal, sickle-shaped in transverse section, and lying above the medulla, the canalis supramedullaris (figs. 3, 4, 5, 7, and 12, MEA). The partial absorption of the walls of these diverticula which leads to the formation of this canal, takes place during the growth of the bird, and posteriorly, near the thorax, where the canal is widest, is usually quite completed in middle-aged birds. Anteriorly this absorption decreases as the medullary diverticula become smaller, the completely formed supramedullary canal usually extending no farther than the third or fourth cervical vertebra. Anterior to that it is replaced by two rows of isolated diverticula (fig. 12). The posterior end of the supramedullary canal lies near the last cervical vertebra. Occasionally it communicates here with the corresponding canal of the thoracic vertebræ. Very delicate extensions of the canales intertransversarii pneumatize the cervical vertebræ. They penetrate the bone radially, but are otherwise quite irregular.

THE THORACIC SYSTEM

The diverticula of the sacci cervicales in the thorax are arranged like those in the neck, but are not so highly developed. These thoracic diverticula pneumatize the thoracic vertebræ and form a supramedullary canal. Extravertebral outgrowths are absent. From the distal end of the pars ovalis of either side a ventrally flattened tubule arises. This passes between the vertebral muscles and through the intervertebral foramen in front of the first thoracic

vertebra into the spinal canal, where it unites with the corresponding tubule from the opposite side, both together forming a duct similar to the canalis supramedullaris (figs. 1, 2, 12, MEP). This duct extends backward but does not reach the last thoracic vertebra. It is very variable, and sends fine branches into the vertebræ and the ribs. According to Baer (1896, p. 434), small diverticula, similar to the canales intertransversarii in the neck, arise from this duct and surround the costo-vertebral articulations. I have not been able to make out anything of this kind in the pigeon. The lungs of the pigeon insinuate themselves so completely between the costo-vertebral articulations that, if such diverticula were present, they would penetrate into the lungs. It has sometimes seemed to me that the ribs were pneumatized directly from the lungs. As a rule, however, the ribs, as is always the case with the vertebræ, are supplied from the medullary canal by means of fine tubules.

THE SACCI CERVICALES IN OTHER BIRDS

Almost all birds possess, like the pigeon, sacci cervicales, but in other species they are usually differently shaped. In the stork, the flamingo, and the crested screamer (*Chauna*) they are divided by numerous partitions into a corresponding number of small spaces. In the albatross, Ulrich has found (1904, p. 30) a tripartite division of these sacs into a median unpaired one and two lateral symmetrical ones. In the cockatoo, Bignon discovered (1887, p. 36) lachrymal, ethmoidal, and supramaxillary extensions of the cervical air-sac system. In this bird also occipital, frontal, parietal, quadratal, and mandibular air cavities are found. These, however, are not true (pneumonial) air-sacs, but diverticula of the nasal chambers. A diverticulum of the cervical system which is entirely wanting in the pigeon is described by Baer (1896, p. 434) as follows: "Bei manchen Raubvögeln, beim Bussard, fand ich endlich eine dritte Fortsetzung der Cervikalsäcke. Dieselbe zieht sich als ziemlich weite, in regelmässigen Abständen perlschnurartig eingeschnurte Röhre, nur von Hautmuskeln des Halses bedeckt, zu beiden Seiten der Spinalfortsätze nach oben bis zum Hinterhauptsbein, wo sie blind endigt."

The Saccus Interclavicularis

Synonyms

- Bertelli*: Sacche interclaviculare.
Campana: Réceptacle supérieur antérieur.
Carus: Erster Luftsack.
Colas: Sac cardiaque.
Girardi: Grosse Brustzelle.

- Gouillot*: Réservoir infralaryngien.
Huxley: Infrabronchial air-sac.
Jacquemin: Poche pneumatique sous-claviculaire.
Merrem: Bulla cordis anterior.
Milne Edwards: Réservoir claviculaire.
Owen: Anterior thoracic cell.
Sappey: Réservoir thoracique.
Tiedemann: Vordere Herzluftzelle.

In full-grown pigeons there is, as in most other birds when full grown, only a single, unpaired, interclavicular sac. This arises from the union in the median plane of two symmetrical, originally completely separate structures. The two distinct sacs which coalesce to form the interclavicular cavity arise from the right and left ostia clavicularia, respectively (figs. 9 and 12, OCL).

In the chick, Bertelli (1900, p. 162) noted these two sacs as early as the sixth day of incubation. They are at first situated dorsally and laterally; they afterwards grow downwards and towards the median plane. They reach their definite position at the end of the eighth day. These sacs give off diverticula which at the time of hatching, have already reached the humerus. Their ingrowth into this bone takes place later. The diverticula of these sacs are very much larger and more complicated than the sacs themselves. As Hunter (1774, p. 209) noted long ago, the median or central portion of the sac is permeated by numerous trabeculae. Hunter says concerning them: "The superior part of the lungs opens into the large cells of a loose network, through which the trachea, œsophagus, and large vessels, going from, and coming to the head, pass."

The interclavicular sac occupies the anterior part of the thoracic cavity, and extends from the membrane stretched out between the branches of the furculum (fig. 7, MF) to the base of the heart, the sacci intermedii anteriores on both sides of the latter, the free ribs, the coracoid, the ligamentum sterno-furculare, and the anterior portion of the sternum. Dorsally the trachea, the œsophagus, the jugular veins, and the vagus nerves separate it from the cervical sacs. The anterior end of the heart, the great vessels, the bifurcation of the trachea, the two bronchi, and the œsophagus lie pretty freely in the cavity of the interclavicular sac. The various parts of the interclavicular sac occupy the space between these organs. Structures indicating the origin of the sac from two distinct points can not be made out in the full-grown pigeon, but we observe that the whole sac is partially divided into three chambers, a medial and two lateral ones.

THE MEDIAL CHAMBER

The medial chamber contains the trachea and its bifurcation; it reaches posteriorly to the heart, dorsally to the sacci cervicales and the œsophagus and laterally to the two lateral chambers. Along its lateral walls run the common carotid arteries and the jugular veins. It pushes a diverticulum, the diverticulum subcordale (fig. 2, DSC) backward between the heart and the sternum. This diverticulum does not reach the posterior margin of this bone, but it extends a good deal farther than the heart, so that the designation given it by Ulrich (1904, p. 332), diverticulum præcordiale, must be replaced by diverticulum subcordale. There is also a well-developed diverticulum supracordale. This arises behind the former, and is therefore not visible in the section represented in fig. 2. It is rather short, and, unlike the former, somewhat compressed. In the deltoid opening traversed by the arteriæ carotides communes, the medial chamber bulges markedly forward, and thus forms the diverticulum œsophageo-tracheale (figs. 7 and 11, DOETR), which, according to Ulrich (1904, p. 331), extends forward right to the head. This diverticulum is not bilaterally symmetrical. It lies between the œsophagus and the trachea, and partly surrounds the latter—not wholly, part of the trachea being attached to certain muscles of the neck.

THE LATERAL CHAMBERS

The two lateral chambers are symmetrical with each other. They occupy the remainder of the space whose limits have been described above, and give off the diverticula costalia (figs. 2 and 11, DC) posteriorly (cf. Roché, 1891, p. 64). These diverticula occupy the space between the heart and the sterno-costal bones, and together with the diverticula of the medial chamber, described above, form a pneumatic investment which surrounds the whole of the anterior, larger portion of the heart. Besides these intrathoracic diverticula, extrathoracic diverticula are also given off from the lateral chambers. These are the diverticula subscapularia, suprahumeralia, and sternalia.

THE DIVERTICULUM SUBSCAPULARE

From each lateral chamber of the interclavicular sac a wide diverticulum, the diverticulum subscapulare (figs. 7, 11, and 12, DSSC 1), arises. This follows the ligamentum sterno-furculare upwards, and, bending backwards farther on, it passes between the upper end of the coracoid and the vertebral column along the brachial plexus. Here only this plexus and a thin membrane separate it from

the interclavicular sac itself. Beyond, it extends backwards past the oval diverticulum of the saccus cervicalis, into the space between the scapula and the anterior ribs, where it attains its greatest extent (figs. 2, 11, and 12, DSSC 3). Its posterior end usually lies upon the second true rib under the scapula. Its anterior end reaches as far as the diverticulum œsophageo-tracheale. Near the oval diverticulum of the cervical sac it communicates with the latter by means of a small but sharply defined triangular opening. Sometimes, but not always, I have seen it communicate also with the suprahumeral diverticulum. In these cases a delicate canal passed outward along the lower border of the scapula and the musculus scapulo-humeralis anterior, and opened into the suprahumeral diverticulum near the tuberculum inferius humeri.

It should also be mentioned that in two cases the principal portion of the diverticulum subscapulare was separated from the interclavicular sac and its own proximal portion by a partition which, in the region of the brachial plexus, divided the diverticulum into two chambers. In these cases the subscapular diverticula were, of course, always connected with the suprahumeral diverticulum, and each of the three chambers appeared to give rise to an anterior diverticulum. The communication between the subscapular and suprahumeral is not infrequently present, and by no means restricted to the cases where the principal portion of the subscapular diverticulum is divided from the interclavicular sac. But still, although not uncommon, this is exceptional, and I was much surprised to find this state of things described as the normal condition by Roché, who says (1891, p. 31): "Ces deux derniers (sacculs sousscapulaire et humeral) ont une origine commune, sortant du réservoir claviculaire par un orifice ménagé en arrière du muscle petit abducteur de l'humerus." Baer (1896, p. 436) expresses himself similarly. I have not found in the literature on the air-sacs of the pigeon any statement concerning a connection between the diverticulum subscapulare and the saccus cervicalis, but it has been described in the domestic fowl.

From the ventral side of the diverticulum subscapulare an outgrowth (figs. 2, 11, and 12, DSSC 3) arises, which extends, parallel to the second false rib, towards the processus lateralis anterior sterni, without, however, reaching it. It is often broken up into a row of small sacculs, and may be so wide at its base that the diverticulum from which it arises appears drawn out locally, as it were, to form it. In this case the outgrowth attains a quite unusual size. The walls of the diverticulum for the most part adhere to the surrounding muscles, only a small portion being free.

THE DIVERTICULUM AXILLARE

From the outer side of each lateral chamber of the interclavicular sac processes arise which extend between the musculus coraco-brachialis posterior and the musculus subcoracoideus, and usually also between the musculus coraco-brachialis brevis and the distal edge of the coracoid. These processes unite to form a spacious chamber, the diverticulum axillare (fig. 11, DA 1). The chamber is more or less completely subdivided into parts, and it has many outgrowths. The connection between its parts is slight, and in many other birds still slighter than in the pigeon. Most authors for this reason distinguish here two such parts, the axillary proper and the subpectoral, as distinct diverticula. The last named is an extension of the axillary diverticulum and lies between the musculus coraco-brachialis brevis and the coracoid. From it a distal outgrowth arises which passes for some distance between the musculus supracoracoideus and the musculus pectoralis major, and is always connected with the diverticulum axillare proper. It does not attain any very considerable size. I do not regard this outgrowth as a true diverticulum; it is not very important, and in two cases was absent altogether.

The principal part of the axillary diverticulum (figs. 2, 11, and 12, DSSC 3) occupies the axillary space between the supracoracoid, subcoracoid, posterior coraco-brachial, great pectoral, and biceps muscles. Medially where it abuts on the subcoracoid and supracoracoid muscles, the axillary vessels and nerves partly pass along its wall and partly penetrate it. The musculus pectoralis major limits the space occupied by this diverticulum on the medial side. Dorsally it extends to the ventral edge of the musculus scapuli humeralis posterior. The part of the membranous wall of the air-sac that divides it from the musculus pectoralis major is free: all the rest is completely adherent to the adjacent muscles. With the exception of a few insignificant fibers in the free membrane, I have found no proper muscular bundles in the wall of this air-sac.

From this diverticulum an outgrowth arises which passes over the short portion of the musculus triceps cubiti (pars humero-cubitalis) and enters the humerus through the foramen pneumaticum of that bone. The pars humero-cubitale of the musculus triceps cubiti arises from the tuberculum minus humeri and the lower part of the crista humeri. Together with the musculus scapuli humeralis posterior it must alternately close and open the foramen during the beating of the wing. I do not think that this has any great physiological significance. More important must be the rhythmic change of volume which the entire diverticulum undergoes during flight. From each

outgrowth a communicating canal passes backward to the diverticulum suprahumerales.

THE DIVERTICULUM SUPRAHUMERALE

This diverticulum (fig. 12, DSH) is much smaller than the axillary one. It covers the head of the humerus, and is bounded by the musculus scapuli humeralis posterior, the musculus triceps cubiti, the musculus biceps brachii, the musculus deltoides major, and the musculus latissimus dorsi. From a small principal cavity, several outgrowths extend between these muscles. It usually communicates, as already mentioned, with the subscapular and axillary diverticula. The connection with the axillary diverticulum is not always developed.

THE DIVERTICULUM STERNALE

An insignificant diverticulum, hitherto overlooked in the pigeon, arises from the interclavicular sac in the immediate vicinity of the lateral margin of the sternum. This diverticulum (figs. 2 and 11, DST) is attached to the musculus sterno-coracoideus. It is lenticular, and often provided with an outgrowth.

THE VARIABILITY OF THE INTERCLAVICULAR SAC

The interclavicular sac and its diverticula are very variable in the pigeon. Some of these variations have been referred to above. In general it may be said concerning them that the development of this system of air-sacs has a relation to the power of flight of the individual. On comparing these air-sacs in a pigeon that has spent its life in a cage with those found in one that has lived in the open and flown about a good deal, it will be seen that they are much larger and more highly developed in the latter than the former; it appears that disuse of the wings leads to a reduction of these air-sacs.

The Sacci Intermedii

Synonyms

Bertelli: Sacchi intermedii.

Campana: Réceptacles moyens supérieurs et postérieurs.

Colas: Sac hépatique.

Fatio: Sacci infracostales superiores et inferiores.

Gouillot: Réceptacles sous-costaux.

Huxley: Anterior and posterior intermediate air-sacs.

Jacquemin: Poches souscostales. Cellules hépatiques.

Merrem: Erster und zweiter Brustsack.

Owen: Lateral thoracic cells, Cellulæ hepaticæ.

Sappey: Réservoirs diaphragmatiques antérieurs et postérieurs.

The sacci intermedii are two pairs of air-sacs that closely correspond to each other in their configuration. This correspondence is so marked that most authors have given expression to it in the names applied to them. They occupy spaces morphologically and functionally similar between the pulmonary diaphragm, the abdominal diaphragm, and the outer wall of the thorax. These sacs are simple in shape and have no diverticula or secondary communications. The saccus intermedius of each side is divided into two parts, an anterior, the saccus intermedius anterior, and a posterior, the saccus intermedius posterior.

THE SACCI INTERMEDII ANTERIORES

According to Bertelli (1900, p. 162), these sacs are visible, in the developing chick, on the sixth day of incubation. On the tenth day they appear as flat vesicles spreading over the concave, ventral surfaces of the lungs. They arise from the right and left ostia intermedia anteriora. Once I saw several small ostia in the place of the single one. The sacs themselves (figs. 1, 11, and 12, SIA) occupy the anterior part of the space between the pulmonary and abdominal diaphragms, and are separated from the interclavicular sacs only by the air-sac walls themselves. They are apparently similarly developed in all birds. The following description, given by Roché (1891, p. 32) as that of their general type, applies also to the pigeon: "Les réservoirs antérieurs se trouvent ainsi délimités étant en rapport avec les poumons, en haut; la première côte, et l'artère pulmonaire, de chaque côté, en avant; les côtes en bas; le foie en dehors, ainsi que le cœur et le diverticule précardiaque du sac claviculaire; enfin, les réservoirs postérieurs, en arrière." These sacs are not in direct contact with the lungs, but separated from them by the pulmonary diaphragm. The pulmonary muscles of Perrault protrude into them. Each sac has the shape of a wedge, its base resting on the pulmonary diaphragm and its edge directed ventrally, and lying near the margin of the sternum. Backwards each sac extends to the last rib. Medially its posterior wall bends forward and unites with the pulmonary diaphragm. Since this sac has no free wall—even its medial side adhering to the pulmonary diaphragm—it does not collapse when the body cavity is opened, and it is probable that also during life it does not undergo any considerable changes in volume. It is, of course, strongly dilated during inspiration; since, however, the pulmonary muscles of Perrault undoubtedly draw the lung into the space it occupies this change of volume (dilatation) must to a great extent be compensated.

Irregularities in the structure of these sacs are seldom met with. Once I found near the ostium a few septa that did not, indeed, project far into the sac, but still divided its basal part into several chambers open towards its principal space. The ostium was situated in the largest of these. In another case I found in the left sac a rather stout transverse membrane pierced in the middle by a round hole. This approaches the structure of these sacs in other birds. In *Streptopelia* and *Platycolumba*, for instance, there are two such membranes dividing the cavity of the sac into three parts.

THE SACCI INTERMEDII POSTERIORES

According to Bertelli these sacs appear in the developing chick on the sixth day of incubation. They (figs. 11 and 12, SIP) arise in the right and left ostium intermedium posterius, and are, in the pigeon as in other birds, asymmetrical, the left sac reaching farther back and being larger than the right. But even the left sac is not so large as either of the sacci intermedii anteriores. The left saccus intermedius posterior extends beyond the last rib into the abdominal cavity; its abdominal portion occupies a narrow slit-like space lying against and partly covering the stomach. When the stomach is pressed against the external abdominal wall this part of the air-sac is undoubtedly compressed and the air driven out of it. The shorter right sac extends but little or not at all beyond the last rib. In a collapsed condition both sacs give the impression that they terminate with an apex attached to the last rib. Owen (1866, p. 212) and Baer (1900, p. 438) describe these sacs as pyramids with bases resting upon the posterior wall of the sac in front and with an apex extending to the pelvic cavity. I have never seen an apex of this sort in good preparations of the air-sacs of the pigeon. The position of these sacs and the way they are attached to the surrounding structures make it appear not improbable that they might assume such a shape when partly evacuated. The sacci intermedii posteriores are in contact with a small portion of the lungs and the wall of the thoraco-abdominal cavity, cover a part of the liver, the abdominal sac, and the intestine, and, on the left side, a part of the stomach. They are not connected with any other sac nor with any pneumatic bones. When the body cavity is opened, they do not completely collapse, because their walls are for the most part attached to the surrounding structures. In most other birds they have the same shape as in the pigeon. Sometimes, as in *Anas* and *Phasianus*, they are considerably larger, reaching in the latter species as far as the anus.

The Sacci Abdominales

Synonyms

Bertelli: Sacchi posteriori.

Campana: Réceptacles inférieurs.

Carus: Quartus magnus saccus æriferus.

Colas: Sac intestinal.

Fatio: Sacci renales et sacci abdominales propriæ dicti.

Gouillot: Réservoirs pneumatiques supérieurs, suprarénales de l'abdomen et abdominales inférieurs.

Huxley: Posterior air-sac.

Jacquemin: Poches pneumatiques sous-fémorales, abdominales et sacrées.

Merrem: Die beiden Bauchsäcke.

Owen: Cellulæ abdominales.

Sappey: Réservoirs abdominaux.

The sacci abdominales are the largest of all the air-sacs. They also appear in the embryo at a much earlier stage than the others. Bertelli says in regard to them (1900, p. 162): "Gli abbozzi dei sacchi posteriori sono i primi ad apparire. Alla settantaduesima ora di prossimità degli estremi caudali un leggerissimo rigonfiamento che è l'abbozzo dei sacchi posteriori, incluso nei legamenti pulmonali-epatici. Gli abbozzi dei sacchi posteriori et i sacchi posteriori sono accolti nei legamenti pulmonali-epatici, nel polmone, nel diaphragma, nelle pareti laterali dell' abdome dalle quali sollevandosi invadono la cavità abdominale."

The abdominal sacs enter the abdominal cavity dorsally and partly enclose the viscera. Their walls are extremely elastic and almost entirely free. They accordingly cling closely to the organs with which they come in contact, and give off numerous diverticula, which protrude into the spaces between the various viscera and between the latter and the outer wall of the abdomen. The shape and distension of the intestine are constantly changing; reciprocal changes must therefore constantly occur in the shape and distension of these air-sacs. Sexual distinctions and the production of eggs are responsible for reciprocal differences in the size and shape of these sacs in the male and female bird. The variations in the distension of the oviduct are particularly to be considered in this respect. In consequence of all these circumstances the casts of these sacs vary very much in different individuals when injected. In consequence of the asymmetry of the viscera the two abdominal sacs are very asymmetric, the right one (figs. 6, 11, and 12, SAD) being much larger than the left (figs. 11 and 12, SAS), the development of the latter being impeded by the stomach. The difference in relative size of the

right and left abdominal sacs is the reverse of that of the sacci intermedii posteriores. In the female, where only the left-hand one of the two oviducts is developed, the difference in size of the abdominal sacs is still greater than in the male.

The abdominal sacs occupy the space limited by the external borders of the posterior parts of the lungs, the sacci intermedii posteriores, the peritoneum, the ilium, the ischium, the pubis, the vena cava, the iliac arteries, the urogenital organs, the organs of the digestive tract, and the roof of the abdominal cavity. In life these sacs are usually only partially distended, more extensive, bladder-like air-spaces being found only at the sides of the cloaca. Everywhere else these sacs and their diverticula are in life narrow or altogether closed folds, containing hardly any air, or no air at all. In injected specimens these parts of the abdominal sacs are often distended beyond their normal size. In the illustrations accompanying this paper these sacs appear larger than they are, the narrow, curved, fold-like diverticula, of which they consist, naturally looking more like thick solid bodies than thin sheets.

The dorsal portion (roof) of the outer abdominal wall is in immediate contact with the abdominal sacs in only one place on each side. On examining the back of a skinned pigeon, one finds that, in the angular space between the pars renalis of the iliac bone and the musculus levator coccygis on either side, a portion of the wall of the abdominal sacs (fig. 6, SAD, SAS) is visible. At these points the sacs are covered by the skin alone, both muscles and bones being absent. In injected specimens the sacs bulge out considerably in these two places, and often form nearly hemispherical protrusions. These are, of course, mere artifacts produced by the abnormal injection-pressure. I might call the attention of physiologists to these portions of their walls, because with some precaution a canula can be introduced here into the system of the air-sacs without injuring the muscles or any other important parts.

The abdominal sacs are very differently arranged in different species of birds, and are, as Baer (1896, p. 40) has demonstrated in the cassowary, entirely absent in *Ratites*.

THE DIVERTICULA OF THE ABDOMINAL SACS

The abdominal sacs form several diverticula. These lie partly within, partly without the abdominal cavity. Many of the intra-abdominal ones, as, for example, the "duodenal cell" of Owen (1866, p. 212), are, as stated above, variable folds of the principal sac that have insinuated themselves between the viscera. There are,

however, besides these, constant processes more like the diverticula of other sacs. Such are the diverticula pelvica, in the vicinity of the lumbar vertebræ, and the diverticula inguinalia, surrounding the head of the femur. The former almost completely surround the kidneys, and extend laterally some distance beyond them. Two pair of processes arising from them enter the ilium and the sacrum, while others extend forward to a considerable distance. Occasionally some of the latter reach, as slender folds, as far as the neighborhood of the posterior border of the lungs. I have often seen a fold of this kind over the proventriculus. In fig. 11 this diverticulum is represented as not extending so far forward.

The inguinal diverticula appear to be quite constant in the pigeon. I will give a more detailed account of them because they have not been described by previous authors.

THE DIVERTICULA INGUINALIA

The inguinal diverticula surround the head of the femur and send slender processes in between the muscles of the thigh. From each of the two abdominal sacs a rather wide canal arises which passes out from the abdominal cavity at the acute, backwardly directed angle between the lateral edge of the præacetabular portion of the ilium (*pars glutæa*) and the *musculus ilio-femoralis internus*. This canal extends outside the abdominal cavity forming a little sac, the *diverticulum femorale anterius* (figs. 11 and 12, DFA), which overlies the *musculus femori-tibialis*. This diverticulum is usually connected with the abdominal sac not only by this canal, but also by another narrower tubule, the *canalis præacetabularis* (figs. 11 and 12, CPRA), which lies in front of the other, and runs along the lateral margin of the *pars glutæa ilii*. In one case this canal, which passes over the *musculus ilio-femoralis internus*, gave off an accessory dendritically ramified branch. This may have been a malformation. The diverticulum itself consists of several chambers freely communicating with each other, and occupies the space between the ilium, the *musculus ilio-femoralis internus*, the three united *musculi ilio-trochanterici anterior, posterior and medius*, the flat, tendon-like end of the *musculus ilio-femoralis externus*, and the head of the femur. One of these chambers, the *diverticulum femorale superius* (figs. 6, 11, and 12, DFS), is flattened, and extends between the *musculi pubo-ischio-femoralis, femoro-tibialis, ambiens, and ilio-tibialis internus*. Another diverticulum arising from the abdominal sac, the *diverticulum femorale posterius* (figs. 11 and 12, DFP), passes out through the *foramen ischiadicum*. This forms

three small chambers covered for the greater part by the musculus ilio-fibularis. This diverticulum femorale posterius and the diverticulum femorale anterius, described above, form the inguinal diverticulum of Owen. I have never observed the diverticulum that Baer describes (1896, p. 440) as passing out through the foramen obturatorium. As Baer also mentions nerves and vessels coming out through this foramen, it appears probable that there is here some confusion of nomenclature. Considering the lack of precision in much of the anatomical data concerning birds, such a confusion is likely enough to arise.

The inguinal diverticula surround the acetabulum on all sides, so that the head of the femur rests upon a ring of air-cushions. This arrangement doubtless increases the mobility of the femur and reduces the friction of the adjacent muscles.

The uppermost chamber of the inguinal system, the diverticulum femorale superius (figs. 6, 11 and 12, DFS), is covered only by the flat tendon of the musculus ilio-femoralis externus and the skin, so that its situation is similar to that of the superficial portion of the abdominal sac above mentioned (fig. 6, SAD, SAS). A penetration of this diverticulum, which is a branch of the præfemoral diverticulum, does not, however, give as satisfactory physiological results as a penetration of the wall of the abdominal sac, because the præfemoral diverticulum communicates with the other parts of the air-sac system only by very devious and narrow passages which are easily closed by the contraction of the contiguous muscles.

GENERAL CONSIDERATIONS CONCERNING THE AIR-SACS OF THE PIGEON THAT LIE BETWEEN THE SOFT PARTS.

While the air-sacs of the pigeon show a great diversity in detail and are in some regions subject to very considerable variations, they are, in their general features, constant enough to enable one to give an account of their typical form. I have not regarded in the foregoing descriptions the numerous pathological divergences from the normal type met with in the investigation. The pathological changes and other variations in size that affect the liver and other organs have a marked influence upon the air-sacs. The deposits of fat found so frequently about the pericardium and elsewhere, in spaces that would otherwise be occupied by air-sacs, also play an important part in this respect.

Subcutaneous air-spaces, such as occur in the pelican and some other birds, are entirely absent in the pigeon. I have, it is true,

often found the injected gelatine or paraffine under the skin of pigeons, but I found that in every such case the wall of an air-sac had been ruptured, and the mass had then effused. It may be possible that such injuries of the air-sac wall sometimes occur in the living animal without fatal result by the rupture of an extra-thoracic diverticulum. I twice found pneumatized bones which had been broken, and had healed.

THE PNEUMATICITY OF THE BONES

The air-sacs, their diverticula and outgrowths, send processes into many bones. These expand there by pushing aside the marrow, the bones thus becoming pneumatized. The sacci cervicales pneumatize the cervical and dorsal vertebræ and the ribs. The latter are sometimes also pneumatized directly from the bronchial branches of the lungs. The intrathoracic diverticula of the saccus interclavicularis pneumatize the sternum and the sterno-costal bones; its subscapular diverticula pneumatize the coracoids, the furculum, and the scapulæ, and its axillary diverticula pneumatize the humeri. The sacci intermedii anteriores and posteriores do not pneumatize any bones. The sacci abdominales pneumatize the bones of the pelvis and the lumbar and the sacral vertebræ.

All the bones of the neck and trunk, as well as the humeri, are pneumatized. All bones situated distally from the humerus in the anterior extremity and all the bones of the posterior extremity are filled with marrow and not pneumatized. The bones of the skull are partly pneumatized, not by the pulmonary air-sacs, but from the nasal air-spaces. All air-sacs that possess diverticula also pneumatize bones. The sacci intermedii anteriores and posteriores have no diverticula, and they alone pneumatize no bones.

The pneumatic bones are strikingly different from the medullated ones. Since they are free from marrow and fat, they are lighter in color and usually so transparent that their internal structure, the lamellæ and trabeculæ, can be seen through their walls. The walls of such bones are thinner, more compact, and more brittle than those of medullated bones, a part of the spongiosa and the innermost layer of the compact substance of the wall appearing to have been re-absorbed. The delicate membranous wall of the air-sac is applied immediately to the nearly smooth inner surfaces of the bone.

THE PNEUMATIC FORAMINA OF THE BONES

In each pneumatic bone there is found a pneumatic foramen through which an air-sac sends a process into the bone. The situa-

tion of the foramen is constant for each bone; its size and form are, however, variable. Strasser (1877, p. 192) was the first to consider the causes of that constancy and this variability. In mechanically unimportant places the osteoclasts destroy the bony substance and the osteoblasts do not produce any. Thus foramina are formed through which the outgrowths of the air-sacs enter. The pneumatic foramen is accordingly always found where the pressure, traction, and torsion are least, a place determined under normal conditions by the mechanical forces acting on each bone. The boundary of this area of least stress, where the foramen is formed, is naturally not sharply defined, and subsequently its margins are often partly covered with osseous substance. These factors determine the constancy of the location of these foramina and the variability of their shape and size. The foramen is either simply circular or oval in form, sometimes, however, through subsequent deposit of bone, divided into several smaller apertures and sieve-like. In the sternum there is always a large foramen at the bottom of the concavity of its upper side. Usually there are also other foramina on its upper surface on either side, less frequently on one side only, which form a row parallel to its lateral margin. The size of these foramina is very variable. Sometimes a third, median, row of foramina is found on the upper surface of the sternum. This shows that the occurrence of these rows of foramina is very variable, whilst the position where they occur when they are formed is always the same. These parts of the bony wall, being unimportant mechanically, are very thin when no foramina are present.

The principal pneumatic foramen of the scapula lies near its articular end; that of the coracoid on the inner surface of the canalis triosseus; that of the clavicle at the broad, spoon-shaped, scapular end; that of the humerus at the bottom of the deep depression on the anterior side of its basal portion; those of the ribs lie on their concave surfaces near the joints; those of the sterno-costalia on their concave surfaces near the sternal border; those of the pelvic bones on their ventral surface, usually above the kidneys; those of the cervical vertebræ on the surfaces turned towards the canalis intertransversarius and at other places, for example, on the distal end of the atlas; and those of the dorsal vertebræ in various places.

THE PNEUMATICITY OF BONES IN DIFFERENT BIRDS

The foramen is formed, and the air-sac enters it at a comparatively late period, when the development of the bone is already quite complete, so that the bones of very young birds are not pneumatic. In

the adult stage *Archæopteryx* and *Hesperornis* (Marsh) had no pneumatic bones at all, and *Apteryx*, the *Odontornithes*, and the New Zealand moa have only a few. The development of pneumaticity in bones appears in birds to have gone hand in hand with their phylogenetic development. Among recent birds the pneumaticity of bones is in general directly correlated with the power of flight and the size of the body. It is most highly developed in large birds of great flying power, such as the vultures, pelicans, swans, and albatrosses. Small birds, even when good fliers like the swift, usually have medullated bones. As there are obviously unknown factors influencing the pneumaticity, besides the known factors of size and flight-power, it is difficult to say beforehand to what degree the bones of any bird may be pneumatic. It is noteworthy that some large reptilian Sauropsida, such as the gigantic *Atlantosaurus*, *Brontosaurus*, etc., had pneumatized bones with air-cavities, while the bones of small reptiles are not pneumatic. This shows how important the size of the body is in this respect.

THE MINUTE STRUCTURE OF THE AIR-SACS

The thin membranes forming the walls of the air-sacs consist chiefly of connective tissue composed of long, coarse, slightly wavy fibrillæ, to which are added, in all the sac-walls with the exception of those in the pneumatic bones, spirally twisted elastic fibers (cf. *Leydig*, 1857, p. 376). The latter render the walls of the sacs in the soft parts of the body elastic, and almost equally extensible in every direction. In this connective-tissue membrane, the *membrana propria*, the blood-vessels of the sac-wall are situated. In the walls of the sacs that lie between the soft parts only few blood-vessels are found (*Strasser*, 1877, p. 205; *Baer*, 1896, p. 451). In the walls of the sacs situated in the bones there are, on the contrary, numerous blood-vessels and a rich capillary network. The respiratory interchange of gases is therefore much more marked in the walls of the sacs in bones than in those situated between the soft parts. All blood-vessels of the air-sac walls belong to the general circulatory system of the body, none to the pulmonary system. Of nerves only a few are observed in the air-sac walls.

Internally the sac-wall is lined with a single layer of epithelial cells. In the vicinity of the ostia this epithelium is high and ciliated; farther on it gradually changes to a low pavement epithelium without cilia. This arrangement of the epithelia in the air-sacs is well shown by the appearances observed in older city pigeons, where all

parts of the walls of the sacs, except those near the ostia, where the inhaled dust is ejected by the cilia, are strongly impregnated with soot. The condition of the atmosphere of Prague, in which lived the pigeons examined, is very favorable to the development of this phenomenon! By treatment with nitrate of silver the boundaries of the irregularly polygonal cells, of which the pavement epithelium of the distal portions of the air-sacs is composed, are easily demonstrated. According to Fourneux and Hermann (1876, p. 218), these cells are similar to those of the epithelium of the posterior portion of the lungs of snakes. A similar epithelium, composed, however, of somewhat larger cells, clothes the walls of the sacs within the cavities of the pneumatic bones. In some places there are found, between these cells, groups of smaller ones, the true nature of which is doubtful. Baer (1896, p. 450) regards them as growth-centers for the pavement epithelium, and believes that the larger cells are produced by a coalescence of such smaller ones.

Externally the *membrana propria* of the air-sac wall is covered, wherever it is free, by an endothelium whose cells are somewhat smaller than those of the inner epithelium. In this external endothelial layer lymph-stomata occur.

Contrary to the accounts given by Lereboullet (1838), Leydig (1857, p. 376), and Eberth (1863, p. 434), I have never been able to find muscles in the proper walls of the air-sacs of pigeons; at the places where these authors thought they saw them I failed to see anything but bundles or strands of elastic fibers. Such occur in the wall of the interclavicular sac near the furcula, in the wall of the cervical sacs (cf. Sappey, 1874, p. 38), and elsewhere. In this respect my results agree with Baer's (1896, p. 448).

A good résumé of the literature relating to the structure of the walls of the air-sacs is found in Oppel (1905, p. 333).

THE FUNCTION OF THE AIR-SACS

Much has been written on the function of the air-sacs and the advantages birds derive from their possession; that, however, which I hold to be their true nature and utility has either been overlooked altogether or far underrated in importance.

The most important hypotheses advanced concerning the function of the air-sacs are the following:

One hypothesis is that the air-sacs serve to erect the feathers. Since, however, this could only be effected by subcutaneous sacs, such as occur in the pelican, and since such sacs are wanting in

most birds, including the pigeon, this hypothesis certainly cannot be considered as satisfactory.

Many authors advocate the view that the air-sacs are resonatory organs for the purpose of increasing the strength of the voice. The similarity in the structure of the air-sacs in the sound-producing males and in the silent females shows the untenability of this view.

The hypothesis advanced by Cuvier (1810), Meckel (1821), Jacquemin (1842), Milne Edwards (1857), Owen (1866), and Magnus (1869), that the air-sacs are directly respiratory in function, has been refuted first by Sappey (1847, p. 48), and since by so many others, that we only need to refer to what we have mentioned above, viz., the slight development of the capillary system in the walls of the air-sacs, in order to demonstrate the incorrectness of this idea.

The statement made by Sappey (1846), Lendenfeld (1897), and other authors that the specific gravity of birds is reduced by the air-sacs contained in their bodies although opposed by Ficalbi (1884), P. Schulz (1896), Madarasz (1899), and to some degree likewise by Baer (1897), is of course incontrovertible. It is, however, questionable whether such a reduction of specific gravity, accompanied as it is by an increase of volume, can be of any use to the bird. It seems to me that this could not be of any advantage to sailing birds like the albatross, and that it would be directly disadvantageous to birds like the pigeon that move their wings rapidly. A reduction of the specific gravity obtained by inflating the body could only, it seems to me, be of use to those ancestors of birds that were accustomed to employ their wings as parachutes for effecting long jumps.

Campanas (1875), Pagenstecher (1878), Bignous (1889), and Soums (1896) consider the evaporation of water on their walls as the most important function of the air-sacs, and Madarász (1899) has suggested that the moist walls of the air-sacs may functionally replace the sweat-glands of mammals. Also Vescovi (1894) holds this opinion and considers the air-sacs as organs assisting in the regulation of the body temperature. I, for my part, do not believe that the air-sacs are a temperature-regulating apparatus, and agree with Baer (1894) in the doubts he expresses concerning this hypothesis. Considering the high body-temperature of birds, an extensive cooling apparatus is surely unnecessary.

Madarász (1899) thinks that the air-sacs of birds are analogous to the swimming bladders of fishes, and, like them, manometric sense-organs comparable to aneroids. That the air-sacs should be there to inform a bird of his height above sea-level seems to me, in view of their irregularity and great extent, highly improbable.

Hunter (1774) and Owen (1886, p. 217) have advanced the view that the air-sacs (when inflated) serve to fix the wings in the extended position. The latter says (l. c.) concerning this: "A fourth use of the air-receptacles relates to the mechanical assistance which they afford to the muscles of the wings. This was suggested by observing that an inflation of the air-cells in a gigantic crane (*Ciconia argala*) was followed by an extension of the wings, as the air found its way along the brachial and antibrachial cells. In large birds, therefore, which, like the Argala, hover with a sailing motion for a long-continued period in the upper regions of the air, the muscular exertion of keeping the wings outstretched will be lessened by the tendency of the distended air-cells to maintain that condition." To this I must remark that a soaring bird holds its wings horizontally without muscular effort, and hangs from them, so that a special apparatus for their fixation in this position is unnecessary.

Most recent authors consider the air-sac system as an apparatus serving as a mechanical adjunct to the respiratory system. This theory that they are bellows appears at first sight to have much in its favor. Even Harvey (1651), who was the first to carefully describe the air-sacs, entertained this opinion. This hypothesis was further developed by Perrault (1666), who pointed out that the respiratory changes in the volume of the thorax must cause a change of the air in the air-sacs. He thought these movements were of such a nature as to cause an antagonism between the sacci intermedii and the sacci abdominales. According to him the air passes from the sacci abdominales into the sacci intermedii during inspiration; and conversely, from the sacci intermedii to the sacci abdominales during expiration. Girardi (1784), and especially Sappey (1847) and Siefert (1896), have warmly supported this theory. Campana (1875) was also of this opinion, but he thought that extra-thoracic sacs (portions of sacs) were compressed by the circumjacent muscles. In 1816 Fuld disputed Perrault's theory of the alternate inflation of the air-sacs, and his views were supported by Roché (1891), Soum (1896), and others. Baer (1896, p. 477) concludes, from anatomical considerations and physiological experiments, that there is no antagonism of the kind suggested by Perrault in the movements (expansions) of the various groups of air-sacs, and he thinks it far more probable that all air-sacs are enlarged during inspiration, and, conversely, all contracted during expiration. I cannot wholly agree to this, as I do not believe that the cervical sacs and extra-thoracic diverticula of other sacs enlarge and contract during respiration at all. Baer, indeed, paid no attention to the extra-

thoracic air-spaces. This certainly was not justifiable, for, taking them altogether, especially if we include among them the non-dilatable air-spaces in the pneumatic bones, their volume is by no means insignificant. That the ventral wall of the body appears somewhat drawn inward during inspiration does not prove that there is a decrease of volume during this respiratory phase, but it shows, at least, that there can be no noticeable enlargement of the abdominal sacs during inspiration. In the *sacci intermedii* the increase of volume during inspiration is also in reality not so great as at first sight appears.

There is, of course, an increase in the size of the thoracic space during inspiration. This is effected by a movement of the sternum downward and forward, whereby the angles between the vertebral and sternal pieces of the ribs are increased. Thus the thoracic space gains in height. The increase of transverse dimensions that occurs at the same time is insignificant. Dorsally the lungs adhere to the ribs, and even extend between them. To the concave ventral surface of the lungs are attached the muscle of Perrault which contract during inspiration. By the enlargement of the thoracic cavity the atmospheric pressure in the thoracic air-sacs is reduced. These air-sacs are chiefly situated ventrally from the lungs. The difference between the (lower) pressure in these sacs and the (higher) pressure outside will indeed be diminished in amount during inspiration by the influx of air through the ostia into the sacs; yet on account of the smallness of the ostia some time must always elapse before the pressure within and without is completely equalized. Until this equalization is complete the air-sacs below the lungs, in which the pressure is low, and the muscles of Perrault must draw the ventral surface of the lungs downwards, thus effecting an expansion of the lungs. Baer himself has (1896, p. 476) pointed out that, in the first period of inspiration, there is a relatively very low air-pressure in the *sacci intermedii*. The consequence of this is that at that respiratory phase the ventral wall of the abdomen sinks in, notwithstanding the fact that it is very thick and muscular, and that it tends to become tense during inspiration and opposes a marked resistance to the depression. The thin wall of the pulmonary diaphragm certainly cannot withstand such a difference of pressure better than this external body wall; it must be pulled downward, and when the pulmonary diaphragm is thus depressed the lungs must necessarily expand. That no complete equalization occurs between the external and internal air pressure during inspiration is stated by Baer (1896, p. 478) in the following words: "Bevor noch der Spannungsunter-

schied zwischen der äusseren Atmosphäre und der Luft der Säcke sich gänzlich ausgeglichen hat, beginnt die expiratorische Verengung des Brustkorbes. . . .”

At the time of the expiratory contraction of the thorax there arises, conversely, an excess of pressure in the intra-thoracic air-sacs. They press against the lungs and compress them wherever they are in contact with them. If the thorax of a living animal is opened the assistance given by the varying pressure of the sacci intermedii ceases and the changes of volume, which are then induced by the muscles of Perrault only, are less than under normal conditions. This circumstance may well be the principal reason for the undue underrating of the respiratory lung movements by a great number of recent authors.

I will by no means deny that there occurs during respiration an exchange of air between the air-sacs and the outer atmosphere. But I fail to see how this can appreciably assist the pulmonary respiration. The expansion and contraction of the lungs is synchronous with that of the air-sacs. During inspiration all parts of these organs draw air out of the bronchi. During expiration the air-sacs do indeed eject some air into the bronchial branches, but this cannot reach the parabronchia, because the latter, during respiration, likewise contract and eject air. If the air thus ejected from the air-sacs does not pass through the parabronchia, it cannot enter the alveoli which branch off from them, and in which the blood oxidation takes place (cf. Siefert, 1896, p. 476; and Lendenfeld, 1896, p. 776). The structure of the lungs, which has been described above, precludes the possibility of this air passing through the parabronchia by following the few narrow communications that exist here and there. But even if it were so, such an arrangement could hardly aid in the respiratory function. Let us suppose that during inspiration the lungs and air-sacs are filled with fresh air. The air which reaches the lungs would there give off a portion of its oxygen; that in the air-sacs would not. During expiration the air from the lungs would be driven out through the bronchi into the trachea, and the air from the sacs would pass into the lungs. There the latter air would be deprived of a portion of its oxygen. During the next inspiration this air (poor in oxygen) would again pass from the lungs into the air-sacs. During the next expiration the same air would then again fill the lungs, and these would thus always contain air poor in oxygen, and therefore ill adapted for respiratory purposes.

There is also a second important circumstance in relation to this subject that appears to have hitherto been overlooked. In birds we

find the trachea relatively much larger and the lungs relatively much smaller, richer in capillaries, and heavier than in mammals. Consequently the volume of air contained in the lungs of birds is relatively much smaller than the volume of air contained in the lungs of mammals. Even during the most powerful expiration only a part of this small allowance of air is renewed by respiration, a considerable portion remaining in the lungs as "residual" air. The amount of air that is really expelled from the lungs would hardly suffice to fill the very spacious trachea, on which account a large portion of the air during respiration would only flow backward and forward between the lungs and trachea, if this were not prevented by special arrangements. Without such special arrangements oxygen would be supplied to the respired air only by the slight mixing of tracheal with external air at the nostrils, and a proper oxidation of the blood would be impossible.

In consequence of the change in volume of the air-sacs during respiration the body of air moved is much greater, and thus the above-mentioned disadvantage to breathing, that would otherwise result from the great extent of the trachea is averted. The air that leaves the air-sacs during expiration passes the ectobronchial branches, and, together with the air that comes from the alveoli of the lungs, enters the trachea, and is in great part expelled through the nostrils. An equally large volume is thereupon again inhaled. This is then, together with the air remaining in the trachea, distributed among the air-sacs and the lungs. In this way, indirectly, and in no other way, the air-sacs assist in respiration.

The width of the trachea diminishes the air-friction, and thus economizes the labor of breathing, which, in view of the considerable length of that organ, is of considerable importance. The length of the trachea is determined by the length of the neck, and the latter affords advantages of quite another sort. The length of the neck in the flying Sauropsida, selectively acquired for other purposes, was one of the causes of the development of the air-sac system, through which its disadvantages in respect to respiration were compensated.

The extra-thoracic air-sacs occupy interstices between the muscles and other parts of the locomotory apparatus. According to Strasser, this is an advantage, because in consequence there is "geringere Kraft an innerer Arbeit verloren" (1877, p. 205); and (Strasser, 1877, p. 206) there is a "Gewinn an Grösse des Bewegungshebels und an Bewegungsleistung ohne entsprechende Vermehrung der Muskulatur und der übrigen Organsysteme;" as well as (Strasser, 1877, p. 207) "eine Vermehrung der Leistung, durch eine Ver-

schiebung der Muskeleinheiten nach der Seite der günstigeren Wirkung hin." I not only share these views of Strasser concerning the extra-thoracic air-sacs, but believe that the intra-thoracic air-sacs also serve such a mechanical purpose. The mechanical advantages which the intra-thoracic air-sacs render are: 1st, an increase in the size of the thorax without an increase in weight; and, 2d, an increase in the freedom of movement of the organs contained in it, especially of the heart.

The advantage of an increase in size of the thorax without increase of weight is clear enough. The strength of hollow cylinders differing from each other in diameter only is proportional to their transverse diameter. The same is the case with other similarly shaped bodies not exactly cylindrical in shape. By the coalescence of the dorsal vertebræ, the paratangential extension and coalescence of the bones of the pelvis, the clenching of the ribs by means of the uncinæ processes, the development of the sterno-costal bones, and finally by the special structure of the sternum and coracoid, the support of the wall of the thorax of the bird has attained the shape of such a hollow cylinder. The above-mentioned mechanical law therefore also applies to it. The same laws of structure which, as Schwendener found everywhere governing the structure of the elastic portions of plants, and which likewise invariably regulate the structure of the bones in animals, control the configuration of the avian thorax, where they find an expression in the development of the intra-thoracic air-spaces. The same law also affects the organization of flying insects, especially those which are good fliers, for such insects also possess air-sacs. It even applies to the flying fish, which have very much larger swimming bladders than other fishes. That this extension of the thorax, without increase of weight, by means of the interpolation of air-spaces, which occurs in such widely separated animal groups, essentially increases the mechanical aptitude for flight cannot be doubted by any one acquainted with the laws of mechanics.

There is yet another circumstance greatly in favor of the view that the function and *raison d'être* of the air-sacs are mechanical and not respiratory. This circumstance is their asymmetry, which, strangely enough, has not been noticed in this connection by any previous author. Baer, whom we must regard as the principal exponent of the respiratory bellows-theory of the air-sacs, has worked out a scheme, based on exhaustive studies and experiments, on the enlargement of the body-cavity of birds during respiration, which gives a clear and accurate account of the respiratory mechanism. This

scheme shows that the enlargement is greatest at the posterior end of the thorax, and decreases anteriorly. The abdominal sacs must, therefore, take in the most air, the sacci intermedii posteriores less, the sacci intermedii anteriores still less, and the saccus interclavicularis least of all. As the external wall of the thorax, the respiratory muscles, and the lungs are all symmetrical, we would, if the air-sacs were merely accessory bellows for the lungs, also expect that each pair of sacs would be symmetrical. And this symmetry should be most clearly pronounced in the largest of all the sacs—that is, the abdominal ones—because, as above mentioned, these sacs are the ones which change their volume most during respiration. In fact, however, this pair of sacs is altogether asymmetrical and dissimilar in size. It is true that the sacci intermedii posteriores are, like the sacci abdominales, asymmetrical, and dissimilar in size in a reverse sense, but their capacity is so small when compared with that of the abdominal sacs that they do not by any means compensate the disturbance occasioned by the asymmetry of the latter. The power necessary to work a small air-sac efficiently as a bellows is very different from that required to work a large one. The asymmetry of the abdominal sacs would, therefore, if they really were, as Baer believes, bellows, make it necessary that the muscles compressing them should also be asymmetrical, which is not the case. The sacci intermedii anteriores and posteriores often consist of two parts, one of which is frequently connected with the other by means of a small opening, but often not directly connected with the lung at all. The complete separation of this air-space from the lung can only have been produced by a secondary closing of the original opening. Such a secondary closing would certainly not have occurred if this space were a bellows employed for breathing. Sometimes, through this bipartite division, the air-sac proper is greatly reduced in dimensions, often by half its size: another asymmetry. Besides, it may be remarked, that the two ostia forming a pair, especially those of the interclavicular sac, are often asymetrically placed.

All this appears in a very different light if we consider the thoracic air-sacs as structures selectively developed for the purpose of increasing the size of the thorax without increasing its weight and facilitating the movements of the organs in the thorax, chiefly the heart. Then it becomes evident that the shape of the air-sacs is of no importance, and that their asymmetry is simply caused by the asymmetry of the spaces they have to occupy between the asymmetrical viscera.

The increase of mobility of the internal organs, especially the heart, due to the air-sacs, is of especial importance on account of the rigidity of the wall of the thorax. Since in birds the pericardium and the amount of pericardial fluid contained in it are small, the heart, if there were no air-sacs around it, could hardly move at all. In birds the heart is relatively much larger, and beats with greater energy and rapidity than in mammals. This energetic heart-movement is necessary for the production of the power required for flight, and it is made possible by the diverticula of the saccus interclavicularis which surround it. The movements of the gizzard, the peristaltic action of the intestine and the oviduct are also made easier by the portions of air-sacs that surround these parts. The pneumaticity reduces the friction to a minimum, whereby a considerable economy of labor is effected.

Merrem and Perrault suggested that the alternation of positive and negative pressure in the air-sacs may help to mix the contents of the intestines, and so assist digestion. I cannot share this view.

Sappey (1846) considered the air-sac system as an apparatus for equilibration. I do not think, however, that they can act as such, for Lendenfeld has shown (1897) that the shifting of the center of gravity occasioned by the alternate filling and emptying of the sacs cannot be great. A balancing of the body during flight by the filling of single air-sacs seems to me neither useful nor possible. Slight alterations in the position of the head or the extremities are in this respect much more effective than a shifting of the internal organs, the former parts being so much farther away from the center of gravity than the latter.

Hunter (1774) thought that the air-spaces in the bones acted as air-reservoirs, and recently Grober (1899) and Madarász (1899) have propounded the view that the storing up of air that may be required for respiration during flight forms a special function of the air-sacs. Baer entertains a similar opinion. He believes that the bird breathes very differently during flight than when at rest, and that the whole air-sac system, the complete aëration of which, during repose, he has sought to prove both theoretically and experimentally, acts during the most strenuous corporeal efforts of the bird when flying merely as an air-reservoir. He says (1896, p. 487): "Nach allen diesen Erwägungen komme ich zu dem Schlusse, dass die Durchlüftung des Atemapparates während des Fluges in ganz anderer Weise erfolgen muss, als in der Ruhe oder bei der Bewegung auf festem Boden und es darf füglich angenommen werden, dass besondere Atembewegungen neben den Flügelbewegungen nicht

ausgeführt werden." Among these "Erwägungen" there is first of all the assertion (p. 486) that in man every great effort of the anterior extremity is accompanied by a more or less complete immobility of the thorax. This is indeed the case in movements occupying only a short time, as in lifting a weight (one of the examples mentioned by Baer), but not in movements of longer duration. A trained gymnast breathes during the most difficult exercise if it lasts long, only he so chooses the moment for making the respiratory movements that he thereby suffers no loss of power. An untrained gymnast, it is true, does not readily select such a moment, and therefore does not trust himself to breathe, and consequently is unable to endure so long a muscular strain. Why should we not assume that the flying bird has the ability of a good gymnast? A flying skylark by no means sings in the time of its wing-beats. These are rapid—about eight in a second—so that one can hardly see the moving wings. Nevertheless the sky-lark produces, during its flight, long-drawn and quite continuous notes, which in their perfectly constant intensity, show no trace of being composed of numerous short notes corresponding to the intervals between the wing-beats. Such would be the case, however, if the view of Baer, given above, which is shared by Campana and Strasser, were correct. But there is also another consideration which makes that opinion untenable. The only direct influence on the lungs and the air-sac system of the wing-movement during flight is the alternation of pressure exerted on the air-sac diverticula lying above and below the shoulder-joint. Every time the wings are raised the former, every time the wings are lowered the latter are compressed. As, however, both are diverticula of one and the same sac, this alternating compression of them caused by the wing-movement cannot produce any considerable air-current passing through the lungs. The air of the sac in question, the *saccus interclavicularis*, is merely agitated to and fro by this means. In this connection it must not be forgotten that, as Lendenfeld (1896, p. 777) has stated, the birds of great wing-power which possess the largest axillary and subpectoral diverticula are for the most part sailing fliers which often continue their flight for many minutes, even for half an hour and longer (Darwin, condor), without flapping their wings, so that in these even that slight air-movement in the air-sac system is interrupted for considerable spaces of time.

We will now consider the question of the utility afforded by the pneumaticity of the bones. It has been mentioned above that the walls of the air-sacs within the bones are very rich in blood-vessels,

and consequently absorb oxygen and give off carbonic acid gas. Even if there were a marked difference of air-pressure at the times of inspiration and expiration in these spaces, the renewal of the air in them could only be effected very gradually on account of the unyielding character of their walls. The carbonic acid gas has, therefore, much time to collect in these spaces, and yet but little such gas can be demonstrated there. This shows how slight the blood oxidation is in pneumatic bones, and, further, that the function of the air-spaces in these bones cannot be a respiratory one.

Sappey (1846) remarked in this connection that the penetration of processes from air-sacs into bones enlarges their sectional area, and thereby increases their power of resistance without increasing their weight. Bergmann and Leuckart (1852, p. 235) ascribe a great significance to the reduction of specific gravity imparted to the skeleton by the pneumaticity of bones. Strasser (1877, p. 223) has treated this subject most thoroughly, and has succeeded in showing in the clearest manner that the utility of the pneumaticity of bones is purely a mechanical one. Most recent authors have accepted this interpretation; only P. Schulz (1896) holds a somewhat different view. Taking into consideration those birds of good flight, which, like the terns, possess no pneumatized bones, he thinks that the mechanical advantages of the pneumaticity cannot be so great as is assumed by many authors.

CONCLUSIONS

I do not consider the air-sacs, including the air-cavities of bones, as organs having a positive and special function, but rather as a system of empty interspaces. Their value lies in their emptiness—that is, in their containing nothing that offers resistance or has an appreciable weight.

Flying is the highest form of locomotion, and as such only possible to a body of high mechanical efficiency. Our most effective machines are by no means compact and solid, but composed of parts as strong as possible in themselves and arranged in the most appropriate manner. The interspaces between the parts are left empty and taken up by air.

The Sauropsida, at the time they obtained the power of flight, became adapted to its mechanical requirements, and thereby similar to the efficient machines mentioned above; they divested themselves of all superfluous material, filling the body-spaces thus obtained with air-sacs. While the body-wall, adapting itself to the mechanical requirement, became a compact, hollow cylinder serving as a support

for the organs of movement, the mobility of the parts was assured by surrounding them with air-sacs.

The lengthening of the neck, produced by quite a different adaptation, made necessary an increase in the quantity of air moved during respiration. This demand was met by air-currents generated through a rhythmical change in the volume of the air-sacs. The connection of the air-sacs with the lungs is a consequence of their phylogenetic development, which is repeated in their embryological development, and has no physiological significance other than that the air-sacs assist in renewing the air in the trachea.

BIBLIOGRAPHICAL REFERENCES

- ALBERS, JOHANN A.
1802. Versuch über das Atemholen der Vögel. In: Beitr. Anat. Physiol. der Tiere, Bremen. Vol. 1, p. 107.
- ALLEN, WILLIAM, and W. H. PEPYS.
1829. On the Respiration of Birds. In: Phil. Trans. R. Soc. London for 1829, p. 207.
- BAER, MAX.
1896. Beiträge zur Kenntnis der Anatomie und Physiologie der Atemwerkzeuge bei den Vögeln. In: Zeitschr. wiss. Zoöl. Vol. 61, p. 420.
1896a. Die Atmung der Vögel. In: Ver. vaterl. Naturk. Württemberg. Vol. 52.
1897. Zur physiologischen Bedeutung der Luftsäcke bei Vögeln. In: Biolog. Centralbl. Vol. 17, p. 282.
- BARTHOLINUS, CASP.
1676. Nova diaphragmatis structura. In: Bibl. anat. Mangetti. Vol. 1, p. 29.
- BEDDARD, FRANK E.
1884. Contribution to the anatomy of *Scopus umbretta*. In: Proc. Zoöl. Soc. London for 1884, p. 543.
1886. Notes on the air-sacs of the Cassowary. In: Proc. Zoöl. Soc. London for 1886, p. 145.
1886a. On some points in the anatomy of *Chauna chavaria*. In: Proc. Zoöl. Soc. Lond. for 1886, p. 178.
1898. The structure and classification of Birds.
- BERGMANN und LEUCKART.
1855. Anatomisch-physiologische Uebersicht des Tierreiches.
- BERT, PAUL.
1870. Leçon sur la physiologie comparée de la respiration.
1874. Recherches expérimentales sur l'influence que les modification dans la pression barometrique exercent sur les phenomènes de la vie. In: Ann. sci. nat., Ser. 5, Vol. 20.
- BERTELLI, D.
1898. Contributo alla morfologia ed allo sviluppo del diaframma ornitico. In: Monit. zool. ital. (1898).
1900. Sviluppo dei sacchi aeriferi del pollo. In: Mem. Soc. Toscana. Vol. 18.
- BIELETZKY, N.
1878. Resultate der Messungen der Atemhöhlen der Ente.
- BIGNON, F.
1888. Recherches sur les cellules aériennes cervico-céphaliques chez les Psitacidées. In: Bull. Soc. Zoöl. France, Vol. 13, p. 180
1888a. Recherches sur les rapports du système pneumatique de la tête des oiseaux avec le système dépendant de l'appareil pulmonaire. In: Comptes Rendus Soc. Biol. Paris, Ser. 8, Vol. 5, p. 357.
1889. Note sur les réservoirs aériens de l'Urubu. In: Comptes Rendus Soc. Biol. Paris, Ser. 9, Vol. 1, p. 39.

BIGNON, F.

1889a. Note sur les réservoirs aériens de *Sula bassana*. In: Comptes Rendus Soc. Biol. Paris, Ser. 9, Vol. 1, p. 90.

1889b. Pneumaticité chez les oiseaux.

1889c. Les cellules aériennes cervico-cephaliques des oiseaux et leurs rapports avec les os de la tête. In: Mem. Soc. Zoöl. France, Vol. 2, p. 260.

BILLARD, G., und M. CAVALIÉ.

1898. Sur les fonctions des branches diaphragmatiques des nerfs intercostaux. In: Comptes Rendus Soc. Zoöl. Paris, Ser. 10, Vol. 5, p. 306.

BLUMSTEIN, J.

1905. Die Pneumatisation des Markes der Vogelknochen. In: Anat. Hefte Merkel und Bonnet. Vol. 29.

BOULART, H.

1882. Note sur un système particulière des sacs aériens observé chez quelques oiseaux. In: Journ. Anat. Physiol. Vol. 18, p. 467.

1885. Note sur les sacs aériens cervicaux du Tantale. In: Bull. Soc. Zoöl. France. Vol. 10, p. 348.

BUTLER, G. W.

1889. On the subdivision of the body-cavity in Lizards, Crocodiles and Birds. In: Proc. Zoöl. Soc. London for 1889.

CADIAT.

1878. Du développement de la portion céphalothoracique de l'embryon, de la formation du diaphragme, des plèvres, du péricarde, du pharynx et de l'œsophage. In: Journ. Anat. Physiol. (1898), Paris.

CAMPANA.

1875. Physiologie de la respiration chez les oiseaux. Anatomie de l'appareil pneumatique-pulmonaire, des faux diaphragmes, des sereuses et de l'intestin chez le poulet.

CAMPER, P.

1776. Mémoire sur la structure des os dans les oiseaux. In: Mém. Acad. Paris, Vol. 7, p. 328.

CARUS.

1826-1852. *Tabulæ anatomix comparatæ*.

CAZIN, M.

1885. Observations sur l'anatomie du Pérel géant. In: Bibl. de l'Écol. Sci. nat. Vol. 31.

COITER, V.

1573. De avium aspera arteria, pulmonibus.

COLAS.

1825. Essai sur l'organisation du poumon des oiseaux. In: Journ. Dict. Ser. méd. Vol. 23, p. 97.

COLIN.

1873. *Traité de Physiologie comparée*. Vol. 2.

COUVREUX.

1892. Sur le pneumatique des oiseaux. In: Ann. Université Lyon. Vol. 2.

CUVIER, G.

1803. *Anatomie comparée*. Vol. 4.

- DESLONGCHAMPS, E.
Sur les poches aériennes sous-cutanées du Fou de Basson. In: Mém. Soc. Normandie, Ser. 2, Vol. 8.
- DROISIER, W. H.
1866. On the function of air-cells and the mechanism of respiration in Birds. In: Ann. Mag. Nat. Hist. Ser. 3, Vol. 17, p. 313.
- DUVAL, M.
1896. Études sur l'embryologie des Cheiroptères. In: Journ. Anat. Physiol. Paris. Vol. 32, p. 104-420.
1897. Précis d'histologie.
- EBERTH, C. J.
1863. Ueber den feineren Bau der Lunge. Zeitschr. wiss. Zoöl. Vol. 12, p. 450.
- FATIO.
1860. De avium corpore pneumatica.
- FICALBI, E.
1884. Alcune ricerche sulla struttura istologica delle sacche aerifere degli uccelli. In: Atti Soc. Toscana, Vol. 8.
- FILHOL, H.
1885. Observations anatomiques relatives à diverses espèces de Manchots. In: Comptes Rendus Acad. Paris (1885).
- FRIEDRICH HOHENSTAUFEN.
1596. Frederici imperatoris reliqua librorum, de arte venanti cum avibus. (Herausgegeben 1788 von Schneider).
- FULD, LEHMANN.
1816. Dissertatio de organis, quibus aves spiritum ducunt.
- GADOW, H.
1890. Description of the modifications of certain organs, which seem to be illustrations of the inheritance of acquired characters in Mammals and Birds. In: Zoöl. Jahrb. Syst. Vol. 5, p. 629.
1891. Vögel. In: Bronn's Klass. Ord. Tierreich. Vol. 6.
- GARROD, A. H.
1872. On the mechanism of the gizzard in Birds. In: Proc. Zoöl. Soc. London for 1872, p. 525.
- GIRARDI, M.
1784. Saggio di osservazioni anatomiche intorno agli organi della espirazioni degli uccelli. In: Mem. Soc. Ital., Verona. Vol. 2.
- GOEPPERT, E.
1902. Die Entwicklung des Mundes und der Mundhöhle mit Drüsen und Zunge, die Entwicklung der Schwimmblase, der Lunge und des Kehlkopfes bei den Wirbeltieren. In: O. Hertwig's Handbuch der Entwicklungslehre der Wirbeltiere. Vols. 6-8.
- GROBER, JUL. A.
1899. Ueber die Atmungsinnervation der Vögel. In: Arch. Physiol. Pflüger, Vol. 76, p. 427.
- GUILLOT, N.
1846. Mémoire sur l'appareil de la respiration des oiseaux. In: Ann. Sc. nat. Ser. 3, Vol. 5, p. 25.
- HARVEY, W.
1651. Exercitatio 3. In: Exercitationes de Generatione animalium.

HEADLEY, F. W.

1893. The Respiration of Birds. In: Nat. Science. Vol. 3, p. 28.

1893a. The air-sacs and hollow bones of Birds. In: Nat. Science, Vol. 3, p. 346.

HUNTER, J.

1774. An account of certain receptacles of air in birds. In: Phil. Trans. R. Soc. London (1774), p. 205.

HUXLEY, T.

1882. On the respiratory organs of Apteryx. In: Proc. Zoöl. Soc. London for 1882.

JACQUEMIN, E.

1842. Mémoire sur la pneumatibilité du squelette des oiseaux. In: Nova Acta Acad. Leop. Vol. 19, p. 283.

KOHLRAUSCH.

1832. De avium saccorum aeriorum utilitate.

LENDENFELD, R. v.

1896. Die physiologische Bedeutung der Lufträume bei den fliegenden Tieren. In: Biol. Zentrbl. Vol. 16, p. 774.

1897. Zur physiologischen Bedeutung der Luftsäcke. In: Biol. Zentrbl. Vol. 17, p. 439.

LEREBoullet, AUG.

1838. Anatomie comparée de l'appareil respiratoire dans les animaux vertébrés.

LEYDIG, F.

1857. Lehrbuch der Histologie des Menschen und der Tiere.

LOUGET, F. A.

1859. Traité de physiologie. ed. 2.

LUCAS, F. A.

1894. Note on the air-sacs and hollow bones of Birds. In: Nat. Science. Vol. 5, p. 36.

MADARÁSZ, J. v.

1899. Die Pneumatizität der Vögel und ihre Rolle beim Ziehen. In: Ornith. Monatsber. Vol. 7, u. 160.

MAGNUS.

1868. Physiologisch-anatomische Studien über das Brustbein der Vögel. In: Arch. Anat. Physiol. (1868), p. 628.

1869. Physiologisch-anatomische Studien über die Brust- und Bauchmuskeln der Vögel. In: Arch. Anat. Physiol. (1869), p. 207.

MALASCARNE, V.

1788. Conferme delle osservazione anatomiche intorno agli organi della respirazione degli uccelli. In: Mem. Soc. Ital. Verona. Vol. 4.

MALM, A. W.

1880. Om Luftröhr-säcken hos Dromaeus. In: Nov. Hollandiae Ak. Förhandl. Vol. 37, p. 33.

MAREY, E. J.

1873. La machine animale.

MECKEL.

1821-1833. Vergleichende Anatomie. Vol. 6.

MERREM, BLAS.

1783. Ueber Luftwerkzeuge der Vögel.

MILANI.

1894. Beiträge zur Kenntnis der Reptilienlunge. In: Zoöl. Jahrb. Anat. Vol. 7.
 1897. Beiträge zur Kenntnis der Reptilienlunge. In: Zoöl. Jahrb. Anat. Vol. 10.

MILNE EDWARDS.

1857. Leçons de la physiologie comparée. Vol. 2.
 1865. Observations sur l'appareil respiratoire de quelques oiseaux. In: Ann. Sci. Nat. Ser. 5, Vol. 3, p. 137.
 1867. Note additionelle sur l'appareil respiratoire. In: Ann. Sci. Nat. Ser. 5, Vol. 7.
 1884. Sur les sacs respiratoires de Calao rhinoceros. In: Comptes Rendus. Ac. Sci. Paris. Vol. 99, p. 833.

NITSCH, CH. L.

1808. Commentationes de respiratione animalium.
 1811. Osteographische Beiträge zur Naturgeschichte der Vögel.
 1826. Ueber die Pneumatizität und einige andere Merkwürdigkeiten des Skelettes der Kalaos. Meckel's Arch. (1826), p. 618.

OPPEL, A.

1905. Atemapparat. In: Opperl, Lehrbuch der vergleichenden, mikroskopischen Anatomie der Wirbeltiere. Vol. 6, p. 312.

OWEN, R.

1830. On the Anatomy of the Gannet (*Sula bassana*). In: Proc. Zoöl. Soc. London for 1830, p. 90.
 1835. Notes on the anatomy of *Pelecanus rufescens*. In: Proc. Zoöl. Soc. London for 1835.
 1835. On the anatomy of the Concave Hornbill (*Buceros cavatus*). In: Trans. Zoöl. Soc. London, Vol. 1, p. 117.
 1836. Aves. In: Todd's Cyclop. Anat. and Physiol. Vol. 1.
 1841. On the anatomy of the Southern Apteryx. In: Trans. Zoöl. Soc. London. Vol. 2.
 1844. Memoir on the Apteryx australis. In: Trans. Zoöl. Soc. London, Vol. 2.
 1866. On the anatomy of vertebrates. Vol. 2.

PAGENSTECHEK.

1878. Allgemeine Zoölogie, Teil 3.

PALLISCH, C.

1885. Luftgeschwülste bei Vögeln. In: Zoöl. Garten. Vol. 26, p. 87.

PARKER, W. K.

1866. On the Osteology of gallinaceous birds and Tinamous. In: Trans. Zoöl. Soc. London. Vol. 5, p. 149.
 1883. Note on the respiratory organs of Rhea. In: Proc. Zoöl. Soc. for 1883, p. 141.

PETERS, W.

1866. Ueber den Kehlsack des Marabustorches. In: Monatsber. Akad. Berlin (1866), p. 168.

PHILOMATINSKY.

1833. De avium respiratione.

PLATEAU, F.

1880. Procédé pour la preparation et l'étude des sacs aérieux des oiseaux.
In: Zoöl. Anz. Vol. 3, p. 286.

PRECHTL, T.

1846. Untersuchungen über den Flug der Vögel.

RAINEY, G.

1849. On the minute anatomy of the lung of the bird. In: Med. chirurg.
Trans. Vol. 32, p. 47.

RATHKE, H.

1828. Ueber die Entwicklung der Atemwerkzeuge bei den Vögeln und
Säugetieren. In: Nov. Act. Acad. Leop. Vol. 14, p. 159.

RETZIUS, A.

1831. Några ord om Fogellungornas verkliga byggnad. In: Vet. Akad
Hdlgr. Stockholm (1831), p. 159.

ROCHÉ, G.

1890. Appareil aërifère des Rallidées. In: Bull. Soc. philom. Paris.
Ser. 8, Vol. 2, p. 107.

- 1890a. Note sur l'appareil aërifère des oiseaux. In: Bull. Soc. philom.
Paris. Ser. 8, Vol. 2, p. 131.

1891. Contribution à l'étude de l'anatomie comparée des réservoirs aériens
d'origine pulmonaire chez les oiseaux. In: Ann. sci. nat. Ser. 7,
Vol. 11, p. 1 and 65.

ROSS, M. J.

1899. Special structural Features in the air-sacs of Birds. In: Trans.
Amer. Micr. Soc. Vol. 20, p. 29.

ROUGET, C. H.

1851. Le diaphragme chez les mammifères, les oiseaux et les reptiles. In:
Bull. Soc. Biol. Paris. Vol. 3.

SAPPEY, PH. C.

1847. Recherches sur l'appareil respiratoire des oiseaux.

SCHMIDT, M.

1885. Luftgeschwülste bei Vögeln. In: Zoöl. Garten. Vol. 25, p. 321.

SCHNEIDER.

1804. Vermischte Abhandlungen, Berlin, p. 137.

SCHROEDER.

1860. Ueber die Struktur der Vogellunge. In: Arch. holländ. Beitr.
Natur. u. Heilkunde. (1860), p. 92.

SCHULZE, F. E.

1871. Die Lungen. In: Stricker, Handbuch der Lehre von den Geweben
des Menschen u. der Tiere.

SELENKA, E.

1866. Beitrag zur Entwicklungsgeschichte des Huhnes. In: Zeitschr. wiss..
Zoöl. Vol. 16, p. 178.

SIBSON.

1846. On the mechanism of respiration. In: Phil. Trans. R. S. London.
(1846), p. 501.

SICARD, H.

1869. Des organs de la respiration dans la série animale.

SIEFERT, E.

1896. Ueber die Atmung der Reptilien und Vögel. In: Arch. ges. Physiol. Vol. 64.

SOUH, J. M.

1896. Recherches physiologiques sur l'appareil respiratoire des oiseaux. In: Ann. Univ. Lyon (1896).

STRASSER, H.

1877. Ueber die Luftsäcke der Vögel. In: Morphol Jahrb. Vol. 3.
 1878. Zur Mechanik des Fluges. In: Archiv. Anat. Physiol. (Anat.) (1878), p. 119.
 1885. Ueber den Flug der Vögel. Ein Beitrag zur Erkenntnis der mechanischen und biologischen Probleme der activen Locomotion. In: Jenaische Zeitschr. Vol. 19, pp. 174 und 330.

TIEDEMANN, F.

1810. Anatomie und Naturgeschichte der Vögel.

TOURNEUX, F., et HERRMANN, G.

1876. Recherches sur quelques épithéliums plats dans la série animale. In: Journ. Anat. Physiol. Paris. (1876.)

ULRICH, F.

1904. Zur Kenntnis der Luftsäcke bei *Diomedea exulans* und *Diomedea fuliginosa*. In: Ergeb. deutsch Tiefsee exped. "Vladivostok." Vol. 7, p. 318.

VESCOVI, DE.

1894. De novo interpretandi modo functionem aeriferarum vesicularum in avibus existentium. In: Zoöl. Res. Rom. Vol. 1, p. 24.

VICQ-D'AZYR.

1772. Premier mémoire pour servir à l'Anatomie des oiseaux. In: Mém. Acad. Paris (1772), p. 617.
 1773. Deuxième mémoire pour servir à l'Anatomie des oiseaux. In: Mém. Acad. Paris (1773), p. 570

VROLIK.

1803. Comper's u. Hunter's Gedanken über den Nutzen der Röhrenknochen bei Vögeln. In: Reil's Archiv. Vol. 7, p. 468.

WEBER, E.

1842. Ueber den Bau der Lungen bei den Vögeln. Bericht 19. Vers. deutscher Naturf. u. Aezte.

WIEDERSHEIM, R.

1898. Lehrbuch der vergleichenden Anatomie der Wirbeltiere.

WILDERMUTH.

1877. Der feinere Bau der lufthaltigen Vögelknochen, nebst Beiträgen zur Kenntnis ihrer Entwicklung. In: Jenaische Zeitschr. Vol. 11, p. 537.

ZUMSTEIN, J. J.

1892. Ueber Korrosionspräparate. In: Sitzber. Ges. Marburg für 1891, p. 27.
 1900. Ueber den Bronchialbaum der Säuger und Vögel. In: Sitzber. Ges. Marburg für 1900, p. 39.

EXPLANATION OF THE FIGURES

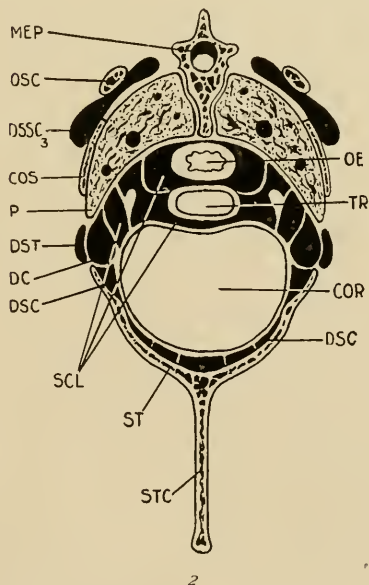
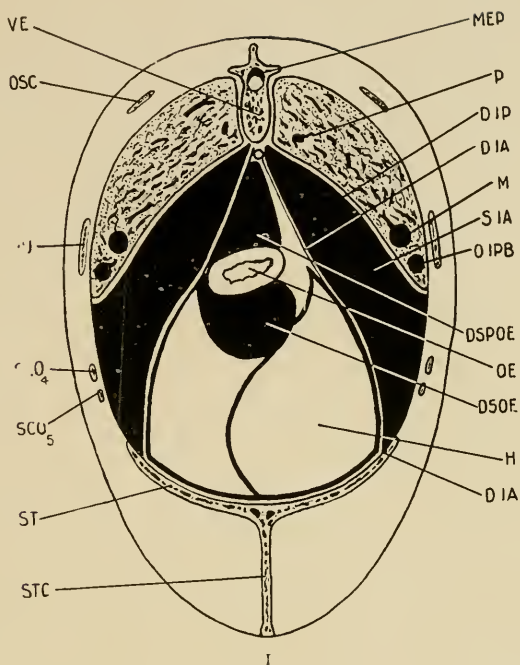
(PLATES XLV-XLIX)

- FIG. 1. Transverse section of the thorax at the interspace between the 3d and 4th thoracic vertebræ.
- FIG. 2. Transverse section of the thorax passing through the middle of the heart.
- FIG. 3. Transverse section of the neck passing through a pair of transverse processes of a vertebra.
- FIG. 4. Transverse section of the neck where the diverticula forming the supramedullary canal are given off from the two canales intertransversarii.
- FIG. 5. Transverse section of the neck at a point where supravertebral diverticula are given off from the canales intertransversarii.
- FIG. 6. Dorsal aspect of the pelvis after the removal of the skin.
- FIG. 7. Frontal aspect of the anterior diverticulum of the interclavicular sac and the adjacent parts.
- FIG. 8. Ventral aspect of the posterior part of the left lung.
- FIG. 9. Ventral aspect of the left lung. (Photographed with prism, therefore a reversed picture. $\times 2$.)
- FIG. 10. Dorsal aspect of the left lung after removal of its superficial portions. The lung has been injected with a dark-colored mass. A number of bronchial branches have been exposed by the dissection. (Photographed with prism, therefore a reversed picture.) $\times 2$.
- FIG. 11. View of the air-sacs that lie between the soft parts and the skeleton on the left side.
- FIG. 12. Dorsal view of the air-sacs that lie between the soft parts and the lungs. (The latter are represented as transparent.)

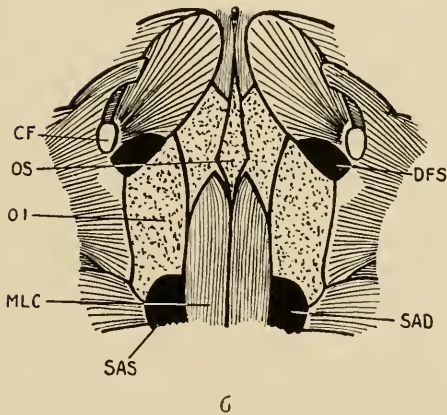
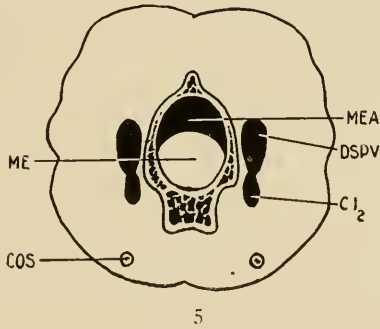
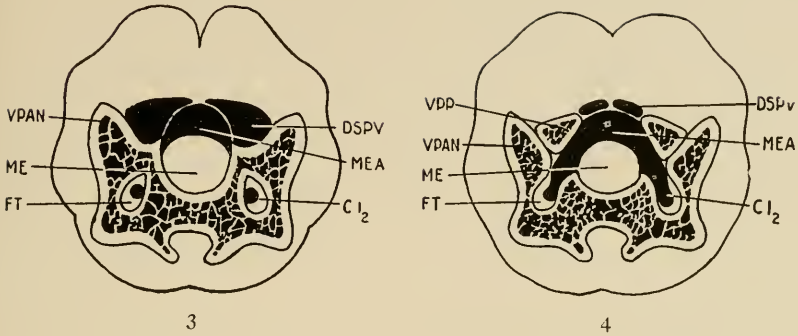
AP	Arteria pulmonalis. Fig. 9.
BR	Bronchus. Figs. 9, 10, and 12.
C	Costal impressions on the lung. Fig. 10.
CF	Caput femoris. Fig. 6.
CI 1	Canalis intertransversarius, enlarged portion. Figs. 11 and 12.
CI 2	Canalis intertransversarius. Figs. 3, 4, 5, 7, 11, and 12.
CI 3	Canalis intertransversarius, anterior end. Figs. 11 and 12.
CO	Cavum orale. Fig. 12.
COR	Heart. Fig. 2.
COS	Rib. Figs. 2 and 5.
CPRA	Canalis præacetabularis. Figs. 11 and 12.
DA 1	Diverticulum axillare. Figs. 11 and 12.
DA 2	Ventral outgrowth of same. Fig. 11.
DC	Diverticulum costale. Figs. 2 and 11.
DFA	Diverticulum femorale anterius. Figs. 11 and 12.
DFI	Diverticulum femorale inferius. Figs. 11 and 12.
DFP	Diverticulum femorale posterius. Figs. 11 and 12.
DFS	Diverticulum femorale superius. Figs. 6, 11, and 12.

DIA	Diaphragma abdominalis. Fig. 1.
DIP	Diaphragma pulmonalis. Fig. 1.
DOETR	Diverticulum œsophageo-tracheale. Figs. 7 and 11.
DSC	Diverticulum subcordale. Fig. 2.
DSH	Diverticulum suprahumeralis. Fig. 12.
DSOE	Diverticulum subœsophageale. Fig. 1.
DSPM 1	Diverticulum supramedullare (not in contact with that of the opposite side). Fig. 12.
DSPM 2	Diverticulum supramedullare (in contact with that of the opposite side). Figs. 11 and 12.
DSPOE	Diverticulum supra-œsophageale. Fig. 1.
DSPV	Diverticulum supravertebrale. Figs. 3, 4, 5, 7, 11, and 12.
DSSC 1	Diverticulum subscapulare, first portion. Figs. 7, 11, and 12.
DSSC 2	Diverticulum subscapulare, ventral outgrowth. Fig. 11.
DSSC 3	Diverticulum subscapulare, principal cavity. Figs. 2, 11, and 12.
DSSC 4	Diverticulum subscapulare, dorsal portion. Fig. 7.
DST	Diverticulum sternale. Figs. 2 and 11.
ECT	Ectobronchium primum ad septimum. Fig. 10.
ENT 1	Entobronchium primum. Fig. 10.
ENT 4	Entobronchium quartum. Fig. 10.
F	Furcula. Fig. 7.
FT	Foramen transversarii. Figs. 3, 4, and 7.
FTR	Foramen triosseum. Fig. 7.
H	Liver. Fig. 1.
L	Larynx. Fig. 12.
M	Mesobronchium. Figs. 1, 8, and 10.
ME	Medulla spinalis. Figs. 3, 4, 5, and 7.
MEA	Canalis supramedullaris, anterior portion. Figs. 3, 4, 5, 7, and 12.
MEP	Canalis supramedullaris, Posterior portion. Figs. 1, 2, and 12.
MF	Furcular membrane. Fig. 7.
MLC	Musculus levator coccygis. Fig. 6.
MP	Musculi Perraulti. Fig. 8.
OC	Ostium cervicale. Figs. 9, 10, and 12.
OCD	Os coracoideum. Fig. 7.
OCL	Ostium claviculare. Figs. 9 and 12.
OE	Æsophagus. Figs. 1, 2, 7, and 9.
OI	Os ischii. Fig. 6.
OIA	Ostium intermedium anterius. Figs. 9 and 12.
OIP	Ostium intermedium posterius. Figs. 8, 9, 10, and 12.
OIPB	Bronchial branch leading to the ostium intermedium posterius. Fig. 1.
OP	Ostium posterius. Figs. 8, 9, 10, and 12.
OS	Os sacrum. Fig. 6.
OSC	Scapula. Figs. 1 and 2.
P	Lung. Figs. 1, 2, 11, and 12.
PAR	Parabronchium. Fig. 10.
PAV	Processus articularis vertebræ. Fig. 7.
PL	Pleura. Fig. 9.
PU	Processus uncinatus. Fig. 1.
R	Kidney. Fig. 8.
S	Syrinx. Fig. 12.

SAD	Saccus abdominalis dexter. Figs. 6, 11, and 12.
SAS	Saccus abdominalis sinister. Figs. 6, 11, 12.
SASD	Dorsal wall of the left Saccus abdominalis. Fig. 8.
SC	Saccus cervicalis. Figs. 7 and 11.
SC 1	Saccus cervicalis, anterior portion. Fig. 12.
SC 2	Saccus cervicalis, pars ovalis. Fig. 12.
SCL	Saccus interclavicularis. Figs. 2, 11, and 12.
SCO 4	Os sternocostale quartum. Fig. 1.
SCO 5	Os sternocostale quintum. Fig. 1.
SI	Portion of the ventral surface of the lung covered by the Sacci intermedii, anterior and posterior. Fig. 9.
SIA	Saccus intermedius anterior. Figs. 1, 11, and 12.
SIAD	Dorsal wall of the Saccus intermedius anterior. Fig. 8.
SICL	Portion of the ventral surface of the lung covered by the Saccus interclavicularis. Fig. 9.
SIP	Saccus intermedius posterior. Figs. 11 and 12.
SIPD	Dorsal wall of the Saccus intermedius posterior. Fig. 8.
ST	Sternum. Figs. 1 and 2.
STC	Crista sterni. Figs. 1 and 2.
T	Entrance to trachea. Fig. 12.
TR	Trachea. Figs. 2, 7, 11, and 12.
V	Vestibulum. Fig. 10.
VE	Vertebra. Fig. 1.
VP	Vena pulmonalis. Fig. 9.
VPAN	Processus anterior vertebræ. Figs. 3 and 4.
VPP	Processus posterior vertebræ. Fig. 4.
X	Limiting wall between the Saccus interclavicularis and the Sacci intermedii anteriores. Fig. 8.
Y	Muscles of the neck. Fig. 7.



FIGS. 1, 2.—Transverse sections of thorax of pigeon. See page 412.



Figs. 3, 4, 5.—Transverse sections of neck of pigeon. FIG. 6.—Dorsal aspect of pelvis. See page 412.

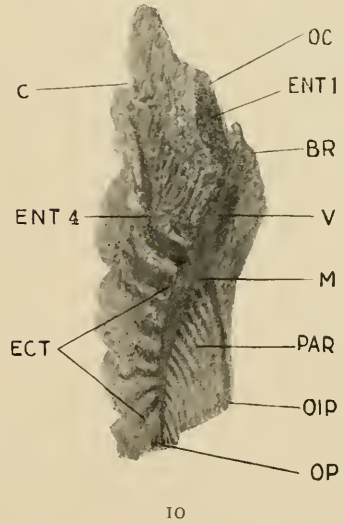
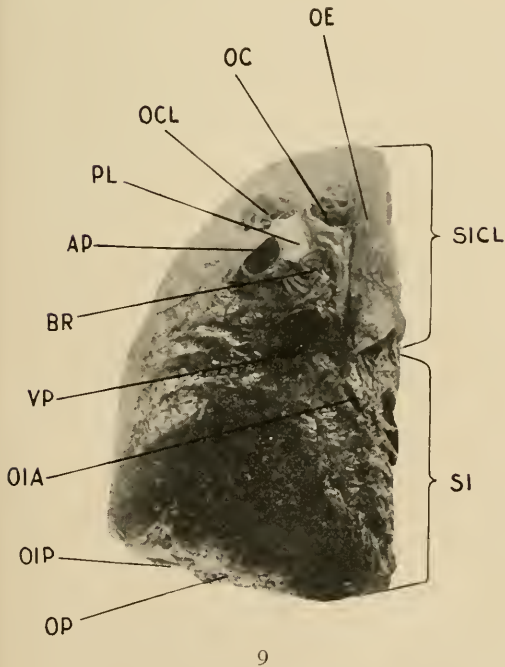
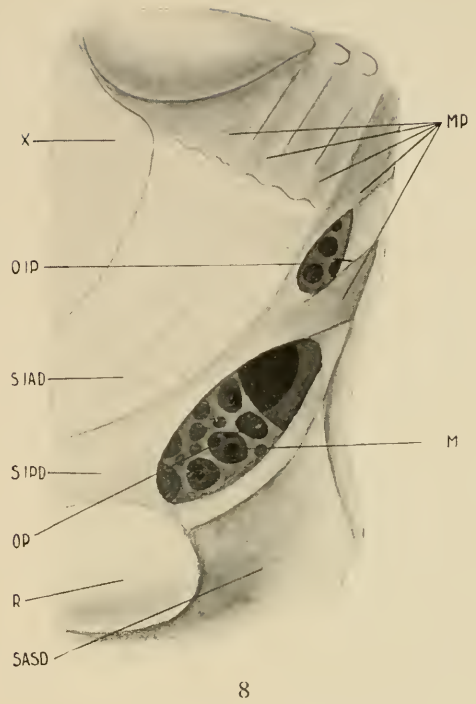
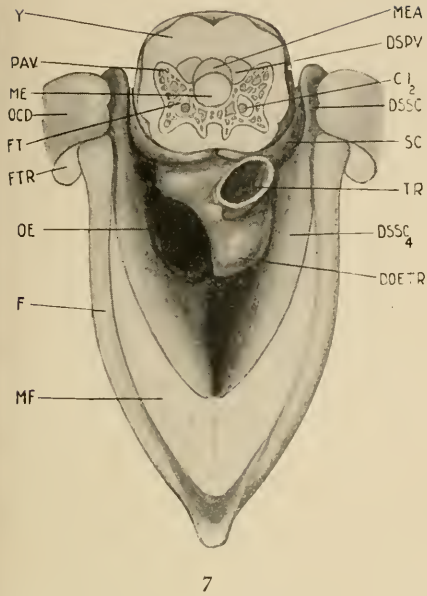
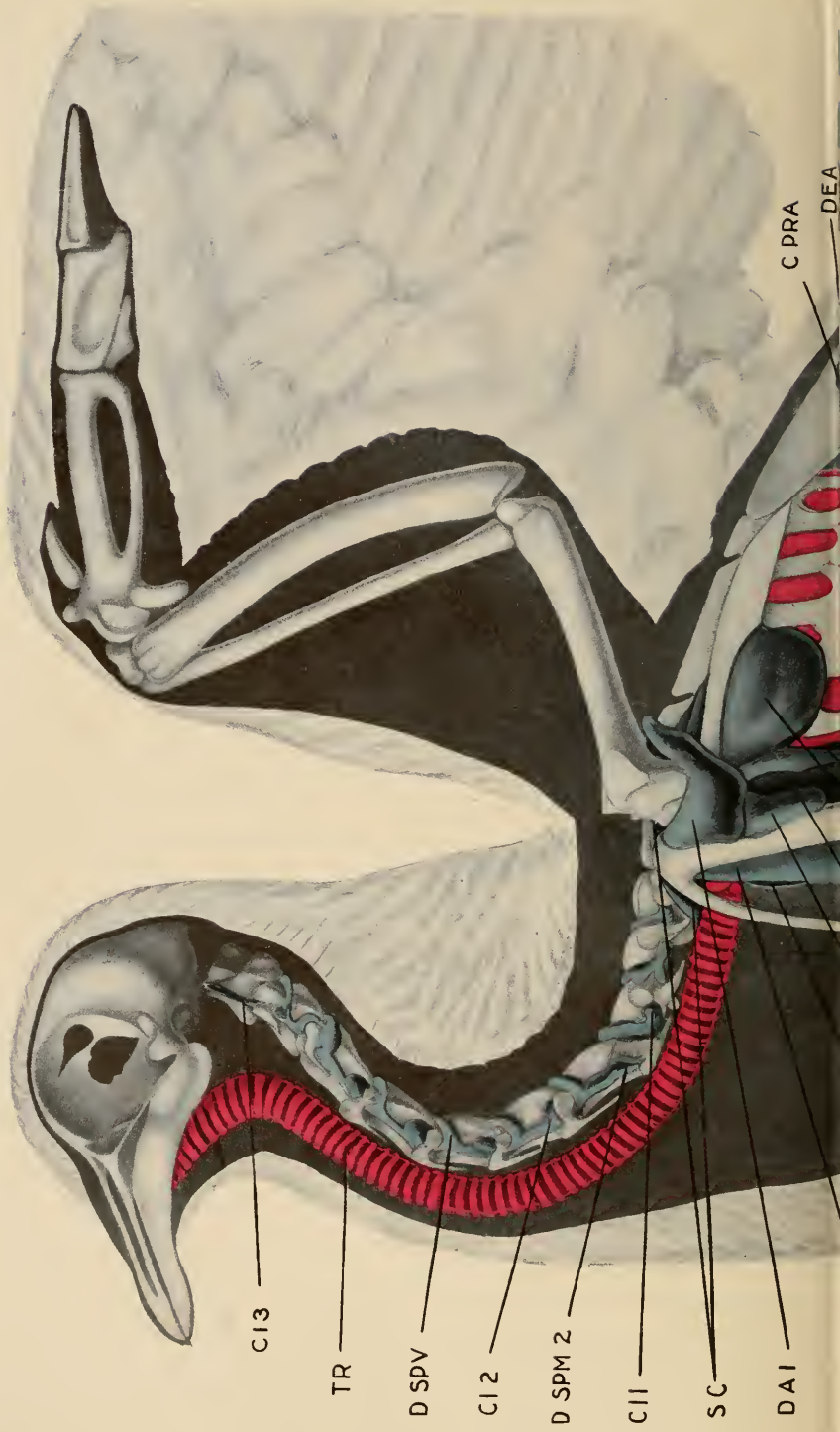

FIG. 7.—Anterior diverticulum of interclavicular sac. FIGS. 8, 9, 10.—Ventral and dorsal aspects of lung of pigeon. See page 412.



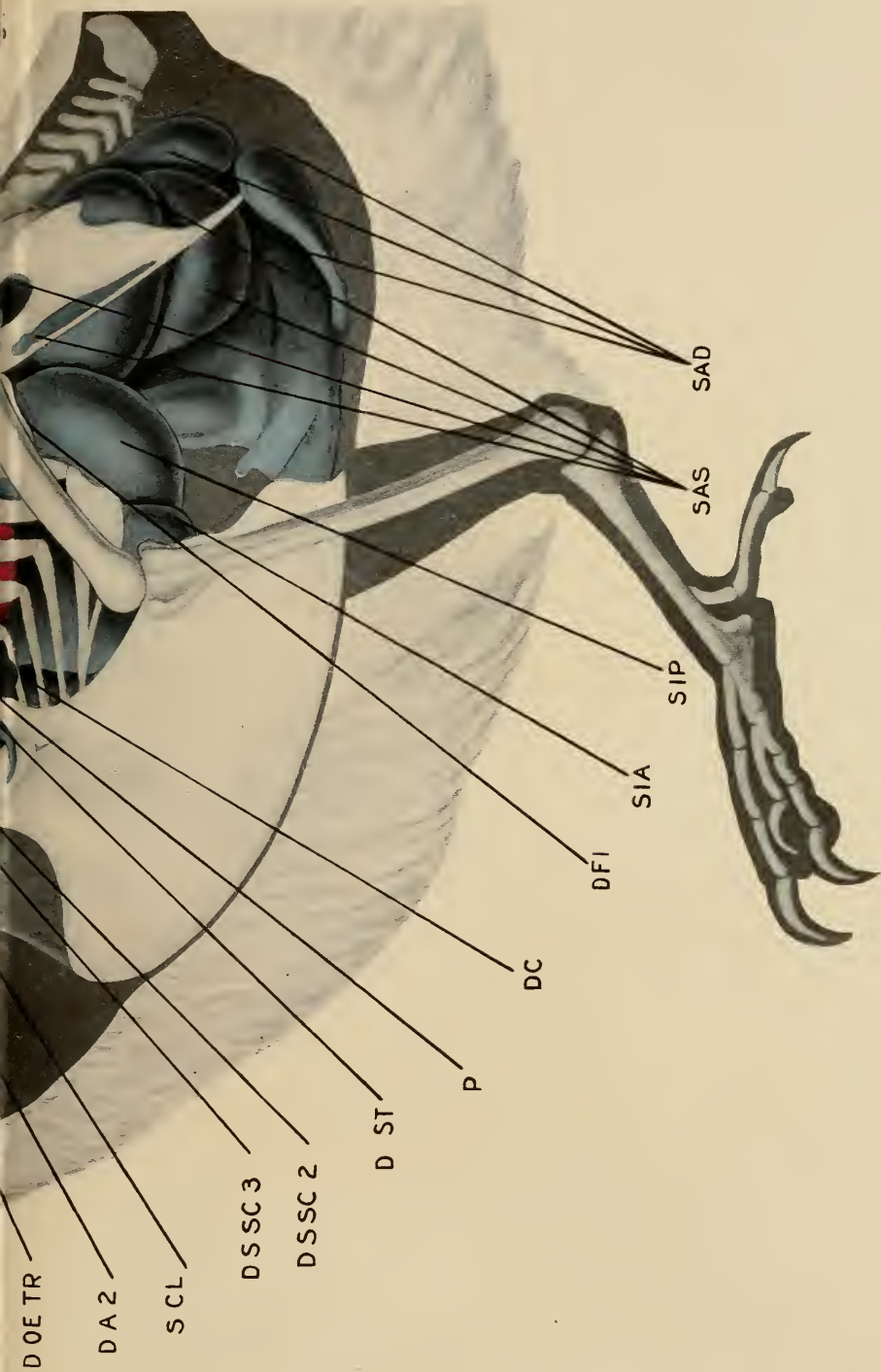


FIG. 11 VIEW OF THE AIR-SACS THAT LIE BETWEEN THE SOFT PARTS AND THE SKELETON ON THE LEFT SIDE.

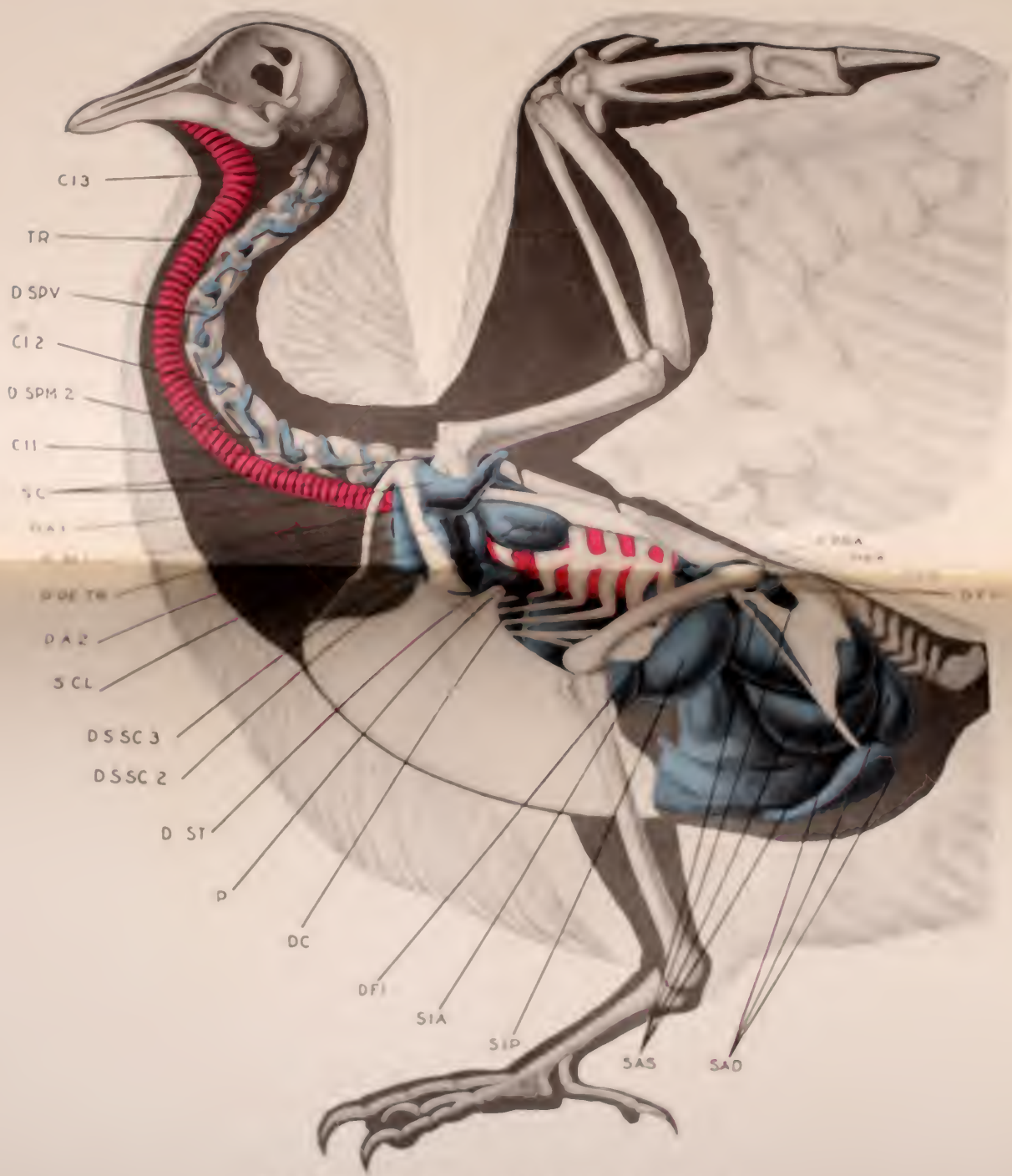
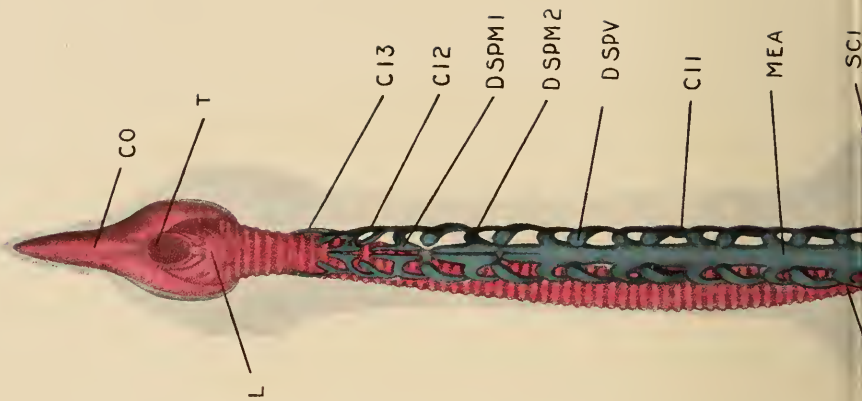


FIG. 10. VIEW OF THE THORACIC MUSCLES BETWEEN THE LEFT WING AND THE SKIN (FIG. 9) OF THE LEFT SIDE.



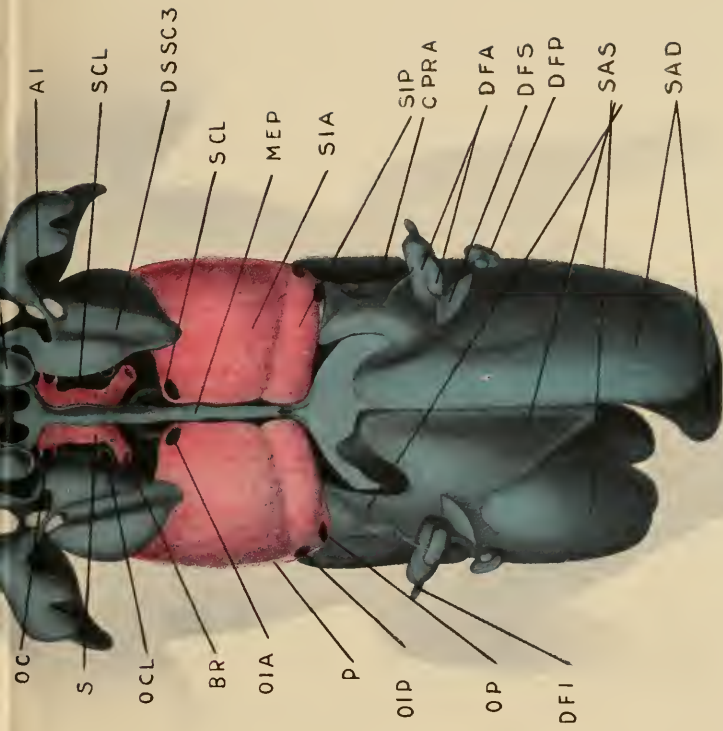


FIG. 12 DORSAL VIEW OF THE AIR-SACS THAT LIE BETWEEN THE SOFT PARTS AND THE LUNGS. (THE LATTER ARE REPRESENTED AS TRANSPARENT).

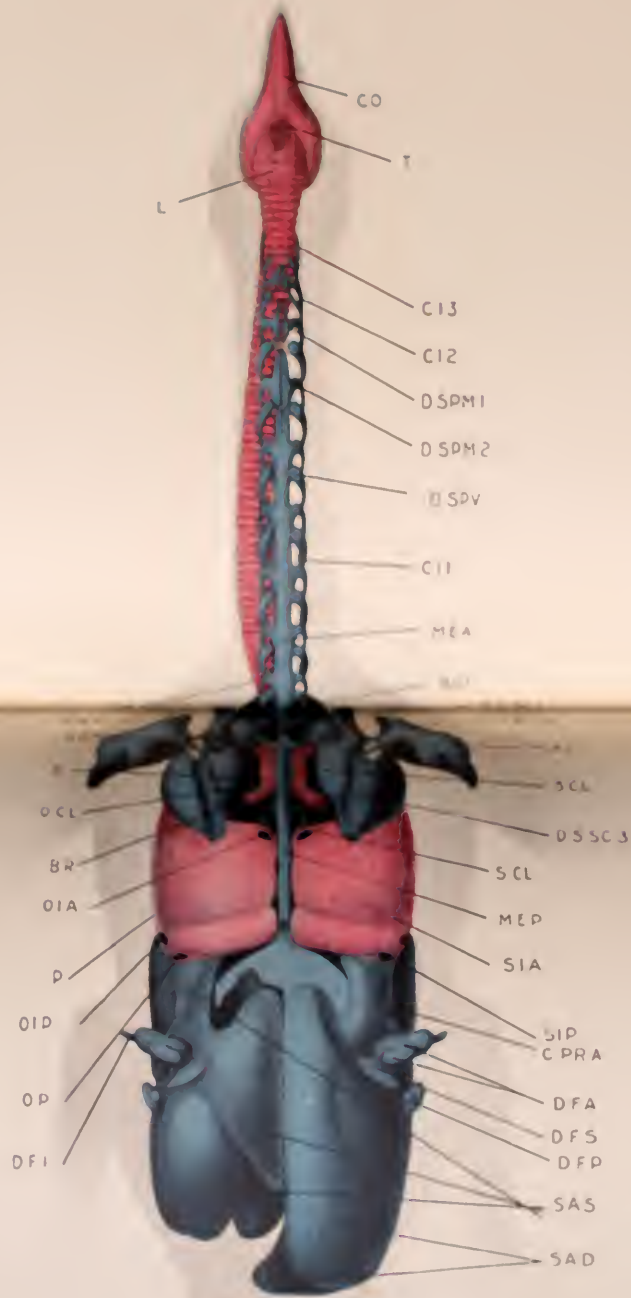


FIG. 10. FRONTAL VIEW TO THE AIRSAC THAT LIES BETWEEN THE SOFT PARTS AND THE THROAT. THE LATTER ARE REPRESENTED AS TRANSPARENT.

