

# Suppurative Arthritis in an Infant Orangutan

Paul Jack Hoopes, DVM; Douglas W. McKay, MD; Gordon W. Daisley, Jr., MD;  
Suzanne Kennedy, DVM; Mitchell Bush, DVM

## SUMMARY

A 12-day-old male orangutan (*Pongo pygmaeus*) was removed from its mother because of oral ulcers and reluctance to suckle. Close examination revealed ulcerations extended to the mandibular bone.

*Staphylococcus aureus* was cultured from the oral lesions. Despite intensive antibiotic therapy, the infection progressed to septicemia, with suppurative arthritis of the left coxofemoral and right radiohumeral joints. Treatment included removal of synovial exudate by aspiration, indwelling drains, and arthrotomy. Antibiotics were administered systemically and by joint irrigation. The infant responded well to the treatment, which lasted for approximately 2 months.

coagulase-positive *Staphylococcus aureus* and a  $\beta$ -hemolytic *Streptococcus* sp were isolated. Hematologic values remained within normal limits (II, Table 1). Body temperature was normal (36.4 C).

Treatment was begun with ampicillin<sup>d</sup> (5.7 mg/kg of body weight, QID, SQ) and kanamycin<sup>e</sup> (3.6 mg/kg, QID, SQ). While awaiting results of the fungal cultures, topical nystatin solution<sup>f</sup> and povidine-iodine were applied to the oral lesions. A small superficial ulceration on the swollen toe was swabbed with povidine-iodine, QID.

Due to the infant's deteriorating condition and the severity of the oral lesions, it was permanently removed from its mother and was maintained in the intensive care unit at the zoo hospital. Initially, the orangutan was reluctant to suckle, which led to dehydration, as detected by decreased elasticity of the skin and increased specific gravity (from 1.011 to 1.030) of the urine. An electrolyte solution<sup>g</sup> (30 ml/kg/day) and an amino acid solution<sup>h</sup> (7 ml/kg/day) were administered subcutaneously as needed, until oral intake of the milk-replacement formula<sup>i</sup> began to increase. The fluids also served to minimize the potential nephrotoxic effects of the kanamycin.

After 5 days' therapy, the infant's condition worsened. Clinical changes included fever (38.7 C), sneezing, lethargy, decreased appetite, and a weight loss of 500 g. In spite of these changes, hematologic values were only slightly altered and still within normal ranges (III, Table 1). Antibiotic therapy was changed to carbenicillin<sup>j</sup> (80 mg/kg, QID, SQ) and tobramycin<sup>k</sup> (1 mg/kg, TID, SQ). Both antibiotics had good in vitro activity against the *S aureus* cultured from the oral lesions. Fungal cultures of the oral lesions were negative, but antifungal medication (miconazole,<sup>l</sup> 15 mg/kg, QID, orally; and gentian violet,<sup>m</sup> QID, topically) was given as a preventive measure.

At 14 days, the oral ulcers began to heal, but there was enlargement of the left inguinal lymph node and generalized swelling and increased warmth of the left coxofemoral and right radiohumeral areas. Manipulation of these areas was painful to the orangutan, and the grasping strength of its right hand and left foot was decreased. Radiographs of the right radiohumeral and

---

NEONATAL SEPTICEMIAS are well-documented in man<sup>1,2</sup> and in other animals,<sup>3-7</sup> often localizing in joints.<sup>1-7</sup> The source of infection is commonly the umbilicus,<sup>4,6,7</sup> but infection may gain entry by other routes.<sup>4,6,7</sup> This report is intended to demonstrate the need for prompt, vigorous therapy of neonatal infection in primates.

## Case Report

A male orangutan (*Pongo pygmaeus*), weighing 2.2 kg, was born at the National Zoological Park, Washington, DC, on Dec 14, 1977. Approximately 12 hours after birth, the infant's umbilicus was swabbed with povidine iodine<sup>a</sup> and was ligated. Injections of benzathine penicillin G<sup>b</sup> (85,000 units/kg) and iron dextran<sup>c</sup> (25 mg) were given intramuscularly. Hematologic values were considered to be in the normal range (I, Table 1). The neonatal treatment was presumed necessary because of fatal meningitis secondary to an umbilical infection in an infant previously born to the mother.

Twelve days after birth, white necrotic plaques were seen on the infant's tongue and lower gingiva. The infant also had a weakened voice, a reduced sucking reflex, a swollen umbilicus, and a swollen toe on the left foot. Specimens taken from the oral lesions were cultured for anaerobic and aerobic bacteria as well as fungi. A

From the Office of Animal Health, National Zoological Park, Smithsonian Institution, Washington, DC 20008 (Hoopes, Kennedy, Bush); the Orthopedic Department, Children's Hospital, National Medical Center, Washington, DC 20010 (McKay); and Pediatric Consultant to the National Zoological Park (Daisley). Dr. Kennedy's present address is Department of Environmental Practice, College of Veterinary Medicine, University of Tennessee, PO Box 1071, Knoxville, TN 37901.

<sup>a</sup> Betadine, Purdue Frederick Co, Norwalk, Conn.

<sup>b</sup> Flo-Cillin, Bristol Laboratories, Syracuse, NY.

<sup>c</sup> Iron dextran, Bialek's Medical Arts Pharmacy, Inc, Washington, DC.

<sup>d</sup> Polyflex, Bristol Laboratories, Syracuse, NY.

<sup>e</sup> Kantrim, Bristol Laboratories, Syracuse, NY.

<sup>f</sup> Mycostatin, ER Squibb and Sons, Inc, Princeton, NJ.

<sup>g</sup> Lactated Ringer's solution, Abbott Laboratories, Chicago, Ill.

<sup>h</sup> Aminoplex solution, Med-Tech, Inc, Elwood, Kan.

<sup>i</sup> Prosobee, Mead Johnson Laboratories, Evansville, Ind. Pedalyte (oral electrolytes), Ross Laboratories, Columbus, Ohio.

<sup>j</sup> Geopen, Roerig (Pfizer Pharmaceuticals), New York, NY.

<sup>k</sup> Tobramycin, Eli Lilly and Co, Indianapolis, Ind.

<sup>l</sup> Miconazole, Janssen Pharmaceutica, Beerse, Belgium.

<sup>m</sup> Gentian violet, Webcon Pharmaceuticals, Fort Worth, Tex.

TABLE 1—Results of Hematologic Examinations

	WBC/ mm <sup>3</sup>	Neutro- phils/ mm <sup>3</sup>	Band neutro- phils/ mm <sup>3</sup>	Lympho- cytes/ mm <sup>3</sup>	Mono- cytes/ mm <sup>3</sup>	Eosino- phils/ mm <sup>3</sup>	Packed cell volume (%)	Hemo- globin (g/dl)	Red blood cells (10 <sup>9</sup> / dl)	Mean corpus- cular volume (fl)	Mean corpus- cular hemo- globin (pg)	Mean corpus- cular hemo- globin concen- tration (g/dl)	Total protein (g/dl)
I													
12/14/77	14,000	9,100	140	4,340	140	280	33.5	8.0	5.30	63	15	24	5.8
II													
12/26/77	18,600	13,764	744	3,162	1,302	.....	30.0	9.4	3.52	.....	.....	.....	6.2
III													
12/30/77	19,000	11,590	570	4,940	1,520	380	28.0	8.4	3.55	.....	.....	.....	5.7
IV													
1/10/78	12,700	7,747	889	3,429	508	127	21.0	6.1	2.60	81	23	29	6.1
V													
1/19/78	12,100	5,082	484	6,171	363	.....	25.5	6.6	3.62	.....	.....	.....	5.8

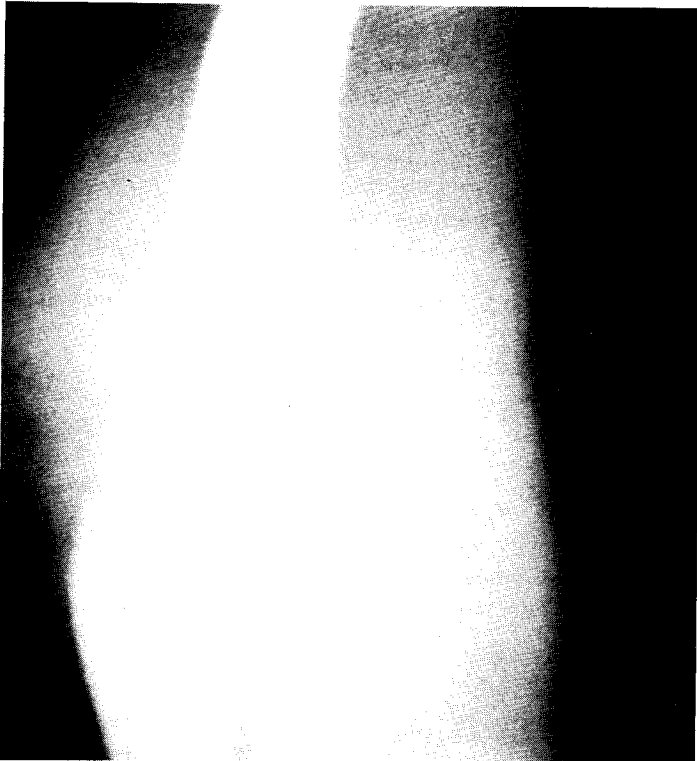


Fig 1—Oblique radiograph of the right elbow, showing enlargement of the joint, increased density within the joint capsule, and widening of the joint space.

left coxofemoral joints showed a widening of the joint spaces (Fig 1 and 2). The right radiohumeral joint area (Fig 1) had an increased density and the left femoral head (Fig 2) appeared radiolucent. Body temperature was 38.3 C. Hematologic examination revealed a slight left shift of the white blood cells and moderate anemia (IV, Table 1). An erythrocyte sedimentation rate value of 25 mm/hour was considered normal, based on values in human infants of similar age. Arthrocentesis of both affected joints yielded thick, yellow-white exudate; culture revealed coagulase-positive *S aureus* identical to that previously cultured from the infant's mouth. This finding incriminated the oral infection as the most probable source of the joint sepsis. Cultures for anaerobic bacteria and mycoplasma were negative.

Due to the lack of clinical improvement, all prior treatments were discontinued and a regimen of chloramphenicol<sup>n</sup> (30 mg/kg, qid, orally), hot packs applied

<sup>n</sup> Chloromycetin Palmitate, Parke, Davis & Co, Detroit, Mich.

topically to the joints, and multiple joint aspirations followed by infusion with lincomycin<sup>o</sup> (90 mg, BID) was initiated. After 3 days' therapy, the joint swellings had not decreased and the infant had an increased pain response when the joints were moved or handled. The orangutan was anesthetized with 1% to 2% halothane<sup>p</sup> and N<sub>2</sub>O/O<sub>2</sub> at a ratio of 1.5/1.5 L/minute by face mask and endotracheal tube. The radiohumeral joint was incised anterolaterally and the coxofemoral joint anteriorly. Viscous fibrinopurulent material was removed from both joint cavities. The periarticular tissues were inflamed, but the articular cartilages appeared normal. Drains modified from polyethylene tubing were instilled into the joints to provide drainage. The joints were irrigated with physiologic saline solution and lincomycin (90 mg) twice each day for 3 days.

Five days after the drains were installed, they were removed by the patient. Within 48 hours, the coxofemoral area was again swollen. Body temperature had risen to 40 C and appetite and behavior were depressed. Both joints were reopened surgically and left open for drainage. Antibiotic therapy was changed to cephalixin<sup>q</sup> (60 mg/kg, qid, sq). Acetaminophen<sup>r</sup> was given (60 mg/tid, orally) for 36 hours to control the fever. Within 48 hours, body temperature had dropped to 38.3 C, and behavior and feeding were returning to normal. Hematologic examination revealed a slight left shift of the white blood cells and an increased packed cell volume (V, Table 1). Fourteen days after the joints were opened, antibiotics were discontinued; joint swelling and pain were greatly reduced and drainage had subsided. Restriction of joint mobility was not evident.

Periodic diarrhea was treated successfully with lactobacillus granules,<sup>s</sup> kaopectate,<sup>t</sup> and paregoric.<sup>u</sup> A vitamin supplement<sup>v</sup> (0.5 ml/day) was added to the orangutan's formula.

## Discussion

Delays in diagnosis and treatment of joint infections appear to be the most important factors affecting prognosis.<sup>1-3,5,8-11</sup> The lack of leukocytosis and typical clin-

<sup>o</sup> Lincocin, The Upjohn Co, Kalamazoo, Mich.

<sup>p</sup> Fluothane, Ayerst Laboratories, Inc, New York, NY.

<sup>q</sup> Keflex, Ely Lilly and Co, Indianapolis, Ind.

<sup>r</sup> Liquiprin, Mitchum-Thayer, Inc, New York, NY.

<sup>s</sup> Lactinex granules, Hynson, Westcott and Dunning, Inc, Baltimore, Md.

<sup>t</sup> Kaopectate concentrate, The Upjohn Co, Kalamazoo, Mich.

<sup>u</sup> Paregoric, McKesson Laboratories, Fairfield, Conn.

<sup>v</sup> Poly-vite, Wolins Pharmacal Corp, Melville, NY.

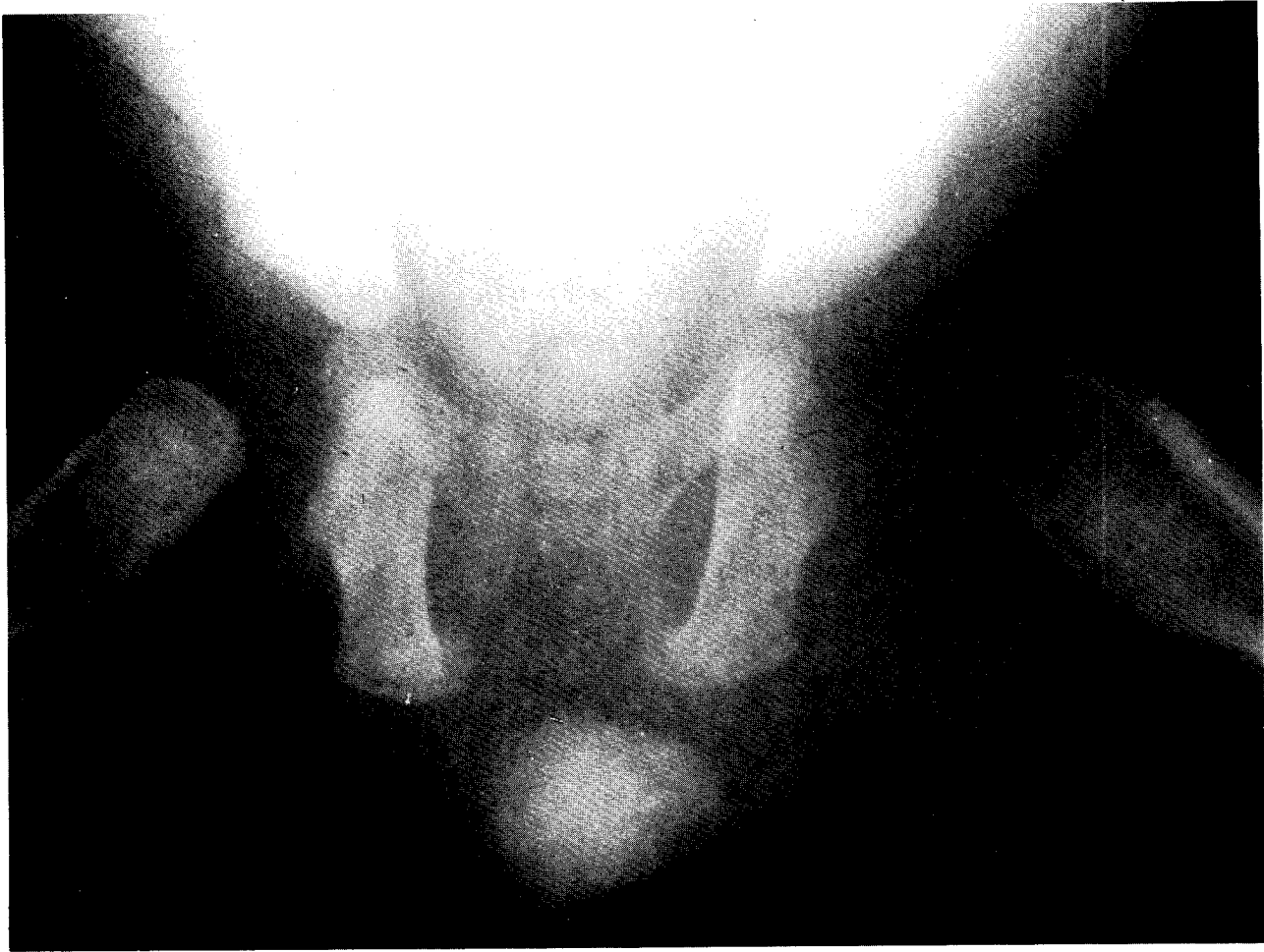

Fig 2—Ventrodorsal radiograph of the pelvis, demonstrating radiolucency of the left femoral head and widening of the left coxofemoral joint space. (The right coxofemoral joint is radiographically normal.)

ical signs (inappetence, limited movement, fever, pain) should not rule out the diagnosis of suppurative arthritis. Clinical signs and laboratory data in this orangutan were initially unimpressive.

In suspected cases of suppurative arthritis, hematologic and radiographic examinations and arthrocentesis should be performed immediately. The joint aspirate should be cultured and examined for inflammatory cells and microorganisms. Gram stains of the aspirate should be used as a preliminary guide to antibiotic therapy. Radiographic changes indicative of suppurative arthritis include distention of the joint capsule, increased opacity within the joint, increased distance between subchondral bone ends, and occasional erosion of the epiphysis.<sup>2,9</sup>

Treatment of suppurative arthritis in man and in hospitalized animals should include joint aspiration or arthrotomy to evacuate any exudate.<sup>1,2,5,8-11</sup> Severe damage can be done to the articular cartilage by the proteolytic enzymes of the neutrophils if they are not promptly removed.<sup>8</sup> Marked improvement in the orangutan in the present report did not occur until the affected joints were surgically opened for drainage. Closure is unnecessary in a clean environment and may even impede healing. Joint irrigation with isotonic saline solution until washings are clear is recommended.<sup>1-7,10,11</sup> Use of antibiotics systemically and by irrigation of the joint is also advised. In cases in which the articular cartilage has been severely damaged, affected joints are

immobilized to prevent ankylosis in unsatisfactory positions.<sup>1,2,10</sup> Appropriate antimicrobial and supportive therapy should be continued for 2 to 3 weeks after the patient has become afebrile, after joint effusion has ceased,<sup>2</sup> and after joint cultures are negative.<sup>5</sup>

## References

1. Cole WG, Elliot BG, Jensen F: The management of septic arthritis in childhood. *Aust NZ J Surg* 45:178-182, 1975.
2. Nade S: Acute septic arthritis in infancy and childhood. *Aust Paediatr J* 11:145-153, 1975.
3. Barrett RE: Canine polyarthritis, in Kirk RW (ed): *Current Veterinary Therapy VI, Small Animal Practice*. Philadelphia, WB Saunders Co, 1977, vol 6, pp 890-892.
4. Blood DC, Henderson JA: *Veterinary Medicine*, ed 4. Baltimore, The Williams & Wilkins Co, 1974, pp 41-42; 232-235.
5. Brown S G: Joint diseases, in Ettinger SJ (ed): *Textbook of Veterinary Internal Medicine*. Philadelphia, WB Saunders Co, 1976, pp 1761-1763.
6. Siegmund OH (ed): *The Merck Veterinary Manual*, ed 4. Rahway, NJ, Merck & Co, 1973, pp 394-398; 554-555.
7. Smith HA, Jones TC, Hunt RD: *Veterinary Pathology*, ed 4. Philadelphia, Lea & Febiger, 1972, pp 1079-1081.
8. Lichtenstein L: *Diseases of Bones and Joints*, ed 2. St Louis, The CV Mosby Co, 1975, pp 270-271.
9. Morrey BF, Bianco AJ, Rhodes KH: Suppurative arthritis in the hip in children. *J Bone Joint Surg (Am)* 55-A: 388-392, 1976.
10. Morrey BF, Bianco AJ Jr, Rhodes KH: Septic arthritis in children, in Kelly PH, Fitzgerald RH Jr (ed): *Orthop Clin North Am* 6:923-934, 1975.
11. Salter RB: Integument and Musculoskeletal System, in Mustard WT, Ravitch MM, Snyder WH Jr, et al (ed): *Pediatric Surgery*, ed 2. Chicago, Year Book Medical Publishers, 1975, vol 2, part 4, 1472-1473.